

Index

- [1- Glenohumeral Joint Anatomy Stabilizer And Biomechanics](#)
- [2- Shoulder Exam](#)
- [3- Rotator Cuff Arthropathy](#)
- [4- Rotator Cuff Tears](#)
- [5- Subacromial Impingement](#)
- [6- Calcific Tendonitis](#)
- [7- Biceps Tendonitis](#)
- [8- Biceps Subluxation](#)
- [9- Os Acromiale](#)
- [10- Phases Of Throwing](#)
- [11- Acromioclavicular Joint Injury](#)
- [12- Distal Clavicle Osteolysis](#)
- [13- Luxatio Erecta Inferior Glenohumeral Joint Dislocation](#)
- [14- Multidirectional Shoulder Instability Mdi](#)
- [15- Traumatic Anterior Shoulder Instability Tubs](#)
- [16- Posterior Shoulder Instability And Dislocation](#)
- [17- Internal Impingement](#)
- [18- Glenohumeral Internal Rotation Deficit Gird](#)
- [19- Slap Lesion](#)
- [20- Little Leaguers Shoulder](#)
- [21- Posterior Labral Tear](#)
- [22- Thoracic Outlet Syndrome](#)
- [23- Scapulothoracic Dyskinesia](#)
- [24- Scapular Winging](#)
- [25- Quadrilateral Space Syndrome](#)
- [26- Suprascapular Neuropathy](#)
- [27- Brachial Neuritis Parsonage Turner Syndrome](#)
- [28- Pectoralis Major Rupture](#)
- [29- Total Shoulder Arthroplasty](#)
- [30- Reverse Shoulder Arthroplasty](#)
- [31- Shoulder Hemiarthroplasty](#)
- [32- Shoulder Arthrodesis](#)
- [33- Glenohumeral Arthritis Shoulder Arthritis](#)
- [34- Adhesive Capsulitis Frozen Shoulder](#)
- [35- Avascular Necrosis Of The Shoulder](#)
- [36- Shoulder Prosthetic Joint Infection](#)

[37- Elbow Anatomy And Biomechanics](#)

[38- Elbow Stiffness And Contractures](#)

[39- Elbow Arthritis](#)

[40- Total Elbow Arthroplasty](#)

[41- Olecranon Stress Fracture](#)

[42- Medial Ulnar Collateral Ligament Injury](#)

[43- Valgus Extension Overload Pitchers Elbow](#)

[44- Little League Elbow](#)

[45- Lateral Ulnar Collateral Ligament Injury Pri](#)

[46- Distal Biceps Avulsion](#)

[47- Lateral Epicondylitis Tennis Elbow](#)

[48- Triceps Rupture](#)

[49- Medial Epicondylitis Golfers Elbow](#)

[50- Osteochondritis Dissecans Of Elbow](#)

[51- Elbow Arthroscopy Indications And Approach](#)

[52- Shoulder Arthroscopy Indications And Approach](#)

[53- Partial Elbow Arthroplasty](#)

[54- Flexor Pronator Strain](#)

[55- Acromioclavicular Joint](#)

[56- Sternoclavicular Joint](#)

[57- Scapulothoracic Joint](#)

[58- Shoulder Imaging](#)

[59- Subcoracoid Impingement](#)

[60- Ac Arthritis](#)

[61- Scapulothoracic Crepitus](#)

[62- Deltoid Rupture](#)

[63- Latissimus Dorsi Rupture](#)

[64- Shoulder Resurfacing](#)

[65- Elbow Physical Exam](#)

[66- Humeral Avulsion Glenohumeral Ligament Hagl](#)

[67- Shoulder Periprosthetic Fracture](#)

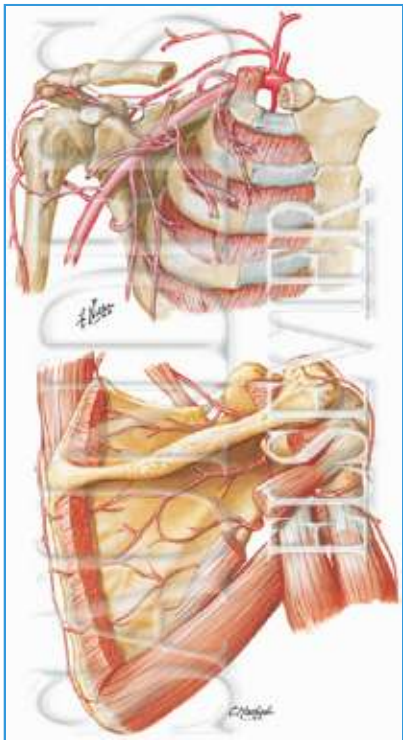
[68- Revision Total Elbow Arthroplasty](#)

[69- Neuropathic Charcot Joint Of The Elbow](#)

[70- Neuropathic Charcot Joint Of Shoulder](#)

1- Glenohumeral Joint Anatomy Stabilizer And Biomechanics

Images



Planes of Motion

- Reference
 - scapular plane is 30 degrees anterior to coronal plane.
- Abduction
 - abduction requires external rotation to clear the greater tuberosity from impinging on the acromion.
 - therefore if someone has an internal rotation contracture they can not abduct > 120
 - 180° of abduction present in shoulder
 - motion occurs at two joints
 - 120° from the glenohumeral joint (2/3)
 - 60° from the scapulothoracic joint (1/3)

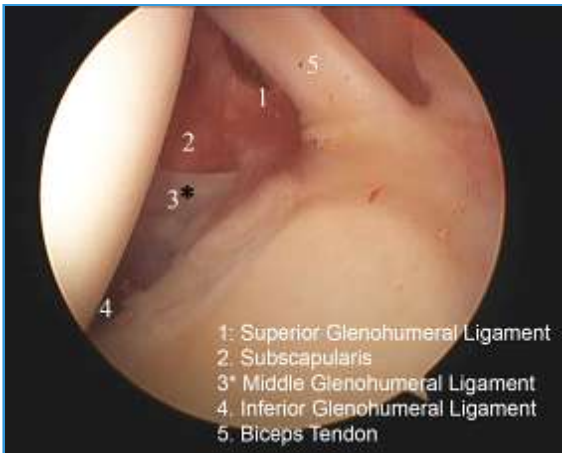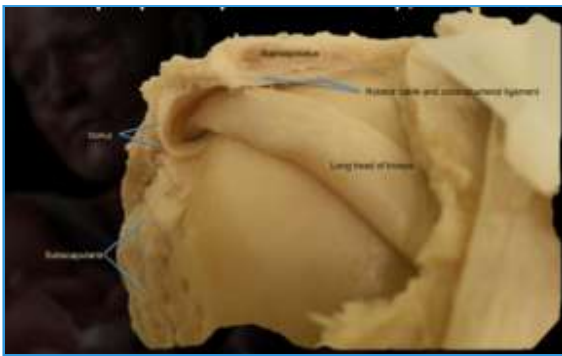
Glenohumeral Stability

- Static restraints
 - glenohumeral ligaments (below)
 - glenoid labrum (below)
 - articular congruity and version
 - negative intraarticular pressure
 - if release head will sublux inferiorly
- Dynamic restraints
 - rotator cuff muscles
 - the primary biomechanical role of the rotator cuff is stabilizing the glenohumeral joint by compressing the humeral head against the glenoid
 - rotator interval
 - biceps long head
 - periscapular muscles

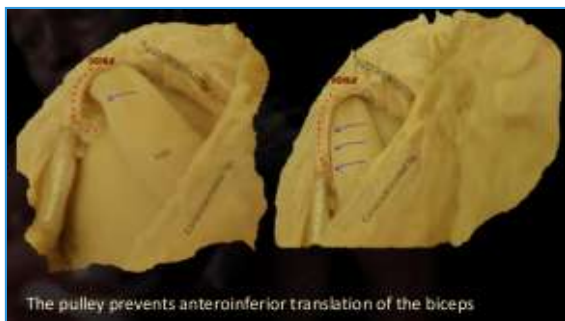
Glenohumeral Ligaments (static)

■ Ligamentous Restraints in different Arm Positions			
■ <i>Arm position</i>	■ <i>Anterior restraint</i>	■ <i>Inferior restraint</i>	■ <i>Posterior restraint</i>
■ 0° (side) and adduction	■	■ SGHL/CHL	■
■ 45° (ER) and 45° abducted	■ MGHL	■	■ MGHL
■ 90° (ER)	■ Anterior band IGHL	■ Anterior band IGHL	■ Posterior band IGHL
■ 90° (forward flexed, abduction, and IR)	■ Anterior band IGHL	■	■ SGHL/CHL

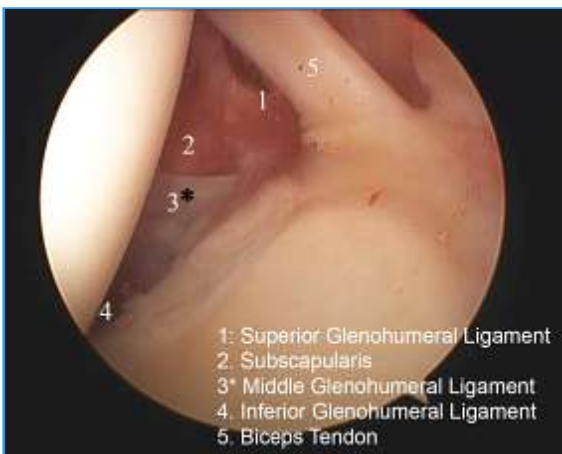- SGHL



- from anterosuperior labrum to humerus
- restraint to inferior translation at 0° degrees of abduction (neutral rotation)
- prevents anteroinferior translation of long head of biceps (biceps pulley)

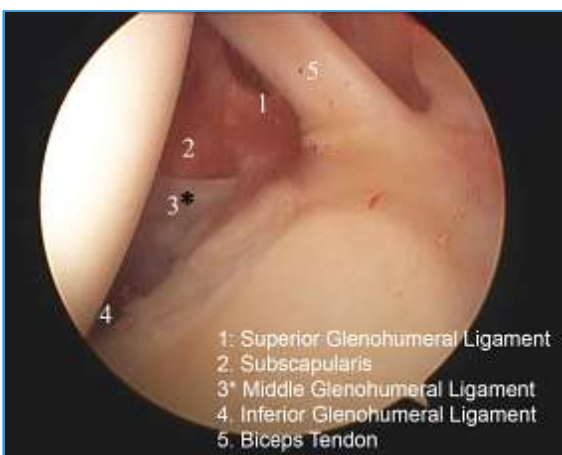

○ MGHL



- resist anterior and posterior translation in the midrange of abduction (~45°) in ER

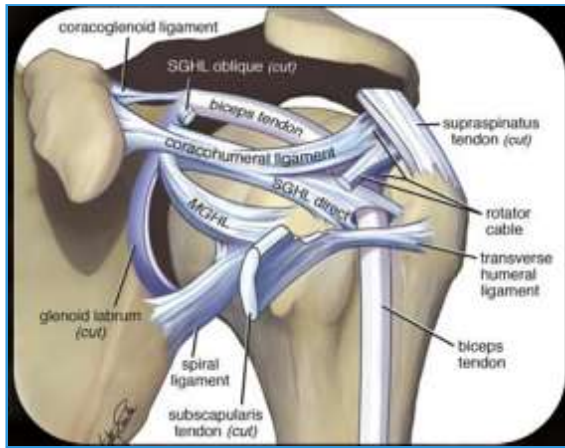
○ IGHL



- posterior band IGHL
 - most important restraint to posterior subluxation at 90° flexion and IR
 - tightness leads to internal impingement and increased shear forces on superior labrum (linked to SLAP lesions)
- anterior band IGHL
 - stability
 - primary restraint to anterior/inferior translation 90° abduction and maximum ER (late cocking phase of throwing)
 - anatomy
 - anchors into anterior labrum
 - forms weak link that predisposes to Bankart lesions
- superior band IGHL
 - most important static stabilizer about the joint

- 100% increased strain on superior band of IGHL in presence of a SLAP lesion

- Coracohumeral ligament (CHL)



- from coracoid to rotator cable
- limits posterior translation with shoulder in flexion, adduction, and internal rotation
- limits inferior translation and external rotation at adducted position

- Glenoid Labrum (static)

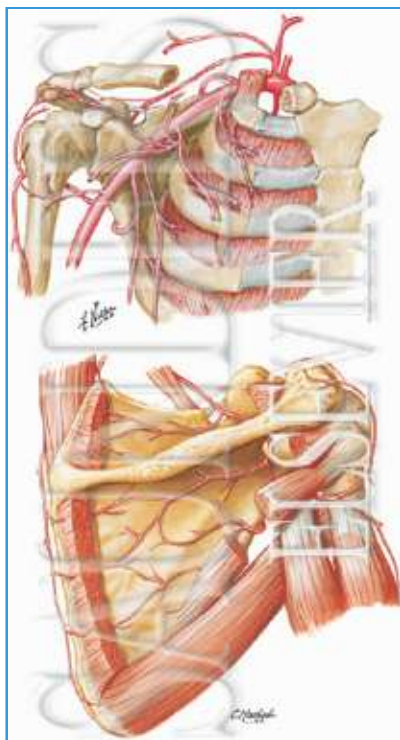
- Function

- helps create cavity-compression and creates 50% of the glenoid socket depth

- Composition

- composed of fibrocartilagenous tissue

- Blood supply



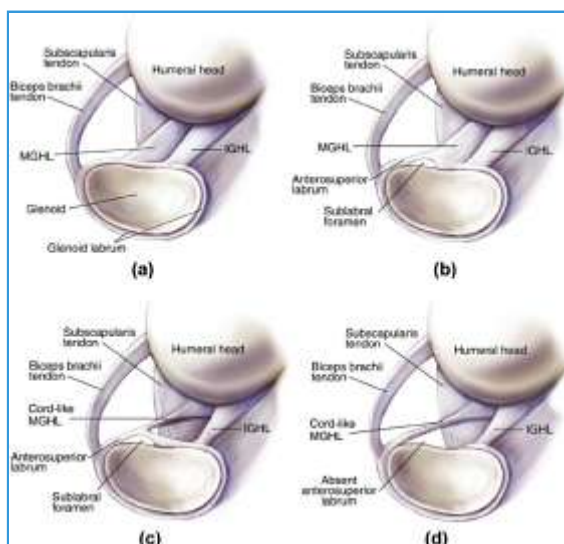
- suprascapular artery
- anterior humeral circumflex scapular
- posterior humeral circumflex arteries
- labrum receives blood from capsule and periosteal vessels and not from underlying bone
- anterior-superior labrum has poorest blood supply

- Stability

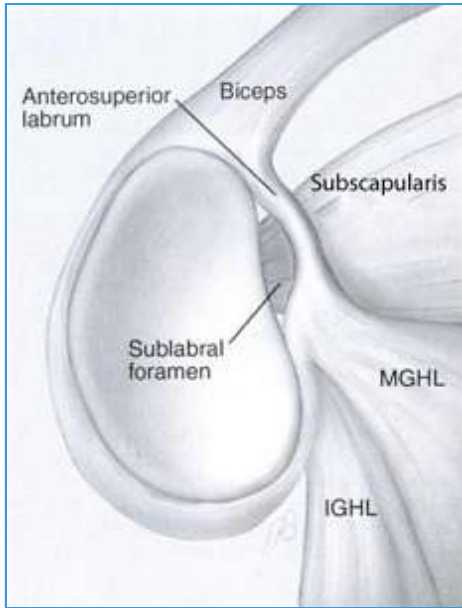
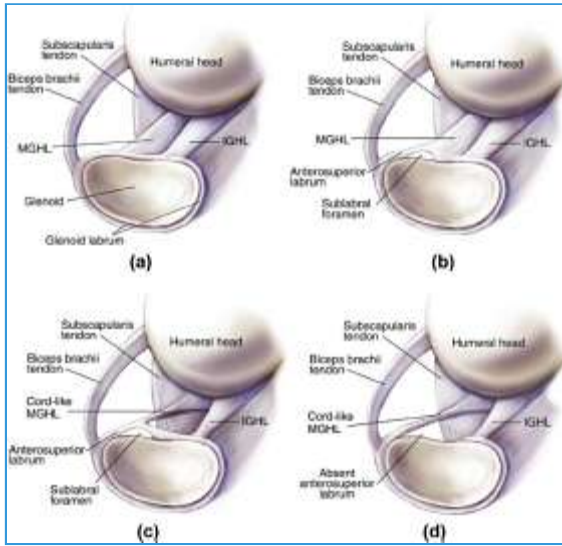
- anterior labrum
 - anchors IGHL (weak link that leads to Bankart lesion)
- superior labrum
 - anchors biceps tendon (weak link that leads to SLAP lesion)

- Anatomic variants

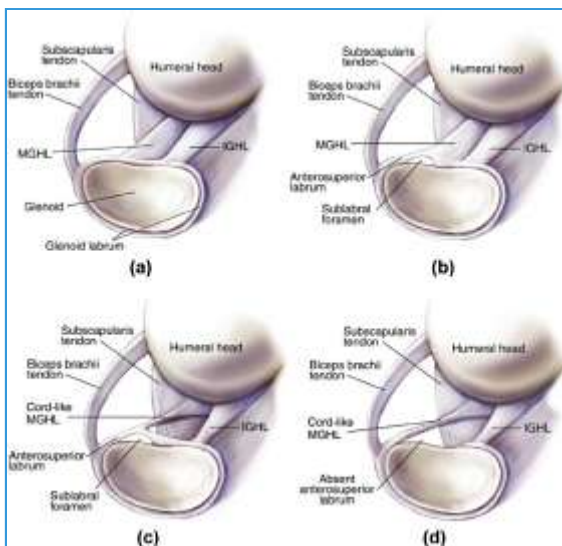
- normal variant



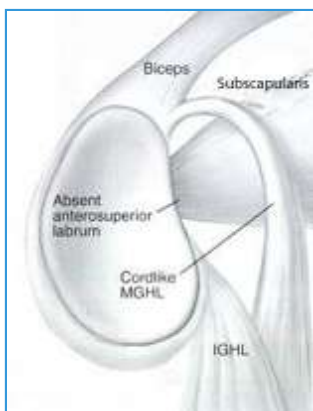
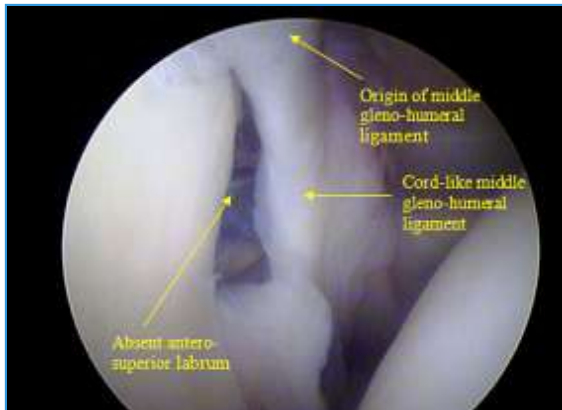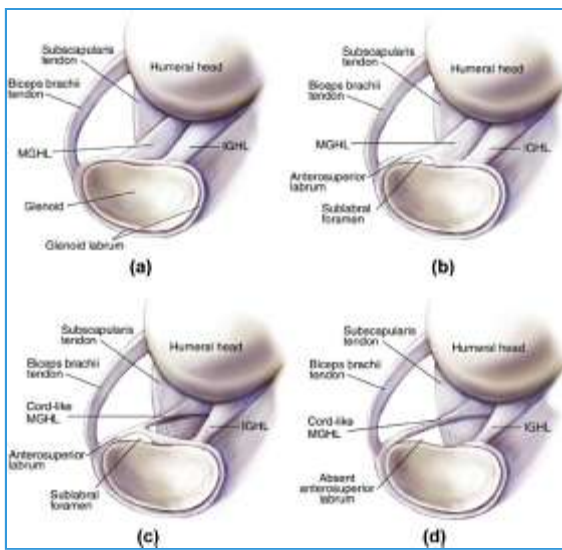
- the labrum attached to the glenoid rim and a flat/broad middle glenohumeral ligament is the most common “normal” variation.
- a cord-like middle glenohumeral ligament is present in 86% of population
- sublabral foramen



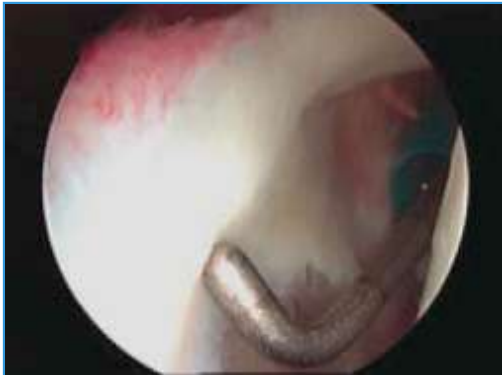- seen in ~12% if population
- sublabral foramen + cordlike MGHL



- Buford complex (absent anteriosuperior labrum + cordlike MGHL)

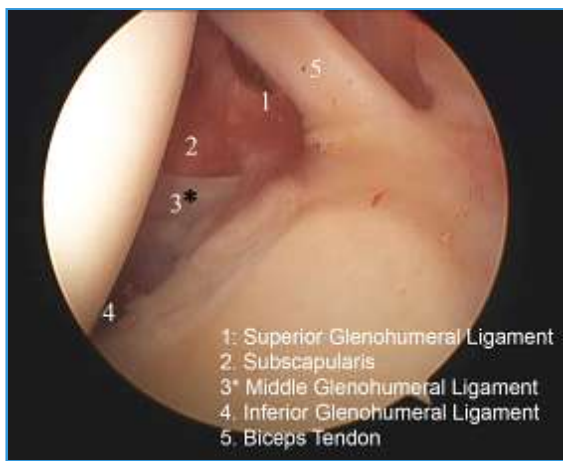

- seen in ~1.5% of population
- cordlike middle glenohumeral ligament with attachment to base of biceps anchor and complete absence of the anterosuperior labrum
- attaching a Buford complex will lead to painful and restricted external rotation and elevation.
- meniscoid appearance (1%)



• Soft Tissue Stabilizers

- Posterior capsule(static)
 - thin (< 1mm) with no ligaments
- Rotator Interval (static)
 - contracture of the rotator interval is seen with adhesive capsulitis (frozen shoulder)
 - laxity of the rotator interval results in a visible sulcus sign with inferior laxity with the shoulder in adduction
 - includes the capsule, SGHL, coracohumeral ligament and long head biceps tendon that bridge the gap between the supraspinatus and the subscapularis.
 - boundaries
 - medially by lateral coracoid base
 - superiorly by anterior edge of supraspinatus
 - inferiorly by superior border of subscapularis
 - lateral apex formed by transverse humeral ligament
- Rotator cuff(dynamic)
 - the primary biomechanical role of the rotator cuff is stabilizing the glenohumeral joint by compressing the humeral head against the glenoid
- Biceps Long Head(dynamic)



- long head of biceps acts as humeral head depressor.
- variable origin from superior labrum
- forms weak links that predisposes to SLAP tear
- SGHL and subscapularis thought to play role in stabilizing long head of biceps

• Osteology

- Humeral head
 - greater and lesser tuberosities are attachment sites for the rotator cuff
 - spheroidal in shape in 90% of individuals
 - average diameter is 43 mm
 - approximate retroversion 20° from transepicondylar axis of the distal humerus
 - articular surface inclined upward 130° from the shaft
- Glenoid
 - pear-shaped surface with average upward tilt of 5°
 - average version is 5° of retroversion in relation to the axis of the scapular body and varies from 7° of retroversion to 10° of anteversion
- Coracoid
 - serves as an anatomic landmark or "lighthouse" for the deltopectoral approach
 - coracobrachialis, pectoralis minor, and short head of the biceps attach to the coracoid
- Acromion
 - 3 ossification centers
 - meta (base), meso (mid), and pre-acromion (tip)
 - acromiohumeral interval is 7-8mm
 - AHI may be normal on Xray but decreased on MRI when pt is supine and weight of arm is removed. This usually signifies multiple tendon tear.
 - acromial morphology
 - I=flat
 - II=curved
 - III=hooked

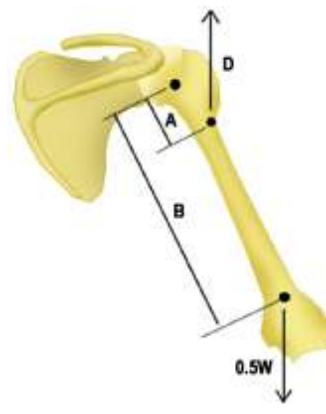
• Blood Supply

- Humeral head
 - ascending branch of anterior humeral circumflex artery and arcuate artery
 - provides blood supply to humeral head
 - vessel runs parallel to lateral aspect of tendon of long head of biceps in the bicipital groove
 - beware not to injure when plating proximal humerus fractures
 - arcuate artery is the interosseous continuation of ascending branch of anterior humeral circumflex artery and penetrates the bone of the humeral head
 - posterior humeral circumflex artery
 - most current literature supports this as providing the main blood supply to humeral head

• Free Body Analysis of Deltoid

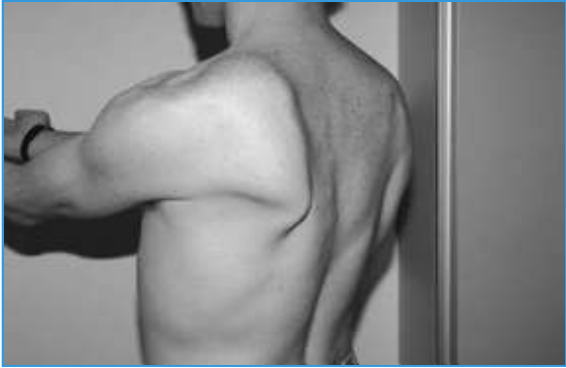- Free body diagram if the arm was at 90 degs of abduction (not pictured)
 - assuming A = 3cm and B = 30 cm
 - sum of moment M = 0
 - $(A \times D) - (B \times 0.5W) = 0$
 - $3D = 0.5W$ (30)
 - $D = 5W$
- Arthrodesis

- optimal position
 - 15-20° of abduction
 - 20-25° of forward flexion
 - 40-50° of internal rotation



2- Shoulder Exam

Images



- Physical exam components

- This topic is broken down into
 - Inspection
 - Palpation
 - Range of Motion
 - Neurovascular
 - Provocative tests

- Inspection

- Important to compare both shoulders
 - skin
 - scars
 - symmetry
 - swelling
 - atrophy
 - hypertrophy
 - scapular winging

- Palpation

- All bony prominences including
 - cervical spinous processes
 - sternoclavicular joint
 - clavicle
 - acromioclavicular joint
 - acromion
 - coracoid process
 - scapular spine
- Muscles and soft tissues including
 - paraspinal muscles
 - periscapular region
 - deltoid
 - rotator cuff tendon insertion / greater tuberosity
 - long head of the biceps tendon in groove

- Range of Motion

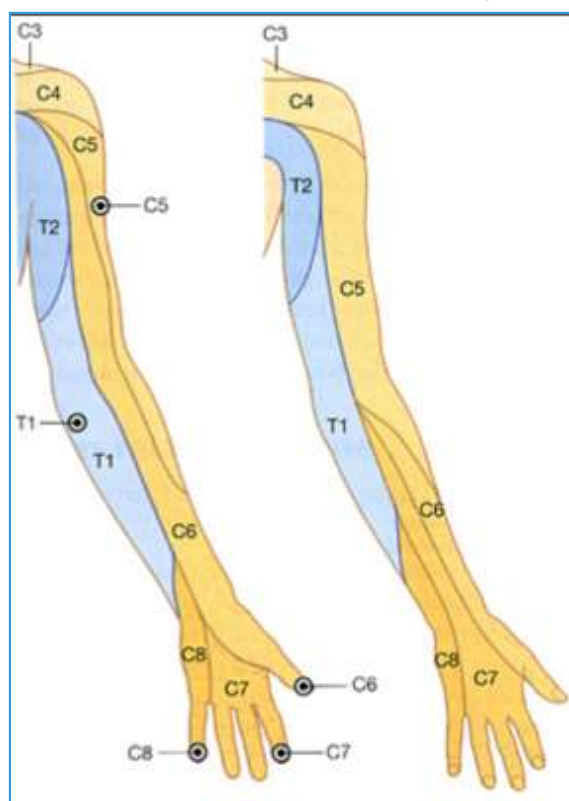
- Cervical spine range of motion
 - flexion
 - extension
 - lateral flexion
 - rotation
- Shoulder range of motion
 - Compare active and passive motion, both sides
 - normal values should be considered relative to contralateral side as patient flexibility may vary

- Six planes of motion should be examined and documented
 - forward elevation
 - 180° considered normal
 - abduction
 - performed with the scapula stabilized by examiner's hand
 - normal is 90 with scapula stabilized
 - external rotation at 90 degrees abduction
 - external rotation at side
 - 80° considered normal
 - internal rotation to vertebral height
 - T4-T8 considered normal
 - internal rotation at 90 degrees abduction

• Neurovascular Exam

○ Sensation

- check all dermatomes along the C4-T1 distribution



○ Motor

Root	Primary Motion	Tested Muscles	Reflex
C4	Scapular Stabilization (winging)	Upper portion of serratus anterior (rarely tested)	
C5	Shoulder abduction Elbow flexion (palm up)	Deltoid Biceps	Biceps
C6	Elbow flexion (thumb up) Wrist extension	Brachioradialis ECRL	Brachioradialis
C7	Elbow extension Wrist flexion	Triceps FCR	Triceps
C8	Finger flexion, hand grip, thumb extension	FDS	
T1	Finger abduction	Interossei (ulnar n.)	

○ Vascular

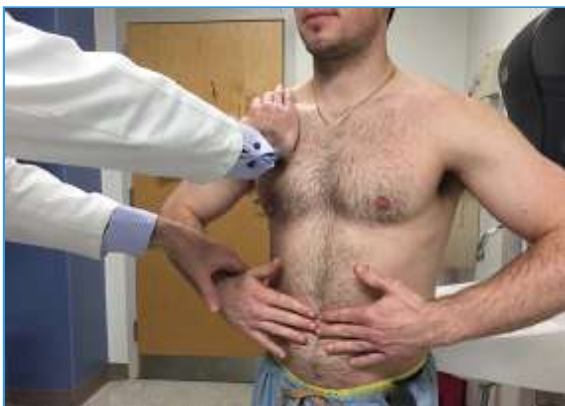- brachial, radial, ulnar artery pulses

• Provocative tests - Impingement

○ Neer Impingement Sign

- indicative of impingement of rotator cuff tendon/bursa against the coracoacromial arch
 - other abnormalities can produce a positive test including
 - stiffness
 - OA
 - instability
 - bone lesions
- technique

- use one hand to prevent motion of the scapula; raise the arm of the patient with the other hand in forced elevation (somewhere between flexion and abduction)
 - pain is elicited (positive test) as the greater tuberosity impinges against the acromion (between 70-110°)
 - note you must have full range of motion for "positive" finding.
 - sensitivity 75-86%, specificity 50%
 - Neer Impingement Test
 - positive when there is a marked reduction in pain from above impingement maneuver following subacromial lidocaine injection
 - technique
 - usually a combination of
 - 4cc 1% Lidocaine
 - 4cc 0.50% Bupivacaine (Marcaine)
 - 2cc corticosteroid
 - Hawkins Test
 - technique
 - performed by flexing shoulder to 90°, flex elbow to 90°, and forcibly internally rotate driving the greater tuberosity farther under the CA ligament.
 - sensitivity 75-92%, specificity 45%
 - Internal Impingement
 - technique
 - abduct affected side to 90° and maximally externally rotate (throwing position-late cocking phase) with extension
 - if this maneuver reproduces pain experienced during throwing (posteriorly located) considered it is considered positive.
 - further confirmed with relief upon performing relocation test
 - ER with elbow in front of plane of body and pain disappears.
- Provocative tests - Rotator Cuff Pathology
- Subscapularis Tests
 - Subscapularis Strength
 - do not test with isolated IR strength with the arm at the side due to contribution of pectoralis major and latissimus dorsi
 - Internal Rotation Lag Sign
 - most sensitive and specific test for subscapularis pathology.
 - technique
 - stand behind patient, flex elbow to 90°, hold shoulder at 20° elevation and 20° extension. Internally rotate shoulder to near maximum holding the wrist by passively lifting the dorsum of the hand away from the lumbar spine - then supporting the elbow, tell patient to maintain position and release the wrist while looking for a lag.
 - Increased Passive ER
 - a person with a subscapularis tear may have increased Passive ER rotation when compared to contralateral side
 - Lift Off Test
 - technique
 - hand brought around back to region of lumbar spine, palm facing outward; test patient's ability to lift hand away from back (internal rotation). Inability to do this indicates subscapularis pathology. Is confounded by other muscles.
 - more accurate if the tested hand can reach the contralateral scapula.
 - more accurate for inferior portion of subscapularis .
 - Belly Press



- technique
 - patient presses abdomen with palm of hand, maintaining shoulder in internal rotation. If elbow drops back (does not remain in front of trunk), the test is positive for subscapularis weakness
 - more accurate for superior portion of subscapularis
 - Bear Hug
 - patient places ipsilateral palm on the opposite deltoid and tries to resist the examiner pulling it away anteriorly
 - positive if at least 20% weaker than contralateral side
 - Supraspinatus Tests
 - Supraspinatus Strength
 - strength is assessed using Jobe's Test (see below) - pain with this test is indicative of a subacromial bursitis/irritation - not necessarily a tear. Only considered positive for tear with a true drop arm. i.e. arm is brought to 90° and literally falls down.
 - Jobe's Test
 - tests for supraspinatus weakness and/or impingement
 - technique
 - abduct arm to 90°, angle forward 30° (bringing it into the scapular plane), and internally rotate (thumb pointing to floor). Then press down on arm while patient attempts to maintain position testing for weakness or pain.
 - Drop Sign
 - tests for function/integrity of supraspinatus
 - technique
 - passively elevate arm in scapular plan to 90°. Then ask the patient to slowly lower the arm. The test is positive when weakness or pain causes them to drop the arm to their side.
 - most specific test for full thickness rotator cuff tear (specificity 98%)
 - Infraspinatus
 - Infraspinatus Strength
 - technique
 - with the patient's elbow in 90 degrees flexion, the arm at the side and internally rotated 45 degrees, external rotation strength can be checked against resistance by the examiner
 - External Rotation Lag Sign
 - technique
 - passively flex the elbow to 90 degrees, holding wrist to rotate the shoulder to maximal external rotation. Tell the patient to hold the arm in that externally rotated position. If the arm starts to drift into internal rotation, it is positive.
 - Teres Minor
 - Teres Minor Strength
 - external rotation tested with the arm held in 90 degrees of abduction
 - Hornblower's sign
 - technique
 - bring the shoulder to 90 degrees of abduction, 90 degrees of external rotation and ask the patient to hold this position. Positive if the arm falls into internal rotation
- Provocative tests - Labral Injuries and SLAP lesions
 - Active Compression test ("O'Brien's Test")
 - positive for SLAP tear when there is pain is "deep" in the glenohumeral joint while the forearm is pronated but not when the forearm is supinated. technique
 - patient forward flexes the affected arm to 90 degrees while keeping the elbow fully extended. The arm is then adducted 10-15 degrees across the body. The patient then pronates the forearm so the thumb is pointing down. The examiner applies downward force to the wrist while the arm is in this position while the patient resists. The patient then supinates the forearm so the palm is up and the examiner once again applies force to the wrist while the patient resists.
 - Crank Test
 - positive when there is clicking or pain in the glenohumeral joint
 - technique
 - hold the patient's arm in an abducted position and apply passive rotation and axial rotation.
- Provocative tests - Biceps Injuries
 - Bicipital Groove Tenderness

- may be present with any condition that could lead to an inflamed long head biceps tendon and a SLAP lesion
- Speed's Test
 - positive when there is pain elicited in the bicipital groove
 - technique
 - patient attempts to forward elevate their shoulder against resistance while they keep their elbow extended and forearm supinated.
- Yergason's Sign
 - positive when there is pain in the bicipital groove
 - technique
 - elbow flexed to 90 degrees with the forearm pronated. The examiner holds the hand/wrist to maintain pronated position while the patient attempts to actively supinate against this resistance. If there is pain located along the bicipital groove the test is positive for biceps tendon pathology.
- Popeye Sign
 - present when there is a large bump in the area of the biceps muscle belly. Consistent with long head of biceps proximal tendon rupture.

- Provocative tests - AC Joint pathology

- Acromioclavicular joint tenderness
 - tenderness with palpation of the acromioclavicular joint
- Cross-Body Adduction
 - positive when there is pain in the AC joint
 - technique
 - patient forward elevates the arm to 90 degrees and actively adducts the arm across the body.
- O'Brien's Test (Active Compression test)
 - positive when there is pain "superficial" over the AC joint while the forearm is pronated but not when the forearm is supinated
 - technique
 - patient forward flexes the affected arm to 90 degrees while keeping the elbow fully extended. The arm is then adducted 10-15 degrees across the body. The patient then pronates the forearm so the thumb is pointing down. The examiner applies downward force to the wrist while the arm is in this position while the patient resists. The patient then supinates the forearm so the palm is up and the examiner once again applies force to the wrist while the patient resists.

- Provocative tests - Instability

○	▪ Grading of Translation of Humeral Head
▪ 1+	▪ Translation to glenoid rim
▪ 2+	▪ Translation over glenoid rim but reduces
▪ 3+	▪ Translates and locks out of glenoid

- Anterior Instability
 - Anterior Load and Shift
 - positive when there is increased translation compared to the contralateral side
 - technique
 - have the patient lie supine with the shoulder at 40-60 degrees of abduction and forward flexion. Axially load the humerus into the glenoid fossa and apply anterior translation forces. Compare to the contralateral side.
 - Apprehension and Relocation
 - positive test if the patient experiences the sensation of instability
 - technique
 - have the patient lie supine. Apprehension test performed by bringing the arm in 90 degrees of abduction and full external rotation and patient experiences sense of instability. Relocation test performed by placing examiner's hand on humeral head applying a posterior force on the humeral head. Patient will experience reduction or elimination of sense of instability.
 - Anterior Release
 - positive test if the patient experiences instability when examiner's hand is released
 - technique
 - have the patient lie supine. Examiner places hand on humeral head to keep reduced as arm is brought into abduction/external rotation. Examiner's hand is removed and the humeral head subluxes causing sense of

instability. NOTE: positive anterior release is really a "3 in 1" test - if it is positive, apprehension and relocation are also positive.

- Anterior Drawer
 - positive if there is sense of instability when compared to the contralateral side
 - technique
 - stabilize the scapula and apply an anteriorly directed force against the humeral head with the contralateral hand. NOTE: graded 1+, 2+, and 3+ but this only documents amount of laxity, not pathologic unless causes symptoms.

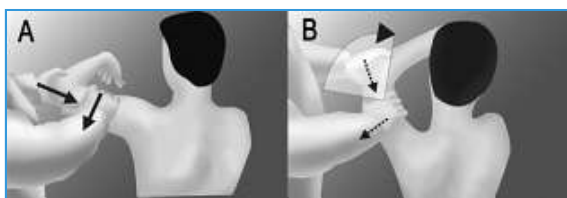
○ Posterior Instability

- Posterior Load and Shift
 - positive if there is increased translation compared to contralateral side
 - technique
 - lie the patient supine with the shoulder in 40-60 degrees of abduction and forward elevation. Load the humerus into the glenoid fossa with an axial load and apply posterior forces to the humeral head. Compare the amount of translation with the contralateral side.

■ Jerk Test

- positive if there is a 'clunk' or pain with the maneuver
- technique
 - have the patient sit straight up with the arm forward elevated to 90 degrees and internally rotated to 90 degrees. Apply an axial load to the humerus to push it posteriorly.

■ Kim test



- test is positive when pain is present
- technique
 - performed by having the patient seated, arm at 90° abduction, followed by flexing the shoulder to 45 forward flexion while simultaneously applying axial load on the elbow & posterior-inferior force on the upper humerus.

■ Posterior Drawer

- positive if there is increased translation when compared to the contralateral side
- technique
 - stabilize the scapula and apply a posteriorly directed force against the humeral head with the contralateral hand.

■ Posterior Stress Test

- positive if there is pain and sense of instability with the maneuver
- technique
 - Place the patient's arm in flexion, adduction, and internal rotation and apply a posteriorly directed force.

■ Loss of External Rotation

- a shoulder that is locked in internal rotation may be subluxed posteriorly.

○ Multidirectional Instability (MDI)

■ Sulcus Sign

- have the patient stand relaxed with their arms at their side. Grab their affected arm and pull it inferiorly. If there is a sulcus that forms at the superior aspect of the humeral head, the test is positive. Sulcus is considered positive if it stays increased (2+ or 3+) with ER at side (pathologic rotator interval).

■ Sulcus grading	
■ 1+	■ Acromiohumeral interval < 1cm
■ 2+	■ Acromiohumeral interval 1-2 cm
■ 3+	■ Acromiohumeral interval > 2cm

● Provocative tests - Other

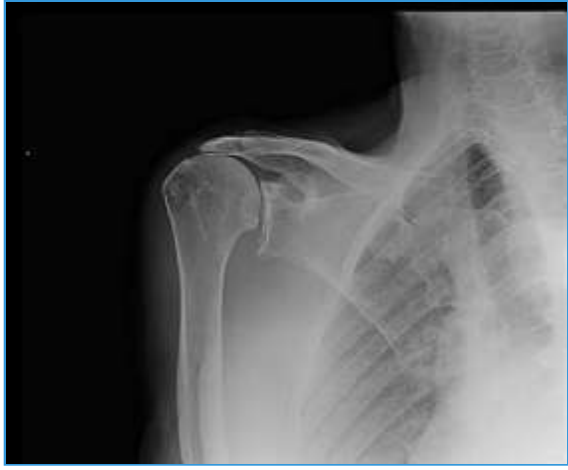○ Wright's Test

- test for thoracic outlet syndrome .
- positive if the patient losses their radial pulse
- technique
 - passively externally rotate and abduct the patient's arm while having the patient turn their neck away from the tested extremity.

- Medial Scapular Winging
 - test for serratus anterior weakness or long thoracic nerve dysfunction.
 - positive if the inferior border of the scapula migrates medially
 - technique
 - while standing, have the patient forward flex their arm to 90 degrees and push against a wall (or other stationary object).
- Lateral Scapular Winging
 - test for trapezius weakness or spinal accessory nerve (CNXI) dysfunction
 - positive if the inferior boarder of the scapula migrates laterally
 - technique
 - while standing, have the patient forward flex to 90 degrees and push against a wall (or other stationary object).
- Pectoralis
 - Axillary Webbing
 - look for a defect in the normal axillary fold. A deformity may be indicative of an pectoralis major muscle rupture

3- Rotator Cuff Arthropathy

Images



• summary

- Rotator cuff arthropathy is a specific pattern of shoulder degenerative joint disease that results from a rotator cuff tear leading to abnormal glenohumeral wear and subsequent superior migration of the humeral head.
- Diagnosis can be made primarily with shoulder radiographs showing glenohumeral arthritis with a decreased acromiohumeral interval.
- Treatment for minimally symptomatic patients involves activity modification, subacromial steroid injections, and physical therapy. Shoulder arthroplasty (most commonly reverse total shoulder arthroplasty) is indicated for patients with progressive pain and deterioration of shoulder function.

• Epidemiology

- Demographics
 - females > males
 - 7th decade most common
- Anatomic location
 - more common in dominant shoulder
- Risk factors
 - rotator cuff tear
 - rheumatoid arthritis
 - crystalline-induced arthropathy
 - hemorrhagic shoulder (hemophiliacs and elderly on anticoagulants)

• Etiology

- Pathophysiology
 - cuff tear arthropathy
 - mechanical factors
 - loss of the concavity due to compression effect
 - decreased range of motion and shoulder function
 - humeral head migration
 - instability with possible recurrent dislocations
 - nutritional factors
 - loss of water tight joint space
 - decreased joint fluid
 - cartilage atrophy (decrease in water and glycosaminoglycan content) and subchondral collapse (disuse osteoporosis)
 - crystalline-induced arthropathy
 - degradation proteins in the synovium destroy the rotator cuff and cartilage
 - end-stage disease leads to calcium phosphate crystal deposits
 - Rotator cuff arthropathy is characterized by the combination of
 - rotator cuff insufficiency
 - glenohumeral cartilage destruction
 - superior migration of the humeral head





- subchondral osteoporosis
- humeral head collapse






- Anatomy

- Glenohumeral joint

- Classification

- ■ Seebauer Classification of Rotator Cuff Arthropathy

<ul style="list-style-type: none"> ■ Type IA 	<ul style="list-style-type: none"> ■ Centered, stable ■ Intact anterior restraints ■ Minimal superior migration ■ Dynamic joint stabilization ■ Femoralization of the humeral head and acetabularization of coracoacromial arch 	<ul style="list-style-type: none"> ■ 
<ul style="list-style-type: none"> ■ Type IB 	<ul style="list-style-type: none"> ■ Centered, medialized ■ Intact or compensated anterior restraints ■ Minimal superior migration ■ Compromised joint stabilization ■ Medial erosion of the glenoid 	<ul style="list-style-type: none"> ■ 
<ul style="list-style-type: none"> ■ Type IIA 	<ul style="list-style-type: none"> ■ Decentered, limited stability ■ Compromised anterior restraints ■ Superior translation ■ Minimum stabilization by coracoacromial arch 	<ul style="list-style-type: none"> ■ 
<ul style="list-style-type: none"> ■ Type IIB 	<ul style="list-style-type: none"> ■ Decentered, unstable ■ Incompetent anterior restraints ■ Anterosuperior escape ■ Nonexistent dynamic stabilization ■ No coracoacromial arch stabilization 	<ul style="list-style-type: none"> ■ 

Hamada Classification of Rotator Cuff Arthropathy		
Grade 1	Acromiohumeral interval ≥ 6 mm	
Grade 2	Acromiohumeral intervals ≤ 5 mm	
Grade 3	Acromiohumeral interval ≤ 5 mm, with acetabularization of acromion	
Grade 4	<ul style="list-style-type: none"> 4A: Glenohumeral arthritis without acetabularization, AHI < 7mm 4B: Glenohumeral arthritis with acetabularization, AHI ≤ 5mm 	
Grade 5	Humeral head collapse	

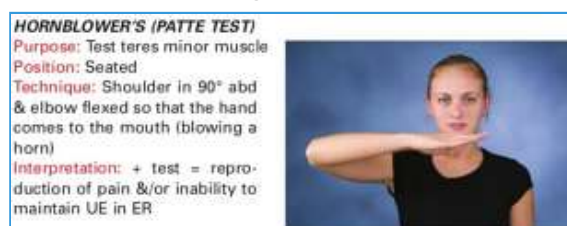• Presentation

○ Symptoms

- pain, including night-pain
- subjective weakness
- subjective stiffness

○ Physical exam

- inspection & palpation
 - supraspinatus/infraspinatus atrophy
 - prominence of humeral head anteriorly (anterosuperior escape) with elevation of arm
 - subcutaneous effusion from loss of fluid from capsule
- range of motion
 - limitations in active and passive ROM
 - crepitus in glenohumeral and/or subacromial joints with ROM
 - pseudoparalysis
 - inability to abduct shoulder
- provocative tests
 - external rotation lag sign
 - inability to maintain passively externally rotated shoulder with elbow at 90 degrees
 - consistent with a massive infraspinatus tear
 - Hornblower sign



- inability to externally rotate or maintain passive external rotation of a shoulder placed in 90 degrees of elbow flexion and 90 degrees of shoulder abduction
- consistent with teres minor dysfunction

• Imaging

○ Radiographs

- recommended views
 - complete shoulder series; AP, axillary, Grashey (true AP)

- findings
 - acromial acetabularization (true AP)
 - femoralization of humeral head (true AP)
 - asymmetric superior glenoid wear
 - lack of osteophytes
 - osteopenia
 - "snowcap sign" due to subchondral sclerosis
 - anterosuperior escape
- MRI
 - indications
 - not necessary if humeral head is already showing anterosuperior escape on x-rays
 - findings
 - shows an irreparable rotator cuff tear with
 - massive fatty infiltration
 - severe retraction
- Treatment
 - Nonoperative
 - **activity modification, subacromial steroid injection, physical therapy**
 - indications
 - first line of treatment
 - technique
 - physical therapy with a scapular and rotator cuff strengthening program
 - non-steroidal anti-inflammatories
 - subacromial steroid injections
 - Operative
 - **arthroscopic debridement**
 - indications
 - controversial
 - outcomes
 - unpredictable results
 - must maintain coracoacromial arch without acromioplasty or release of CA ligament
 - **hemiarthroplasty**
 - indications
 - anterior deltoid is preserved
 - coracoacromial arch intact
 - deficiency of the coracoacromial arch will lead to subcutaneous humeral escape
 - younger patients with active lifestyles
 - outcomes
 - will relieve pain but will not improve function (motion limited to 40-70 degrees of elevation)
 - **reverse shoulder arthroplasty**
 - indications
 - pseudoparalytic cuff tear arthropathy
 - preferred in elderly (>70) with low activity level
 - anterosuperior escape
 - requires functioning deltoid (axillary nerve) and good bone stock
 - deltoid is used to assist glenohumeral joint to act like a fulcrum in elevation
 - outcomes (short and intermediate at this point)
 - has the potential to improve both function and pain
 - risk of inferior scapular notching with poor technique
 - **latissimus dorsi transfer**
 - indications
 - external rotation pseudoparalysis
 - combination with reverse total shoulder arthroplasty
 - **pectoralis transfer**
 - indications
 - internal rotation deficiency and subscapularis insufficiency
 - techniques

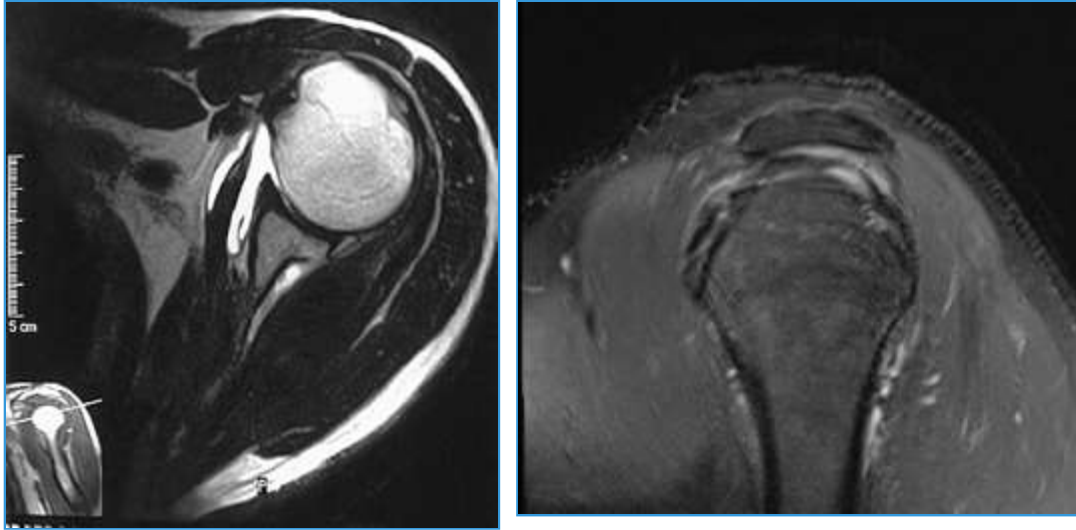
- upper portion or whole pectoralis tendon transferred near subscapularis insertion on lesser tuberosity
- complications
 - musculocutaneous nerve injury
- **resection arthroplasty**
 - indications
 - salvage only (chronic osteomyelitis, infections, poor soft tissue coverage)
- **glenoid resurfacing**
 - contraindicated
 - excess shear stress on superior glenoid leads to failure through loosening
- **TSA**
 - contraindicated

- **Complications**

- Infection
- Neurovascular injury
- Deltoid dysfunction
- Instability (more common after hemiarthroplasty, rare after RTSA)

4- Rotator Cuff Tears

Images



• summary

- Rotator cuff tears are a very common source of shoulder pain and decreased motion that can occur due to both traumatic injuries in young patients as well as degenerative disease in the elderly patient.
- Diagnosis can be suspected clinically with provocative tests of the supraspinatus, infraspinatus, teres minor and subscapularis, but confirmation requires an MRI of the shoulder.
- Treatment can be nonoperative or operative depending on the chronicity of symptoms, severity of the tear, degree of muscle fatty atrophy, patient age and patient activity demands.

• Epidemiology

- Prevalence
 - age >60: 28% have full-thickness tear
 - age >70: 65% have full-thickness tear
- Risk factors
 - age
 - smoking
 - hypercholesterolemia
 - family history

• Etiology

- Pathophysiology
 - mechanisms of tear includes
 - chronic degenerative tear (intrinsic degeneration is the primary etiology)
 - usually seen in older patients
 - usually involves the SIT (supraspinatus, infraspinatus, teres minor) muscles but may extend anteriorly to involve the superior margin of subscapularis tendon in larger tears
 - chronic impingement
 - typically starts on the bursal surface or within the tendon
 - acute avulsion injuries
 - acute subscapularis tears seen in younger patients following a fall
 - acute SIT (supraspinatus, infraspinatus, teres minor) tears seen in patients > 40 yrs with a shoulder dislocation
 - full thickness rotator cuff tears need to be repaired in throwing athletes
 - iatrogenic injuries
 - due to failure of surgical repair
 - often seen in repair failure of the subscapularis tendon following open anterior shoulder surgery.
- Impingement and rotator cuff disease are a continuum of disease including
 - subacromial impingement
 - subcoracoid impingement
 - calcific tendonitis
 - rotator cuff tears (this topic)

- rotator cuff arthropathy



- Associated conditions

- AC joint pathology
- proximal biceps subluxation
- proximal biceps tendonitis
- internal impingement
 - seen in overhead throwing athletes
 - associated with partial thickness rotator cuff tears
 - deceleration phase of throwing leads to tensile forces and potential for rotator cuff tears

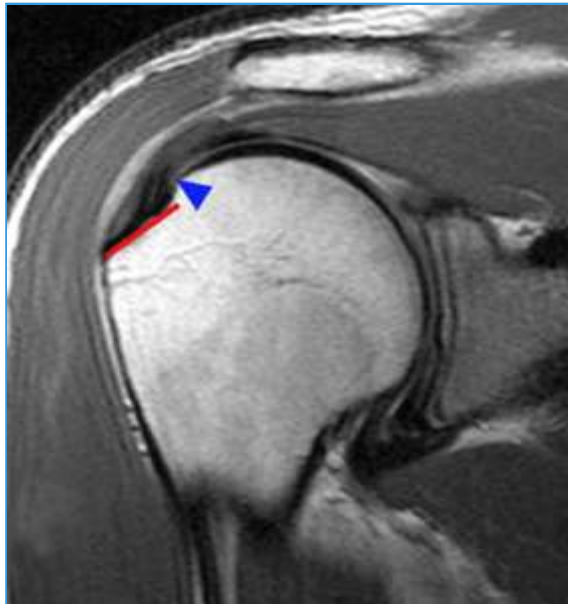
- Anatomy

- Rotator cuff function


- the primary function of the rotator cuff is to provide dynamic stability by balancing the force couples about the glenohumeral joint in both the coronal and transverse plane.
 - coronal plane
 - the inferior rotator cuff (infraspinatus, teres minor, subscapularis) functions to balance the superior moment created by the deltoid
 - transverse plane
 - the anterior cuff (subscapularis) functions to balance the posterior moment created by the posterior cuff (infraspinatus and teres minor)
 - this maintains a stable fulcrum for glenohumeral motion.
 - the goal of treatment in rotator cuff tears is to restore this equilibrium in all planes.

- Rotator cuff footprint

- supraspinatus inserts on anterosuperior aspect of greater tuberosity
- medial-lateral width at insertion
 - supraspinatus is 12.7mm (covers superior facet of greater tuberosity)

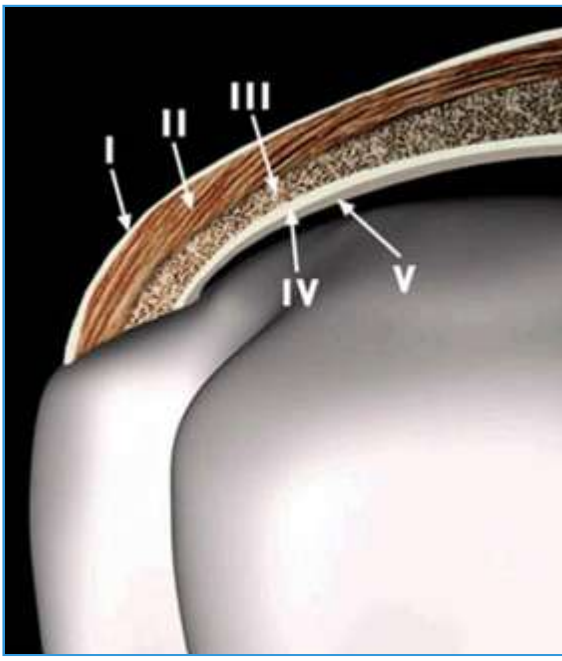


- 6-7 mm tear corresponds to 50% partial thickness tear
- infraspinatus is 13.4mm
- subscapularis is 17.9mm
- teres minor is 13.9mm
- distance between articular cartilage to medial footprint of rotator cuff is 1.6-1.9 mm
- AP dimension of footprint is 20mm

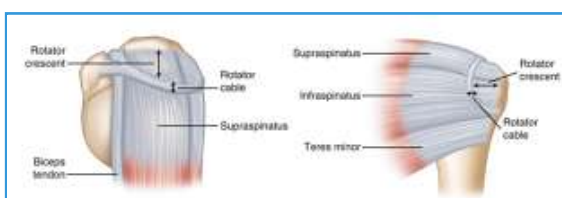


- corresponds to insertion of supraspinatus and anterior infraspinatus

- Rotator cuff histologic areas (5 layers)

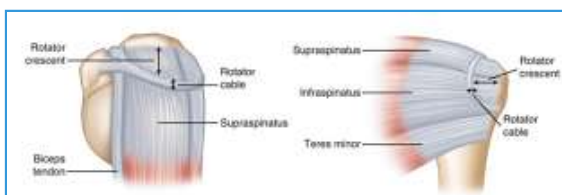


- important because articular side has only half the strength of bursal side
 - explains why most tears are articular sided
- Layer I
 - most superficial layer (1 mm thick) and composed of fibers from the coracohumeral ligament which extend posteriorly and obliquely
- Layer II
 - composed of densely packed fibers that parallel the long axis of the tendon (3-5 mm thickness)
- Layer III
 - smaller loosely organized bundles of collagen at 45° angle to the long axis of the tendon (3 mm thick)
- Layer IV
 - loose connective tissue and thick collagen bands and merges with fibers from coracohumeral ligament
- Layer V
 - shoulder capsule (2 mm thick)
- Rotator cuff blood supply
 - from subscapular, suprascapular and humeral circumflex arteries
 - branching within layer II and layer III (see above for layers)
 - bursal side is more vascular than the articular side (which is hypovascular)
 - zone of critical hypovascularity adjacent to most lateral portion of supraspinatus insertion
- Anatomic features associated with rotator cuff
 - rotator interval
 - includes the capsule, long head of the biceps tendon, SGHL, and the coracohumeral ligament that bridge the gap between the supraspinatus and the subscapularis.



- thin, crescent-shaped sheet of rotator cuff comprising the distal portions of the supraspinatus and infraspinatus insertions.

- rotator cable



- thick bundle of fibers found at the avascular zone of the coracohumeral ligament running perpendicular to the supraspinatus fibers and spanning the insertions of the supra- and infraspinatus tendons.

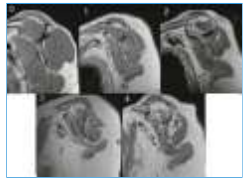
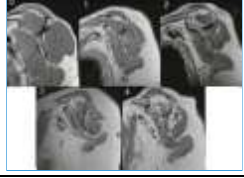


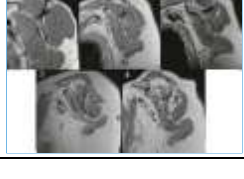
- Complete glenohumeral anatomy

- Classification

<ul style="list-style-type: none"> Anatomic Classification 		
<ul style="list-style-type: none"> Supraspinatus, infraspinatus, teres minor (SIT) tears 	<ul style="list-style-type: none"> Make up the majority of tears Associated with subacromial impingement Mechanism is often a degenerative tear in older patients or a shoulder dislocation in patients > 40 yrs. 	■
<ul style="list-style-type: none"> Subscapularis tears 	<ul style="list-style-type: none"> New evidence suggests higher prevalence than previously thought Associated with subcoracoid impingement Mechanism is often an acute avulsion in younger patients with a hyperabduction/external rotation injury or an iatrogenic injury due to failure of repair 	■

<ul style="list-style-type: none"> Cuff Tear Size 		
<ul style="list-style-type: none"> Small 	<ul style="list-style-type: none"> 0-1 cm 	■
<ul style="list-style-type: none"> Medium 	<ul style="list-style-type: none"> 1-3 cm 	■
<ul style="list-style-type: none"> Large 	<ul style="list-style-type: none"> 3-5 cm 	■
<ul style="list-style-type: none"> Massive 	<ul style="list-style-type: none"> > 5 cm (involves 2 or more tendons) 	■

<ul style="list-style-type: none"> Ellman Classification of Partial-Thickness Rotator Cuff Tears 		
<ul style="list-style-type: none"> Grade 	<ul style="list-style-type: none"> Description 	
<ul style="list-style-type: none"> I 	<ul style="list-style-type: none"> < 3mm (< 25% thickness) 	■
<ul style="list-style-type: none"> II 	<ul style="list-style-type: none"> 3-6 mm (25-50%) 	■
<ul style="list-style-type: none"> III 	<ul style="list-style-type: none"> > 6 mm (>50%) 	■
<ul style="list-style-type: none"> Location 		
<ul style="list-style-type: none"> A 	<ul style="list-style-type: none"> Articular sided 	■
<ul style="list-style-type: none"> B 	<ul style="list-style-type: none"> Bursal sided 	■
<ul style="list-style-type: none"> C 	<ul style="list-style-type: none"> Intratendinous 	■

<ul style="list-style-type: none"> Goutallier Classification of Rotator Cuff Atrophy 		
<ul style="list-style-type: none"> 0 	<ul style="list-style-type: none"> Normal 	<ul style="list-style-type: none"> 
<ul style="list-style-type: none"> 1 	<ul style="list-style-type: none"> Some fatty streaks 	<ul style="list-style-type: none"> 
<ul style="list-style-type: none"> 2 	<ul style="list-style-type: none"> More muscle than fat 	<ul style="list-style-type: none"> 
<ul style="list-style-type: none"> 3 	<ul style="list-style-type: none"> Equal amounts fat and muscle 	<ul style="list-style-type: none"> 
<ul style="list-style-type: none"> 4 	<ul style="list-style-type: none"> More fat than muscle 	<ul style="list-style-type: none"> 

Cuff Tear Shape		
<ul style="list-style-type: none"> Crescent 	<ul style="list-style-type: none"> Usually do not retract medially, are quite mobile in the medial to lateral direction, and can be repaired directly to bone with minimal tension. 	<p>Figure 7. Crescent-shaped rotator cuff tear. A, superior view of a crescent-shaped rotator cuff tear involving the supraspinatus (SS) and infraspinatus (IS) tendons. B, medial view of the same tear.</p>
<ul style="list-style-type: none"> U-shape 	<ul style="list-style-type: none"> Similar shape to crescent but extend further medially with apex adjacent or medial to the rim of the glenoid. Must be repaired side-to-side using margin convergence first to avoid overwhelming tensile stress in the middle of the rotator cuff repair margin. 	<p>Figure 8. U-shaped rotator cuff tear. A, superior view of a U-shaped rotator cuff tear involving the supraspinatus (SS) and infraspinatus (IS) tendons. B, medial view of the same tear. C, lateral view of the same tear.</p>
<ul style="list-style-type: none"> L-shape 	<ul style="list-style-type: none"> Similar to U shape except one of the leaves is more mobile than the other. Use margin convergence in repair. 	<p>Figure 9. L-shaped rotator cuff tear. A, superior view of an L-shaped rotator cuff tear involving the supraspinatus (SS) and infraspinatus (IS) tendons. B, medial view of the same tear. C, lateral view of the same tear.</p>
<ul style="list-style-type: none"> Massive & immobile 	<ul style="list-style-type: none"> May be u-shaped or longitudinal. Difficult to repair and often requires an interval slide. 	<p>Figure 11. Massive, contracted longitudinal rotator cuff tear. A, superior view of a massive, contracted longitudinal rotator cuff tear involving the supraspinatus (SS) and infraspinatus (IS) tendons. B, anterior interval slide is performed by incising the interval between the supraspinatus tendon (SS) and rotator interval (RI). C, the improved mobility from the release allows repair of the supraspinatus tendon to a lateral bone bed. D, the posterior leaf of the tear consisting of the infraspinatus (IS) and lesser minor tendons is then advanced superiorly and laterally and the residual longitudinal defect is closed by side-to-side sutures. Sub, subscapularis tendon; CHL, coracohumeral ligament.</p>

Presentation

Symptoms

- pain
 - typically insidious onset of pain exacerbated by overhead activities
 - pain located in deltoid region
 - night pain, which is a poor indicator for nonoperative management
 - can have acute pain and weakness with an traumatic tear
 - weakness
 - loss of active ROM with greater or intact passive ROM

Overview of Physical Exam of Rotator Cuff		
Cuff Muscle	Strength Testing	Special Tests
Supraspinatus	Weakness to resisted elevation in Jobe position	<ul style="list-style-type: none"> Drop arm test Pain with Jobe test
Infraspinatus	ER weakness at 0° abduction	ER lag sign
Teres minor	ER weakness at 90° abduction and 90° ER	Hornblowers
Subscapularis	IR weakness at 0° abduction	<ul style="list-style-type: none"> Excessive passive ER Belly Press Lift off IR lag sign

Imaging

Radiographs

- views
 - true AP, AP in internal/external rotation, axillary
 - outlet view to assess acromion
 - findings
 - calcific tendonitis
 - calcification in the coracohumeral ligament
 - cystic changes in greater tuberosity
 - proximal migration of humerus seen with chronic RCT (acromiohumeral interval <7 mm)
 - Type III (hooked) acromion

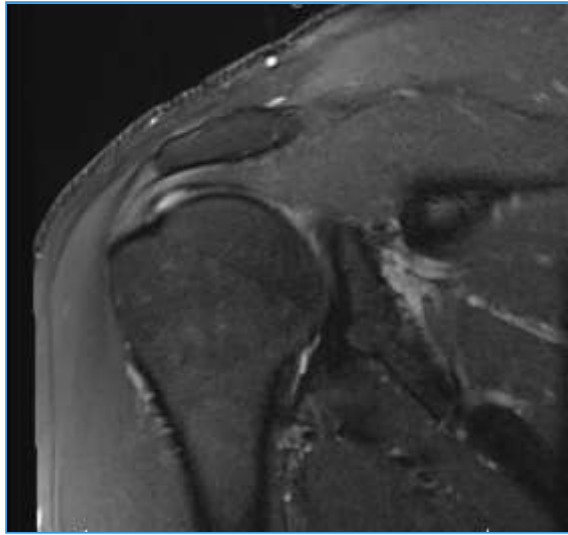
Arthrogram

- indications

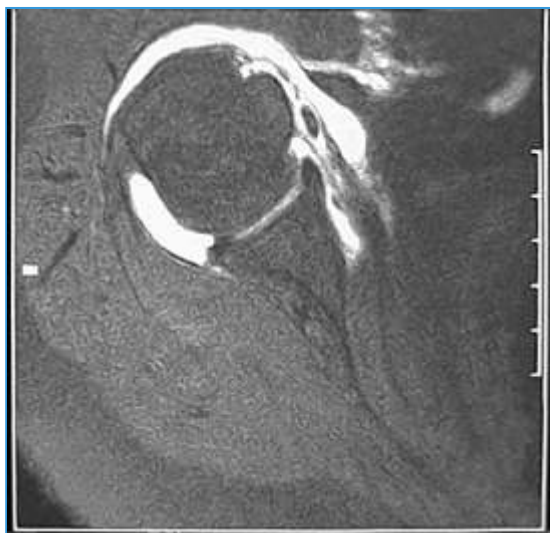- not commonly used in isolation; used when MRI contraindicated
- findings
 - rotator cuff tear present if dye leaks from glenohumeral joint into subacromial joint
 - MR arthrogram may improve sensitivity and specificity

○ MRI

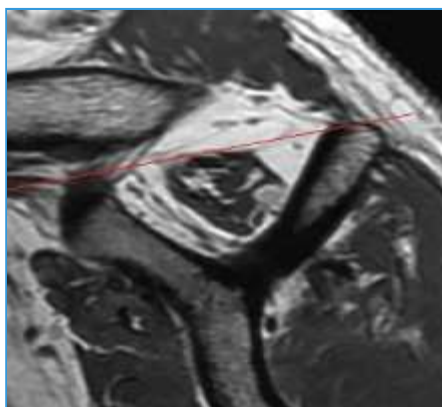
- indications
 - diagnostic standard for rotator cuff pathology



- obtain when suspicion for pain or weakness attributable to a rotator cuff tear
- findings
 - important to evaluate muscle quality
 - size, shape, and degree of retraction of tear
 - degree of muscle fatty atrophy (best seen on sagittal image)
 - medial biceps tendon subluxation



- indicative of a subscapularis tear
- cyst in humeral head on MRI seen in almost all patients with chronic RCT
- tangent sign



- failure of the supraspinatus to cross a line drawn between the superior borders of the scapular spine and coracoid process on a sagittal MRI slice
- sensitivity and specificity
 - in asymptomatic patients 60 yrs and older, 55% will have a RCT

○ Ultrasound

- indications
 - suspicion of rotator cuff pathology
 - need for dynamic examination
- advantages include
 - allows for dynamic testing
 - inexpensive
 - readily available at most centers
 - helpful to confirm intraarticular injections

- disadvantages include
 - highly user dependent
 - limited ability to evaluate other intraarticular pathology
- sensitivity/specificity
 - similar sensitivity, specificity, and overall accuracy for diagnosis of rotator cuff disease as compared to MRI
 - 23% of asymptomatic patients had a rotator cuff tear on ultrasound in one series

- Treatment

- Treatment considerations
 - activity and age of patient
 - mechanism of tear (degenerative or traumatic avulsion)
 - characteristics of tear (size, depth, retraction, muscle atrophy)
 - partial thickness tears vs. complete tear
 - articular sided (PASTA lesion) vs. bursal sided
 - bursal sided tears treated more aggressively
- Nonoperative
 - **physical therapy, NSAIDS, subacromial corticosteroid injections**
 - first line of treatment for most tears
 - partial tears often can be managed with therapy
 - technique
 - avoidance of overhead activities
 - physical therapy with aggressive rotator cuff and scapular-stabilizer strengthening over a 3-6 month treatment course
 - subacromial injections if impingement thought to be major cause of symptoms
- Operative
 - **subacromial decompression and rotator cuff debridement alone**
 - indications
 - select patients with a low-grade partial articular sided rotator cuff tear
 - **rotator cuff repair (arthroscopic or mini-open)**
 - indications
 - acute full-thickness tears
 - bursal-sided tears >3 mm (>25%) in depth
 - release remaining tendon and debride degenerative tissue
 - partial articular-side tears >50% can be treated with tear completion and repair
 - Partial articular-side tears <50% treated with debridement alone
 - PASTA with >7mm of exposed bony footprint between the articular surface and intact tendon represents significant (>50%) cuff tear (must have at least 25% healthy bursal sided tissue)
 - younger patients with acute, traumatic tears
 - in situ repair leave bursal sided tissue intact
 - older patients with degenerative tears
 - tendon release, debridement of degenerative tissue and repair
 - postoperative
 - rate-limiting step for recovery is biologic healing of RTC tendon to greater tuberosity, which is believed to take 8-12 weeks
 - peribursal tissue and holes drilled in greater tuberosity are major source of vascularity to repaired rotator cuff
 - vascularity can increase with exercise
 - postop with limited passive ROM (no active ROM)
 - outcomes
 - Worker's Compensation patients report worse outcomes
 - higher postop disability and lower patient satisfaction
 - patients should expect to return to full work duty by 6-10 months after surgery
 - **tendon transfer**
 - indications
 - massive cuff tears
 - techniques (see details below)
 - pectoralis major transfer
 - latissimus dorsi transfer

- best for irreparable posterosuperior tears with intact subscapularis
 - **superior capsular reconstruction**
 - indications
 - massive irreparable rotator cuff tear with intact subscapularis
 - **reverse total shoulder arthroplasty**
 - indications
 - massive cuff tears with glenohumeral arthritis with intact deltoid

• **Technique**

○ **Mini-open rotator cuff repair**

- once was gold standard but has been largely been replaced by arthroscopic techniques
- approach
 - small horizontal variant of shoulder lateral (deltoid splitting) approach
- advantages over open approach
 - decreased risk of deltoid avulsion
 - faster rehabilitation (do not need to protect deltoid repair)
 - may begin passive ROM immediately to prevent adhesive capsulitis
 - most surgeons wait ~6 weeks before initiating active ROM

○ **Arthroscopic rotator cuff repair**

- advantages
 - studies now show equivalent results to open or mini-open repair
- important concepts
 - margin convergence

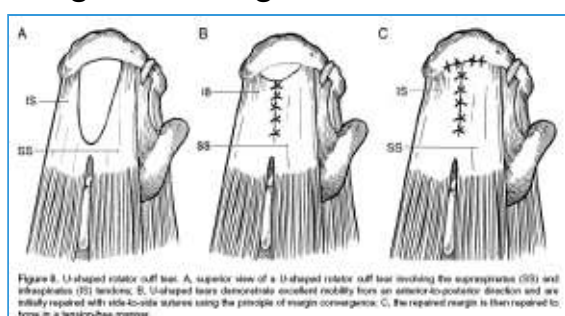


Figure 9. U-shaped rotator cuff tear. A, superior view of a U-shaped rotator cuff tear involving the supraspinatus (SS) and infraspinatus (IS) tendons. B, U-shaped tears demonstrate excellent mobility from an anterior-to-posterior direction and are initially repaired with side-to-side sutures using the principle of margin convergence. C, the repaired margin is then repaired to bone in a tension-free manner.

- shown to decrease strain on lateral margin in U shaped tears
 - anterior interval slide

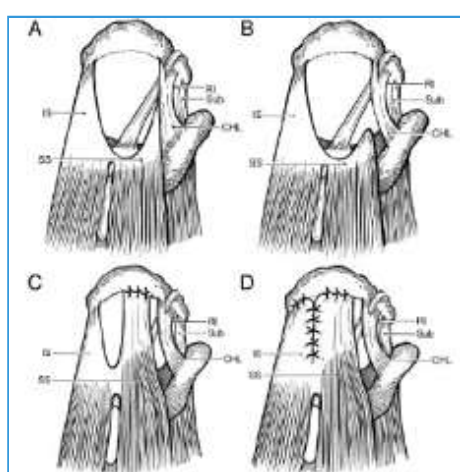


Figure 11. Massive, contracted longitudinal rotator cuff tear. A, superior view; B, an anterior interval slide is performed by incising the interval between the supraspinatus tendon (SS) and rotator interval (RI); C, the improved mobility from the release allows repair of the supraspinatus tendon to a lateral bone bed; D, the posterior leaf of the tear consisting of the infraspinatus (IS) and teres minor tendons is then advanced superiorly and laterally and the residual longitudinal defect is closed by side-to-side sutures. Sub, subscapularis tendon; CHL, coracohumeral ligament.

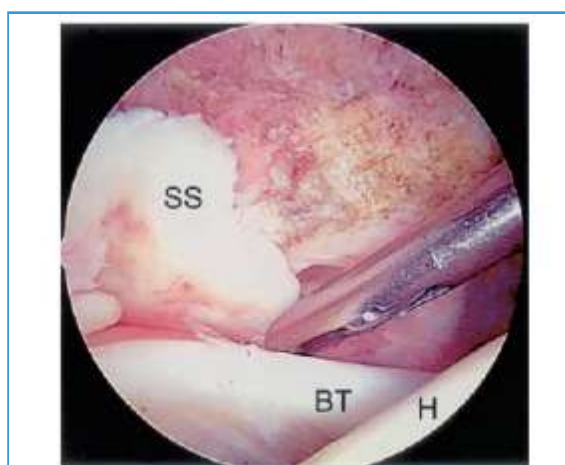
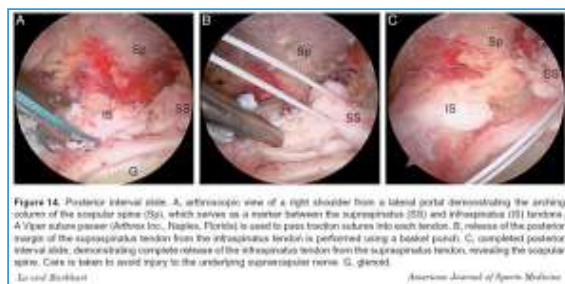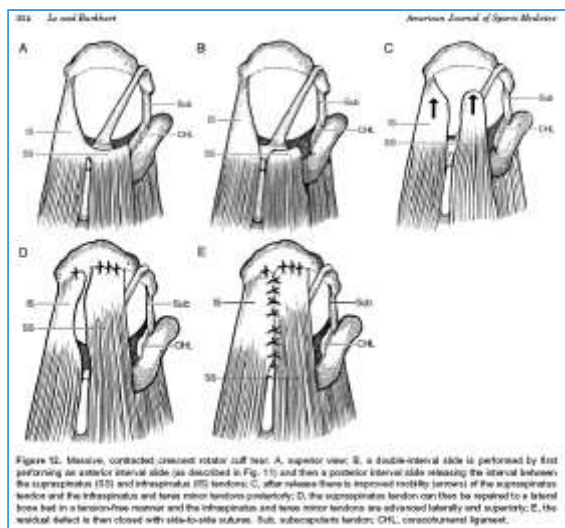
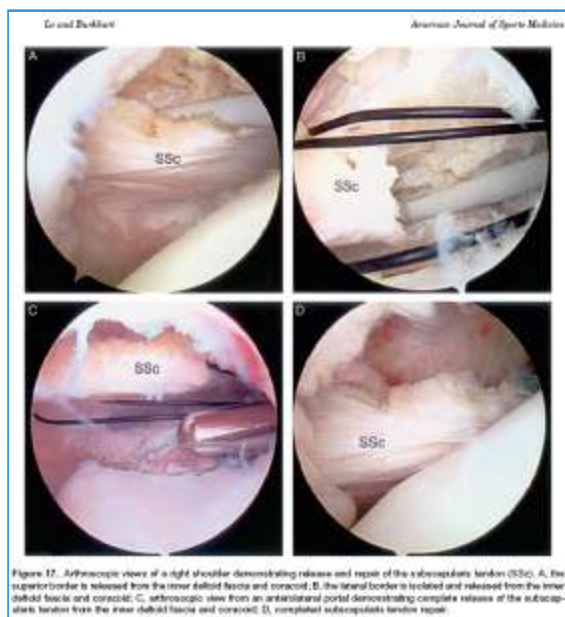


Figure 13. Anterior interval slide. Arthroscopic view of a right shoulder from a posterior portal demonstrating an anterior interval slide with release of the anterior margin of the supraspinatus tendon (SS). Care is taken to avoid injury to the underlying biceps tendon (BT). (Note: All arthroscopic figures are oriented from a beach-chair perspective with the head toward the top of the figure). H, humerus.

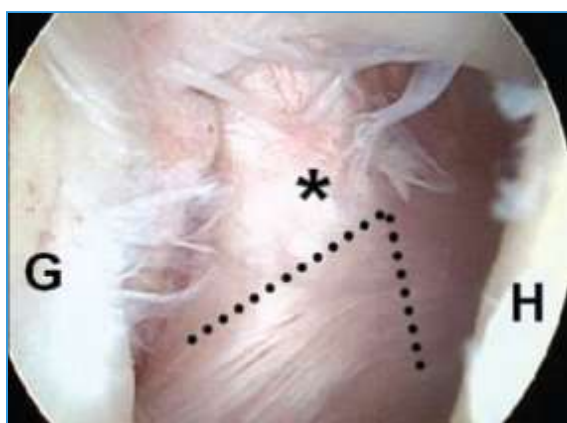- release supraspinatus from the rotator interval (effectively incising coracohumeral ligament). This increases the mobility of supraspinatus and allows it to be fixed to the lateral footprint.
- posterior interval slide



- release supraspinatus from infrapinatus. This further increases the mobility of supraspinatus and allows it to be fixed to the lateral footprint. Then repair supraspinatus to infrapinatus with margin convergence.
- subscapularis repair



- although arthroscopic repair is technically challenging, new studies show superior outcomes (motion and pain) compared to open repair
- stabilize biceps tendon with tenodesis
- posterior lever push maneuver useful to identify insertional humeral footprint tears
- superolateral margin of subscapularis identified by the "comma sign"
 - superior glenohumeral and coracohumeral ligaments attach to the subscapularis tendon



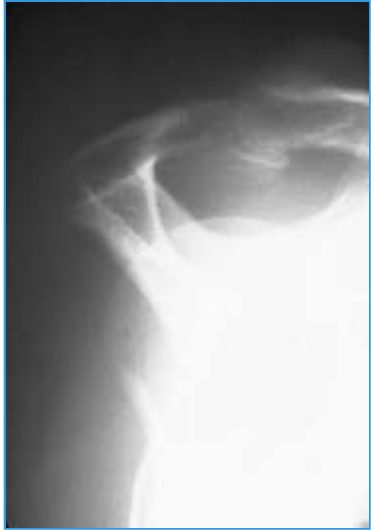
- long head biceps tendon repair
 - most studies show negligible difference between tenotomy vs. tenodesis after concurrent rotator cuff repair
- footprint restoration
 - it is hypothesized that a larger footprint will improve healing and the mechanical strength of the rotator cuff repair
 - double row suture techniques (mattress sutures in medial row and simple sutures in lateral row) have been shown to create a more anatomic repair of the footprint
 - lower retear rate compared with single row
 - no difference in functional score, pain score, time to healing (compared to single row)

- addition of a trough in the greater tuberosity to allow tendon-to-cancellous bone interface as opposed to tendon-to-cortical bone has NOT show increased repair strength in animal models
 - coracoacromial ligament release
 - release leads to an increased anterior/inferior translation of the glenohumeral joint
 - acromioclavicular joint arthritis
 - no significant difference in long-term functional outcomes, shoulder range of motion, or reoperation rates when performing rotator cuff repair with concomitant distal clavicle resection compared to rotator cuff repair alone
 - **Tendon transfer**
 - indicated for massive and irreparable rotator cuff tears
 - pectoralis major transfer
 - indicated in chronic subscapularis tears
 - transferring pectoralis major under the conjoined tendon more closely replicates the vector forces of the native subscapularis
 - requires 4-6 weeks of rigid immobilization
 - latissimus dorsi transfer
 - indicated in large supraspinatus and infraspinatus tears
 - best candidate is young laborer
 - attach to cuff muscles, subscapularis, and GT
 - brace immobilize for 6 wks. in 45° abduction and 30° ER.
 - nerves at risk
 - radial nerve
 - runs along anterior surface of latissimus dorsi, ~3cm medial to humeral insertion
 - at risk during tenotomy
 - posterior branch of the axillary nerve
 - runs in deep fascia of posterior deltoid
 - at risk during passage of tendon deep to deltoid to subacromial space
 - **Superior capsular reconstruction with biologic or synthetic grafts**
 - some recent evidence of improved outcomes with the use of xenograft, allograft, or synthetic patches for massive cuff tears
 - limited human and long-term studies
 - xenograft
 - from bovine dermis or intestine
 - mixed functional outcomes and graft incorporation
 - allograft
 - from human skin or muscular fascia
 - some evidence of good function and survival at short-term
 - synthetics
 - concern for foreign body reaction
 - mixed functional results
 - **Lateral acromionectomy**
 - historic significance only
 - contraindicated due to high complication rate
- **Complications**
 - Recurrence / repair failure
 - most common cause of failed RCR is failure of cuff tissue to heal, resulting in suture pull out from repaired tissue
 - patient risk factors for repair failure
 - patient age >65 years is a risk factor for non-healing of rotator cuff repair and subsequent failure
 - large tear size (>5 cm)
 - muscle atrophy
 - diabetes
 - smokers
 - tear retraction medial to glenoid
 - poor compliance with post-op protocol
 - no difference in clinical outcomes or healing with early vs. delayed motion protocols
 - multiple tendons involved
 - concomitant AC and/or biceps procedures performed at time of repair

- treatment
 - **revision rotator cuff repair vs RTSA**
 - variables to consider when choosing revision RCR vs RTSA
 - patient age (older age favors RTSA)
 - etiology of re-tear
 - quality of tissue / MRI findings
 - static proximal humeral migration (favors RTSA)
 - Deltoid detachment
 - complication seen with open approach
 - AC pain
 - Axillary nerve injury
 - Suprascapular nerve injury
 - may occur with aggressive mobilization of supraspinatus during repair
 - Lateral femoral cutaneous nerve injury
 - Secondary to beach chair positioning without appropriate padding
 - Infection
 - less than 1% incidence
 - Usually common skin flora: staph aureus, strep, p.acnes
 - Propionibacterium acnes is the most commonly implicated organism in delayed or indolent cases
 - risk factors
 - patients who underwent an injection within 3 months of surgery
 - Stiffness
 - Physical therapy and guided early range of motion exercises are not shown to reduce stiffness one-year post-operatively
 - Pneumothorax
 - Can be a complication of regional anesthesia (interscalene or supraclavicular block) or the arthroscopy itself
- Prognosis
 - 50% of asymptomatic tears become symptomatic in 2-3 years
 - 50% of symptomatic full-thickness tears progress at 2 years and bigger tears progress faster

5- Subacromial Impingement

Images



• Summary

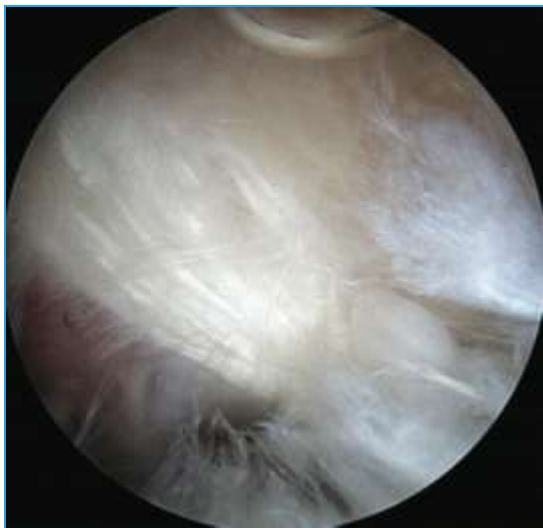- Subacromial impingement is the most common cause of shoulder pain which occurs as a result of compression of the rotator cuff muscles by superior structures (AC joint, acromion, CA ligament) leading to inflammation and development of bursitis.
- Diagnosis can be made on physical examination with a positive Neer and Hawkins tests, and can be supplemented with MRI studies.
- Treatment is a trial of nonoperative measures including NSAIDs, physical therapy and corticosteroid injections. Arthroscopic subacromial decompression with possible acromioplasty is indicated in patients who fail conservative measures.

• Epidemiology

- Incidence
 - subacromial impingement is the most common cause of shoulder pain
 - accounts for 44-65% of shoulder disorders

• Etiology

- Pathophysiology
 - subacromial impingement is thought to be a combination of
 - extrinsic compression
 - of the rotator cuff between the humeral head and
 - anterior acromion
 - coracoacromial ligaments

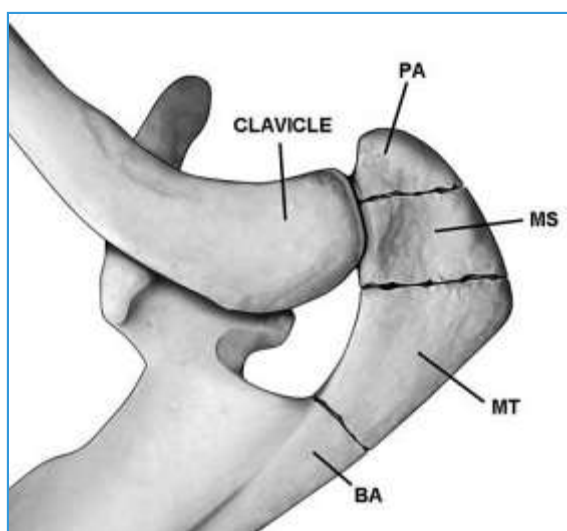


- acromioclavicular joint
- intrinsic degeneration
 - supraspinatus
 - attrition of the supraspinatus leads to inability to balance the humeral head on the glenoid causing superior migration and narrowing of the subacromial space
- inflammatory process
 - inflammation of the subacromial bursa due to abutement between the humerus and rotator cuff, and acromion and associated ligaments

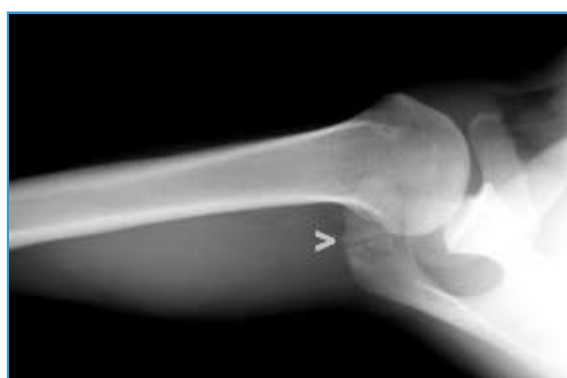- Subacromial impingement is the first stage of rotator cuff disease which is a continuum of disease from
 - impingement and bursitis
 - partial to full-thickness tear
 - massive rotator cuff tears
 - rotator cuff tear arthropathy
- Associated conditions
 - hook-shaped acromion
 - os acromiale
 - posterior capsular contracture
 - scapular dyskinesia
 - tuberosity fracture malunion
 - instability

• Anatomy

- Acromion
 - 3 ossification centers unite to form the acromion



- meta-acromion (base)
- meso-acromion (mid)
- pre-acromion (tip)
- failure of the ossification centers to fuse results in an os acromiale



• Classification

- Bigliani classification
 - studies have shown classification system has poor inter observer reliability

<ul style="list-style-type: none"> Bigliani classification of acromion morphology (based on a supraspinatus outlet view) 		
<ul style="list-style-type: none"> Type I 	<ul style="list-style-type: none"> Flat 	<ul style="list-style-type: none">
<ul style="list-style-type: none"> Type II 	<ul style="list-style-type: none"> Curved 	<ul style="list-style-type: none">
<ul style="list-style-type: none"> Type III 	<ul style="list-style-type: none"> Hooked 	<ul style="list-style-type: none">

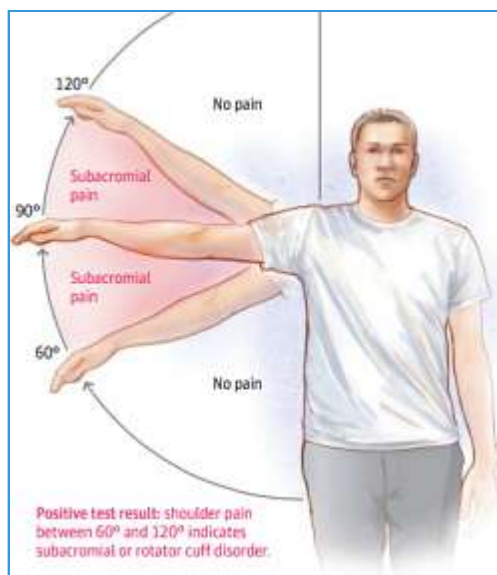
• Presentation

○ Symptoms

- pain
 - insidious onset
 - exacerbated by overhead activities and lifting objects away from body
 - night pain
 - poor indicator of successful nonoperative management

○ Physical exam

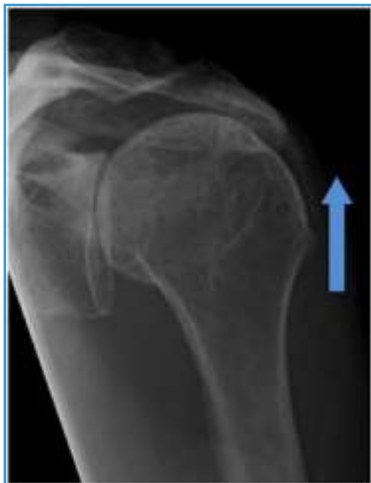- strength
 - usually normal
 - impingement tests (see complete physical exam of shoulder)
 - positive Neer impingement sign
 - positive if passive forward flexion $>90^\circ$ causes pain
 - positive Neer impingement test
 - if a subacromial injection relieves pain associated with passive forward flexion $>90^\circ$
 - positive Hawkins test
 - positive if internal rotation and passive forward flexion to 90° causes pain
 - Jobe test
 - pain with resisted pronation and forward flexion to 90° indicates supraspinatus pathology
 - Painful Arc Test
 - pain with arm abducted in scapular plane from 60° to 120°



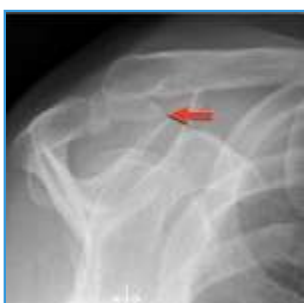- Yocum Test
 - positive if pain reproduced with elbow elevation while ipsilateral hand placed on contralateral shoulder
 - sensitive but nonspecific
 - Internal Impingement test
 - positive if pain is elicited with abduction and external rotation of the shoulder

• Imaging

- Radiographs
 - recommended views
 - true AP of the shoulder
 - useful in evaluating the acromiohumeral interval
 - normal distance is 7-14 mm
 - 30° caudal tilt view
 - useful in identifying subacromial spurring
 - supraspinatus outlet view
 - useful in defining acromial morphology
 - findings
 - common radiographic findings associated with impingement
 - proximal migration of the humerus as seen in rotator cuff tear arthropathy



- traction osteophytes
- calcification of the coracoacromial ligament
- cystic changes within the greater tuberosity
- Type III-hooked acromion
 - associated with impingement
- os acromiale



- best seen on axillary lateral

- MRI
 - useful in evaluating the degree of rotator cuff pathology
 - subacromial and subdeltoid bursitis often seen
- CT arthrography
 - can also accurately image the rotator cuff tendons and muscle bellies
- Ultrasound
 - can also accurately image the rotator cuff tendons and muscle bellies

• Studies

- Histology
 - tendinopathy histology shows
 - disorganized collagen fibers
 - mucoid degeneration
 - inflammatory cells
 - inflammation of the subacromial bursa
 - high levels of metalloproteases and other inflammatory cytokines

• Treatment

- Nonoperative
 - **physical therapy, oral anti-inflammatory medication, subacromial injections**
 - indications
 - first line and mainstay of treatment of subacromial impingement alone without rotator cuff tear
 - techniques

- aggressive rotator cuff strengthening and periscapular stabilizing exercises
- an integrated rehabilitation program is indicated in the presence of scapular dyskinesia which aims to regain full shoulder range of motion and coordinate the scapula with trunk and hip motions
- platelet-rich plasma injections
 - most recent meta-analysis showing insufficient evidence to support use

○ Operative

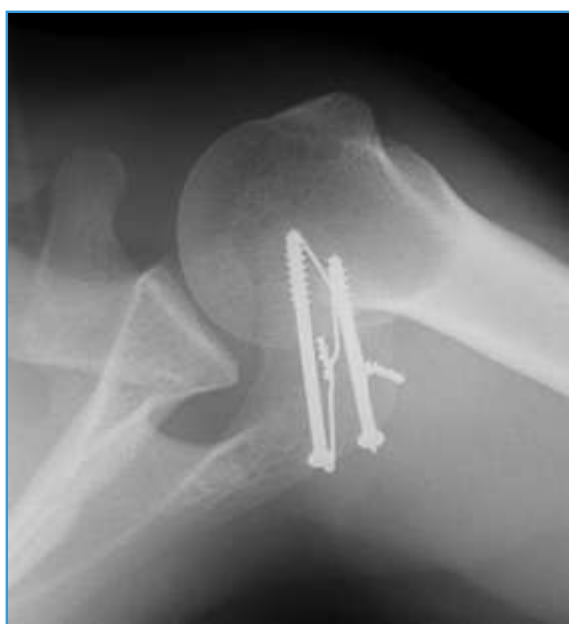▪ **subacromial decompression / acromioplasty**

- indications
 - subacromial impingement syndrome that has failed a minimum of 4-6 months of nonoperative treatment
- outcomes
 - poor subjective outcomes have been observed after acromioplasty in patients with
 - workers' compensation claims
 - anxiety and depression

• Technique

○ **Subacromial decompression and acromioplasty**

- acromioplasty
 - two-step procedure performed open or arthroscopically
 - an anterior acromionectomy is performed first
 - the anterior deltoid origin determines the extent of the acromionectomy when performed arthroscopically and must remain intact
 - an anteroinferior acromioplasty to smooth the undersurface of the acromion follows as the second step of the procedure
 - a bone rasp is used if performed open
 - a shaver or burr is used if performed arthroscopically
 - the deltoid is meticulously repaired to bone in open procedures
 - treatment of an os acromiale
 - a two-stage procedure may be required with the presence of an os acromiale to avoid deltoid dysfunction caused by direct excision
 - the os acromiale is first fused with bone graft and allowed to heal



- an acromioplasty is then performed as a separate second procedure

• Complications

- Deltoid dysfunction
 - resulting from a failed deltoid repair following an open acromioplasty or an excessive acromionectomy during an arthroscopic procedure
 - secondary to direct excision of an os acromiale
- Anterosuperior escape
 - avoid acromioplasty and CA ligament release to preserve the coracoacromial arch in patients with massive, irreparable rotator cuff tears

6- Calcific Tendonitis

- summary

- Calcific tendonitis is the calcification and tendon degeneration near the rotator cuff insertion, most commonly leading to shoulder pain with decreased range of motion.
- Diagnosis can be made radiographically with orthogonal radiographs of the shoulder showing calcium deposits overlying the rotator cuff insertion.
- Treatment is a course of NSAIDs, physical therapy, corticosteroid injections and ultrasound-guided needle lavage. Arthroscopic decompression of the calcium deposit is indicated for patients with progressive symptoms having failed conservative measures.











- Epidemiology

- Demographics
 - typically affects patients aged 30 to 60
 - more common in women
- Anatomic location
 - supraspinatus tendon is most often involved
- Risk factors
 - association with endocrine disorders
 - diabetes
 - hypothyroidism

- Etiology

- Pathophysiology
 - unknown etiology
 - pathoanatomy
 - three stages of calcification
 - precalcific
 - fibrocartilaginous metaplasia of the tendon
 - clinically this stage is pain-free
 - calcific
 - subdivided into three phases
 - formative phase
 - characterized by cell-mediated calcific deposits
 - +/- pain
 - resting phase
 - lacks inflammation or vascular infiltration
 - +/- pain
 - resorptive phase
 - characterized by a phagocytic resorption and vascular infiltration
 - clinically this phase is most painful
 - postcalcific
 - cellular biochemistry
 - calcium hydroxyapatite crystals are deposited
 - key molecular pathways involved
 - osteopontin
 - cathepsin K
 - transglutaminase 2

- Classification

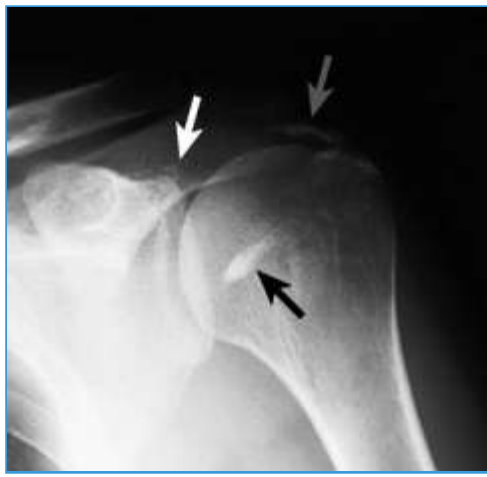<ul style="list-style-type: none"> ■ Gartner and Heyer Classification of Calcific Tendinitis 		
<ul style="list-style-type: none"> ■ Type I 	<ul style="list-style-type: none"> ■ Well circumscribed, dense calcification, formative 	<ul style="list-style-type: none"> ■  ■ 
<ul style="list-style-type: none"> ■ Type II 	<ul style="list-style-type: none"> ■ Soft contour/dense or sharp/transparent 	<ul style="list-style-type: none"> ■  ■ 
<ul style="list-style-type: none"> ■ Type III 	<ul style="list-style-type: none"> ■ Translucent and cloudy appearance without clear circumscription, resorptive 	<ul style="list-style-type: none"> ■  ■ 
<ul style="list-style-type: none"> ■ Mole et al. Classification of Calcific Tendinitis 		
<ul style="list-style-type: none"> ■ Type A 	<ul style="list-style-type: none"> ■ Dense, homogeneous, sharp contours 	<ul style="list-style-type: none"> ■ 
<ul style="list-style-type: none"> ■ Type B 	<ul style="list-style-type: none"> ■ Dense, segmented, sharp contours 	<ul style="list-style-type: none"> ■ 
<ul style="list-style-type: none"> ■ Type C 	<ul style="list-style-type: none"> ■ Heterogeneous, soft contours 	<ul style="list-style-type: none"> ■ 
<ul style="list-style-type: none"> ■ Type D 	<ul style="list-style-type: none"> ■ Dystrophic calcifications at the insertion of the rotator cuff tendon 	<ul style="list-style-type: none"> ■ 

• Presentation

- History
 - similar to the clinical presentation of subacromial impingement
- Symptoms
 - atraumatic pain (most severe in resorptive phase)
 - catching, crepitus
 - mechanical block
- Physical exam
 - inspection
 - supraspinatus fossa muscle atrophy
 - motion
 - decreased active range of motion
 - scapular dyskinesia
 - may be associated with a decrease in rotator cuff strength
 - provocative tests
 - subacromial impingement signs

• Imaging

- Radiographs
 - gold standard for diagnosis
 - views
 - AP, supraspinatus outlet, and axillary views show supraspinatus calcification
 - internal rotation view shows infraspinatus and teres minor calcification
 - external rotation view shows subscapularis calcification
 - findings
 - deposits usually 1 to 1.5cm from supraspinatus tendon insertion
 - useful to monitor progression over time



- allow assessment of location, density, extent, and delineation of deposit

- CT

- indications
 - rarely required
 - may characterize the three-dimensional shoulder anatomy

- MRI

- indications
 - limited utility in the diagnosis of calcific tendonitis
 - consider in patients with refractory pain as it can assess for concomitant pathology (e.g., rotator cuff tears)
- findings
 - calcific deposits have low signal intensity on all sequences

- Ultrasound

- indications
 - may be useful to quantify the extent of the calcification
 - also utilized for guidance during needle decompression and injection
- findings
 - deposits are hyperechoic

- Treatment

- Nonoperative

- **NSAIDs, physical therapy, stretching & strengthening, steroid injections**

- indications
 - first line of treatment for all phases
- techniques
 - steroid injections
 - commonly used but controversial
 - duration of relief is variable
- outcomes
 - resolution of symptoms in 60-70% of patients after 6 months
 - increased probability of failure when:
 - bilateral or large calcifications
 - deposits underlying the anterior third of acromion
 - deposits extending medial to the acromion

- **extracorporeal shock-wave therapy**

- indications
 - adjunct treatment
 - most useful in refractory calcific tendonitis in the formative and resting phases
- modalities
 - high- vs. low-energy therapy
- outcomes
 - dose dependent outcomes
 - high-energy > low-energy in clinical outcome scores, and rate of calcific deposit resorption
 - high-energy > low-energy in procedural pain and local reaction (e.g. ecchymosis)

- **ultrasound-guided needle lavage vs. needle barbotage**

- indications
 - persistent symptomatic calcific tendonitis in the resorptive phase
- outcomes
 - improved outcomes in patients with Type II/III calcific tendinitis vs Type I

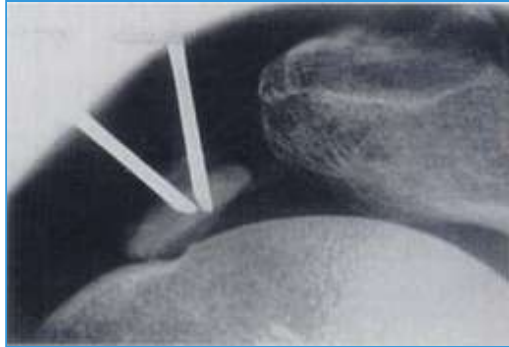
- Operative

- **surgical decompression of calcium deposit**
 - indications
 - progression of symptoms
 - refractory to nonoperative treatments
 - interference with activities of daily living
 - outcome
 - good results in short term outcome studies
 - longer return to work with subacromial decompression and/or rotator cuff repair
 - risk of shoulder stiffness with operative treatment

• Techniques

○ **Ultrasound-guided needle lavage**

- technique
 - two needles to maintain an outflow system for lavage



- small amount of saline+/-anesthetic injected around the calcification
- aspiration of calcific material with other needle

○ **Needle barbotage**

- technique
 - use needle to break up calcium deposit then follow with by corticosteroid injection

○ **Surgical decompression of calcium deposit**

- approach
 - may be done arthroscopically or with mini-open approach
- technique
 - +/- subacromial decompression
 - +/- rotator cuff repair

• Complications

- Recurrence
- Persistent shoulder pain
- Shoulder stiffness
- Iatrogenic injury to rotator cuff with operative treatment

7- Biceps Tendonitis

- summary

- Biceps tendonitis is a well recognized source of anterior shoulder pain that may be associated with subscapularis tears and subacromial impingement.
- Diagnosis can be suspected clinically with anterior shoulder pain made worse with provocative tests and confirmed with MRI studies to evaluate for concurrent pathology.
- Treatment involves an initial trial of NSAIDs, activity modification and physical therapy. Arthoscopic versus open biceps tenodesis/tenotomy is indicated for recurrent symptoms.

- Etiology

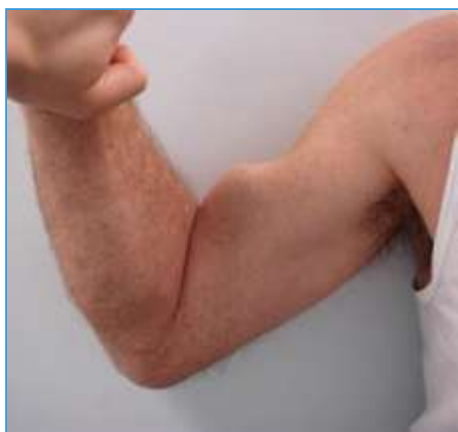- Pathoanatomy
 - more consistent with "tendinosis" than true inflammation
- Often associated with other primary shoulder pathology
 - subacromial impingement
 - stenosis of bicipital groove
 - rotator cuff tears
 - especially subscapularis pathology

- Anatomy

- Glenohumeral anatomy
- Bicep long head tendon
 - originates off supraglenoid tubercle and superior labrum
 - stabilized within bicipital groove by transverse humeral ligament

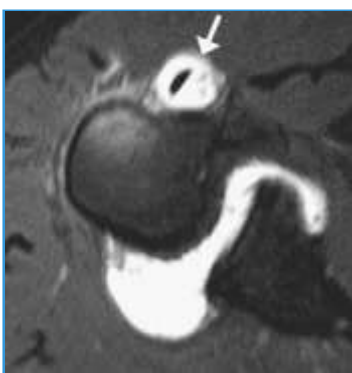
- Presentation

- Symptoms
 - pain
 - anterior shoulder pain
 - may have pain radiating down the in the region of the biceps
 - symptoms may be similar in nature and location to rotator cuff or subacromial impingement pain
- Physical exam
 - tenderness with palpation over biceps groove
 - worse with arm internally rotated 10 degrees
 - Speed test
 - pain elicited in bicipital groove when patient attempts to forward elevate shoulder against examiner resistance while elbow extended and forearm supinated.
 - may also be positive in patients with SLAP lesions.
 - Yergason's test
 - pain elicited in biceps groove when patient attempts to actively supinate against examiner resistance with elbow flexed to 90-degrees and forearm pronated
 - "popeye" deformity
 - indicates rupture



- Imaging

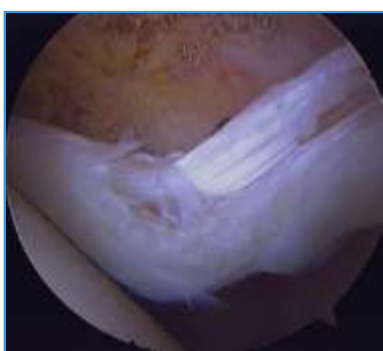
- Ultrasound
 - can show thickened tendon within bicipital groove
- MRI



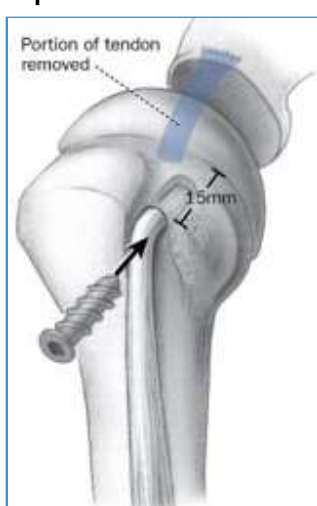
- can show thickening and tenosynovitis of proximal biceps tendon
 - increased T2 signal around biceps tendon

• Treatment

- Nonoperative
 - **NSAIDS, PT strengthening, and steroid injections**
 - indications
 - first line of treatment
 - technique
 - direct steroid injection in proximity, but not into tendon
- Operative
 - **arthroscopic tenodesis vs. tenotomy**
 - indications
 - surgical release reserved for refractory cases for bicep pathology seen during arthroscopy



- technique
 - repair vs. release/tenodesis



- post-op rehab: tenodesis
 - avoid active forearm supination with the elbow at 90° of flexion
- outcomes
 - tenotomy is associated with increased rate of cosmetic deformity ("Popeye deformity")
 - tenodesis may be associated with "groove pain"
 - no difference in strength, functional outcomes, or range of motion between two techniques

8- Biceps Subluxation

• summary

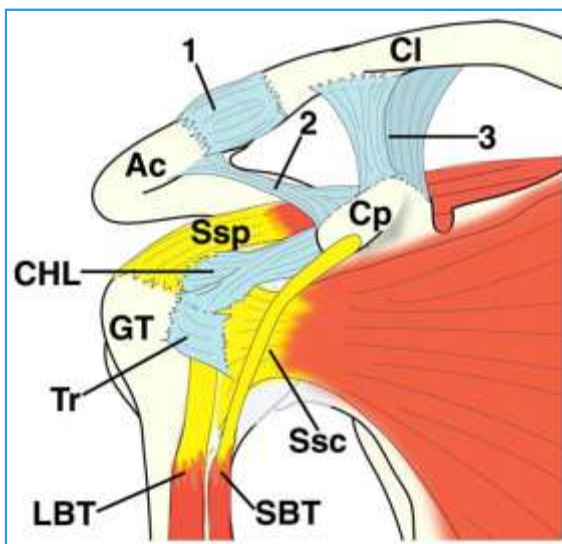
- Biceps subluxation is a recognized cause of anterior shoulder pain usually associated with a subscapularis tear.
- Diagnosis can be suspected clinically with anterior shoulder pain made worse with provocative tests and confirmed with MRI studies to evaluate for concurrent subscapularis tear.
- Treatment involves an initial trial of NSAIDs, activity modification and physical therapy. Arthroscopic versus open biceps tenodesis/tenotomy with or without subscapularis repair is indicated for recurrent symptoms.

• Etiology

- Pathophysiology
 - most commonly associated with
 - subscapularis tears
 - most common associated pathology
 - disruption of the biceps sling

• Anatomy

- Biceps tendon anatomy
 - originates off supraglenoid tubercle and superior labrum
 - stabilized by the biceps sling which is comprised of



- fibers of the subscapularis
- supraspinatus
- coracohumeral
- superior glenohumeral ligaments
- Function
 - acts as dynamic stabilizer
 - involved in movement such as shoulder flexion, abduction
- Complete glenohumeral anatomy

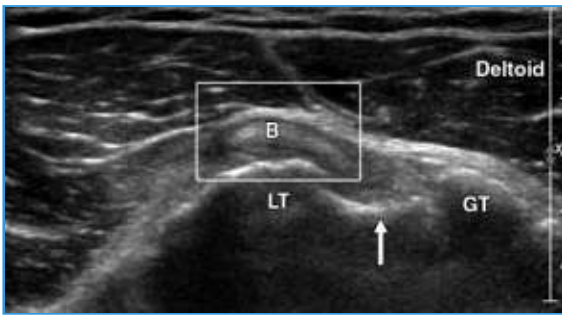
• Presentation

- Symptoms
 - anterior shoulder pain
 - may have sensation of clicking
- Physical exam of shoulder
 - strength
 - due to the association with subscapularis tears, strength of the subscapularis muscle should be performed
 - biceps provocation tests
 - Yergason's test
 - anterior shoulder pain with resisted forearm supination with the arm at the side and the elbow flexed to 90 degrees.
 - Speed's test
 - anterior shoulder pain with resisted shoulder flexion with the shoulder flexed at 90 degrees, elbow in full extension and the palm facing upwards"

- palpable click
 - may be produced with arm abduction and external rotation
 - occurs when tendon subluxes or dislocates out of groove

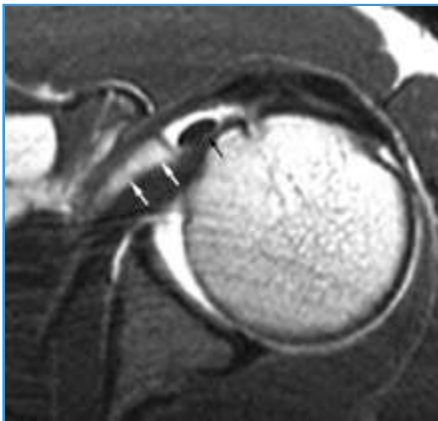
• Imaging

○ Ultrasound



- can give dynamic test of bicep instability

○ MRI



- can show increased T2 signal, and displacement out of the bicipital groove
- coincides with subscapularis tears
 - decreased angle between the long head biceps to glenoid during arthroscopy has been associated with biceps tendon subluxation

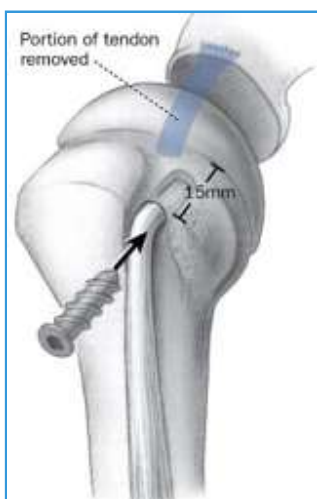• Treatment

○ Nonoperative

- **NSAIDS, PT strengthening, and steroid injections**
 - indications
 - initial management
 - technique
 - direct steroid injection in proximity, but not into tendon

○ Operative

- **arthroscopic vs open biceps tenotomy vs tenodesis**



- indications
 - reserved for refractory cases for bicep pathology
- technique
 - performed with or without subscapularis repair
 - can test instability intra-operatively

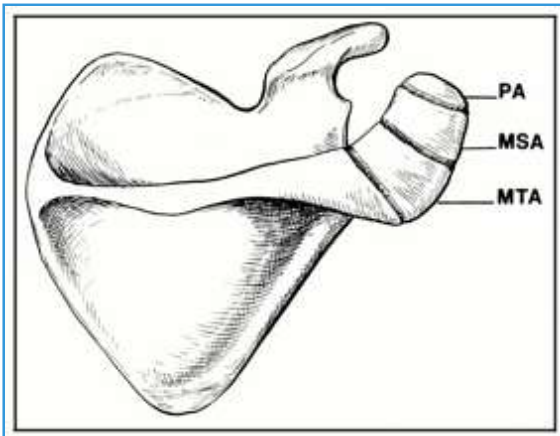
9- Os Acromiale

• summary

- An Os Acromiale is an unfused secondary ossification center of the acromion that can be associated with shoulder impingement and rotator cuff tendonitis.
- Diagnosis is made with axillary lateral radiographs of the shoulder.
- Treatment is observation in the majority of cases with operative management reserved for patients who have persistent shoulder impingement or rotator cuff disease that have failed nonoperative management.

• Epidemiology

- Incidence
 - common
 - 8%
 - bilateral in 60%
- Demographics
 - more common in males
 - more common in African American
- Anatomic location



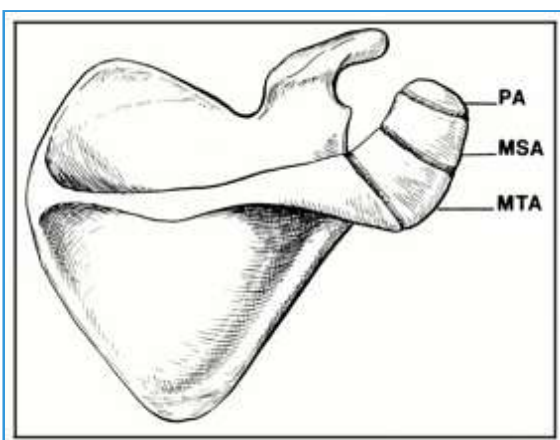
- most common location is the junction of meso- and meta-acromion

• Etiology

- Associated conditions
 - shoulder impingement
 - rotator cuff disease
 - meso-acromion is associated with rotator cuff tendonitis and full thickness tears (in 50%)

• Anatomy

- 3 ossification centers



- meta-acromion (base)
 - origin of posterior portion of deltoid
- meso-acromion (mid)
 - origin of middle deltoid
- pre-acromion (tip)
 - origin of anterior deltoid fibers and coracoacromial ligament
- Blood supply
 - acromiale branch of thoracoacromial artery

- Presentation

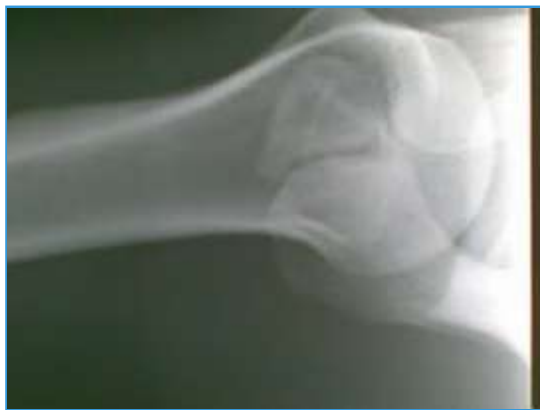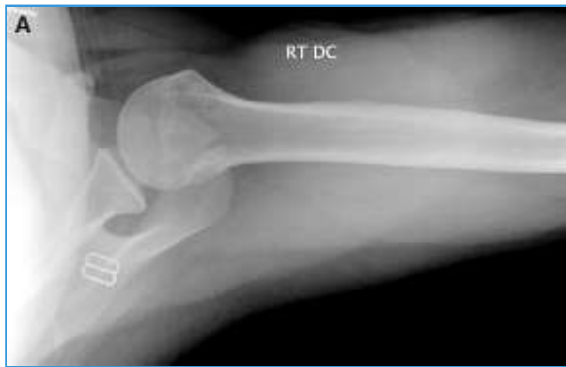- History

- pain
 - from impingement
 - reduction in subacromial space from flexion of the anterior fragment with deltoid contraction and arm elevation
 - from motion at the nonunion site (painful synchondrosis)
 - incidental finding on radiographs
 - trauma can trigger onset of symptoms from previously asymptomatic os acromiale

- Imaging

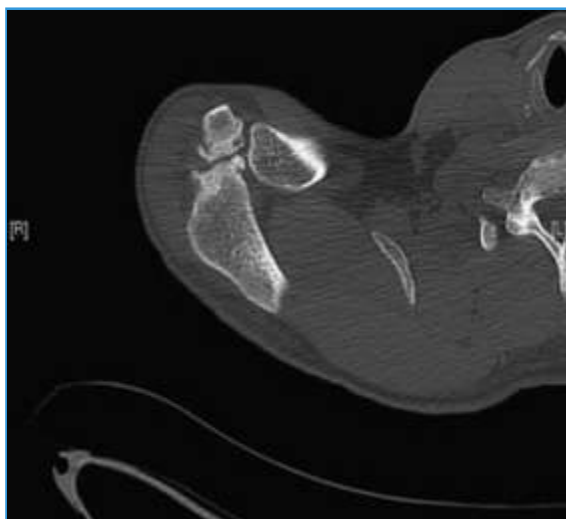
- Radiographs

- recommended views
 - best seen on an axillary lateral of the shoulder



- CT

- indications
 - to better visualize the nonunion site
 - to detect degenerative changes (cysts, sclerosis, hypertrophy)



- Treatment

- Nonoperative

- **observation, NSAIDS, therapy, subacromial corticosteroid injections**
 - indications
 - mild symptoms

- Operative

- **two-stage fusion**
 - indications
 - symptomatic os acromiale with impingement
 - technique
 - direct excision can lead to deltoid dysfunction
 - a two-stage procedure may be required
 - first stage - fuse the os acromiale ± bone graft

- second stage - perform acromioplasty
- preserve blood supply (acromiale branch of thoracoacromial artery)
- tension band wires, sutures, cannulated screws
- **arthroscopic subacromial decompression and acromioplasty**
 - indications
 - impingement with/without rotator cuff tear (where the os acromiale is only incidental and nontender)
- **open or arthroscopic fragment excision**
 - indications
 - symptomatic pre-acromion with small fragment
 - salvage after failed ORIF
 - results
 - arthroscopic has less periosteal and deltoid detachment
 - better excision results with pre-acromion

• Complications

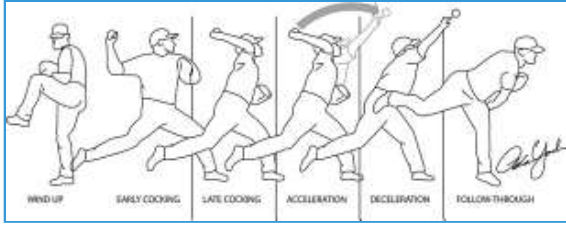
- Deltoid weakness
 - from fragment excision
- Persistent pain/weakness

• Prognosis

- Poorer outcomes after rotator cuff repairs in patients with meso-os acromiale

10- Phases Of Throwing

Images



• Phases of Throwing

- There are 5 main phases of throwing
 - wind up (see below)
 - cocking
 - acceleration
 - deceleration
 - follow-through
- Biomechanics
 - scapula must work in concert with humerus to maintain glenohumeral stability
 - the entire throwing motion takes approximately 2 seconds
 - with wind up and acceleration phases taking approximately 75% of time (1.5 seconds)

• 1. Wind Up

- Description
 - minimal force on the shoulder during first stage
- Muscle activity
 - rotator cuff muscles are inactive during this phase

• 2. Cocking

- Sometimes described as 2 sub-phases
 - early cocking
 - peak muscle activation
 - deltoid
 - late cocking
 - high torque phase with maximal shoulder external rotation
 - elbow valgus stress is greatest in late cocking phase
 - peak muscle activation
 - supraspinatus
 - infraspinatus
 - teres minor
 - FDS and FCU muscles provide local dynamic stability of the elbow during late cocking
 - protective against injury to UCL
- Associated pathology
 - Medial ulnar collateral ligament elbow injury
 - internal Impingement
 - GIRD (glenohumeral internal rotation defect)
 - SLAP tears ("Peel-back" mechanism during late cocking)

• 3. Acceleration

- Description
 - rotates ball to release point
- Muscle activity
 - early muscle activation
 - triceps
 - late muscle activation
 - pectoralis major

- latissimus dorsi
- serratus anterior

• 4. Deceleration

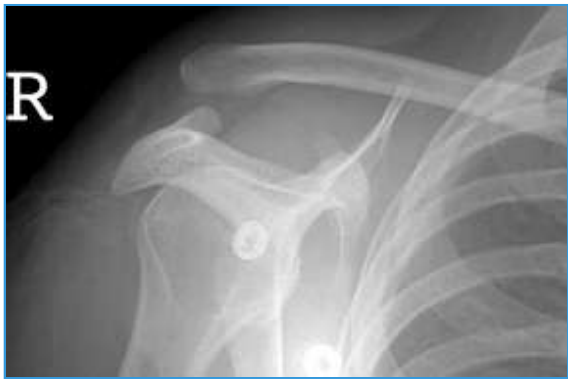- Description
 - center of gravity moves over plantar foot
- Muscle activity
 - eccentric contraction of all muscles is required to slow down arm motion
 - highest torque phase
- Associated pathology
 - recognized as the most harmful phase of throwing
 - associated injuries
 - superior labrum (SLAP lesion)
 - biceps tendon injury
 - brachialis injury
 - teres minor injury

• 5. Follow-through

- Description
 - phase where body rebalances and stops forward motion
- Muscle activity
 - muscle activity returns to resting levels

11- Acromioclavicular Joint Injury

Images



• summary

- An acromioclavicular joint injury, otherwise known as a shoulder separation, is a traumatic injury to the acromioclavicular (AC) joint with disruption of the acromioclavicular ligaments and/or coracoclavicular (CC) ligaments.
- Diagnosis is made with bilateral focused shoulder radiographs to assess for AC and CC interval widening.
- Treatment is immobilization or surgical reconstruction depending on patient activity levels, degree of separation and degree of ligament injury.

• Epidemiology

- Incidence
 - common injury making up 9% of shoulder girdle injuries
- Demographics
 - more common in males and athletes

• Etiology

- Pathophysiology
 - mechanism
 - direct blow to the shoulder
 - often sustained while falling onto the shoulder

• Anatomy

- Osteology
 - diarthrodial joint
 - articulation of the scapula (medial acromion) and the lateral clavicle
 - oblique orientation of joint surface
 - contains a fibrocartilaginous intraarticular disc between the osseous elements
 - analogous to the meniscus of the knee
 - involutes with age, disintegrates by age 40
- Motion
 - primarily gliding motion
 - rotational motion is minimal
 - clavicle rotates 40-50° posteriorly with shoulder elevation
 - only ~8° rotation through the AC joint, due to synchronous scapuloclavicular motion
- Stability
 - static
 - joint capsule
 - acromioclavicular (AC) ligaments
 - controls horizontal motion and anterior-posterior stability
 - has superior, inferior, anterior and posterior components
 - posterior and superior AC ligaments are most important for stability
 - coracoclavicular (CC) ligaments
 - controls vertical motion and superior-inferior stability
 - two ligaments
 - conoid

- attaches to the conoid tubercle, which is posteromedial to the trapezoid tubercle
- inserts on clavicle 4.5cm medial to lateral edge
- most important for vertical stability
- trapezoid
 - attaches to the trapezoid tubercle, which is anterolateral to the conoid tubercle
 - inserts on clavicle 3cm medial to lateral edge
- dynamic
 - anterior deltoid
 - trapezius

• Presentation

○ Symptoms

- pain
 - usually over AC joint
 - can also be referred to the trapezius

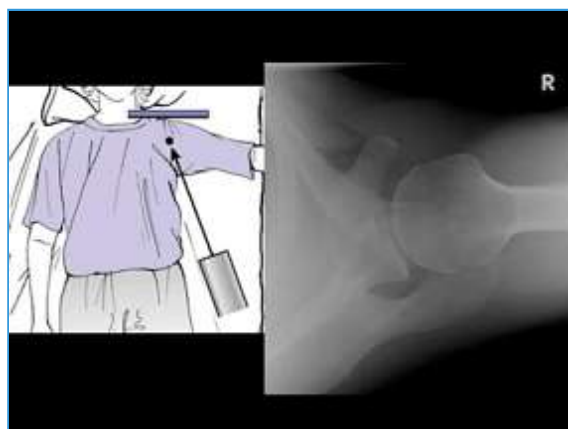
○ Physical exam

- lateral clavicle or AC joint tenderness
- abnormal contour of the shoulder compared to contralateral side
- stability assessment
 - horizontal (anterior-posterior) stability evaluates AC ligaments
 - cross-body adduction
 - horizontal instability (ISAKOS type 3B) may indicate need for more aggressive treatment
 - vertical (superior-inferior) stability evaluates CC ligaments
- AC joint exacerbation tests
 - O'Brien's test
 - superficial pain localized to AC joint is suggestive of AC joint pathology
 - deep pain is suggestive of a SLAP lesion
 - crossbody adduction

• Imaging

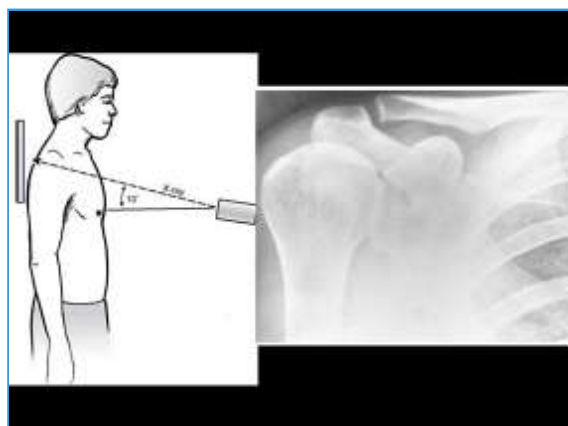
○ Radiographs

- required views
 - bilateral anteroposterior (AP) view of AC joints
 - compare displacement to contralateral side
 - measured as distance from top of coracoid to bottom of clavicle
 - use 1/3 penetration on AP to visualize AC joint
 - axillary lateral view



- required to diagnose Type IV (posterior)

▪ zanca view

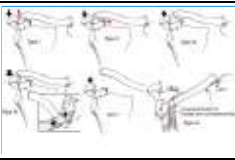

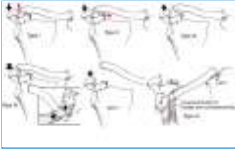



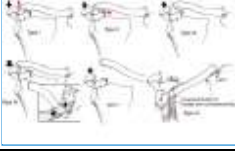







- performed by tilting the x-ray beam 10-15° cephalad and using only 50% of the standard shoulder AP penetration

- additional veiw
 - cross-body adduction view (Basmania)
 - scapular Y performed with cross-body adduction stress
 - weighted stress views
 - usually no longer used
 - may help differentiate Type II from Type III
- findings
 - fractures can mimic AC separations
 - base of coracoid fracture
 - Neer type 2A distal clavicle fracture
 - ligaments remain attached to distal fragment as proximal (medial) fragment displaces

• Classification

○ Rockwood Classification

■ Type	■ AC ligament	■ CC ligament	■ Exam	■ Radiographs	■ Reducibility	■ Treatment	■ Illus.	■ XR
■ Type I	■ Sprain	■ Normal	<ul style="list-style-type: none"> ■ AC tenderness ■ No AC instability 	<ul style="list-style-type: none"> ■ Normal 	<ul style="list-style-type: none"> ■ Reducible 	<ul style="list-style-type: none"> ■ Sling 	<ul style="list-style-type: none"> ■  	<ul style="list-style-type: none"> ■ 
■ Type II	■ Torn	■ Sprain	<ul style="list-style-type: none"> ■ AC horizontal instability 	<ul style="list-style-type: none"> ■ AC joint disrupted ■ Increased CC distance < 25% of contralateral 	<ul style="list-style-type: none"> ■ Reducible 	<ul style="list-style-type: none"> ■ Sling 	<ul style="list-style-type: none"> ■  	<ul style="list-style-type: none"> ■ 
■ Type III	■ Torn	■ Torn	<ul style="list-style-type: none"> ■ AC vertical instability ■ No horizontal stability 	<ul style="list-style-type: none"> ■ AC joint disrupted ■ Increased CC distance 25-100% of contralateral 	<ul style="list-style-type: none"> ■ Reducible 	<ul style="list-style-type: none"> ■ Controversial 	<ul style="list-style-type: none"> ■  	<ul style="list-style-type: none"> ■ 
■ IIIA	■	■	<ul style="list-style-type: none"> ■ AC vertical instability ■ No horizontal stability 	<ul style="list-style-type: none"> ■ 	<ul style="list-style-type: none"> ■ 	<ul style="list-style-type: none"> ■ 	<ul style="list-style-type: none"> ■ 	<ul style="list-style-type: none"> ■
■ IIIB	■	■	<ul style="list-style-type: none"> ■ AC vertical instability ■ H orizontal instability 	<ul style="list-style-type: none"> ■ 	<ul style="list-style-type: none"> ■ 	<ul style="list-style-type: none"> ■ 	<ul style="list-style-type: none"> ■ 	<ul style="list-style-type: none"> ■
■ Type IV	■ Torn	■ Torn	<ul style="list-style-type: none"> ■ Skin tenting ■ P osterior fullness 	<ul style="list-style-type: none"> ■ Lateral clavicle displaced posterior through trapezius on the axillary lateral XR 	<ul style="list-style-type: none"> ■ Not reducible 	<ul style="list-style-type: none"> ■ Surgery 	<ul style="list-style-type: none"> ■  	<ul style="list-style-type: none"> ■ 
■ Type V	■ Torn	■ Torn	<ul style="list-style-type: none"> ■ S evere shoulder droop, does not improve with shrug 	<ul style="list-style-type: none"> ■ Increased CC distance > 100% of contralateral 	<ul style="list-style-type: none"> ■ Not reducible 	<ul style="list-style-type: none"> ■ Surgery 	<ul style="list-style-type: none"> ■  	<ul style="list-style-type: none"> ■ 
■ Type VI	■ Torn	■ Torn	<ul style="list-style-type: none"> ■ Rare; Associated injuries; paresthesias 	<ul style="list-style-type: none"> ■ I nferior dislocation of lateral clavicle, lying either in subacromial or subcoracoid position 	<ul style="list-style-type: none"> ■ Not reducible 	<ul style="list-style-type: none"> ■ Surgery 	<ul style="list-style-type: none"> ■  	<ul style="list-style-type: none"> ■ 

• Differential

- Coracoid fracture
 - base of coracoid fracture can mimic a CC ligament disruption
 - has superiorly displaced distal clavicle, but normal CC distance (normal is 11-13mm)
- Distal Clavicle Fracture (Neer 2A)
 - can mimic AC separations as well, as ligaments remain attached to distal component
- Pediatric medial clavicle physeal injury
- Pediatric distal clavicle physeal injury

• Treatment

○ Nonoperative

▪ **brief sling immobilization, rest, ice, physical therapy**

- indications
 - type I and II
 - type III in most individuals
 - good results when clavicle displaced < 2cm
- rehab
 - early shoulder range of motion
 - regain functional motion by 6 weeks
 - return to normal activity at 12 weeks
 - consider corticosteroid injections
- outcomes
 - type III treated non-op had higher DASH scores at 6 weeks and 3 months, and equal function at 1 year with lower rate of secondary surgery (removal of hardware) compared to those treated operatively
- complications
 - AC joint arthritis
 - chronic subluxation and instability

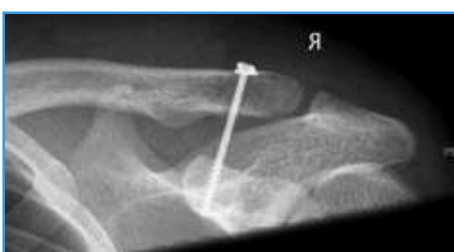○ Operative

▪ **CC interval restoration (ORIF vs. Ligament Reconstruction)**

- indications
 - acute type IV, V or VI injuries
 - recent studies suggest no difference in functional outcomes between operative and nonoperative interventions for high grade injuries
 - acute type III injuries in laborers, elite athletes, patients with cosmetic concerns
 - chronic type III injuries that failed non-op treatment
 - historically it was thought acute injuries were treated with ORIF and chronic injuries were treated with CC ligament reconstruction
 - however, new studies have shown no difference in outcomes in types III injuries treated surgically after 6 weeks non-op treatment versus immediate surgery
- contraindications
 - patient unlikely to comply with postoperative rehabilitation
 - skin problems over fixation approach site
- techniques
 - ligament reconstruction with soft tissue graft
 - Modified Weaver-Dunn
 - distal clavicle excision with transfer of coracoacromial ligament to the distal clavicle to recreate CC ligament
 - autograft
 - allograft
 - fixation
 - suture
 - hook plate
 - CC screw (Bosworth)
 - cortical flip button (e.g Dog Bone)(+/- arthroscopic assistance)
 - K-wire
- rehabilitation
 - sling immobilization for 6 weeks, no shoulder range of motion
 - return to full activity after 6 months

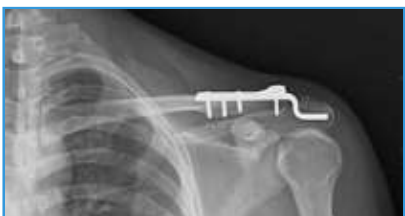• Techniques

○ **ORIF with CC screw fixation (Bosworth screw)**



- has fallen out of favor

- approach
- technique
 - screw placement from distal clavicle to coracoid, superior to inferior
- pros
 - rigid internal fixation
- cons
 - danger of screw being too long and damage to critical structure below coracoid
 - routine screw removal at 8-12 weeks is advised to prevent screw breakage
 - due to normal motion between clavicle and scapula
- complications
 - hardware irritation at level of screw purchase in coracoid
 - hardware failure at level of screw purchase in coracoid
- **ORIF with CC suture fixation**
 - approach
 - proximal aspect of anterolateral approach to the shoulder
 - technique
 - suture placed either around or through clavicle and around the base of the coracoid
 - can also use suture anchors for coracoid fixation
 - pros
 - no risk of hardware failure or migration
 - cons
 - suture not as strong as screw fixation
 - requires careful suture passage inferior to coracoid due to proximity of crucial neurovascular structures
 - complications
 - suture erosion causing distal third clavicle fracture
 - hardware irritation
- **ORIF with AC pin fixation (Phemister Technique)**
 - approach
 - can be done percutaneously
 - technique
 - smooth wire or pin fixation directly across AC joint
 - cons
 - hardware irritation
 - complications
 - high incidence of pin migration
 - generally not performed due to high complication rates
- **ORIF with AC hook plate fixation**

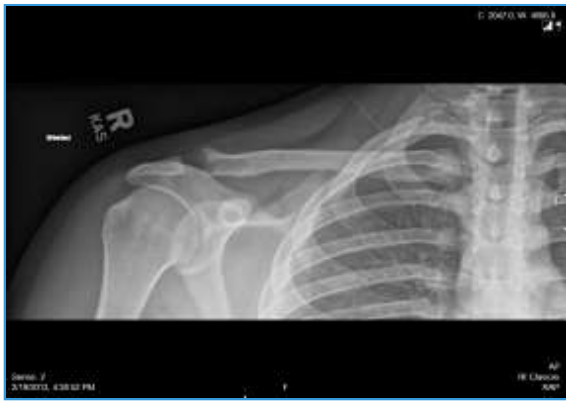

- approach
 - exposure of distal and middle clavicle
- technique
 - use of standard hook plate over superior distal clavicle
- pros
 - rigid fixation
- cons
 - may require second surgery for plate removal if symptomatic
- complications
 - acromial erosion
 - hook pullout
- **CC ligament reconstruction with coracoacromial (CA) ligament (Modified Weaver-Dunn)**
 - approach
 - arthroscopic technique also described
 - technique
 - distal clavicle excision
 - transfer of coracoacromial ligament to the distal clavicle to recreate CC ligament

- reinforce with internal fixation
- cons
 - coracoacromial ligament only 20% as strong as normal CC ligament
 - lack of internal fixation risks failure of soft tissue repair
- **CC ligament reconstruction with free tendon graft**
 - approach
 - can be performed arthroscopically-assisted
 - graft
 - autograft
 - palmaris longus
 - semitendinosus
 - allograft
 - tibialis anterior
 - technique
 - figure-of-eight passage of graft, looping around coracoid and fixation through clavicular tunnels
 - reinforce with internal fixation
 - pros
 - graft reconstruction more closely recreates strength of native CC ligament
 - cons
 - standard risks of allograft use or autograft harvest
 - lack of internal fixation risks failure of soft tissue repair
- **Complications**
 - Residual pain at AC joint
 - 30-50%
 - AC arthritis
 - more common with surgical management than with nonoperative treatment
 - Hardware failure
 - CC screw breakage/pullout
 - Coracoid fracture
 - can occur with coracoid tunnel drilling

12- Distal Clavicle Osteolysis

Images



• Summary

- Distal clavicle osteolysis is the painful development of bony erosions and resorption of the distal clavicle caused by repetitive trauma to the AC joint.
- Diagnosis is made with radiographs of the shoulder revealing osteolysis, cysts, erosions and resorption of the distal end of the clavicle.
- Treatment is a trial of NSAIDs, activity modifications, and corticosteroid injections. Arthroscopic versus open distal clavicle excision is indicated for patients with persistent symptoms that have failed nonoperative treatment.

• Epidemiology

- Demographics
 - patients in their 20s, mostly male
 - commonly seen in weightlifters
- Risk factors
 - history of traumatic injuries

• Etiology

- Pathophysiology
 - pathoanatomy
 - caused by repetitive stress and micro-fracture in distal clavicle which leads to osteopenia

• Anatomy

- Osteology
 - clavicle is
 - S-shaped bone
 - last bone to fuse
- Medial growth plate fuses early 20s
- Diarthrodial joint with fibrocartilage meniscus
- Ligamentous
 - AC ligaments: horizontal stability
 - CC ligaments: vertical stability

• Presentation

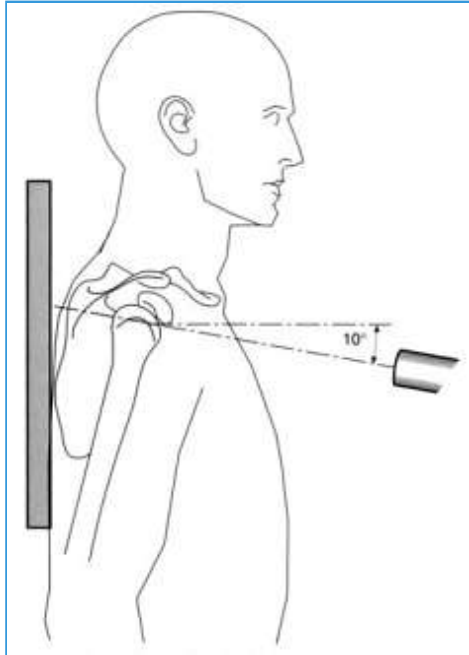
- Similar to AC joint arthritis
- Symptoms
 - pain
 - located at distal clavicle and anterior superior shoulder
 - insidious in onset
 - exacerbated by repetitive loading (ie. bench press or push-ups)
- Physical exam
 - palpation
 - tenderness at the distal end of clavicle and AC joint
 - provocative test

- pain with cross-body adduction

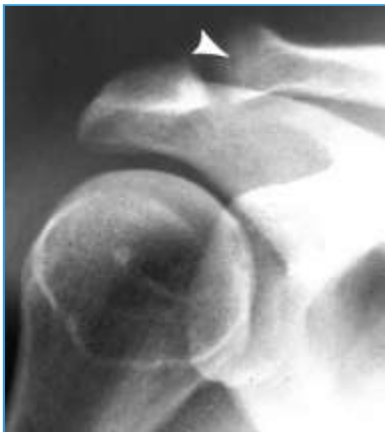
• Imaging

○ Radiographs

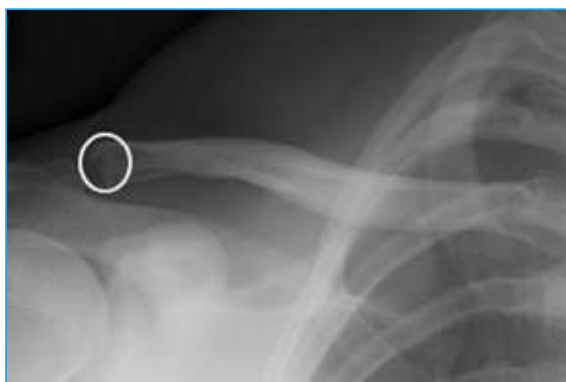- recommended views
 - AP clavicle
 - Zanca view (15 degrees cephalad tilt)



- findings of the distal clavicle (should not involve the acromion)



- cysts



- osteopenia
- resorption and erosion
- tapering of distal clavicle
- AC joint widening

○ Advanced Imaging

- MRI: increased signal of T2 sequences and bone marrow edema
- bone scan: increased uptake in the distal clavicle (may be seen earlier than radiographic changes)

• Treatment

○ Nonoperative

- **activity modification, NSAIDs**

- indications
 - first line of treatment
- modification
 - avoid aggravating weight-lifting exercises or modify technique
 - ie. moving hand grip closer together and ending weight descent to 4 to 6 cm above the chest

- **corticosteroid injections**

- indications
 - diagnostic and therapeutic
- technique

- more accurate with ultrasound

- Operative

- **open or arthroscopic distal clavicle excision**

- indications
 - persistent symptoms that have failed nonoperative treatment
- technique
 - need to address associated pathology to the rotator cuff and long head of biceps
- outcomes
 - open vs. arthroscopic based on surgeon preference and comfort
 - arthroscopic resection has the advantage of allowing evaluation of the glenohumeral joint
 - good results are shown with arthroscopic treatment
 - quicker recovery and return to activity
 - open procedures require meticulous repair of deltoid-trapezial fascia

- Techniques

- **Arthroscopic distal clavicle resection (Mumford procedure)**

- should resect only 0.5-1cm of the distal clavicle
- too large a resection can lead to AC joint instability

- Complications

- Horizontal instability

- avoid violating the posterosuperior capsule during distal clavicle excision as will lead to horizontal instability

13- Luxatio Erecta Inferior Glenohumeral Joint Dislocation

• summary

- Luxatio Erecta is the specific term for inferior dislocation of the glenohumeral joint trapped underneath the coracoid and glenoid, very commonly associated with neurovascular injury.
- Diagnosis is made clinically with the presence of the shoulder in a fixed, abducted position and confirmed with radiographs of the shoulder.
- Treatment is closed reduction and assessment of possible concomitant neurovascular injury.

• Epidemiology

- Incidence
 - very rare, only 0.5% of all shoulder dislocations

• Etiology

- Pathophysiology
 - pathoanatomy
 - typically a high-energy injury
 - hyperabduction force applied to arm, levering the proximal humerus onto the acromion, injuring inferior capsule/labrum, which subsequently allows for disengagement of HH inferiorly from glenoid
 - commonly involves variable sized tearing of static glenohumeral ligaments
- Associated conditions (common)
 - neurovascular injury
 - has greatest incidence of neurovascular injury of all types of shoulder dislocations
 - brachial plexopathy
 - axillary artery injuries
 - proximal humerus fractures
 - especially greater tuberosity
 - rotator cuff tears
 - anterior capsule and labral tears

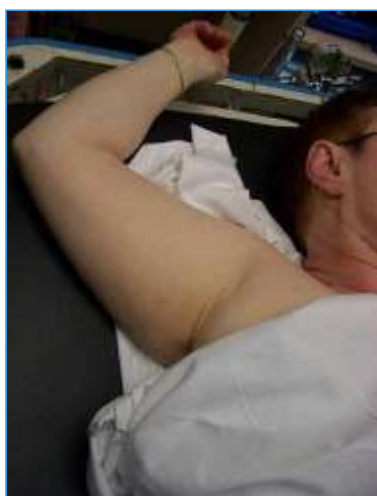• Anatomy

- Static glenohumeral ligaments
 - SGHL
 - restraint to inferior translation at 0° degrees of abduction (neutral rotation)
 - MGHL
 - resist anterior and posterior translation in the midrange of abduction (~45°) in ER
 - IGHL
 - posterior band IGHL
 - most important restraint to posterior subluxation at 90° flexion and IR
 - anterior band IGHL
 - primary restraint to anterior/inferior translation 90° abduction and maximum ER (late cocking phase of throwing)
 - superior band IGHL
 - most important static stabilizer about the joint
- See complete Glenohumeral anatomy

• Presentation

- Symptoms
 - shoulder pain
 - inability to move shoulder - arm is in fixed, abducted, overhead position
 - neurovascular injury
 - neurologic injury up to 60%
 - vascular injury up to 39%

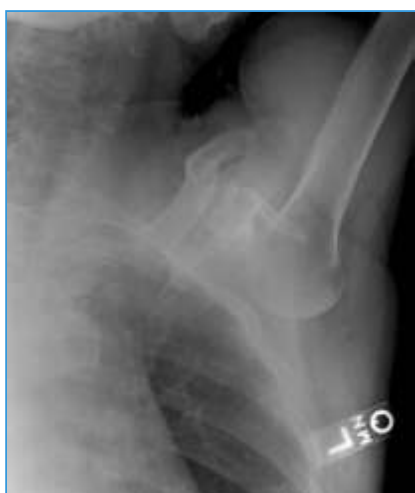- Physical exam
 - motion
 - patient presents with the arm in a fixed, abducted position



- neurovascular exam
 - assessment is important PRE and POST reduction
 - assess for radial and brachial pulse
 - assess neurologic exam including axillary nerve and distal neurologic exam
 - high rate of axillary nerve neuropraxia and brachial plexopathy

• Imaging

- Radiographs
 - recommended views
 - complete shoulder series
 - findings
 - inferior glenohumeral dislocation with arm fully abducted



- MRI
 - indications
 - should be obtained after shoulder is relocated given common occurrence of traumatic soft tissue injuries to the shoulder
 - findings
 - may show capsulolabral pathology
 - rotator cuff tears are extremely common

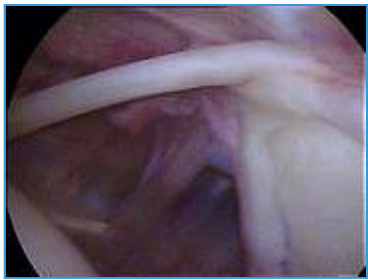• Treatment

- Nonoperative
 - **closed reduction and immobilization**
 - indications
 - inactive elderly patients
 - may be considered in the absence of acute traumatic rotator cuff tear
 - technique
 - traction-countertraction
 - similar technique as for anterior shoulder dislocations
 - two-step technique
 - converts inferior dislocation to anterior dislocation
 - clinician stands at patient's head, pushes laterally on humerus (one hand) while pulling superiorly on medial epicondyle (other hand), which should rotate HH from inferior to anterior around the glenoid rim
 - when successful, shoulder position will have changed from abduction to adduction against chest wall
 - then use any anterior-dislocation technique to reduce shoulder

- post-reduction
 - brief period of immobilizer
 - followed by ROM exercises assuming intact rotator cuff
 - physical therapy should focus on periscapular and rotator cuff strengthening
 - Operative
 - **arthroscopic or open repair**
 - indications
 - active younger patients
 - advantage of arthroscopic approach
 - allows assessment and addressing multiple concomitant pathologies including
 - capsulolabral damage
 - traumatic rotator cuff tear
 - prompt surgical repair for acute RTC tear typically recommended
 - prolonged non-operative treatment may result in significant retraction and rapid progression to nonrepairable condition
 - technique
 - repair vs reconstruction of shoulder pathology
- **Complications**
 - Axillary nerve palsy
 - most common nerve palsy
 - may resolve with reduction of shoulder
 - if persists - EMG may be warranted at 6-12 weeks postinjury for prognosis
 - Brachial plexopathy
 - high energy of injury and displacement of humeral head may result in significant brachial plexopathy
 - will usually resolve following reduction of shoulder and observation
 - Axillary artery thrombosis
 - may occur late
 - Rotator cuff tear
 - common, especially in older patients, but also in young patients as well
 - prompt MRI warranted in young patients following reduction to avoid missed diagnosis/ treatment

14- Multidirectional Shoulder Instability Mdi

Images



• summary

- Multidirectional shoulder instability (MDI) is a condition characterized by generalized instability of the shoulder in at least 2 planes of motion (anterior, posterior, or inferior) due to capsular redundancy.
- Diagnosis is made clinically with presence of increased anterior and posterior humeral translation, a sulcus sign, and overall increased external rotation.
- Treatment is a trial of prolonged physical therapy focusing on dynamic stabilization and periscapular muscle training. Arthroscopic stabilization with capsular shift is indicated for patients with persistent instability who fail an extensive course of physical therapy.

• Epidemiology

- Incidence
 - peaks in second and third decades of life

• Etiology

- Pathophysiology
 - mechanisms
 - underlying mechanism includes
 - microtrauma from overuse
 - seen with overhead throwing, volleyball players, swimmers, gymnasts
 - generalized ligamentous laxity
 - associated with connective tissue disorders: Ehlers-Danlos and Marfan's
 - pathoanatomy
 - hallmark findings of MDI
 - Imaging findings: patulous inferior capsule on MRI (IGHL anterior and posterior bands)
 - rotator interval deficiency
 - labral lesions or glenoid erosion can still occur from traumatic events
 - Bankart lesion is anteroinferior labral tear
 - Kim lesion is posteroinferior labral avulsion
 - MDI is also referred to as AMBRI
 - A traumatic
 - M ultidirectional
 - B ilateral (frequently)
 - R ehabilitation (often responds to)
 - I nferior capsular shift (best alternative to nonop)

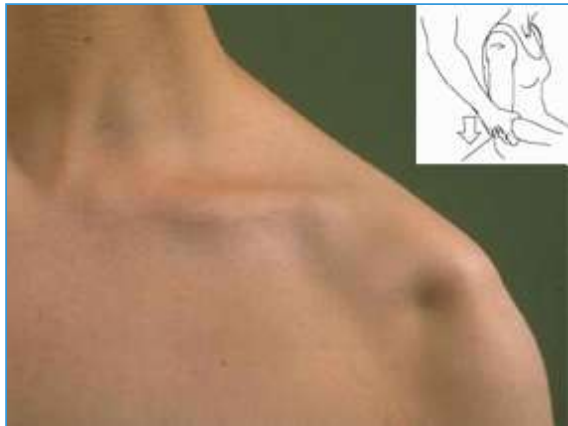• Anatomy

- Glenohumeral stability
 - static restraints
 - glenohumeral ligaments (below)
 - glenoid labrum (below)
 - articular congruity and version
 - negative intraarticular pressure
 - if release head will sublux inferiorly
 - dynamic restraints
 - rotator cuff muscles

- the primary biomechanical role of the rotator cuff is stabilizing the glenohumeral joint by compressing the humeral head against the glenoid
 - biceps
 - periscapular muscles
 - Complete Glenohumeral anatomy

• Presentation

- Symptoms
 - pain
 - instability
 - weakness
 - paresthesias
 - crepitus
 - shoulder instability during sleep
- Physical exam
 - Tests - must have instability in 2 or more planes (anterior, posterior, or inferior) to be defined as MDI
 - sulcus sign (2+ or more)



- assesses rotator interval
 - laxity of rotator interval presents as increased external rotation with the arm fully adducted and at 90 degrees abduction
 - apprehension/relocation test
 - anterior and posterior load and shift test (2+ or more)
 - Neer and Hawkins test
 - impingement or rotator cuff tendonitis in <20 year old signals possible MDI
 - signs of generalized hypermobility - generalized ligamentous laxity = Beighton's criteria >4/9
 - able to touch palms to floor while bending at waist (1 point)
 - genu recurvatum (2 points)
 - elbow hyperextension (2 points)
 - MCP hyperextension (2 points)
 - thumb abduction to the ipsilateral forearm (2 points)

• Imaging

- Radiographs
 - recommended views
 - a complete trauma series needed for evaluation (AP-IR, AP-ER, AP-True, Axillary, Scapular Y)
 - findings
 - may be normal in multidirectional instability
- MRI
 - indications
 - to fully evaluate shoulder anatomy
 - arthrogram needed to assess volume of capsule
 - findings
 - patulous inferior capsule (IGHL anterior and posterior bands)
 - Bankart lesion - may occur in conjunction with traumatic anterior instability
 - Kim lesion - may occur in conjunction with traumatic posterior instability
 - bony erosion of glenoid - following chronic anterior instability
- Arthroscopy
 - drive-through sign may be present

- a positive drive-through sign is considered the ability to pass an arthroscope easily between the humeral head and the glenoid at the level of the anterior band of the IGHL
- also associated with shoulder laxity

• Differential Diagnosis

- Anterior shoulder instability
- Posterior shoulder instability
- Cervical spine disease
- Brachial plexitis
- Thoracic outlet syndrome

• Treatment

- Nonoperative
 - **dynamic stabilization physical therapy**
 - indications
 - first line of treatment
 - vast majority of patients
 - technique
 - 3-6 month regimen needed
 - strengthening of dynamic stabilizers (rotator cuff and periscapular musculature)
 - closed kinetic chain exercises are used early in the rehabilitation process to safely stimulate co-contraction of the scapular and rotator cuff muscles
- Operative
 - **capsular shift / stabilization procedure (open or arthroscopic)**
 - indications
 - failure of extensive nonoperative management
 - pain and instability that interferes with ADLs of sports activities
 - contraindications
 - voluntary dislocators
 - capsular reconstruction (allograft)
 - rare, described in refractory cases and patients with collagen disorders

• Techniques

- **Capsular shift / stabilization procedure (open or arthroscopic)**
 - approach
 - arthroscopic approach to shoulder
 - deltopectoral approach for open
 - subscapularis tenotomy versus subscapularis split
 - stabilization
 - must address capsule +/- rotator interval
 - inferior capsular shift (capsule shifted superiorly)
 - plication of redundant capsule in a balanced fashion
 - rotator interval closure (open or arthroscopic)
 - produces the most significant decrease in range of motion in external rotation with the arm at the side
 - address any anterior or posterior labral pathology if present
 - thermal capsulorrhaphy (historical)
 - is contraindicated because of complications including capsular thinning/insufficiency and attenuation, and chondrolysis
 - post-operative rehabilitation
 - 4-6 weeks: shoulder immobilizer or sling
 - 6-10 weeks: ADL's with 45 degree limit on abduction and external rotation
 - 10-16 weeks: gradual range of motion
 - >16 weeks: strengthening
 - >10 months: contact sports
 - patient should resume sports activities only after normal strength and motion have returned

• Complications

- Subscapularis deficiency
 - more common after open anterior-inferior capsular shift
 - may be caused by injury or failed repair
 - postop physical exam will show a positive lift-off test and excessive external rotation
 - late finding - humeral head anterior subluxation on axillary radiograph
- Loss of motion
 - may be due to asymmetric tightening or overtightening of capsule
 - leads to loss of ER
 - treat with Z-lengthening of subscapularis
 - rare
- Axillary nerve injury
 - iatrogenic injury with surgery (abduction and ER moves axillary nerve away from glenoid)
 - usually a neuropraxia that can be observed postoperatively
 - can occur with anterior dislocation of shoulder
- Late arthritis (capsulorrhaphy induced arthritis)
 - usually wear of posterior glenoid with posterior humeral head subluxation and significant retroversion of the glenoid
 - may have internal rotation contracture (severe lack of external rotation on exam)
 - historically seen with Putti-Platt and Magnuson-Stack (non-anatomic, historical) procedures
- Recurrence
 - most common complication following arthroscopic or open capsulorrhaphy
 - high rate following thermal capsulorrhaphy (historical) due to capsular insufficiency
 - open revision indicated (not arthroscopic)

15- Traumatic Anterior Shoulder Instability Tubs

• summary

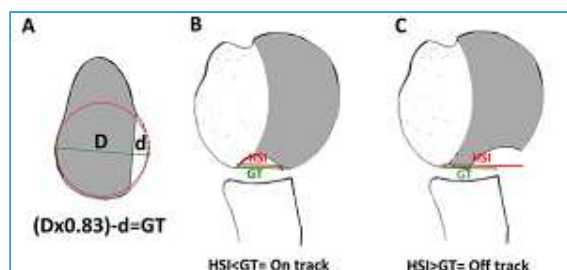
- Traumatic Anterior Shoulder Instability, also referred to as TUBS (**T**raumatic **U**nilateral dislocations with a **B**ankart lesion requiring **S**urgery), are traumatic shoulder injuries that generally occur as a result of an anterior force to the shoulder while its abducted and externally rotated and may lead to recurrent anterior shoulder instability.
- Diagnosis is made clinically with the presence of positive anterior instability provocative tests and confirmed with MRI studies that may reveal labral and/or bony injuries of the glenoid and proximal humerus (Hill-Sachs lesion).
- Treatment may be nonoperative or operative depending on the chronicity of symptoms, the presence of risk factors for recurrence, and the severity of labral and/or glenoid defects. In high-risk populations, surgery is often offered after a single dislocation event.

• Epidemiology

- Incidence
 - one of most common shoulder injuries
 - 1.7% annual rate in general population
- Demographics
 - have a high recurrence rate that correlates with age at dislocation
 - up to 80-90% in teenagers (90% chance for recurrence in age <20)
- Risk factors
 - markedly higher incidence in
 - military patients
 - contact athlete patients

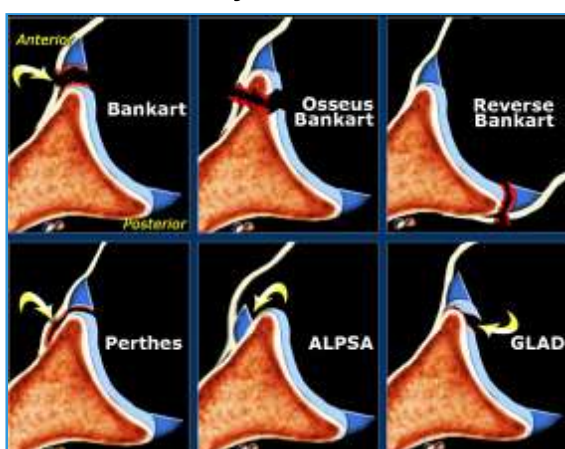
• Etiology

- Pathophysiology
 - mechanism of injury
 - anteriorly directed force on the arm when the shoulder is abducted and externally rotated
 - pathoanatomy
 - "on-track" versus "off-track" concept of Hill-Sachs lesion (instability as a bipolar concept)

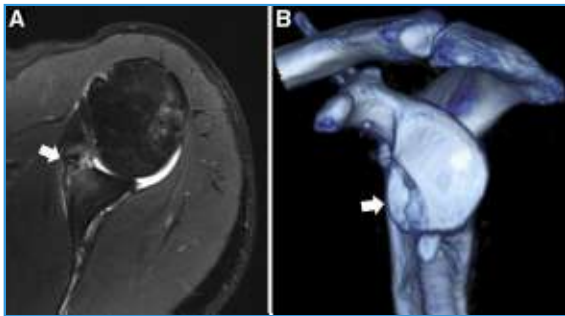
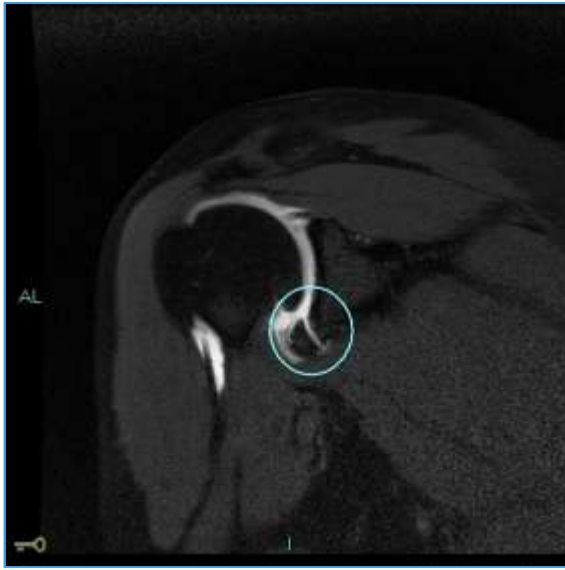


- Hill-Sachs defect is "off-track" and will "engage" on the glenoid if the size of the Hill-Sachs defect > glenoid articular track (HSI > GT)
- conversely, the Hill-Sachs defect is "on track" and will NOT "engage" if the size of the Hill-Sachs defect < glenoid articular track (HSI < GT)
- Glenoid Track (GT) = $0.83D - d$ (D = diameter of inferior glenoid, d = width of anterior glenoid bone loss)
- Hill-Sachs Interval (HSI) = HS+BB (HS = width of the Hill-Sachs, BB = width of bony bridge)
- may have implications regarding surgical management
 - goal is to convert on off-track lesion into an on-track lesion

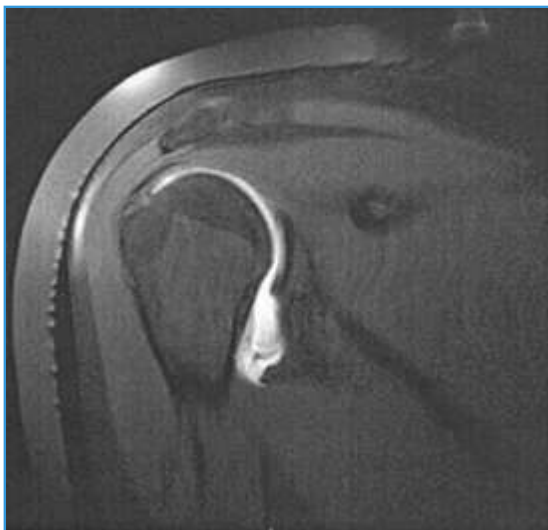○ Associated injuries



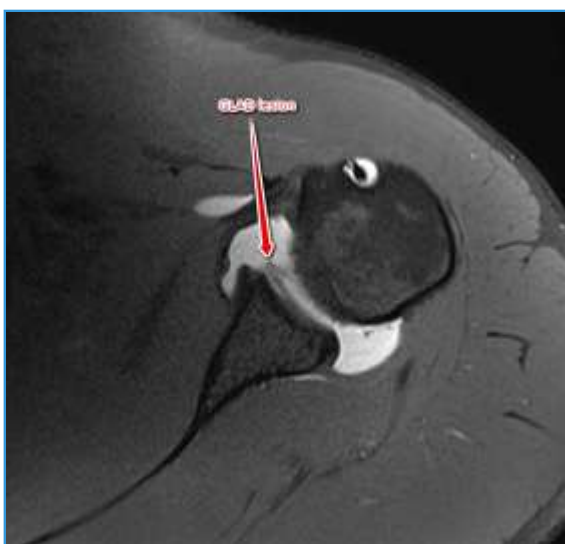
- orthopaedic
 - labrum & cartilage Injuries
 - bankart lesion



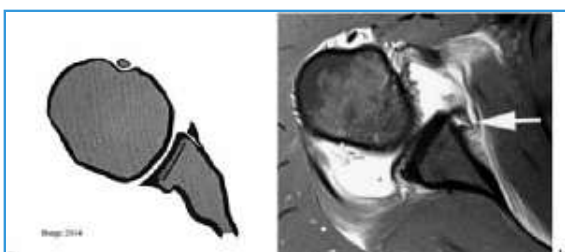- is an avulsion of the anterior labrum and anterior band of the IGHL from the anterior inferior glenoid.
- is present in 80-90% of patients with TUBS
- humeral avulsion of the glenohumeral ligament (HAGL)



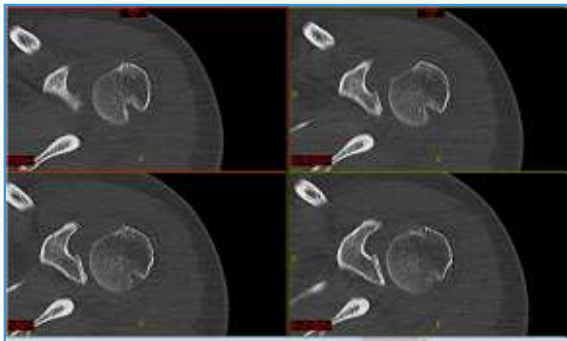
- occurs in patients slightly older than those with Bankart lesions
 - also found in female collegiate athletes
- associated with a higher recurrence rate if not recognized and repaired
- an indication for possible open surgical repair
- glenoid labral articular defect (GLAD)



- is a sheared off portion of articular cartilage along with the labrum
- presence is a risk factor for failure following arthroscopic stabilization procedures
- anterior labral periosteal sleeve avulsion (ALPSA)



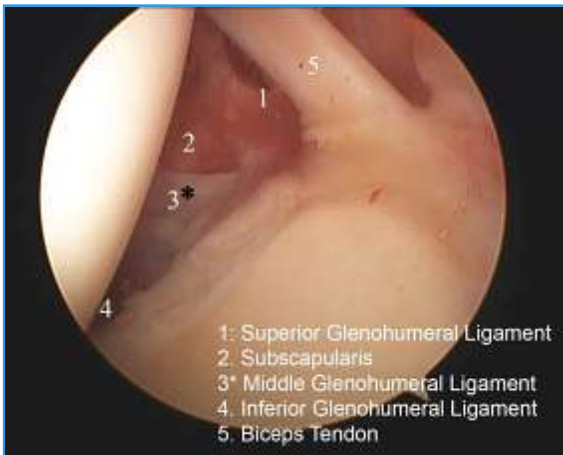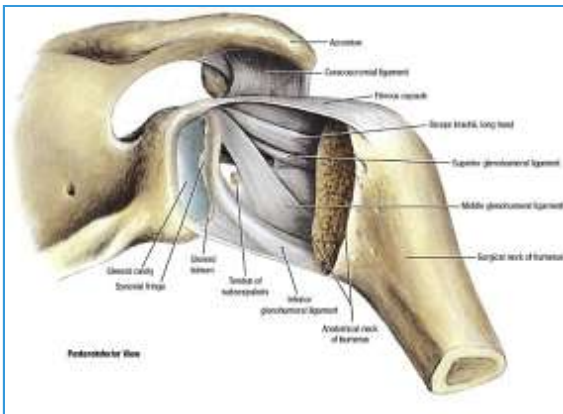
- can cause torn labrum to heal medially along the medial glenoid neck
 - associated with higher failure rates following arthroscopic repair
 - common finding in patients with recurrent instability managed nonoperatively
 - 97% of patients with recurrent instability have either a Bankart or ALPSA lesion
- fractures & bone Defects
 - bony bankart lesion
 - is a fracture of the anterior inferior glenoid
 - present in up to 49% of patients with recurrent dislocations
 - higher risk of failure of arthroscopic treatment if not addressed
 - defect >20-25% is considered "critical bone loss" and is biomechanically highly unstable
 - stability cannot be restored with soft tissue stabilization alone (unacceptable >2/3 failure rate)
 - requires bony procedure to restore bone loss (Latarjet-Bristow, other sources of autograft or allograft)
 - recent studies suggest critical bone loss may be as low as 13.5%
 - each dislocation event causes, on average, 6.8% bone loss
 - glenoid takes on an inverted-pear appearance as bone loss increases
 - 89% failure rate following arthroscopic repair in patients with this glenoid morphology



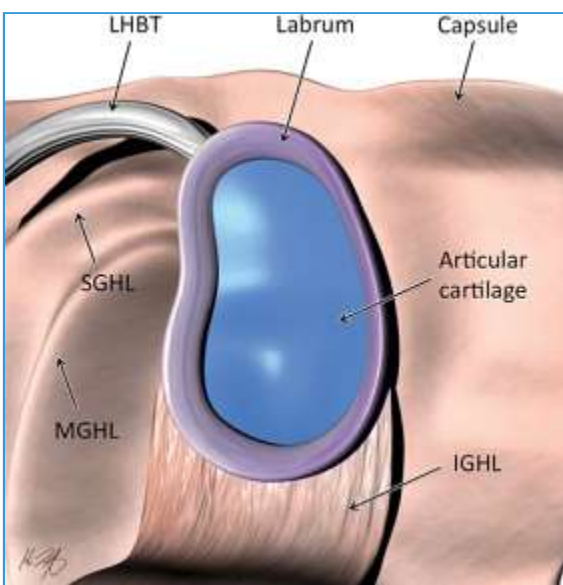
- is a chondral impaction injury in the posterosuperior humeral head secondary to contact with the glenoid rim.
 - is present in 80%-100% of traumatic dislocations and 25% of traumatic subluxations
 - is not clinically significant unless it engages the glenoid
- greater tuberosity fracture
 - is associated with anterior dislocation in patients > 50 years of age
 - increases risk of recurrence
- lesser tuberosity fracture
 - is associated with posterior dislocations
- nerve injuries
 - axillary nerve injury
 - is most often a transient neurapraxia of the axillary nerve
 - present in up to 5% of patients
- rotator cuff tears
 - 30% of TUBS patients > 40 years of age
 - 80% of TUBS patients > 60 years of age
- medical
 - global hyperlaxity (i.e. Ehlers-Danlos Syndrome, collagen disorders)
 - often associated with atraumatic instability
 - global hyperlaxity confers an odds ratio (OR) of 2.68 for the development of anterior shoulder instability
 - individuals with global hyperlaxity have a 3x higher rate of recurrent instability
 - patients with global hyperlaxity are less likely to develop capsulolabral lesions

• Anatomy

- Glenohumeral anatomy
- Static restraints
 - bony anatomy
 - capsule
 - glenohumeral ligaments



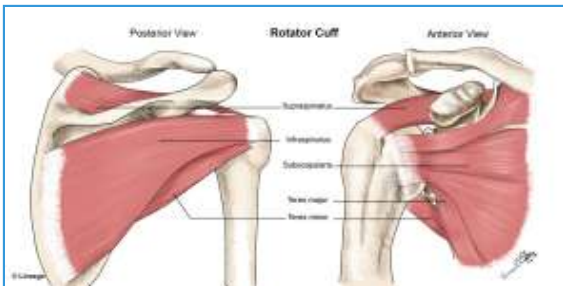■ labrum



- labrum contributes 50% of additional glenoid depth

○ Dynamic restraints

- rotator cuff muscles



- long head of biceps tendon

○ Anterior static shoulder stability is provided by

- Anterior band of IGHL (main restraint)
 - provides static restraint with arm in 90° of abduction and external rotation
- MGHL
 - provides static restraint with arm in 45° of abduction and external rotation
- SGHL
 - provides static restraint with arm at the side

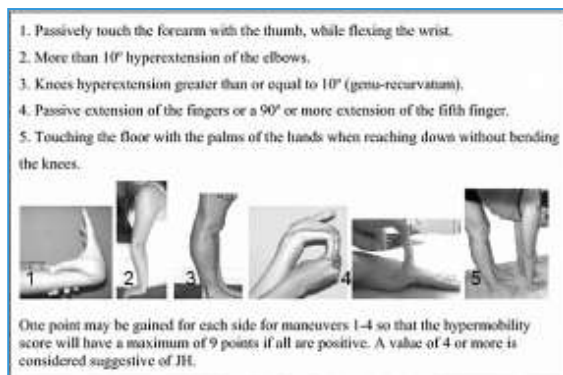
• Classification

○	■ Anteroposterior Translation Grading Scheme	
	■ Grade 0	■ Normal glenohumeral translation
	■ Grade 1+	■ Humeral head translation up to glenoid rim
	■ Grade 2+	■ Humeral head translation over glenoid rim with spontaneous reduction once force withdrawn
	■ Grade 3+	■ Humeral head translation over glenoid rim without spontaneous reduction

<ul style="list-style-type: none"> ■ Sulcus Test Grading Scheme 		
<ul style="list-style-type: none"> ■ Grade 1 	<ul style="list-style-type: none"> ■ Acromiohumeral interval < 1cm 	<ul style="list-style-type: none"> ■
<ul style="list-style-type: none"> ■ Grade 2 	<ul style="list-style-type: none"> ■ Acromiohumeral interval 1-2 cm 	<ul style="list-style-type: none"> ■
<ul style="list-style-type: none"> ■ Grade 3 	<ul style="list-style-type: none"> ■ Acromiohumeral interval > 2cm 	<ul style="list-style-type: none"> ■
<ul style="list-style-type: none"> ■ Instability Severity Score 		
<ul style="list-style-type: none"> ■ <i>Variable</i> 	<ul style="list-style-type: none"> ■ <i>Parameter</i> 	<ul style="list-style-type: none"> ■ <i>Score</i>
<ul style="list-style-type: none"> ■ Age 	<ul style="list-style-type: none"> ■ < 20 years ■ > 20 years 	<ul style="list-style-type: none"> ■ 2 ■ 0
<ul style="list-style-type: none"> ■ Degree of sports participation 	<ul style="list-style-type: none"> ■ Competitive ■ Recreational/none 	<ul style="list-style-type: none"> ■ 2 ■ 0
<ul style="list-style-type: none"> ■ Type of sport participation 	<ul style="list-style-type: none"> ■ Contact/forced overhead ■ Other 	<ul style="list-style-type: none"> ■ 1 ■ 0
<ul style="list-style-type: none"> ■ Shoulder Hyperlaxity 	<ul style="list-style-type: none"> ■ Hyperlaxity (anterior/inferior) ■ Normal 	<ul style="list-style-type: none"> ■ 1 ■ 0
<ul style="list-style-type: none"> ■ Hill sachs on AP x-ray 	<ul style="list-style-type: none"> ■ Visible on external rotation ■ Not visible on external rotation 	<ul style="list-style-type: none"> ■ 2 ■ 0
<ul style="list-style-type: none"> ■ Glenoid contour loss on AP x-ray 	<ul style="list-style-type: none"> ■ Loss of contour ■ No lesions 	<ul style="list-style-type: none"> ■ 2 ■ 0
<ul style="list-style-type: none"> ■ 	<ul style="list-style-type: none"> ■ Clinical Implications 	<ul style="list-style-type: none"> ■ Total Possible = 10
<ul style="list-style-type: none"> ■ 	<ul style="list-style-type: none"> ■ An acceptable recurrence risk of 10% with arthroscopic stabilization. 	<ul style="list-style-type: none"> ■ < 6 points
<ul style="list-style-type: none"> ■ 	<ul style="list-style-type: none"> ■ A score of > 6 points has an unacceptable recurrence risk of 70% and should be advised to undergo open surgery (i.e. Laterjet procedure). 	<ul style="list-style-type: none"> ■ > 6 points

- Presentation

- History
 - patients often recount a traumatic event leading to a dislocation
 - important to clarify whether patient needed a formal reduction, or if they spontaneously reduced
- Symptoms
 - traumatic event causing dislocation
 - feeling of instability
 - shoulder pain complaints
 - caused by subluxation and excessive translation of the humeral head on the glenoid
- Physical exam
 - load and shift
 - Grade 0 - normal glenohumeral translation
 - Grade I - translation to the glenoid rim, without dislocation
 - Grade II - shifts over glenoid rim, spontaneously reduces
 - Grade III - shifts over glenoid rim, does not spontaneously reduce
 - apprehension sign
 - patient supine with arm 90 degrees abducted and 90 degrees externally rotated
 - positive when patients experiences apprehension
 - positive sign in mid-ranges of abduction is highly suggestive of concomitant glenoid bone loss
 - relocation sign
 - decrease in apprehension with anterior force applied on shoulder during apprehension testing
 - sulcus sign
 - tested with patient's arm at side
 - generalized ligamentous laxity
 - increased risk of recurrent instability in patients with hyperlaxity
 - assess via Beighton's criteria (score > 4)



- shoulder specific laxity defined as
 - hyperexternal rotation at side > 85 degrees
 - hyperabduction > 105 degrees (Gagey's maneuver)
 - OR > 2+ load shift in 2 or more planes (anterior, posterior, inferior)

• Imaging

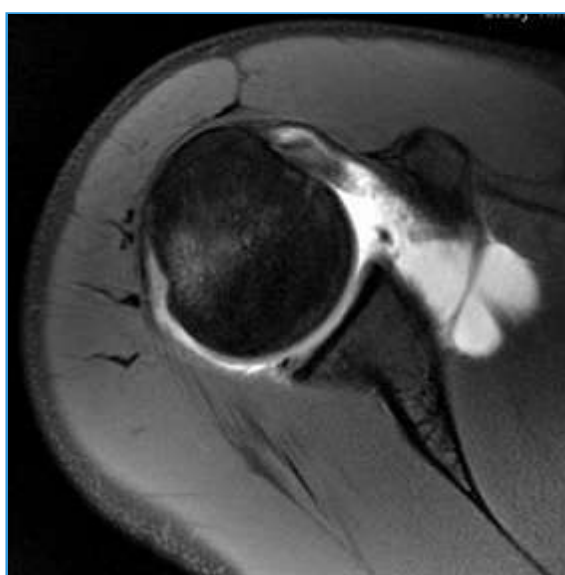
○ Radiographs

- see imaging of shoulder
- recommended views
 - a complete trauma series needed for evaluation
 - true AP
 - scapular Y
 - axillary
- optional views
 - West Point view
 - shows glenoid bone loss
 - Stryker view
 - shows Hill-Sachs lesion

○ CT scan +/- arthrogram

- indications
 - helpful for evaluation of bony injuries and calculation of glenoid bone loss
 - arthrogram usually reserved for patients who are unable to undergo MRI i.e. patients with pacemakers and/or cochlear implants
- due to limited soft-tissue contrast, CT arthrogram not as effective at visualizing internal soft-tissue derangements as MR arthrogram

○ MRI



- indications
 - best for visualization of labral tear
 - has been validated as an imaging modality through which to assess bone loss

○ MR Arthrogram

- increases sensitivity and specificity (86-91% and 86-96%) for detecting soft-tissue injuries when compared to conventional MRI (44-100% and 66-95%)

• Treatment

○ Nonoperative

- **acute reduction, ± immobilization, followed by therapy**
 - indications
 - management of first-time dislocators remains controversial

- current ASES recommendations are for surgical intervention for athletes aged 14 to 30 at the end of their competitive season if they have positive apprehension testing and bone loss
- reduction
 - simple traction-countertraction is most commonly used
 - other reduction techniques include:
 - Kocher: arm at side in external rotation is forward-flexed and then internally rotated
 - Hippocratic: traction against a heel placed in the patients axilla
 - Stimson's: weight is hung from the affected arm of a patient in the prone position
- immobilization
 - studies have not shown any benefit of immobilization > 1 week for decreasing recurrence rates
 - some studies show immobilization in external rotation decreases recurrence rates in patients < 40
 - thought to reduce the anterior labrum to the glenoid leading to more anatomic healing
 - subsequent studies have refuted this finding and the initially published results have not been reproducible
- physical therapy
 - strengthening of dynamic stabilizers (rotator cuff and periscapular musculature)
- outcomes
 - goal is return to sport within 7 to 21 days
 - military and overhead and/or contact athletes experience an unacceptably high rate of recurrent instability
 - risk factors for re-dislocation are
 - age < 20 (highest risk)
 - male
 - contact sports
 - hyperlaxity
 - glenoid bone loss >20-25%
 - greater tuberosity fractures
- Operative
 - **Arthroscopic Bankart repair +/- capsular plication**
 - indications
 - relative indications
 - first-time traumatic shoulder dislocation with Bankart lesion confirmed by MRI in athlete younger than 25 years of age
 - high demand athletes
 - recurrent dislocation/subluxation (> one dislocation) following nonoperative management
 - < 20-25% glenoid bone loss
 - remplissage augmentation with arthroscopic Bankart may be considered if Hills-Sachs "off-track"
 - techniques
 - at least three (preferably four) anchor points shoulder be used
 - paramount that labrum is fully mobilized prior to repair
 - outcomes
 - results now equally efficacious as open repair with the advantage of less pain and greater motion preservation
 - increased failure rates seen in patients with global hyperlaxity, glenoid bone loss, or too few fixation points
 - too many anchors does pose a risk for fracture through the anchor holes (postage stamp fracture)
 - **Open Bankart repair +/- capsular shift**
 - indications
 - Bankart lesion with glenoid bone loss < 20-25%
 - revision stabilization following failed arthroscopic Bankart repair without glenoid bone loss >20%
 - can be considered when there is a concomitant acute glenoid fracture, or if the patient is hyperlax and requires a formal capsular shift during the same procedure
 - humeral avulsion of the glenohumeral ligament (HAGL)
 - can also be performed arthroscopically but is technically challenging
 - technique
 - generally accessed through a deltopectoral approach
 - can fix bony bankart with screws or suture in a linear or bridge technique
 - outcomes
 - results are equivalent to arthroscopic repair, although patients have more pain and less range of motion postoperatively
 - patients with greater than 13.5% glenoid bone loss have higher rates of recurrent instability

- **Latarjet (coracoid transfer) or Bristow Procedure**
 - indications
 - chronic bony deficiencies with >20-25% glenoid deficiency (inverted pear deformity to glenoid)
 - in the setting of glenoid bone loss, excessive stress is transferred to labrum and attenuated anterior soft tissues, increasing the risk of failure of labral repair alone
 - transfer of coracoid bone with attached conjoined tendon and CA ligament
 - Latarjet procedure performed more commonly than Bristow
 - Latarjet triple effect = bony (increases glenoid track), sling (conjoined tendon on top of subscapularis), capsule reconstruction (CA ligament)
 - technique
 - deltopectoral approach
 - subscapularis is split
 - outcomes
 - over recurrent instability rate ranges from 0% to 8%
 - good to excellent outcomes are seen in over 90% of patients
- **Autograft (tricortical iliac crest or distal clavicle) or allograft (iliac crest or distal tibia)**
 - indications
 - bony deficiencies with >20-25% glenoid deficiency (inverted pear deformity to glenoid)
 - revision of failed Latarjet
 - technique
 - can be performed arthroscopic or open
 - distal tibia gaining popularity since graft is a true osteochondral graft
 - outcomes
 - 89% healing rate at a mean of 1.4 years
- **Remplissage + Bankart Repair**
 - indication
 - engaging large (>25-40%) Hill-Sachs defect
 - "off-track" Hill-Sachs lesions with <20-25% glenoid bone loss
 - technique
 - posterior capsule and infraspinatus tendon sutured into the Hill-Sachs lesion
 - may be performed with concomitant Bankart repair
 - by decreasing size of Hill-Sachs, converts on off-track lesion into an on-track lesion
 - outcomes
 - when compared to Latarjet with 2-year outcomes, remplissage + bankart had lower recurrent instability rates (1.4% vs. 3.2%) despite greater bipolar bone loss
- **Bone graft reconstruction for Hill Sachs defects**
 - indication
 - engaging large (>40%) Hill-Sachs lesions
 - technique
 - allograft reconstruction
 - arthroplasty
 - rotational osteotomy
 - outcomes
- **Tendon transfers**
 - indication
 - chronic, irreparable subscapularis tear
 - technique
 - latissimus dorsi
 - may better replicate line of pull of native subscapularis
 - pectoralis major - sternal head
 - outcomes
- **Historical procedures: Putti-Platt / Magnuson-Stack / Boyd-Sisk**
 - indications
 - led to over-constraint and arthrosis
 - technique
 - goal is to tighten subscapularis
 - Putti-Platt is performed by lateral advancement of subscapularis and medial advancement of the shoulder capsule

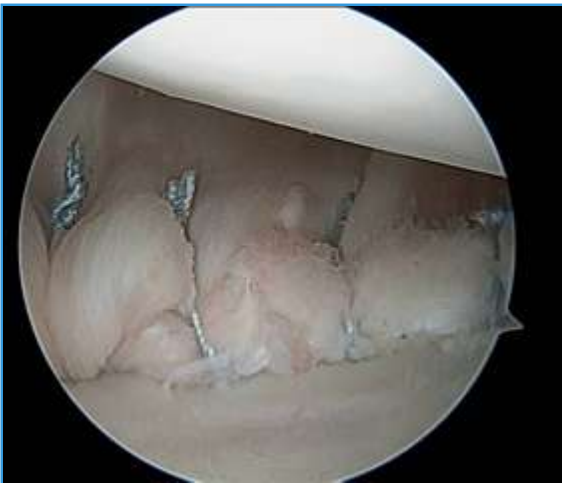- Magnuson-Stack is performed with lateral advancement of subscapularis (lateral to bicipital groove and at times to greater tuberosity)
- Boyd-Sisk is transfer of biceps laterally and posteriorly
- outcomes
 - high rate of post-operative stiffness and subsequent osteoarthritis
 - typical presentation of open procedure performed in 1970s-80s, now with presenting complaint of pain and stiffness from glenohumeral OA, especially lack of ER, and significant posterior glenoid wear and retroversion
 - high rate of recurrent instability with Boyd-Sisk

• Techniques

○ Acute Reduction +/- Immobilization followed by physical therapy

- indications
 - acute dislocations presenting to the emergency departments
- techniques
 - relaxation of patient with sedation or intraarticular lidocaine is essential
 - various methods for reduction exist
 - scapular manipulation
 - Kocher
 - Stimson
- pros/cons
 - timely reduction can help to stave the development of further bone loss or joint contractures
- complications
 - unsuccessful in 5-10% of cases
 - biceps tendon, joint capsule, fracture fragments most common blocks to reduction
 - nerve injury
 - axillary nerve if excessive traction is utilized
 - recurrent instability
 - risk factors include young patient age, bone loss, contact sport participation, global hyperlaxity

○ Arthroscopic Bankart Repair + Capsular plication



- indications
 - recurrent anterior instability
 - anterior instability in young athletes
 - current trend is towards surgical management after first-time dislocation event, as recurrent instability is associated with greater degrees of glenoid bone loss, which may preclude arthroscopic stabilization
- approach
 - shoulder arthroscopic approach
- technique
 - drive through sign might be present prior to labral repair and capsulorrhaphy
 - studies support use of > 3 anchors (< 4 anchors is a risk factor for failure)
- complications
 - recurrence, most often due to unrecognized glenoid bone loss or lack of concomitantly addressing "off-track" HS lesion
 - stiffness, especially in external rotation, further loss of ER may occur with the addition of remplissage
 - over-tightening increases the risk of post-capsulorrhaphy arthropathy, especially in older patients
 - axillary nerve injury
 - axillary nerve is on average 12mm from infra-glenoid tubercle
 - chondrolysis (from use of thermal capsulorrhaphy which is no longer used)
- Open Bankart repair +/- capsular shift

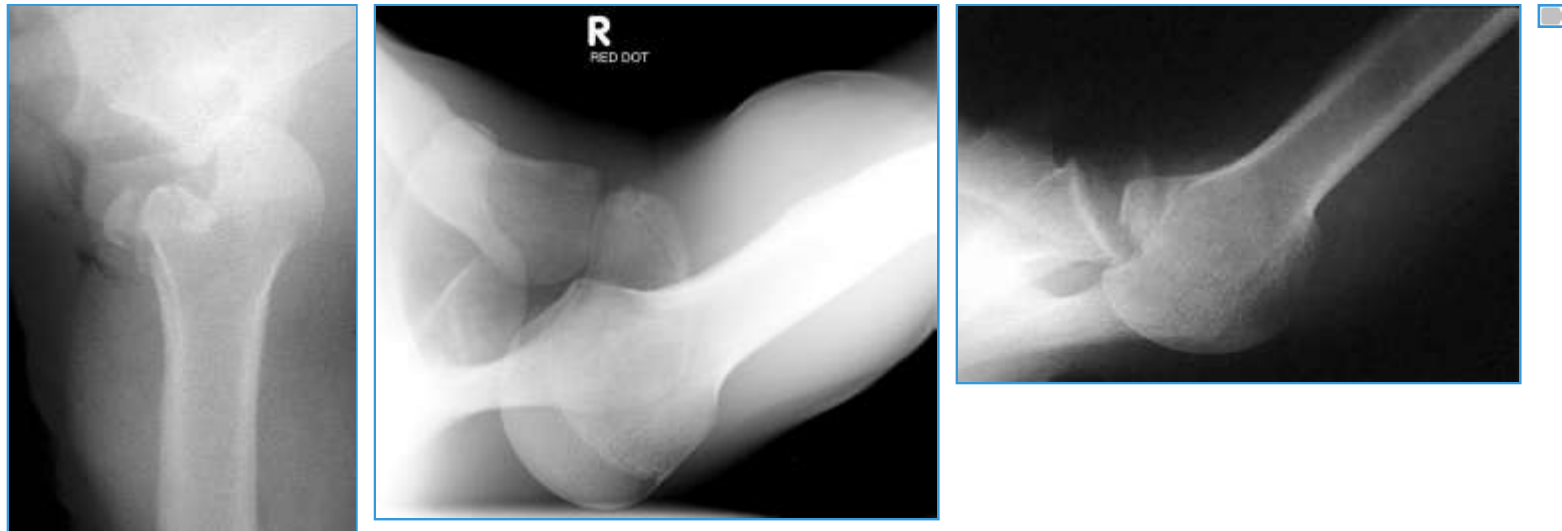
- indications
 - often employed in the setting of failed arthroscopic stabilization
 - some surgeons prefer an open procedure if the patient is found to have a HAGL lesion
- approach
 - shoulder anterior (deltopectoral) approach
- technique
 - subscapularis transverse split or tenotomy
 - open labral repair and capsulorrhaphy
 - capsular shift
 - inferior capsule is shifted superiorly
- complications
 - recurrence
 - most often due to unrecognized glenoid bone loss
 - subscapularis injury or failed repair
 - post-operative physical exam will show a positive lift off and excessive ER
 - stiffness
 - caused by overtightening of capsule
 - leads to loss of external rotation
 - treat with Z lengthening of subscapularis
 - axillary nerve injury
 - iatrogenic injury with surgery (avoid by abduction and ER of arm during procedure)
 - arthritis
 - usually wear of posterior glenoid
 - may have internal rotation contracture
 - seen with Putti-Platt and Magnuson-Stack procedures
- **Latarjet or Bristow Procedure**
 - indications
 - indications vary based on geographic region
 - European surgeons aggressively employ the Latarjet
 - young, high-demand contact athletes or athletes of consequence (mountain climbers, big wave surfers)
 - recurrent anterior instability with critical (>20-25%) or subcritical (>13.5%) bone loss
 - patients at high-risk of failure with soft-tissue procedures alone (ISIS > 4-6 points)
 - approach
 - shoulder anterior (deltopectoral) approach
 - can be performed arthroscopically
 - technique
 - coracoid transfer to anterior inferior glenoid bone defect
 - traditional or congruent arc technique for coracoid graft placement
 - after harvest, coracoid is passed through a split in the distal 1/3 or middle 1/2 subscapularis
 - traditional versus congruent arc technique
 - in the congruent arc technique, the undersurface of the coracoid ends up articulating with the humeral head
 - graft can be placed intraarticularly (capsular repaired to CA ligament stump) or extraarticularly (capsule repaired to native glenoid rim)
 - concerns exist for increased rates of subsequent osteoarthritis with intraarticular placement, although this isn't fully supported by high-quality literature
 - no difference in outcomes between open and arthroscopic procedures, although literature has identified a profound learning curve for the arthroscopic Latarjet
 - complications
 - generally higher than arthroscopic or open Bankart, some studies report up to 25% incidence of complications
 - nonunion
 - graft lysis
 - up to 90% of patients undergo some degree of resorption within the first six months
 - hardware problems
 - stiffness, particularly in external rotation
 - glenohumeral osteoarthritis
 - will rapidly occur with lateral overhang of graft into the joint space
 - occurs in up to 38% of patients
 - nerve injury

- majority are traction or contusion neuropraxias and resolve spontaneously
 - treat with observation for 3-6 weeks; delayed EMG if deficits persist
 - musculocutaneous nerve
 - occurs during instrumentation around the conjoint tendon
 - pierces conjoint tendon, on average, 5.6 cm distally to the tip of the coracoid
 - axillary nerve
 - occurs during graft fixation
 - located, on average, 12mm from infra-glenoid tubercle
- **Autograft (tricortical iliac crest or distal clavicle) or allograft (iliac crest or distal tibia)**
 - indications
 - area of research
 - ideal patient for Latarjet versus bone block is yet to be identified
 - indications similar to those of Latarjet
 - critical or subcritical glenoid bone loss
 - patients at high risk of failure with soft-tissue procedures alone
 - loss graft resorption overall when compared to Latarjet
 - can be used to revise a failed Latarjet
 - some surgeons recommended use of Bovie electrocautery or checkpoint during dissection to ensure that musculocutaneous nerve is not inadvertently injured
 - approach
 - shoulder anterior (deltopectoral) approach
 - arthroscopic
 - technique
 - can use autograft of allograft iliac crest, allograft glenoid or allograft distal tibia
 - can secure with screws or buttons
 - complications
 - hardware failure
 - subscapularis repair failure
- **Remplissage + Bankart Repair**
 - indications
 - medium to large engaging/off-track Hill-Sachs lesion
 - some surgeons have begun using remplissage in the setting of subcritical bone loss, as in these patients rates of recurrent instability following arthroscopic management alone approaches 20%
 - approach
 - arthroscopic
 - percutaneous
 - additional posterolateral portal made under visualization
 - technique
 - goal is to fill Hill-Sachs with capsule and infraspinatus tendon
 - can use knotted or knotless configurations
 - most surgeons recommend passing sutures prior to anterior labral repair, and then tying once anterior labral repair is complete
 - new knotless anchors allow for passage and construction of a "double-pulley" configuration, with final tensioning completed after additional intraarticular work
 - complications
 - stiffness, specifically loss of external rotation
 - most patients lose 5-15° of external rotation
 - recurrence
 - 5% at two years
- **Bone graft reconstruction for Hill-Sachs defects**
 - indications
 - large Hill-Sachs (>40% of articular surface)
 - approach
 - open
 - anterolateral
 - deltopectoral
 - arthroscopic
 - technique

- autograft iliac crest
 - allograft (humeral head, talus, femoral head)
 - fresh-frozen osteochondral allograft
- complications
 - graft lysis
 - disease transmission from allograft
 - osteoarthritis
- **Historical procedures: Putti-Platt / Magnuson-Stack / Boyd-Sisk**
 - indications
 - historically indicated for recurrent instability
 - rarely indicated now
 - approach
 - open anterior (deltopectoral) approach
 - technique
 - Putti-Platt is performed by lateral advancement of subscapularis and medial advancement of the shoulder capsule
 - Magnuson-Stack is performed with lateral advancement of subscapularis (lateral to bicipital groove and at times to greater tuberosity)
 - Boyd-Sisk transfer of biceps laterally and posteriorly
 - outcomes
 - Putti-Platt and Magnuson-Stack both lead to decreased external rotation and increased loading on the posterior glenoid, which can lead to post-capsulorrhaphy arthropathy
- **Complications**
 - Recurrence
 - often due to unrecognized glenoid bone loss treated with a soft tissue only procedure (especially with glenoid bone loss >20-25%)
 - can be due to poor surgical technique (ie, < 4 suture anchors)
 - increased risk with preoperative risk factors including age < 20, male sex, contact/collision sport, ligamentous laxity, and unrecognized glenoid and/or humeral head bone loss (critical bone loss or "off-track" lesion)
 - medical management should be exhausted prior to surgery in patients with seizures, as there is a high recurrence risk even when bony augmentation techniques are used
 - unrecognized pan-labral tear
 - high incidence of posterior and/or combined front-to-back tears in the military population
 - Shoulder pain
 - overtightening during labral repair can lead to post-capsulorrhaphy arthropathy
 - Nerve injury
 - musculocutaneous (most common)
 - axillary
 - Stiffness
 - especially in external rotation (particularly with Latarjet and additional remplissage)
 - Infection
 - Graft lysis (Latarjet)
 - present in up to 90% of patients at six-months
 - Hardware complications
 - anchor pull-out (Bankart repair)
 - screw pull-out (Latarjet)
 - Chondrolysis
 - historically due to use of thermal capsulorrhaphy (now contraindicated) or intra-articular pain pumps (now contraindicated)

16- Posterior Shoulder Instability And Dislocation

Images



• Summary

- Posterior shoulder instability and dislocations are less common than anterior shoulder instability and dislocations, but are much more commonly missed.
- Diagnosis is made radiographically in the setting of acute dislocations. Chronic instability can be diagnosed with presence of positive posterior instability provocative tests and confirmed with MRI studies showing posterior labral pathology.
- Treatment may be nonoperative or operative depending on chronicity of symptoms, recurrence of instability, and the severity of labrum and/or glenoid defects.

• Epidemiology

- Incidence
 - 2% to 5% of all unstable shoulders
 - 50% of traumatic posterior dislocations seen in the emergency department are undiagnosed
- Risk factors
 - bony abnormality
 - glenoid retroversion or hypoplasia is a less common cause of instability
 - ligamentous laxity

• Etiology

- Pathophysiology
 - mechanism
 - trauma (posterior dislocation)
 - 50% of cases that present for evaluation
 - usually dramatic presentation
 - microtrauma (posterior instability)
 - may lead to a labral tear, incomplete labral avulsion, or erosion of the posterior labrum
 - may lead to gradual stretching of capsule and patulous posterior capsule
 - common in lineman, weight lifters, overhead athletes
 - usually insidious onset and presentation
 - seizures and electric shock
 - tetanic muscle contraction pulls the humeral head out
 - anterior instability and dislocations are still more common with seizures
 - however, posterior dislocations are unlikely to occur without significant trauma (ie. seizures)
 - biomechanical forces
 - flexed, adducted, and internally rotated arm is a high-risk position
- Associated conditions
 - see table below

<ul style="list-style-type: none"> Lesions Associated with Posterior Instability 	
<ul style="list-style-type: none"> Avulsion of posterior band of IGHL 	<ul style="list-style-type: none"> Associated with acute subluxations
<ul style="list-style-type: none"> Posterior Bankart lesions 	<ul style="list-style-type: none"> Characterized by detachment of posterior inferior capsulolabral complex
<ul style="list-style-type: none"> Reverse Hill-Sachs lesions 	<ul style="list-style-type: none"> Associated with locked and difficult to reduce dislocations
<ul style="list-style-type: none"> Posterior labral cyst 	<ul style="list-style-type: none"> Associated with chronic reverse Bankart lesion
<ul style="list-style-type: none"> Posterior glenoid rim fracture 	<ul style="list-style-type: none"> Associated with chronic reverse Bankart lesion
<ul style="list-style-type: none"> Lesser tuberosity fracture 	<ul style="list-style-type: none"> Associated with acute posterior dislocation
<ul style="list-style-type: none"> Large capsular pouch 	<ul style="list-style-type: none"> Can see with MRI with contrast, often with chronic posterior instability

• Anatomy

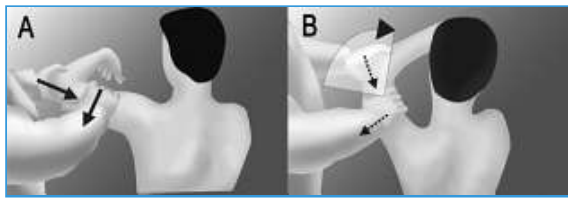
- Glenohumeral anatomy
- Primary stabilizers of the posterior shoulder
 - posterior band of IGHL
 - primary restraint in internal rotation
 - subscapularis
 - primary dynamic restraint in external rotation
 - primary dynamic restraint against posterior subluxation
 - superior glenohumeral ligament and coracohumeral ligament
 - primary restraint to inferior translation of the adducted arm and to external rotation
 - primary static stabilizer to posterior subluxation with shoulder in flexion, adduction, and internal rotation
- Static restraint
 - labrum deepens the glenoid by 50%

• Classification

- Acute versus chronic
 - Acute = trauma, seizure, electric shock with dramatic presentation
 - Chronic = microtrauma from repetition such as offense football lineman with insidious onset and presentation
- Voluntary versus involuntary

• Presentation

- History
 - trauma or microtrauma with the arm in a flexed, adducted, and internally rotated position
 - chronic instability often presents with insidious onset, and vague symptoms (usually pain and not instability as opposed to anterior instability)
 - often in sporting or occupational activities that require repetitive pushing with the arm in forward flexed position
foot ball lineman, weight lifters, etc
- Symptoms
 - pain with flexion, adduction, and internal rotation of the arm
- Physical exam
 - inspection
 - prominent posterior shoulder and coracoid for acute posterior dislocation
 - may be normal from chronic posterior instability from microtrauma
 - motion
 - limited external rotation for acute posterior dislocation
 - shoulder locked in an internally rotated position common in undiagnosed posterior dislocations
 - pain on flexion, adduction and internal rotation for posterior instability
 - provocative tests - performed in the setting of chronic posterior instability
 - Jerk test
 - place arm in 90° abduction, internal rotation, elbow bent
 - apply an axial force along axis of humerus and adduct the arm to a forward-flexed position
 - a 'clunk' is positive for posterior subluxation
 - 97% sensitive for posterior labral tear when combined with a Kim test
 - Kim test



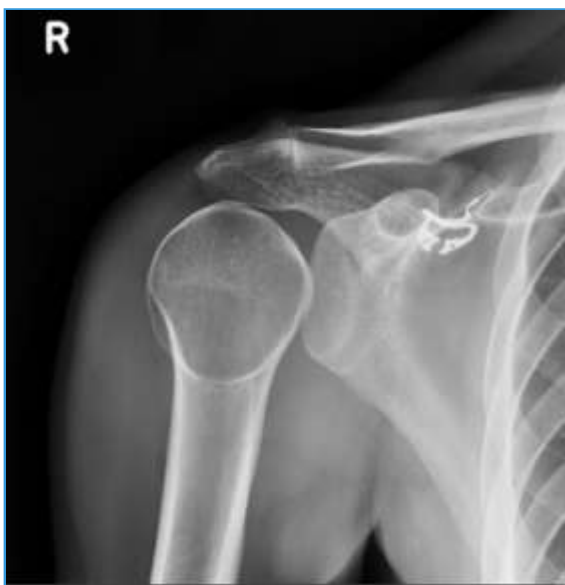- performed by having the patient seated, arm at 90° abduction, followed by flexing the shoulder to 45 forward flexion while simultaneously applying axial load on the elbow & posterior-inferior force on the upper humerus.
- test is positive when pain is present
- posterior stress test
 - stabilize scapula and look for posterior translation with a posterior direct force
 - pain is elicited often, but this is not a specific finding
- posterior load & shift test
 - place patient supine with arm in neutral rotation with 40 to 60° abduction and forward flexion, load humeral head and apply anterior and posterior translating forces noting subluxation

Posterior Load & Shift Grading		
1+	Apparent translation but not to rim	■
2+	Translation to glenolabral rim	■
3+	Translation over glenolabral rim	■
4+	Translation with complete dislocation	■

Imaging

Radiographs

- recommended views
 - AP
 - unreliable
 - may show a 'lightbulb' sign



- axillary lateral
 - best view to demonstrate a dislocation
- optional
 - Velpeau view if patient is unable to abduct arm for axillary view
- CT
 - indications
 - analyze the extent and location of bone loss in a chronic dislocation (>2 to 3 weeks)
- MRI
 - indications
 - chronic posterior instability without history of acute posterior dislocation
 - evaluate for suspected posterior labral tear, reverse Hill-Sach's lesion, or associated rotator cuff tear
 - may show Kim lesion (concealed avulsion of the deep posteroinferior labrum, with apparently intact superficial labrum)

Treatment

Nonoperative

- **acute reduction and immobilization in external rotation for 4 to 6 weeks**
 - indications
 - should be initially attempted for all acute traumatic posterior dislocations
 - most dislocations reduce spontaneously

- technique
 - immobilize in 10-20 degrees of external rotation with elbow at side
 - after 6 weeks advance to physical therapy (rotator cuff strengthening and periscapular stabilization) and activity modification (avoid activities that place arm in high-risk position)
 - physical therapy
 - may be a first line treatment for chronic posterior instability with rotator cuff strengthening, periscapular stabilizers may be considered for the in-season athlete
- Operative
 - **open or arthroscopic posterior labral repair (Bankart)**
 - indications
 - recurrent posterior shoulder instability despite appropriate course of physical therapy
 - continued pain with loading of arm in forward flexed position (bench press, football blocking)
 - negative Beighton score
 - outcomes
 - 80% to 85% success at 5- to 7-year follow-up after open repair
 - similar outcomes with arthroscopic repair after shorter follow-ups
 - avoidance of excessive shoulder flexion, adduction, and internal rotation in the immediate post-operative period
 - **open or arthroscopic posterior capsular shift and rotator interval closure**
 - indications
 - positive Beighton score
 - **posterior glenoid opening wedge osteotomy**
 - indications
 - excessive congenital glenoid retroversion
 - limited studies assessing outcomes with this approach
 - **open reduction with subscapularis transfer (McLaughlin) or lesser tuberosity transfer to the defect (Modified McLaughlin)**
 - indications
 - chronic dislocation < 6 months old
 - reverse Hill-Sachs defect < 40%
 - **hemiarthroplasty**
 - indications
 - chronic dislocation > 6 months old
 - severe humeral head arthritis
 - collapse of humeral head during reduction
 - reverse Hill-Sachs defect > 40% of articular surface
 - **total shoulder arthroplasty**
 - indications
 - significant glenoid arthritis in addition to one of the hemiarthroplasty indications
- Techniques
 - **Open or arthroscopic posterior labral repair and capsular shift**
 - goal is to repair any labral detachment or capsular tears, and/or reduce the posterior capsule volume
 - approach
 - arthroscopic approach to shoulder
 - high lateral portal may be better than standard portal for posterior labral work (ie drilling trajectory for suture anchors)
 - lateral decubitus position may allow for improved visualization for arthroscopic stabilization
 - posterior capsular shift
 - may be performed in addition to labral repair, capsular shift may be less desirable in throwing athletes
 - closure of rotator interval
 - augments posterior capsular shift
 - controversial
 - thermal shrinkage of capsule (historical)
 - contraindicated due to complications
 - mechanism
 - breaks collagen cross links
 - critical temp (65 to 75° C)

- complications
 - recurrence
 - capsular necrosis
 - axillary nerve injury
- postoperative care
 - immobilizer with arm in neutral position (external rotation sling) or standard sling
 - early range of motion and strengthening
 - full heavy labor and contact sports after 6 month
- **Open reduction with subscapularis with or without tuberosity transfer to defect**
 - approach
 - deltopectoral approach
 - technique to repair defect
 - subscapularis transfer (McLaughlin procedure)
 - subscapularis with lesser tuberosity transfer
 - used by most (modified McLaughlin procedure)
 - iliac crest bone graft
 - can be used for any glenoid bone loss
 - disimpaction and bone grafting of the defect
 - if < 3 weeks the surgeon can try disimpaction and bone grafting of the defect
 - opening wedge glenoplasty
 - may be indicated with congenital glenoid retroversion
 - complications
 - stiffness
 - AVN
 - osteoarthritis

- **Complications**

- Stiffness
 - most common complication after labral repair
- Recurrence
 - 2nd most common (7% to 50%)
- Degenerative joint disease
 - 3rd most common
- Adhesive capsulitis
- Overtightening of posterior capsule
 - may lead to anterior subluxation or coracoid impingement
- Nerve injury
 - axillary or suprascapular

17- Internal Impingement

• Summary

- Internal impingement is a cause of shoulder pain in overhead athletes caused by repetitive impingement between the undersurface of the rotator cuff and the posterosuperior glenoid.
- Diagnosis is made clinically with worsening posterior shoulder pain during maximal abduction and external rotation (position of late cocking) associated with decreased internal rotation and supplemented with MRI showing posterior rotator cuff and posterior labral pathology.
- Treatment with physical therapy and posterior capsule stretching is effective for most patients. Arthroscopic surgery is indicated for patients who fail conservative management.

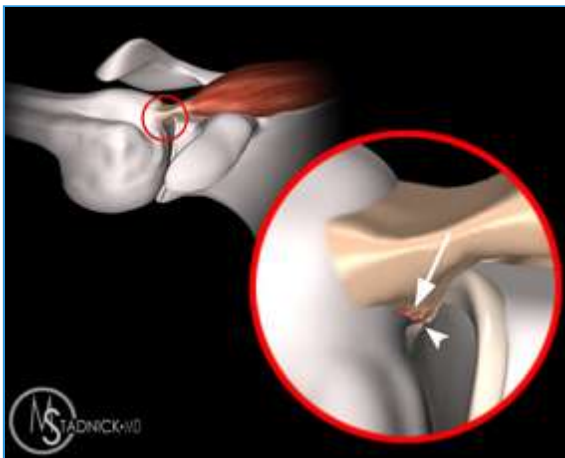• Epidemiology

- Demographics
 - major cause of shoulder pain in throwing and overhead athletes

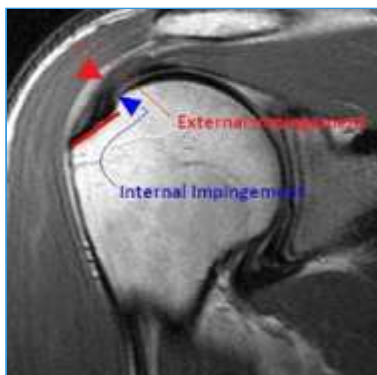• Etiology

○ Pathophysiology

- mechanism
 - impingement occurs during maximum arm abduction and external rotation during late cocking and early acceleration phases of throwing
 - causes "peel-back" phenomenon of posterosuperior labrum by the biceps
- pathoanatomy



- caused by repetitive impingement of the posterior under-surface of the supraspinatus tendon and the posterior superior aspect of the glenoid
- pathologic micromotion of the humeral head allows the rotator cuff to become impinged between the humeral head and glenoid.
 - in contrast to subacromial or "external" impingement which occurs on bursal side of rotator cuff
- internal impingement covers a spectrum of injuries including



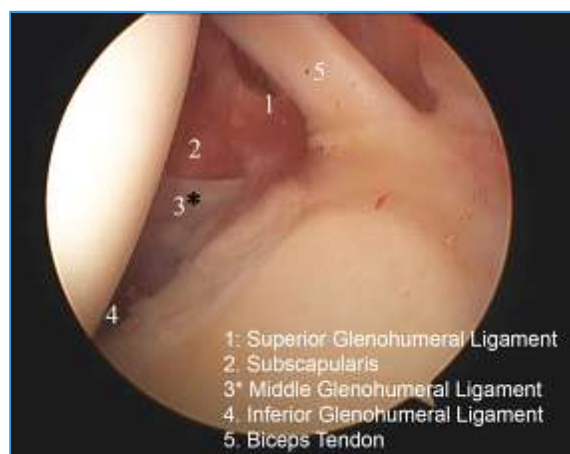- fraying of posterior rotator cuff (supraspinatus-infraspinatus interval)
- posterior and superior labral lesions
- hypertrophy and scarring of posterior capsule glenoid (Bennett lesion)
- cartilage damage at posterior glenoid
- etiology
 - tightness of posterior band of IGHL
 - anterior micro-instability
- Associated conditions
 - associated with GIRD

- SLAP tears
- SICK scapula and dyskinesia

• Anatomy

- Glenohumeral joint anatomy
- Glenohumeral stability

- static restraints
 - glenohumeral ligaments



- glenoid labrum
- articular congruity and version
- negative intraarticular pressure
- dynamic restraints
 - rotator cuff muscles
 - biceps
 - periscapular muscles
- Rotator cuff
 - primary function is dynamic stability and centering the humeral head within the glenoid via balancing the force couples about the glenohumeral joint in both coronal and transverse planes, creating a stable fulcrum
 - coronal plane
 - the inferior rotator cuff (infraspinatus, teres minor, subscapularis) balances the superior moment of the deltoid
 - transverse plane
 - the anterior cuff (subscapularis) balances the posterior moment of the posterior cuff (infraspinatus and teres minor)
 - the goal of treatment in rotator cuff tears is to restore this equilibrium in all planes

• Classification

- No formal classification scheme

• Presentation

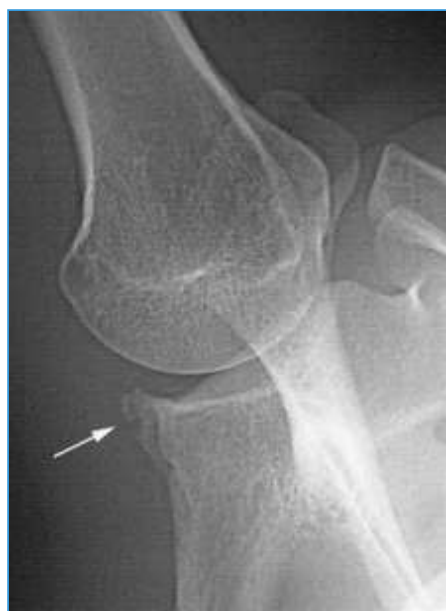- Symptoms
 - shoulder pain, sometimes localized posteriorly
 - diffuse pain in posterior shoulder along the posterior deltoid
 - shoulder pain worse with throwing
 - especially during late cocking and early acceleration
- Physical exam
 - inspection
 - may see retroversion of proximal humerus
 - pain with palpation along infraspinatus
 - ROM
 - increased external rotation
 - decreased internal rotation
 - loss of > 20° of IR at 90° compared to contralateral shoulder
 - must stabilize the scapula to get true measure of glenohumeral rotation
 - preservation of the total arc of motion
 - strength
 - often can demonstrate rotator cuff weakness
 - provocative tests
 - Whipple test

- performed to test for partial suprapinsatus tears
 - performed by ranging shoulder in forward flexion, adduction and scapular retraction
 - positive when pain is reproduced on resistance
 - Apprehension test
 - positive for internal impingement
 - performed by bringing shoulder into maximum ER, abduction and extension
 - positive if posterior shoulder pain reproduced in this position and relieved when arm brought into neutral extension/flexion

- Imaging

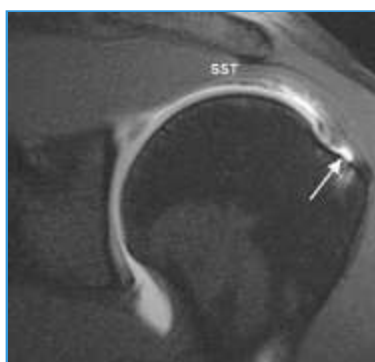
- Radiographs

- recommended views
 - complete shoulder series
 - findings
 - usually unremarkable
 - AP may show a Bennett lesion (exostosis of posteroinferior glenoid)

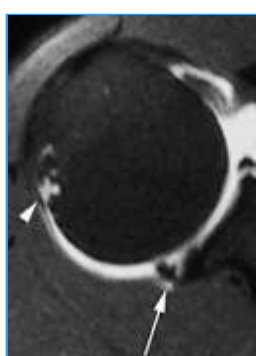
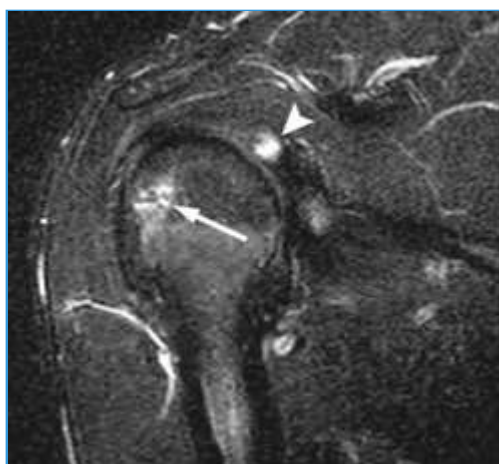


- MRI or MR arthrogram

- findings
 - can show pathology of the rotator cuff and/or labral pathology
 - such as partial articular-sided supraspinatus-infraspinatus tendon avulsion (PASTA), fraying, or tear



- signal at greater tuberosity and/or posterosuperior labrum



- optional views

- ABER positioning reproduces position of impingement showing dynamic process on the humerus and glenoid sides

• Treatment

○ Nonoperative

▪ **PT, cessation from throwing, posterior capsule stretching**

- indications
 - first-line of treatment
 - most internal impingement can be treated non-operatively
 - Operative treatment should only be considered if patient has failed adequate physical therapy for an extended period of time as results following operative intervention are unpredictable

○ Operative

▪ **arthroscopic debridement of rotator cuff and/or labrum**

- indications
 - failure of nonoperative treatment and
 - partial thickness rotator cuff tear (PASTA) that compromise the integrity of the rotator cuff
 - partial rotator cuff tears <50%
 - Bennett lesions
 - peel-back labral lesion

▪ **Arthroscopic vs mini-open rotator cuff and/or labral repair**

- indications
 - partial tears >50% tendon thickness or full thickness tears
 - unstable labral tears

▪ **Posterior capsule release vs anterior capsular stabilization**

- indications
 - persistent posterior capsule contracture or anterior shoulder instability in addition to any of the above pathology

• Techniques

○ **PT, cessation from throwing, posterior capsule stretching**

- cessation
 - break from throwing until pain subsided, followed by supervised return to throwing focusing on proper mechanics
- therapy
 - posterior capsular stretching program (i.e. sleeper stretches), rotator cuff strength balancing, scapular stabilization, kinetic chain coordination
 - stretching for 6 months
- outcomes correlated with compliance to therapy regimen

○ **Arthroscopic debridement of rotator cuff tear and/or labrum**

- diagnostic arthroscopy
 - perform meticulous exam under anesthesia to assess range of motion
 - diagnostic arthroscopy intra-articular and subacromial
- debridement
 - arthroscopic shaver to debride loose tissue edges
- allows accelerated rehab and return to throwing
- shorter post-op immobilization time

○ **Arthroscopic vs mini-open rotator cuff repair**

- approach
 - arthroscopic has advantage of addressing labral and other intra-articular pathology
- acromioplasty
 - bursectomy performed to visualize bursal-side of tendon
 - acromioplasty is not indicated if no bursal-sided pathology seen
- cuff repair
 - abrasive preparation of the greater tuberosity footprint
 - portal of Wilmington usually necessary
 - partial-thickness tears
 - in-situ trans-tendinous repair
 - pulley technique utilizing suture anchors to reduce tendon to tuberosity

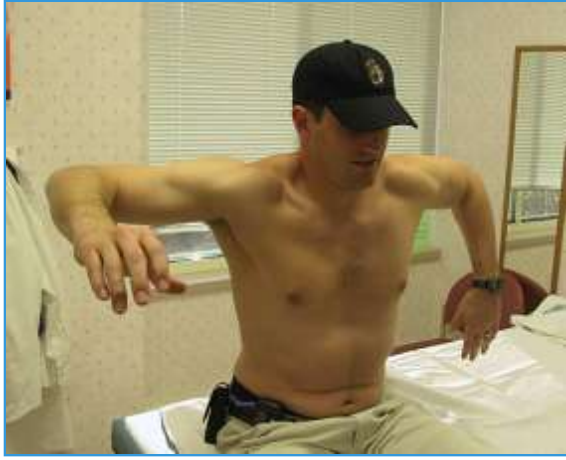- will functionally shorten the tendon length
- complete partial tear followed by anatomic repair technique
 - single or double-row repair
- labrum
 - prepare glenoid rim and repair of unstable labral tear
- **Posterior capsular release vs anterior stabilization**
 - posterior release
 - done adjunctively with above procedures
 - cautery wand or arthroscopic shaver to release synovium and capsular tissues
 - risk of axillary nerve injury
 - anterior stabilization
 - done adjunctively with the above procedures
 - capsular plication most common

- **Complications**

- Progression to full-thickness rotator cuff tear
 - small risk of partial tears treated with debridement alone
- Delayed Rate of Return to Play
 - worse rates following rotator cuff repairs in throwing athletes
- Axillary nerve injury
 - at risk during posterior release at the inferior border of infraspinatus

18- Glenohumeral Internal Rotation Deficit Gird

Images



summary

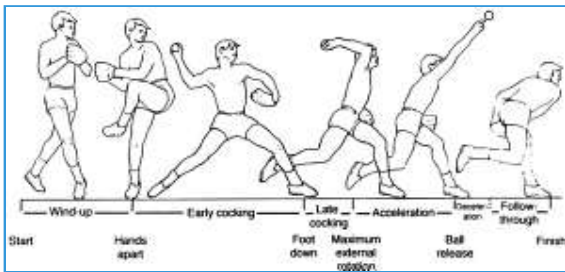
- Glenohumeral internal rotation deficit (GIRD) is a condition resulting in the loss of internal rotation of the glenohumeral joint as compared to the contralateral shoulder, most commonly seen in the throwing athlete.
- Diagnosis is made clinically with a decrease in internal rotation, increase in external rotation, with a decrease in total arc of rotation compared to the contralateral shoulder.
- Treatment consists of physical therapy with a focus on posteroinferior capsular stretching.

Epidemiology

- Demographics
 - occurs primarily in overhead athletes
 - often seen in baseball pitchers

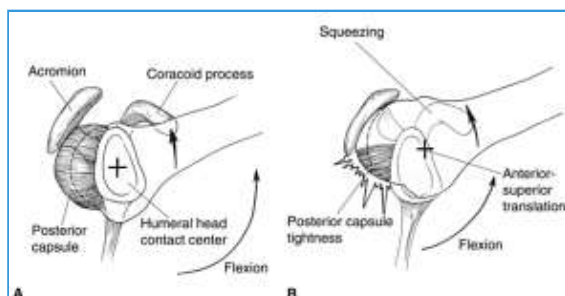
Etiology

- Pathophysiology
 - mechanism
 - caused by repetitive throwing
 - thought to occur during the late cocking and early acceleration phase

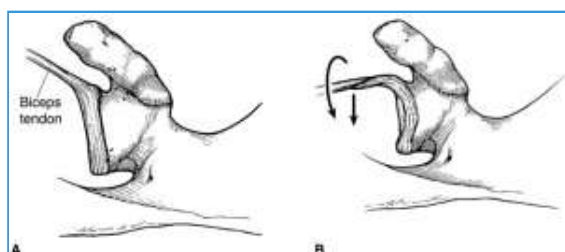


■ pathoanatomy

- tightening of posterior capsule or posteroinferior capsule leads to translation of humeral head (capsular constraint mechanism)
- translation of humeral head is in the OPPOSITE direction from area of capsular tightening
- posterior capsular tightness leads to anterosuperior translation of humeral head in flexion



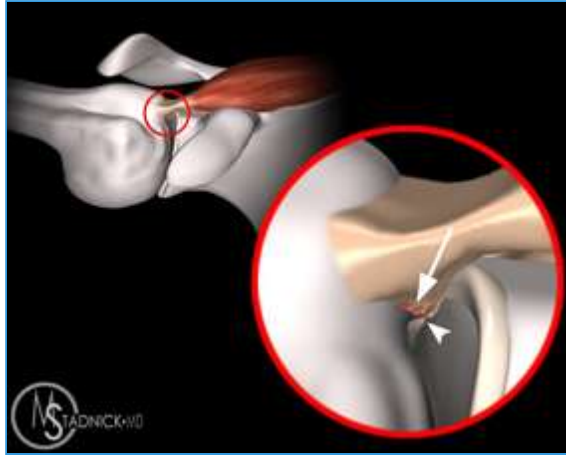- posteroinferior capsular tightness leads to posterosuperior translation of humeral head in ABER



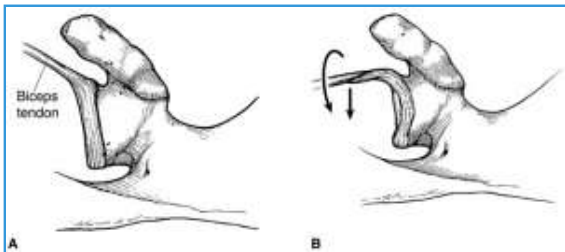
- anterior capsule is stretched

- Associated conditions

- glenohumeral instability
- internal impingement
 - abutment of the greater tuberosity against the posterosuperior glenoid during abduction and external rotation leads to pinching of posterosuperior rotator cuff



- articular-sided partial rotator cuff tears
 - tensile failure in excessive rotation
 - internal impingement
- SLAP lesion
 - throwers with GIRD are 25% more likely to have a SLAP lesion
 - peel-back mechanism (biceps anchor and postero superior labrum peels back) during late cocking
 - because of posterosuperior translation of humeral head and change in biceps vector force posteriorly



• Anatomy

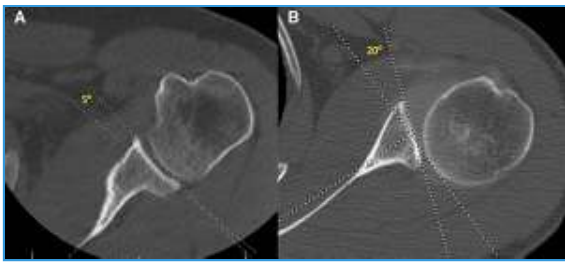
- Glenohumeral joint

• Presentation

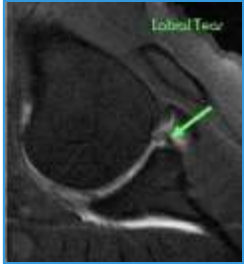
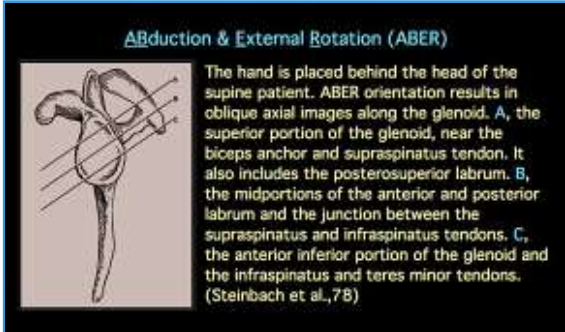
- Symptoms
 - vague shoulder pain
 - sometimes painless
 - may report a decrease in throwing performance
- Physical exam
 - stabilize the scapula to obtain true measure of glenohumeral rotation
 - increased sulcus sign
 - due to stretching of anterior structures that resist external rotation (coracohumeral ligament, rotator interval)
 - characterized by altered glenohumeral range of motion
 - decrease in internal rotation and increase in external rotation
 - if the GIRD (loss of internal rotation) is less than external rotation gain (ERG), the shoulder maintains normal kinematics
 - if the GIRD exceeds external rotation gain (ERG), this leads to deranged kinematics
 - decrease in internal rotation is usually greater than a 25° difference as compared to non-throwing shoulder

• Imaging

- Radiographs
 - recommended views
 - AP and lateral of glenohumeral joint
 - findings
 - usually normal
- CT
 - may show increased glenoid retroversion

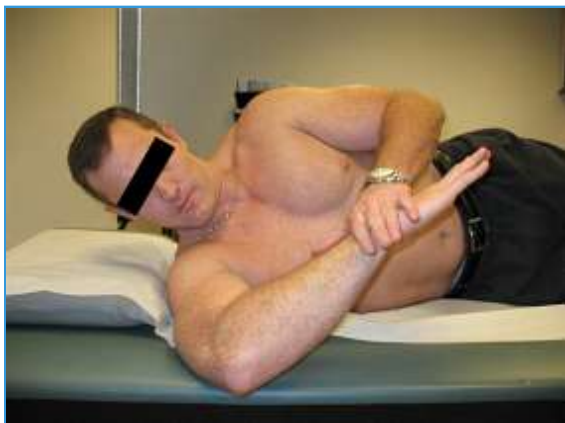

- MRI
 - ABER view on MRI can show associated lesions

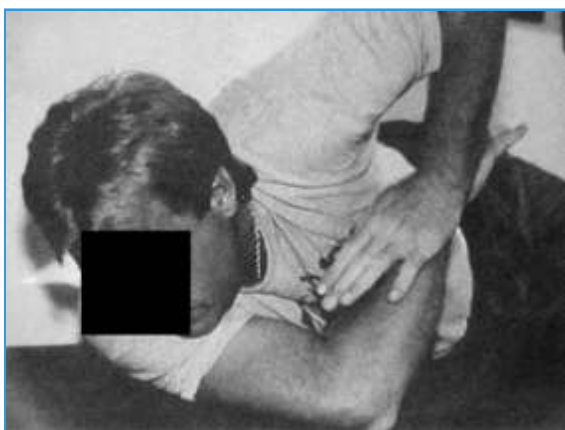


- Treatment

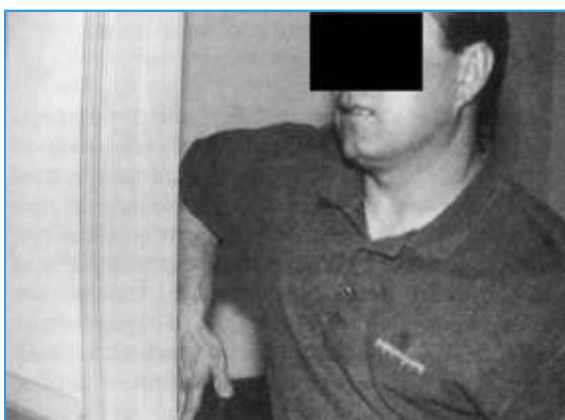- Nonoperative
 - rest from throwing and physical therapy for 6 months
 - indications
 - first line of treatment
 - physical therapy
 - posteroinferior capsule stretching
 - sleeper stretch




- performed with internal rotation stretch at 90 degrees abduction with scapular stabilization
- roll-over sleeper stretch



- arm flexed 60° and body rolled forward 30°
- doorway stretch



- cross-body adduction stretch



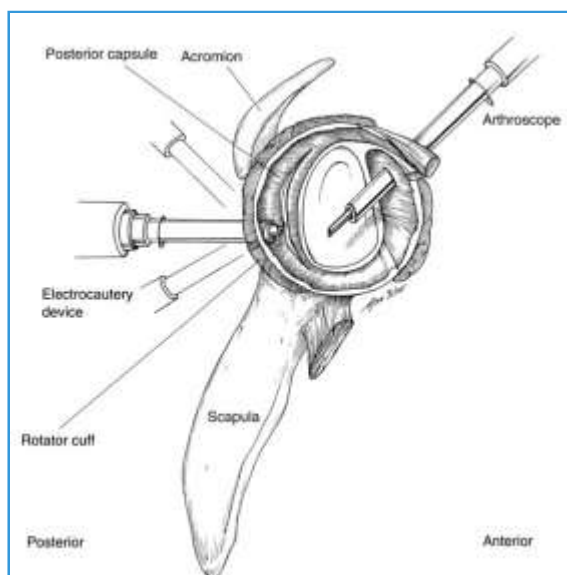
- pectoralis minor stretching
- rotator cuff and periscapular strengthening
- outcomes
 - 90% of young throwers respond to sleeper stretches/PT
 - 10% of older throwers do not respond, and will need arthroscopic release eventually

- Operative

- **posteroinferior capsule release vs. anterior stabilization**
 - indications
 - only indicated if extensive PT fails

- Techniques

- **Posterior capsule release vs. anterior stabilization**

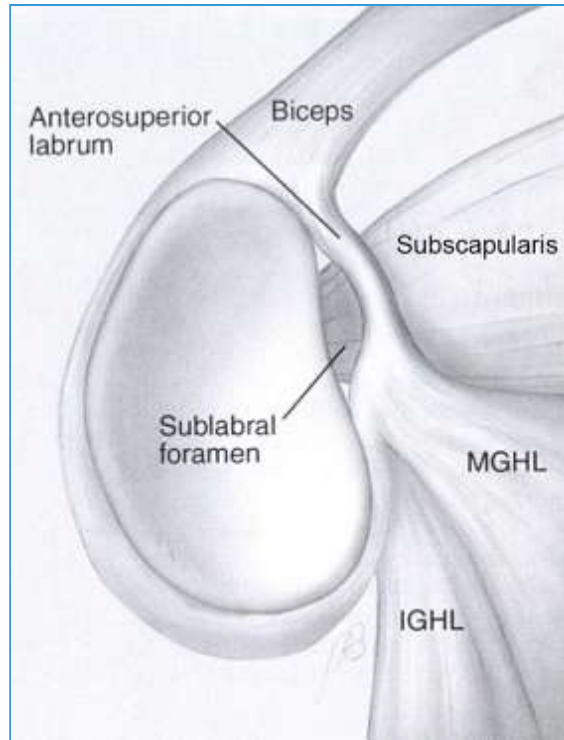
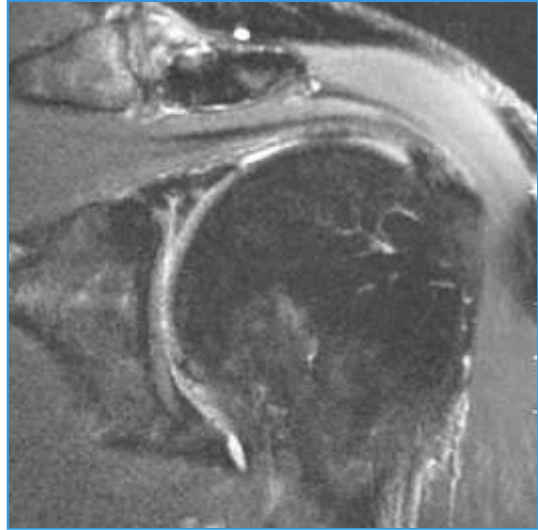


- some advocate posterior capsule release while others advocate anterior stabilization
- repair thinned rotator cuff if significantly thinned (transcuff or takedown and repair)
- technique controversial
 - for throwing athlete with posteroinferior capsular contracture, release posterior inferior capsule and posterior band of IGHL
 - electrocautery inserted through posterior portal, camera from anterior portal
 - from 9 to 6 o'clock position
 - at level of glenoid rim
 - until rotator cuff fibers (behind the capsule) can be seen from within joint
 - insert arthroscopic shaver to widen gap in capsule (prevents recurrence)
 - gentle manipulation at the end completes release of any remaining fibers, maximizes IR and flexion
- results
 - will immediately gain 65° of internal rotation postop

- Complications

19- Slap Lesion

Images



• summary

- A SLAP lesion (Superior Labrum from Anterior to Posterior tear) generally occurs as result of overuse injury to the shoulder in overhead athletes or traumatic falls in older patients and can result in deep shoulder pain and biceps tendonitis.
- Diagnosis generally requires MRI studies to assess the superior labrum and the integrity of the biceps tendon.
- Treatment may be nonoperative or operative depending on patient age, activity levels, severity of symptoms and associated instability.

• Epidemiology

- Incidence
 - uncommon injuries, account for less than 5% of all shoulder injuries
- Demographics
 - dominant shoulder of overhead and throwing athletes
- Risk factors
 - glenohumeral internal rotation deficit

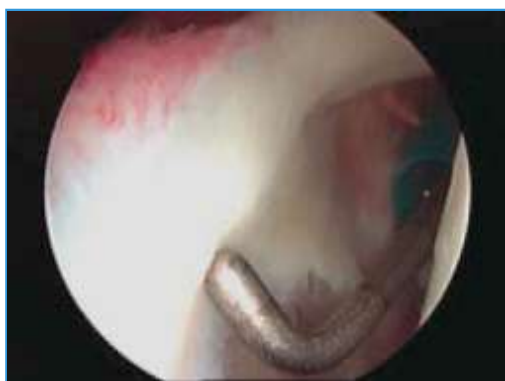
• Etiology

- Pathophysiology
 - mechanisms of injury
 - repetitive overhead activities (often seen in throwing athletes)
 - fall on outstretched arm with tensed biceps
 - traction on the arm
 - pathoanatomy
 - in throwers may be due to tightness of the posterior-IGHL which shifts the glenohumeral contact point posterosuperiorly and increases the shear force on the superior labrum
 - SLAP lesion increases the strain on the anterior band of the IGHL and thus compromises stability of shoulder
- Associated conditions
 - internal impingement
 - GIRD
 - rotator cuff tears (usually articular sided)
 - instability (may be subtle)
 - scapular dyskinesis

• Anatomy



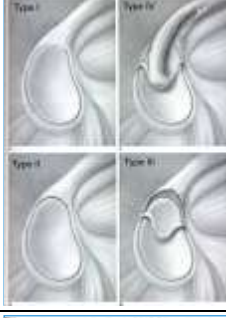
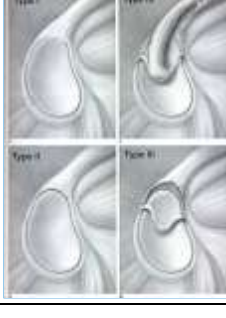
- Anatomy of glenohumeral joint
- Variant anatomic anatomy

- variable anatomic relationships extremely common in the glenohumeral joint
- recognition of these critical but often challenging
- Biceps
 - anatomy
 - long head of biceps tendon most commonly has 50% fibers attaching to labrum and 50% to supraglenoid tubercle
 - tubercle located over 6mm medial to glenoid surface
 - biceps tendon attachment on glenoid (Tuoheti classification)
 - Type I - completely posterior
 - Type II - predominantly posterior
 - Type I and II together comprise >70%
 - Type III - anterior + posterior (25%)
 - Type IV - anterior (5%)
 - most common pattern of biceps tendon attachment to the superior labrum is posterior to the 12 o'clock position
 - blood supply
 - poorest tendon blood supply while traversing through joint
 - function
 - contributes to torsional and horizontal stability during late-cocking phase of throwing
- Glenoid labrum
 - function
 - chock block to subluxation
 - composition
 - composed of fibrocartilaginous tissue
 - blood supply
 - from suprascapular, circumflex scapular, posterior humeral circumflex arteries
 - labrum receives blood from capsule and periosteal vessels and not from underlying bone
 - anterior-superior labrum has poorest blood supply
 - stability
 - superior labrum
 - attaches further (medial) from glenoid rim than rest of labrum
 - anchors biceps tendon and is weak link that leads to SLAP lesion
 - anatomic variants
 - sublabral recess/foramen
 - can be confused with a tear on MRI
 - sublabral recess/foramen with thickened MGHL
 - meniscoid appearance (1%)



- Buford complex
 - cordlike MGHL with associated bare area of the anterosuperior labrum
 - repair of Buford complex to glenoid will result in significant loss of external rotation
 - superior attachment of MGHL on glenoid

• Classification

SLAP Classification		
Type	Description	
I	Labral and biceps fraying, anchor intact (11% of cases)	
II	Labral fraying with detached biceps tendon anchor (41% of cases)	
III	Bucket handle tear, intact biceps tendon anchor (33% of cases) (Biceps separates from bucket handle tear)	
IV	Bucket handle tear with detached biceps tendon anchor (15% of cases) (Biceps remains attached to bucket handle tear)	
V	Type II + anteroinferior labral extension (Bankart lesion)	
VI	Type II + unstable flap	
VII	Type II + MGHL injury	
VIII	Type II + posterior extension	
IX	Circumferential	
X	Type II + posteroinferior extension (reverse Bankart)	

- Snyder Classification: Original classification which includes Types I-IV
- Maffet sub-classification: Includes the original I-IV and added Types V-VII
- Significant inter-and intra-observer variability when designating classification for SLAP tears

• Presentation

- History
 - feeling "pop" sensation in shoulder during overhead activity or traumatic event
- Symptoms
 - location
 - vague deep shoulder pain
 - timing
 - often a lag between the time of injury and the onset of symptoms
 - mechanical symptoms of popping and clicking
 - weakness, easy fatigue, and decrease athletic performance
- Physical exam
 - inspection
 - evaluate scapular position and muscle atrophy
 - palpation
 - bicipital groove tenderness
 - motion
 - pop may be reproduced during overhead range of motion
 - particular attention to internal rotation and total rotational arc of motion
 - always compare to contralateral side
 - neurovascular

- atrophy of supra- and/or infraspinatus due to suprascapular neuropathy
- provocative tests
 - there is no one specific test for SLAP lesions
 - biceps provocation tests
 - Speed's test
 - Yergason's test
 - Kim biceps load test
 - SLAP lesion tests
 - active compression test (O'Brien's test)
 - crank test
 - arm placed in full abduction and humerus loaded and rotated
 - dynamic labral shear test
 - Kibler anterior slide test
 - apprehension positive in 85% of patients

• Imaging

- Radiographs
 - findings often normal
- MRI +/- arthrogram
 - indications
 - high suspicion for labral tear
 - findings
 - T2 signal intensity between the superior labrum, lateral to glenoid rim, and posterior to the biceps
 - sensitivity ~50% and specificity ~90% which increases with arthrogram
 - may see an associated paralabral ganglion cyst, which is highly specific for labral tear
 - usually in the spinoglenoid notch

• Treatment

- Nonoperative
 - **rest from sports followed by physical therapy and NSAIDs**
 - indications
 - first line of treatment
 - address GIRD if present
 - rehab focusing on scapular dyskinesia and rotator cuff strengthening for all patients
- Operative
 - **arthroscopic debridement**
 - indications
 - Types I, III, and IV tears involving <1/3rd of the biceps tendon, causing severe symptoms that have failed nonoperative management
 - **arthroscopic debridement with repair of the labrum/biceps versus debridement with biceps tenotomy/tenodesis**
 - indications
 - highly controversial
 - Type 2 tears traditionally repaired in overhead athletes
 - return to play rates after SLAP repairs are significantly lower for pitchers compared to non-pitchers
 - general consensus bodes for tenotomy/tenodesis among those over 40 years of age
 - **arthroscopic debridement with repair or debridement of the labrum with biceps tenotomy/tenodesis**
 - indications
 - Type IV tears with >1/3rd of the biceps tendon involved, causing severe symptoms that have failed nonoperative management

• Techniques

- **Arthroscopic debridement versus stabilization of the labrum and biceps tendon versus tenotomy/tenodesis**
 - approach
 - standard arthroscopic approach to the shoulder
 - soft tissue
 - look for erythema and tearing under labrum to differentiate from normal recess
 - "peel back" test shows "peel back" of the labrum with 90° of external rotation and abduction

- debride loose flaps of labrum/biceps
- decompress any cysts
- SLAP repair
 - utilize accessory or percutaneous portals as necessary for anchor placement near glenoid rim
 - sutures placed depending on tear anatomy
 - traditionally, sutures placed anterior to biceps anchor place patient at increased risk of stiffness post-operatively
- biceps tenotomy/tenodesis
 - tenotomize biceps near attachment to labrum with arthroscopic scissors or shaver device
 - tenodesis may be done all-arthroscopically or through mini-open incision
 - variety of tenodesis devices used for biceps fixation into proximal humerus
- rehabilitation
 - week 1-4
 - passive and active assisted flexion in the scapular plane
 - avoid extremes of abduction and external rotation, and resisted biceps exercises
 - week 4-6
 - progress to active ROM, isometrics
 - week 6-12
 - functional exercise and light strengthening
 - week 12+
 - advance strength and ROM, sport-specifics
 - typical return to sport around 6 months

• Complications

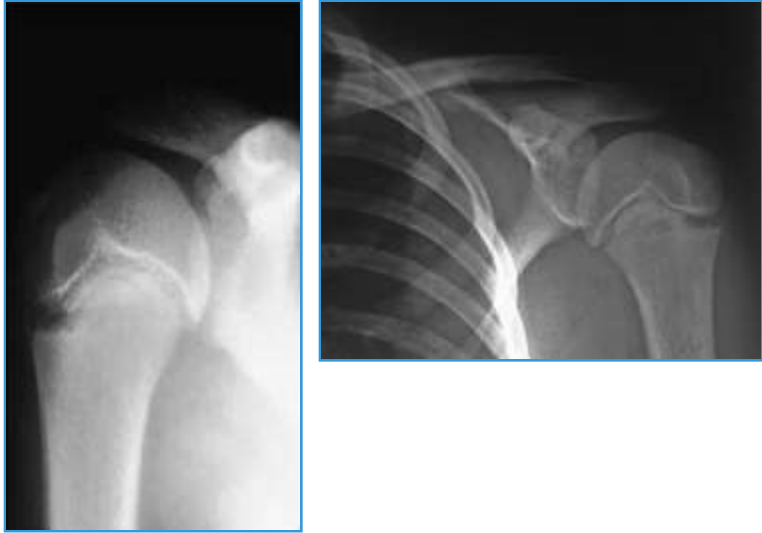
- Stiffness
 - incidence
 - most common complication following SLAP repair, around 78% of all patients
 - risk factors
 - incidental SLAP lesions repaired in older patients (>45 years) having arthroscopic rotator cuff repair
 - treatment
 - early passive and active assisted range of motion (pendulum) exercises begun 1 week following repair
 - if stiffness does not resolve with physical therapy, capsular release is indicated
- Suprascapular nerve injury
 - overdrilling the glenoid can injure the suprascapular nerve
- Failed SLAP repair and persistent symptoms
 - many causes including articular cartilage injuries, hardware failure and anchor pullout
 - failures associated with age >36 years
 - biceps tenodesis better option in this age group

• Prognosis

- Return to Play
 - variable and unpredictable rates of return among elite-level throwers

20- Little Leaguers Shoulder

Images



• summary

- Little Leaguer's shoulder is an overuse injury occurring in young baseball pitchers resulting in epiphysiolysis of the proximal humerus (a Salter Harris Type 1 injury).
- Diagnosis is made with radiographs of the shoulder showing a widened proximal humerus physis in comparison to contralateral shoulder.
- Treatment is cessation of throwing, followed by PT and progressive throwing program after sufficient rest.

• Epidemiology

- Demographics
 - seen in skeletally immature overhead athletes
 - adolescent pitchers
 - 10% of all shoulder pain in pediatric patients is related to throwing
 - occasionally seen in tennis players
 - males > females
 - age 11-16 years

• Etiology

- Pathophysiology
 - mechanism
 - repetitive torsional and distractive stresses at the physis (Saltar Harris 1 injury)
 - pitching
 - phases
 - late cocking
 - shoulder is maximally externally rotated, leading to extreme rotatory torque through the growth plate, approximately 400% greater than the fragile physeal cartilage can tolerate
 - deceleration
 - opposing forces of forward arm motion and rotator cuff results in excessive eccentric physeal stress
 - breaking pitches are implicated
 - number of pitches is the most important factor
 - cell biology
 - hypertrophic zone of the physis is affected
 - weakest portion of the growth plate

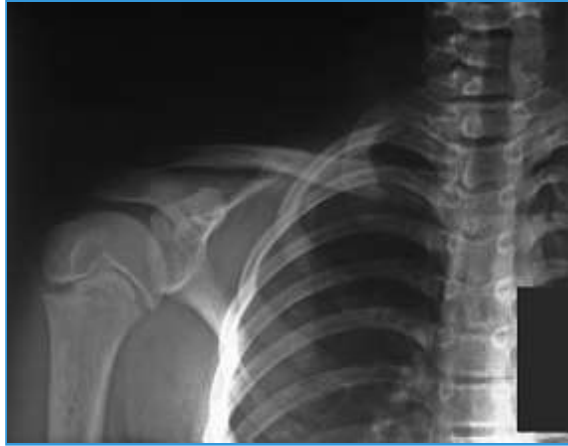• Presentation

- History
 - decreased pitch velocity
 - decreased pitch accuracy
- Symptoms
 - diffuse arm and shoulder pain with throwing
 - worse in late cocking or deceleration phases

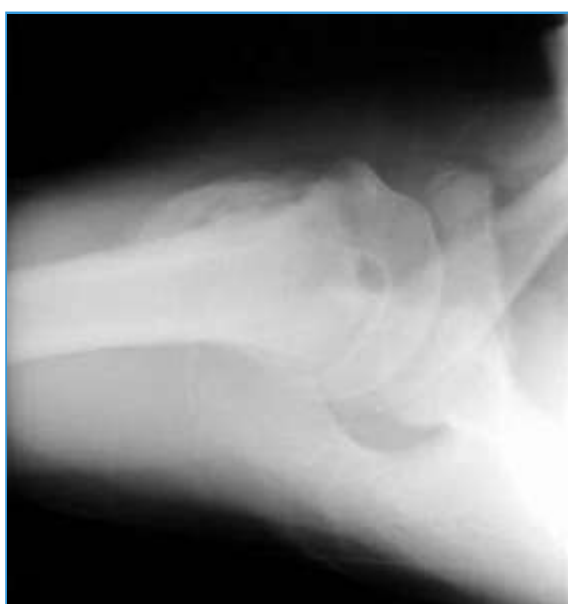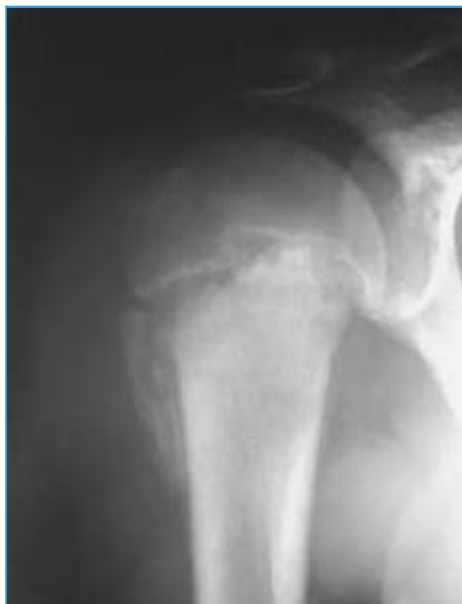
- pain resolves with rest
- Physical exam
 - point tenderness over lateral proximal humerus, at the shoulder physis
 - pain reproduced with shoulder rotation
 - glenohumeral internal rotation deficit
 - patients with GIRD are three times more likely to experience recurrent symptoms

- Imaging

- Radiographs
 - recommends views
 - AP in external rotation, scapular Y and axillary views
 - contralateral shoulder can be obtained for comparison in subtle cases
 - findings
 - widened proximal humerus physis in comparison to contralateral shoulder

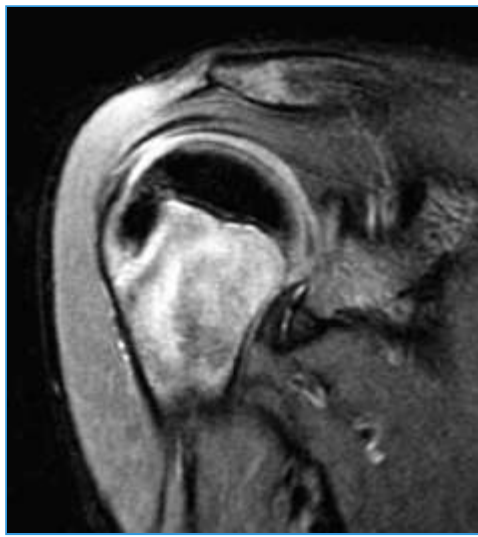

- metaphyseal bony changes



- may have normal radiographs (17%)

- MRI
 - findings
 - edema around physis



- may be helpful to rule out other pathology
 - labral tear
 - partial articular-sided rotator cuff tears (less likely)

• Treatment

○ Nonoperative

- **cessation of throwing, followed by PT and progressive throwing program after sufficient rest**

- indications
 - mainstay of treatment
- technique
 - refrain from pitching for 3 months
 - start progressive throwing program only after symptom resolution
 - physical therapy
 - rotator cuff strengthening
 - posterior shoulder capsule stretching
 - core strengthening
 - progressive throwing program
 - start with short tosses at low velocity
 - slowly progress distance and velocity of throws

○ Prevention

- proper pitching mechanics
 - using pitching coaches
- discourage breaking ball pitches
 - until skeletal maturity
- enforcement of pitch counts
 - as well as days off for shoulder rest
- avoid year-round pitching

▪ Pitch Count Recommendations			
▪ Age (years)	▪ Pitches per Game	▪ Max Games per Week	
▪ 8-10	▪ 52	▪ 2	▪
▪ 11-12	▪ 68	▪ 2	▪
▪ 13-14	▪ 76	▪ 2	▪
▪ 15-16	▪ 91	▪ 2	▪
▪ 17-18	▪ 106	▪ 2	▪

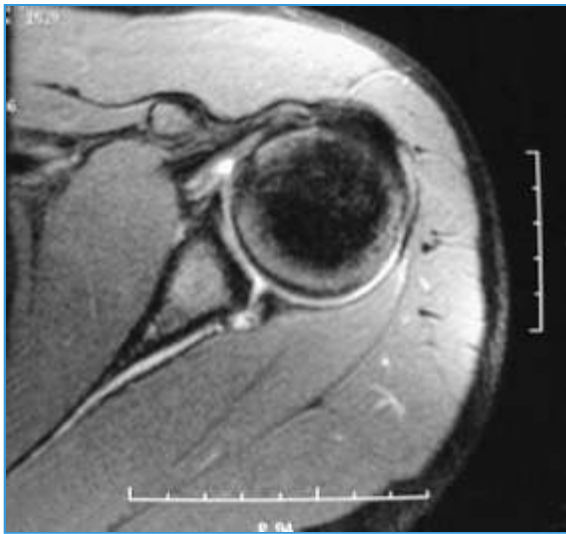• Complications

○ Premature growth arrest of proximal humeral epiphysis

- can cause
 - growth arrest
 - angular deformity

21- Posterior Labral Tear

Images



• summary

- A posterior labral tear is referred to as a reverse Bankart lesion, or attenuation of the posterior capsulolabral complex, and commonly occurs due to repetitive microtrauma in athletes.
- Diagnosis can be made clinically with positive posterior labral provocative tests and confirmed with MRI studies of the shoulder.
- Treatment may be nonoperative or operative depending on chronicity of symptoms, degree of instability, and patient activity demands.

• Epidemiology

- Demographics
 - athletes
 - weightlifters (bench press)
 - football linemen (blocking)
 - swimmers
 - gymnasts
 - wrestlers

• Etiology

- Pathophysiology
 - repetitive microtrauma to the posterior capsulolabral complex
 - most common mechanism
 - posteriorly directed force with the arm in a flexed, internally rotated and adducted position
 - glenoid retroversion
 - patients with increased glenoid retroversion ($\sim 17^\circ$) were 6x more likely to experience posterior instability compared to those with less glenoid retroversion ($\sim 7^\circ$)
- Associated injuries
 - Kim lesion
 - an incomplete and sometimes concealed avulsion of posteroinferior labrum

• Anatomy

- Posterior labrum
 - function
 - helps generate cavity-compression effect of glenohumeral joint
 - creates 50% of the glenoid socket depth
 - provides posterior stability
 - anatomy
 - composed of fibrocartilagenous tissue
 - anchors posterior inferior glenohumeral ligament (PIGHL)
- Glenohumeral joint anatomy

• Presentation

○ Symptoms

- vague, nonspecific posterior shoulder pain is the most common symptoms
 - worsens with provocative activities that apply a posteriorly directed force to the shoulder
 - ex: pushing heavy doors, bench press, push-ups
- clicking or popping in the shoulder with range of motion
- sense of instability
 - less common
- pain during throwing
 - late cocking phase

○ Physical exam

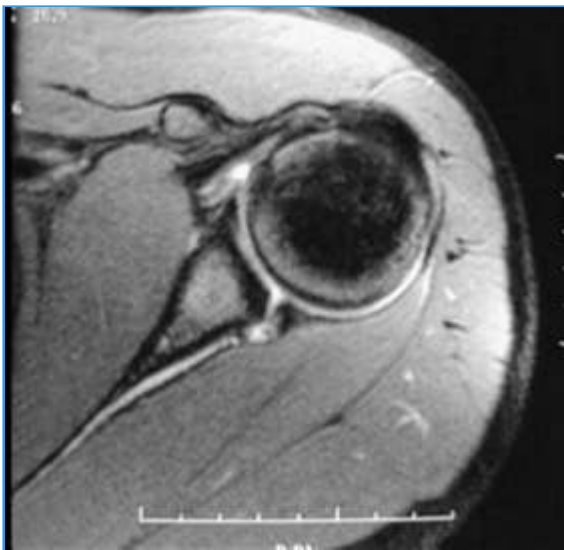
- posterior joint line tenderness
- provocative tests
 - posterior apprehension test
 - arm positioned with shoulder forward flexed 90° and adducted
 - apply anterior support to scapula
 - apply posteriorly directed force to shoulder through humerus
 - positive if patient experiences sense of instability or pain
 - posterior load and shift test
 - patient rests arm at their side
 - grasp the proximal humerus and apply a posteriorly directed force
 - assess distance of translation and patient response
 - grade 0 = no translation
 - grade 1 = to edge of glenoid
 - grade 2 = over edge of glenoid but spontaneously relocates
 - grade 3 = over edge of glenoid, does not spontaneously relocate
 - jerk test
 - arm positioned with shoulder abducted 90° and fully internally rotated
 - axially load humerus while adducting the arm across the body
 - clunk indicates subluxation of the humeral head off the posterior glenoid
 - highly sensitive and specific for a posterior labral tear
 - kim test
 - arm positioned with shoulder abducted 90° and forward flexed 45°
 - apply posteriorly and inferiorly directed force to shoulder through humerus
 - positive if patient experiences pain
 - highly sensitive and specific for posteroinferior labral tear

• Imaging

○ Radiographs

- recommended views
 - true AP, scapular Y and axillary views
 - axillary view required to ensure glenohumeral joint reduction
 - posterior shoulder dislocations may be missed on AP radiographs alone
- findings
 - often normal
 - in chronic cases axillary view may show
 - glenoid retroversion or
 - posterior glenoid erosion

○ MRI



- indications
 - diagnostic study of choice
- technique
 - intra-articular contrast increases sensitivity for labral pathology

• Treatment

○ Nonoperative

▪ **activity modification, NSAIDs, PT**

- indications
 - first line of treatment
- technique
 - rotator cuff and deltoid strengthening
 - periscapular stabilization

○ Operative

▪ **posterior labral repair, capsulorrhaphy**

- indications
 - extensive nonoperative management fails
- technique
 - arthroscopic and open techniques may be used
 - arthroscopic preferred to open given the extensive posterior surgical dissection required
 - more reliable return to play
 - suture anchor repair and capsulorrhaphy results in fewer recurrences and revisions than non-anchored repairs
 - probing of posterior labrum is required to rule out a subtle Kim lesion
- outcomes
 - generally good
 - return to previous level of function in overhead throwing athletes not as reproducible as other athletes
 - failure risk increases if adduction and internal rotation are not avoided in the acute postoperative period

• Complications

○ Axillary nerve palsy

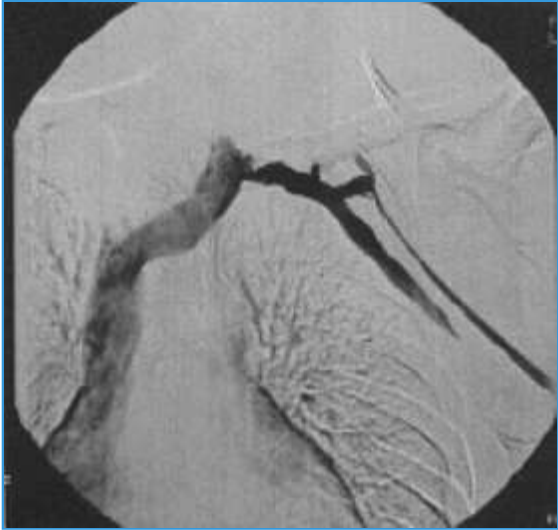- posterior branch of the axillary nerve is at risk during arthroscopic stabilization
 - travels within 1 mm of the inferior shoulder capsule and glenoid rim
 - at risk during suture passage at the posterior inferior glenoid

○ Overtightening of posterior capsule

- can lead to anterior subluxation or coracoid impingement

22- Thoracic Outlet Syndrome

Images



• Summary

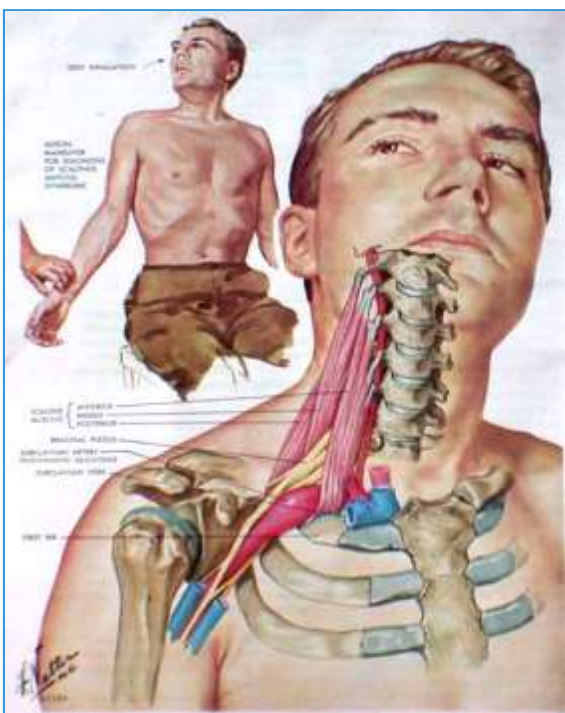
- Thoracic outlet syndrome is a neurovascular disorder resulting from compression of the brachial plexus and/or subclavian vessels in the interval between the neck and axilla.
- Diagnosis can be suspected clinically with specific provocative tests and supplemented with radiographs or vascular studies, showing anatomic causes of compression.
- Treatment may be nonoperative or include surgical decompression or a vascular procedure depending on the specific etiology.

• Epidemiology

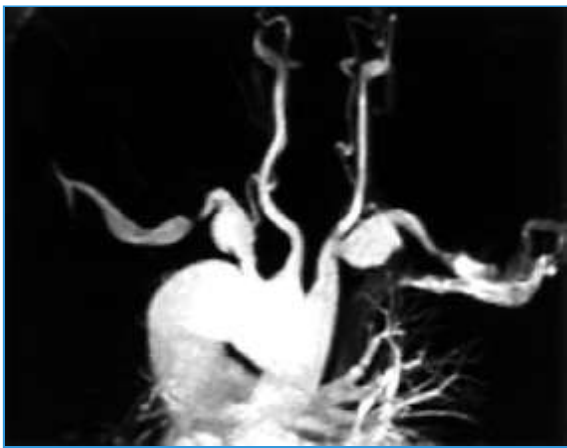
- Incidence
 - 1-2% of the population
- Demographics
 - females > males (3:1)
 - tend to be thin with long necks and drooping shoulders
 - age 20-60

• Etiology

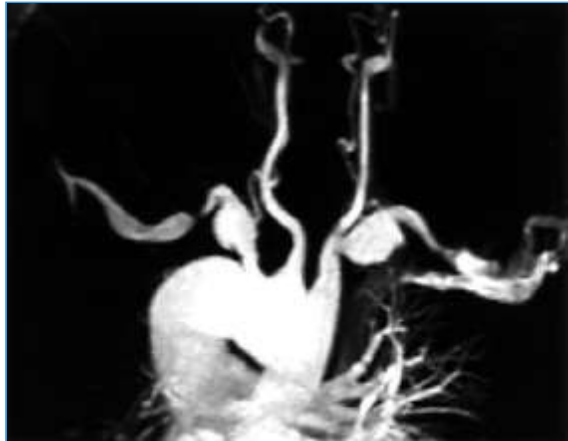
- Type
 - neurogenic is most common (95%)



- vascular may be venous (4%) or arterial (< 1%)



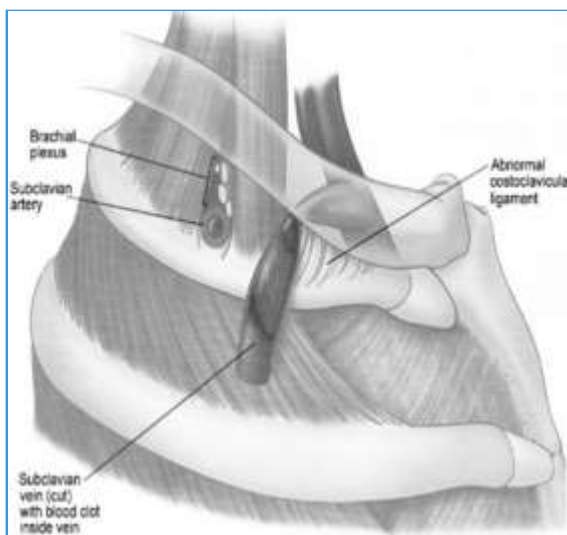
- more common in athletic males compared to athletic females



○ Pathophysiology

- most cases are thought to stem from anatomic predisposition with superimposed neck trauma (acute or chronic repetitive stress)
 - anatomically, can be organized into soft tissue (70%) and osseous (30%) abnormalities
- soft tissue
 - scalene muscle abnormalities
 - hypertrophy of anterior scalene
 - passage of the brachial plexus through the anterior scalene muscle
 - rather than posterior within the interscalene triangle
 - variable origin and insertion
 - anterior insertion of the middle scalene muscle on the 1st rib
 - scalenus minimus
 - accessory muscle found in 30-50% of patients with TOS
 - originates from cervical transverse process and inserts onto 1st rib between the subclavian artery and T1 root
 - anomalous ligaments or bands
 - fibromuscular bands
 - increase stiffness and decrease compliance of the thoracic outlet
 - costoclavicular ligament
 - abnormal insertion implicated in Paget-Schroetter syndrome
 - soft tissue tumors
 - Pancoast tumor
 - tumor of the pulmonary apex
 - 1-3% of lung cancer cases
 - generally lack typical symptoms of lung cancer (cough, hemoptysis and dyspnea)
 - neuroblastomas
 - schwannoma of the brachial plexus
 - abnormal pectoralis minor
- osseous
 - cervical rib
 - occur in < 1% of the population
 - arise from the 7th cervical vertebra
 - four types
 - type 1: complete rib that articulates with the first rib or manubrium
 - type 2: incomplete rib with a free distal bulbous tip
 - type 3: incomplete rib with distal attachment via fibrous band
 - type 4: short bar of bone (millimeters) extending beyond the C7 transverse process
 - prominent C7 transverse process
 - abnormal clavicle or first rib
 - acute fracture displacement

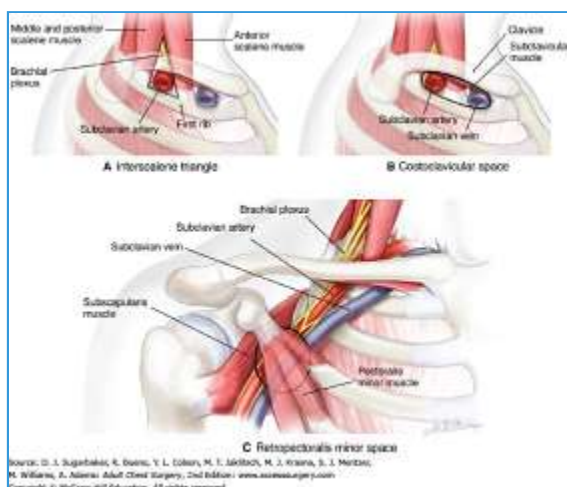
- hypertrophic fracture callus formation
- fracture malunion
- acromioclavicular (AC) or sternoclavicular (SC) joint injury or dislocation
- osseous tumors
 - bone metastasis to first rib
 - breast, prostate, kidney
 - osteoid osteoma
- chronic overuse
 - repetitive shoulder use
 - frequent lifting above the level of the shoulder
 - extreme arm positions, including hyperabduction
 - athletes at risk
 - weight lifting
 - rowing
 - swimming
- vascular
 - repetitive compression over time can result vessel damage
 - aneurysm formation
 - thrombosis
 - embolic events
 - limb-threatening ischemia
- Associated conditions
 - Paget-Schroetter syndrome
 - type of venous thoracic outlet syndrome seen in well-developed young athletes
 - intermittent obstruction of the subclavian vein in the costoclavicular space by
 - abnormal costoclavicular ligament



- anterior scalene muscle hypertrophy
- results in upper extremity deep vein thrombosis

• Anatomy

- Thoracic outlet
 - comprised of three distinct spaces



- interscalene triangle
 - proximal space
 - borders
 - anterior: anterior scalene muscle
 - posterior: middle scalene muscle
 - inferior: first rib

- contents
 - brachial plexus trunks
 - subclavian artery
- subclavian vein does not pass through interscalene triangle
 - runs beneath anterior scalene muscle prior to entering the costoclavicular space
- costoclavicular space
 - middle space
 - separated from the interscalene triangle by the first rib
 - borders
 - anterior: clavicle and subclavius muscle
 - posterior: first rib and scalene muscles
 - medial: costoclavicular ligament
 - lateral: upper scapular border
 - contents
 - brachial plexus divisions
 - subclavian artery and vein
- retropectoralis minor space
 - distal space
 - also known as the thoraco-coraco-pectoral space or subcoracoid space
 - borders
 - superior: coracoid
 - anterior: pectoralis minor muscle
 - posterior: ribs 2-4
 - contents
 - brachial plexus cords
 - axillary artery and vein

• Presentation

○ History

- presentation is very variable
 - ranges from mild pain to sensory changes to severe vascular compromise
 - can be unilateral or bilateral
- neurogenic
 - pain over the neck, trapezius, chest, shoulder and/or arm
 - 92% of patients endorse trapezius pain
 - upper extremity weakness, numbness and paresthesias
 - distribution differs from other compression syndromes
 - nonradicular nature
 - cervical nerve root compression presents with radicular pain
 - wide anatomic distribution (plexus)
 - isolated peripheral nerve compression (cubital tunnel syndrome, carpal tunnel syndrome) presents with a clear dermatomal distribution
 - involves the lower plexus (C8-T1) or combined (C5-T1) in 90% of patients
 - upper extremity paresthesias occur in 98%
 - upper extremity heaviness
 - particularly with overhead activities
 - symptoms can be activity-related and/or occur at night-time
 - night-time symptoms thought to result from decreased pressure on the brachial plexus with return of sensation manifesting as pain
- vascular
 - venous
 - episodic cyanotic discoloration and swelling of the limb
 - distended veins
 - diffuse deep pain in the arm and forearm
 - upper extremity heaviness
 - worse after activity
 - arterial
 - unilateral Raynaud-type symptoms

- episodic coolness and pallor of the limb, followed by cyanosis and ultimately erythema
- worsens in cold temperatures
- pain and numbness
- symptoms tend to predominantly involve the hand (distal circulation)

○ Physical examination

▪ inspection

- note specific postures , can increase loading on the brachial plexus
 - rounded shoulders
 - increased thoracic kyphosis
 - downward rotation or depression of the scapula

▪ skin

- cyanosis, congestion, pallor
- distal ulcerations, signs of microembolic events (rare)
- hair distribution
- nail changes

▪ muscle atrophy

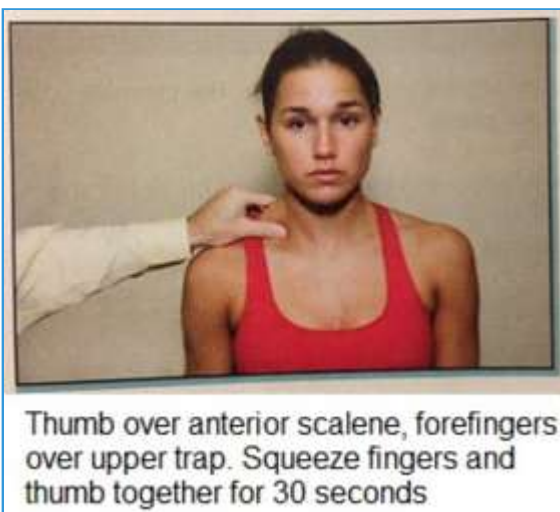- Gilliatt-Sumner hand
 - characteristic finding of neurogenic TOS
 - atrophy of the abductor pollicis brevis (APB), hypothenar muscles and interossei

▪ palpation

- over the supraclavicular area
 - may reveal tenderness and/or masses
- skin temperature

▪ provocative tests

- high rate of false positives
- supraclavicular pressure test
 - evaluates for compression at the interscalene triangle
 - technique



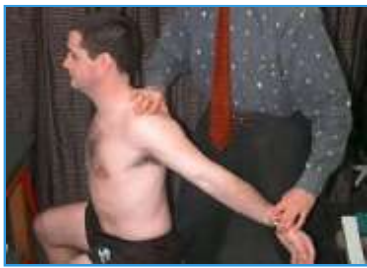- patient seated with arm resting at side
- apply pressure to upper trapezius and anterior scalene muscle, squeezing for 30 seconds
- positive result
 - reproduction of pain or paresthesias

▪ Adson test

- evaluates for compression at the interscalene triangle
- technique
 - patient seated with shoulder slightly abducted and externally rotated, elbow extended, forearm supinated
 - examiner palpates radial pulse
 - patient maximally extends and laterally rotates the neck towards side being tested, then inhales and holds breath
- positive result
 - reduction in amplitude or loss of radial pulse
 - 51% of normal population has diminished pulse with this maneuver
 - reproduction of pain or paresthesias

▪ costoclavicular maneuver

- evaluates for compression at the costoclavicular space
- technique



- patient seated with the arm at the side, elbow extended, forearm supinated
- examiner palpates radial pulse
- patient retracts and depresses the bilateral shoulders, protruding the chest anteriorly and superiorly ("at attention" stance)
 - examiner extends the shoulder $\sim 30^\circ$ for 1 minute
- positive result
 - reduction in amplitude or loss of radial pulse
 - reproduction of pain or paresthesias
- Wright test
 - evaluates for compression at the retropectoralis minor space
 - technique
 - patient seated with arm at the side, elbow extended, forearm supinated
 - examiner palpates radial pulse
 - patient laterally rotates neck away from side being test
 - examiner externally rotates and maximally abducts the shoulder, holding the arm above the level of the head for 1 minute
 - positive result
 - reduction in amplitude or loss of radial pulse
 - 7% of the normal population has diminished or lost radial pulse with this maneuver
 - reproduction of pain or paresthesias
- Roos test / elevated arm stress test
 - evaluates the entire thoracic outlet
 - technique
 - in seated position, patient abducts the bilateral shoulders to 90° with the elbow flexed 90°
 - patient opens and closes the hands for 3 minutes
 - positive result
 - reproduction of pain or paresthesias
 - will often prevent the patient from completing the test for the full 3 minutes
 - normal person have discomfort with this maneuver, but are able to complete it
 - resolution of pain or paresthesias with dropping of the arms
- Cyriax release test
 - evaluates the result of unloading the brachial plexus
 - technique



- examiner stands behind patient and grasps the bilateral forearms with the elbows in flexion and forearms in pronation
- examiner leans against the patient's trunk to passively elevate the shoulder girdle for 3 minutes
- positive result
 - reproduction of pain or paresthesias

• Evaluation

- Radiographs
 - recommended views
 - chest radiograph and cervical spine radiographs
 - findings
 - cervical rib
 - prominent C7 transverse process

- low lying shoulder girdle
 - Pancoast tumor
- CT
 - indications
 - identify osseous space-occupying lesions
 - evaluate malunited fractures of the ribs or clavicle
- MRI
 - indications
 - evaluate for soft tissue anatomic anomalies
- Nerve conduction studies
 - EMG and NCV
 - historically thought to be equivocal and unhelpful
 - studies were often normal unless significant permanent nerve damage was already established
 - recently discovered that nerve fibers from C8 and T1 may show early changes in neurogenic TOS
 - abnormal nerve conduction velocities in the medial antebrachial cutaneous nerve and median motor nerve to the abductor pollicis brevis
- Vascular studies
 - doppler ultrasound
 - helpful for evaluating subclavian vein for obstruction or thrombosis
 - 92% specificity and 95% sensitivity for diagnosis of venous TOS
 - angiography
 - CT or MR angiography
 - arteriography
 - indicated in cases of embolic disease or suspected arterial aneurysm
 - venography
 - indicated in work up of suspected subclavian or axillary venous thrombosis
- Treatment
 - Nonoperative
 - **activity modification, pain control, physical therapy and modalities**
 - indications
 - first line of treatment
 - technique
 - activity modification to avoid provocative activities
 - limiting repetitive overhead motion
 - changing employment if necessary
 - pain control
 - NSAIDs, muscle relaxants
 - physical therapy
 - core and back strengthening, shoulder girdle strengthening, improving posture and relaxation techniques
 - modalities
 - transcutaneous electrical nerve stimulation
 - outcomes
 - less successful in
 - obese patients
 - patients on worker's compensation
 - patients with double-crush neurologic pathology involving the carpal or cubital tunnels
 - **anterior scalene blocks**
 - indications
 - neurogenic TOS related to scalene muscle contracture
 - technique
 - ultrasound-guided lidocaine or botulinum toxin injections
 - outcomes
 - successful block correlates with 14% higher rate of good surgical outcomes
 - Operative
 - **thoracic outlet decompression**
 - indications
 - symptoms that have failed conservative treatment for 6 months

- progressive muscle atrophy and/or worsening neurologic deficits
- technique
 - decompression includes a combination of the following depending on etiology
 - first rib resection, anterior and middle scalenectomy, neurolysis
 - most common procedure
 - 95% good outcomes
 - isolated scalenectomy
 - indications
 - upper plexus symptoms
 - absence of abnormal bony architecture
 - excessively muscular or obese patients
 - recurrent TOS following prior first rib resection
 - isolated pectoralis minor tenotomy
 - indications
 - neurogenic TOS with symptoms reproducible to the retropectoralis minor space
 - cervical rib resection
 - release of fibromuscular bands
 - costoclavicular ligament resection
 - ORIF of clavicle malunion
- **vascular intervention**
 - indications
 - embolic events
 - stenosis with persistent pain and vascular insufficiency
 - subclavian aneurysm
 - thrombosis with critical ischemia
 - technique indications
 - heparin IV, +/- embolectomy, +/- local thrombectomy, +/- TPA, systemic anticoagulation
 - acute embolic event
 - small vessel embolism - TPA, systemic anticoagulation
 - large / proximal vessel embolism - embolectomy, systemic anticoagulation
 - endovascular stent placement
 - mild stenotic disease
 - vascular resection +/- primary repair, +/- saphenous vein graft, +/- arterial autograft, +/- synthetic graft
 - subclavian aneurysm
 - severe stenosis or thrombosis with critical ischemia
 - vascular bypass
 - chronic emboli with critical ischemia

• Technique

○ Thoracic Outlet Decompression

- approaches
 - transaxillary
 - most commonly used approach
 - pros
 - superior exposure for the first rib resection
 - allows resection of cervical ribs, costoclavicular ligament, fibromuscular bands and scalene muscles
 - access to lower plexus for neurolysis (C7-T1)
 - more cosmetic scar
 - no retraction of neurovascular structures necessary for first rib removal
 - cons
 - risks brachial plexus injury
 - supraclavicular
 - pros
 - superior exposure of upper plexus (upper and middle trunks), scalene muscles, neck of the first rib and vascular structures
 - best approach for isolated scalenectomy and arterial reconstruction
 - allows resection of first rib (but requires significant retraction)
 - cons

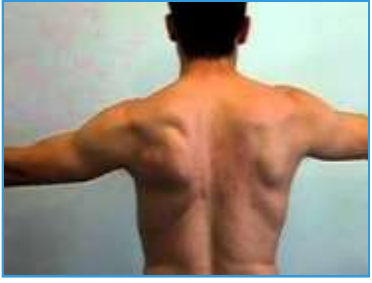- inferior visualization for first rib resection
 - requires retraction of brachial plexus and vascular structures for complete first rib exposure
- posterior
 - pros
 - favored for recurrent TOS and in cases of prior neck surgery
 - may allow better exposure of proximal elements of the brachial plexus
 - cons
 - requires extensive muscle dissection that can lead to postoperative shoulder dysfunction
 - risks injury to the long thoracic, dorsal scapular and accessory nerves
- decompression techniques
 - **first rib resection, anterior and middle scalenectomy, neurolysis**
 - usually performed with combined approach
 - transaxillary: to access first rib and lower plexus
 - supraclavicular: to access anterior and middle scalene muscles and upper plexus
 - specific complications
 - pneumothorax is one of the most common complications of first rib resection

- Complications

- Pneumothorax
 - is one of the most common complications of first rib resection

23- Scapulothoracic Dyskinesia

Images



• summary

- Scapulothoracic dyskinesia is a rare condition characterized by abnormal scapula motion leading to shoulder impingement and dysfunction.
- Diagnosis is clinical with presence of scapulothoracic crepitus with a low and protracted scapula and symptoms being relieved with scapula stabilization.
- Treatment involves NSAIDs and physical therapy with emphasis on periscapular muscle and rotator cuff strengthening.

• Epidemiology

- Demographics
 - seen in athletes (baseball pitchers)

• Etiology

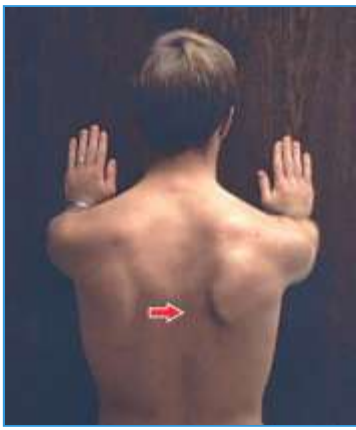- Pathophysiology
 - causes are multifactorial including
 - neurologic injury
 - pathologic thoracic spine kyphosis
 - periscapular muscle fatigue
 - poor throwing mechanics
 - secondary to pain (shoulder, neck)
 - pathoanatomy
 - scapulothoracic power imbalance leads to protraction of scapula
 - leads to alteration of mechanics at glenohumeral joint
 - excessive stress placed on anterior capsule of shoulder and posterosuperior labrum
 - athletes have increased risk of injuring
 - labrum
 - rotator cuff
 - capsule

• Anatomy

- Scapulothoracic joint anatomy

• Presentation

- Symptoms
 - shoulder pain and dysfunction worse with arm elevation
 - loss of throwing velocity
- Physical exam
 - scapulothoracic crepitus
 - affected scapula may be lower and protracted



- symptoms relieved with scapula stabilization

• Imaging

○ Radiographs

- recommended views
 - complete shoulder series
- findings
 - usually unremarkable

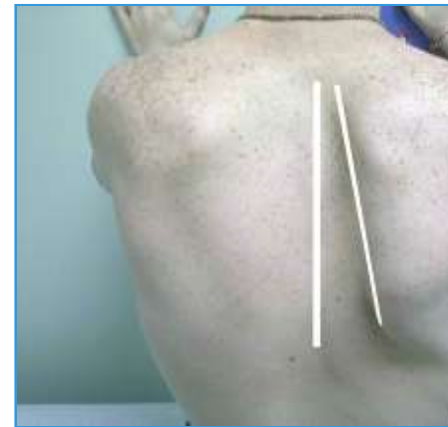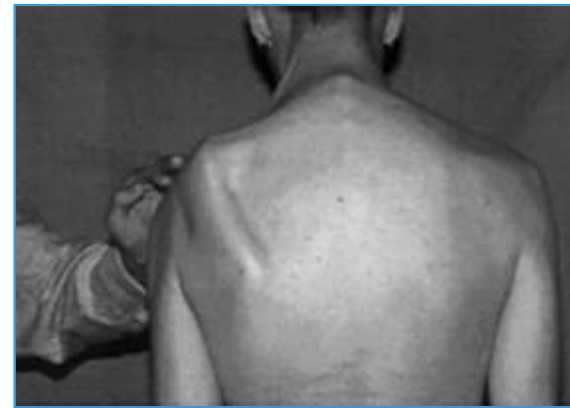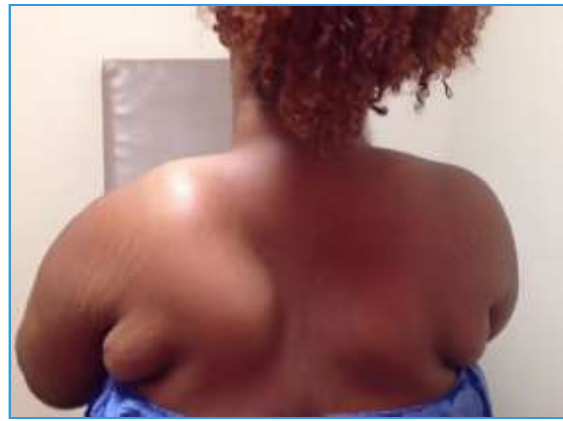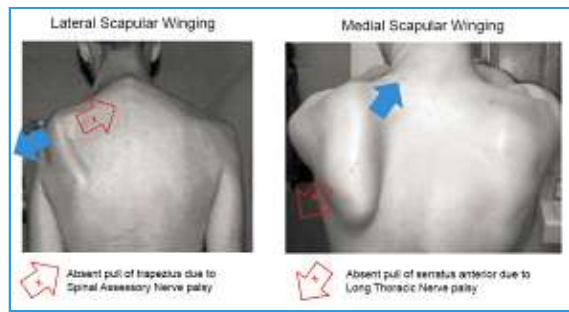
• Treatment

○ Nonoperative

- **NSAIDs, PT, local injections**
 - indications
 - main treatment
 - technique
 - physical therapy with emphasis on
 - core strengthening
 - scapular stabilizers, serratus anterior, trapezius
 - rotator cuff muscles
 - teaching proper core mechanics in throwers

24- Scapular Winging

Images



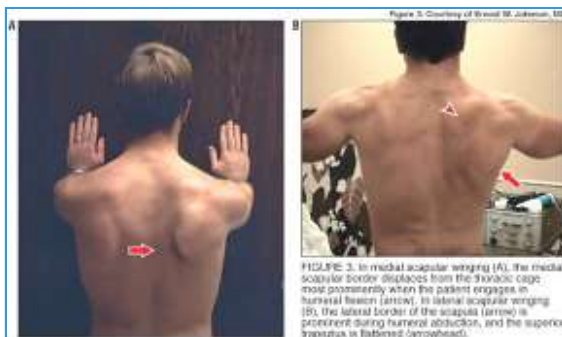summary

- Scapular winging is a dysfunction involving the stabilizing muscles of the scapula resulting in imbalance and abnormal motion of the scapula.
- Diagnosis is made clinically with the presence of excessive medializing scapular retraction (medial winging) or excessive lateralizing scapular protraction (lateral winging).
- Treatment is generally observation, physical therapy and activity modification or operative depending on etiology of winging and presence of identifiable neurological lesion.

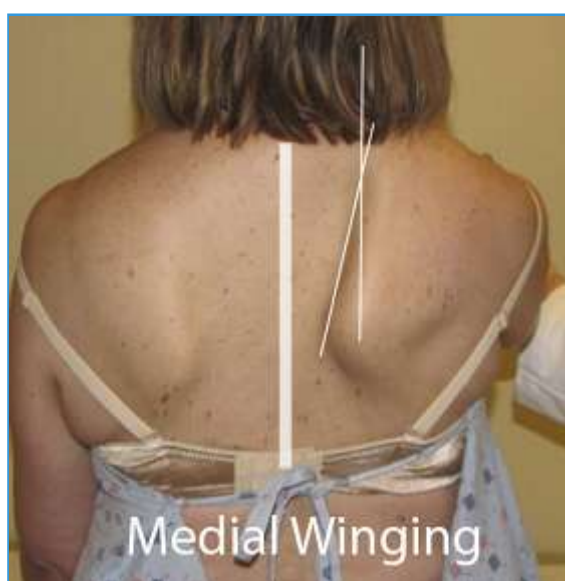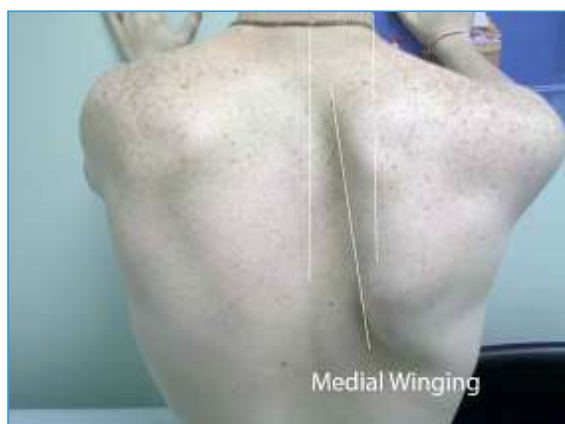Epidemiology

Anatomic location

Types of scapular winging



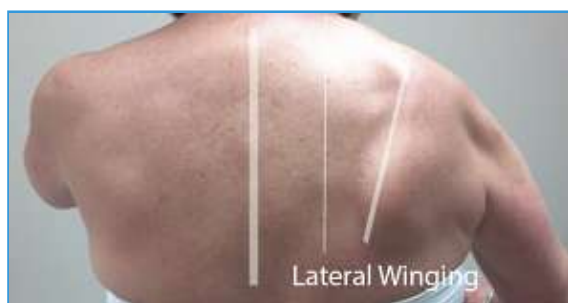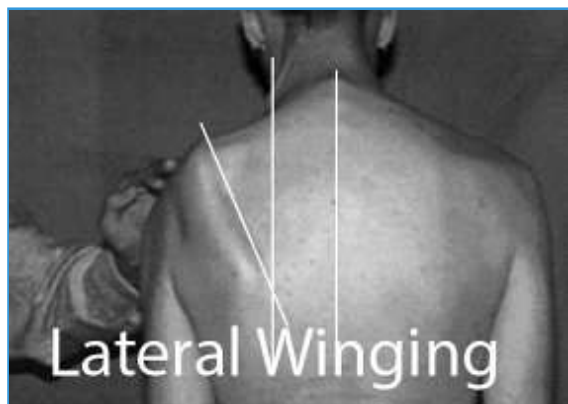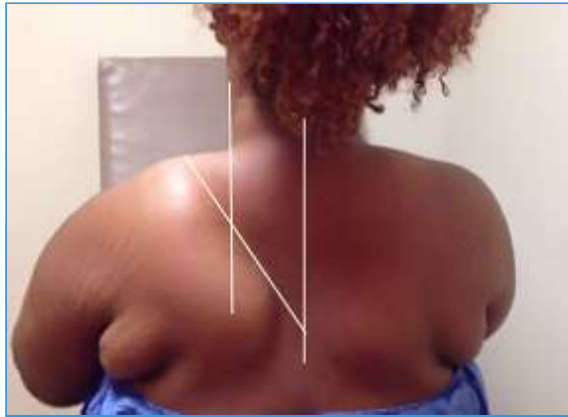- defined by the direction of the superomedial corner of the scapula
- medial scapular winging



etiology

- dysfunction of the serratus anterior (long thoracic nerve)
 - weak protraction of the scapula

- excessive medializing scapular retraction (rhomboid major and minor) and elevation (trapezius)
- epidemiology
 - young athletic patient
 - more common than lateral
- lateral scapular winging

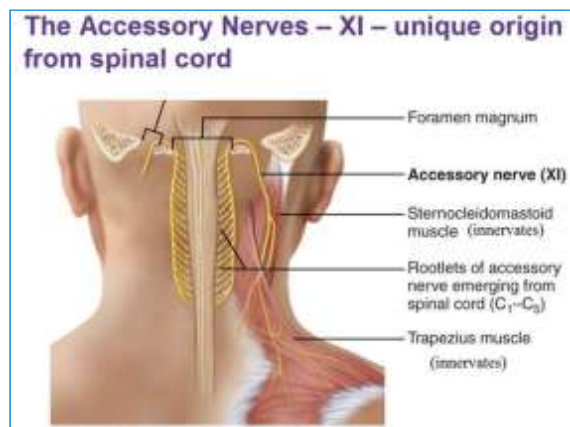


- etiology
 - dysfunction of the trapezius (cranial nerve XI - spinal accessory nerve)
 - weak superior and medializing force on the scapula
 - excessive lateralizing scapular protraction (serratus anterior, pectoralis major and minor)
- epidemiology
 - usually iatrogenic (history of neck surgery)

• Anatomy

- Scapulothoracic articulation
 - not a true joint
 - attached to thorax via ligaments at the acromioclavicular (AC) joint
 - suction mechanism created by serratus anterior and subscapularis holds scapula closely to thorax
 - allows scapular movement against the posterior rib cage
 - contributes to glenohumeral joint positioning and mechanics
- Stabilizing muscles
 - scapula serves as attachment site for 17 muscles
 - function to stabilize scapula to the thorax, provide power to the upper limb and synchronize glenohumeral motion
 - serratus anterior
 - originates from ribs 1-8 and inserts on anteromedial border of scapula
 - total 7-10 slips
 - primary motion is scapular protraction (anterior and lateral motion)
 - innervated by long thoracic nerve
 - ventral rami of C5, C6, C7
 - blood supply
 - superiorly: long thoracic artery
 - inferiorly: thoracodorsal artery branches
 - three parts with different functions
 - upper: downward rotation (glenoid down), stabilizes superior scapula
 - middle: scapular protraction
 - lower: upward rotation and abduction

- trapezius
 - originates from medial third superior nuchal line, external occipital protuberance, nuchal ligament and C7-T12 spinous processes
 - inserts on lateral third clavicle, acromion and scapular spine
 - primary motion is upward rotation and elevation of the scapula
 - innervated by spinal accessory nerve



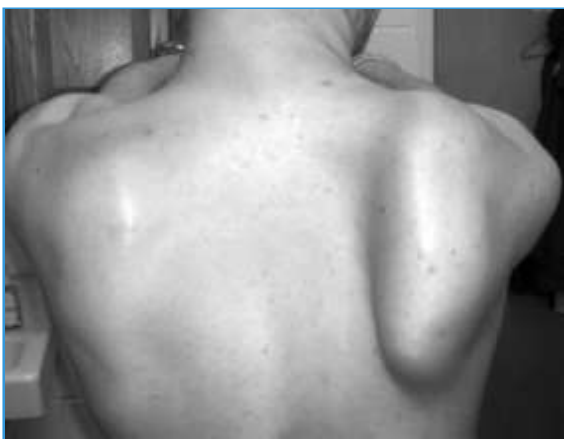- cranial nerve XI
- three parts with different functions
 - upper: upward rotation and elevation
 - middle: scapular retraction and adduction
 - lower: downward rotation and depression
- rhomboid major and rhomboid minor
 - rhomboid major originates from T2-T5 spinous processes and inserts onto medial scapular border, just below insertion of rhomboid minor
 - rhomboid minor originates from C7 and T1 spinous processes and inserts onto medial scapular border, near base of scapular spine
 - primary motion is scapular retraction
 - innervated by dorsal scapular nerve
- levator scapulae
 - originates from C1-C4 transverse processes and inserts onto medial border of scapula at the level of the scapular spine
 - primary motion is elevation of the scapula and downward rotation to tilt the glenoid cavity inferiorly
 - innervated by C3-C4 cervical plexus with contributions from dorsal scapular nerve
- Nerves
 - long thoracic nerve
 - arises from ventral rami of C5, C6 and C7
 - anatomic variations
 - C4 contribution in 13%
 - absence of C7 contribution in 8%
 - travels posterior to the axillary vessels and brachial plexus
 - runs superficially to the serratus anterior, giving branches to each slip
 - crow's foot
 - point where the long thoracic nerve intersects the most dominant and inferior serratus branch of the thoracodorsal artery
 - spinal accessory nerve (cranial nerve XI)
 - spinal and cranial portions join to form the accessory trunk
 - accessory trunk traverses the jugular foramen, crosses laterally over the internal jugular vein to innervate the sternocleidomastoid
 - enters posterior triangle of the neck to innervate the trapezius

• Medial Scapular Winging

- Pathophysiology
 - deficit in serratus anterior function due to injury to the muscle itself or to the long thoracic nerve
 - mechanical
 - traumatic avulsion of the serratus anterior
 - displaced fractures of the inferior pole of the scapula
 - neurologic
 - traction nerve injury
 - > 50% of the cases
 - repetitive stretch injury is most common

- gradual onset of weakness and winging
- increased risk with head tilted away during overhead arm activity, repetitive throwing, prolonged abduction
- weight lifters, volleyball players
- can be acute injury with immediate winging in cases of high-energy trauma (motorcycle accident)
- compressive nerve injury
 - acute
 - blunt trauma to the chest wall, head or neck (contact sports, motor vehicle accidents)
 - sudden depression of the shoulder girdle (fall)
 - chronic
 - sites of compression
 - scalene muscles
 - subcoracoid between coracoid and 1st or 2nd rib (carrying heavy objects on shoulder)
 - inflamed bursae (subcoracoid, subscapular, accessory and supracoracoid)
 - anteroinferior scapular border
- direct nerve injury
 - iatrogenic
 - 10% of patients had prior surgery
 - radical mastectomy / axillary lymph node dissection
 - thoracic surgery
 - chest tube placement for pneumothorax
 - penetrating injury to chest wall
- neuralgic amyotrophy (brachial neuritis)
 - presents with isolated unilateral palsy of the long thoracic nerve in 22%
 - consider in patients without clear traumatic onset and with antecedent immunological insult and/or inflammatory response

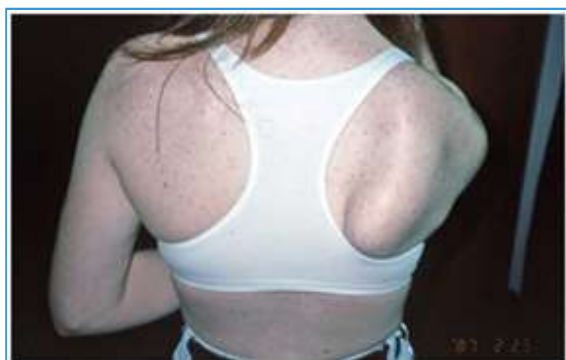○ Presentation



- vague, nonspecific shoulder girdle pain and fatigue
 - base of neck, scapula and deltoid
- muscle spasms
- weakness when lifting away from body and overhead activity
- discomfort sitting against a chair
- may have neurologic symptoms due to traction on brachial plexus
- subjective shoulder instability
 - failure of the scapula to provide a stable platform for rotation of the glenohumeral joint

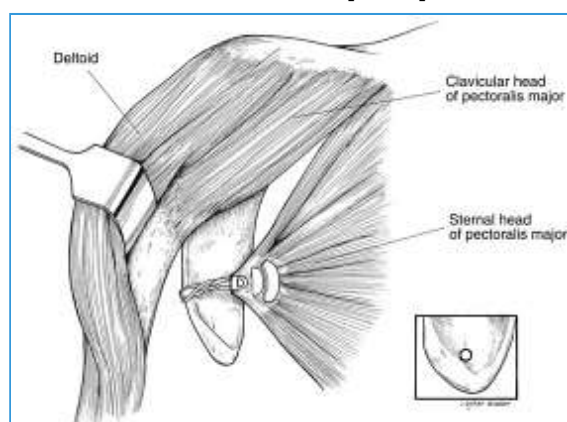
○ Evaluation

- physical examination
 - inferior medial scapula elevates and protrudes posteriorly and medially



- worsened by forward arm flexion
- abduction often limited to 90° or less
- weakness of forward arm flexion and abduction
- wasting of anterior scalene triangle

- due to atrophy of the sternocleidomastoid muscle
 - scapular stabilization
 - manual stabilization of the scapula often improves pain and increases flexion and abduction
 - diagnostic studies
 - electromyography
 - helps assess involvement of long thoracic nerve versus a mechanical cause of winging (serratus anterior avulsion)
- Treatment
 - nonoperative
 - **observation, physical therapy and activity modification**
 - indications
 - observe for a minimum of 6 months , ideally 18 months to 2 years
 - wait for nerve to recover
 - technique
 - physical therapy for serratus anterior strengthening , stretching
 - avoid painful or heavy lifting activities
 - bracing with a modified thoracolumbar brace can be considered
 - poor compliance and little benefit
 - outcomes
 - majority of patients will spontaneously resolve with full return of shoulder function and resolution of winging by 2 years
 - operative
 - **early repair of serratus anterior avulsion**
 - indications
 - mechanical disruption of the serratus anterior muscle (avulsion) and/or its insertion (inferior pole scapula fractures) with symptomatic winging should undergo surgical repair acutely
 - **neurolysis of the long thoracic nerve**
 - indications
 - failure to improve with conservative treatment, at least 6 months
 - electromyography with signs of nerve compression (distal latency, denervation)
 - technique
 - supraclavicular decompression as the nerve traverses the scalene muscles
 - outcomes
 - excellent improvement in pain and resolution of winging in patients who failed nonoperative management (98%)
 - better improvement in shoulder strength (flexion and abduction) compared to muscle transfers
 - **muscle transfer: split pectoralis major transfer**

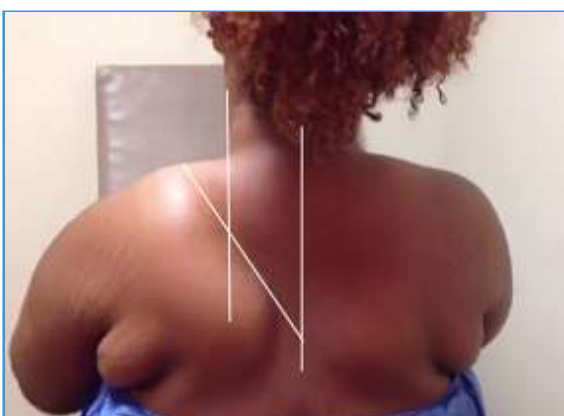

- indications
 - failure to improve with conservative treatment, for 1-2 years
 - pain relief and improved shoulder function with manual scapular stabilization
 - technique
 - split pectoralis major transfer (sternal head)
 - with or without augmentation with a fascia lata or hamstring graft
 - most effective
 - other transfers
 - pectoralis minor transfer
 - rhomboid transfer
 - outcomes
 - predictor of successful surgery is symptom relief and improved function with preoperative manual scapular stabilization

- often have persistent shoulder abduction weakness
- complications
 - failure of pectoralis muscle transfer attachment at scapula
 - unsatisfactory cosmesis (breast asymmetry in women)
 - infection
 - adhesive capsulitis
- **nerve transfer**
 - developing area in the microsurgical field
 - technique
 - lateral branch of the thoracodorsal nerve to the long thoracic nerve
 - medial pectoral nerve with sural nerve graft to the long thoracic nerve
 - outcomes
 - shown to successfully reinnervate the long thoracic nerve
 - benefit of preserving proper muscle biomechanics
- **scapulothoracic fusion**
 - indications
 - scapular winging from diffuse neuromuscular disorders
 - failed muscle transfer surgery
 - often not the first surgical treatment of choice
 - primary goal is pain relief
 - technique
 - fusion of the anterior scapula to the posterior rib cage, with wire cables and/or plates and screws
 - outcomes
 - limited increase in shoulder motion
 - ~20° gain of abduction
 - recent studies show high satisfaction levels in 82% of patients at 5-year follow up
 - complications
 - nonunion
 - pleural effusion
 - adhesive capsulitis
 - symptomatic hardware requiring removal

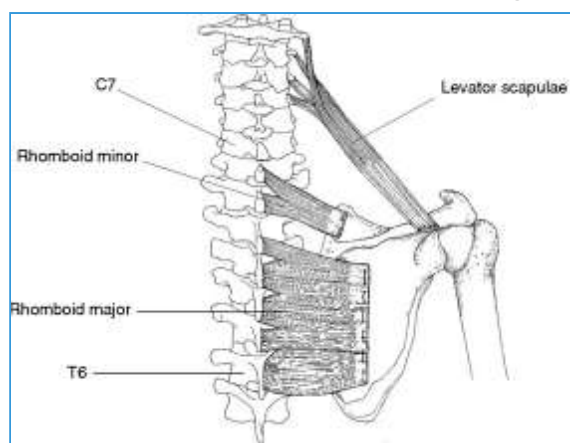
• Lateral Scapular Winging

- Pathophysiology
 - deficit in trapezius function due to injury to the spinal accessory nerve (CN XI)
 - neurologic
 - iatrogenic
 - most common
 - vulnerable in the posterior triangle of the neck
 - cervical lymph node biopsy
 - radical neck dissection
 - traumatic
 - traction injury
 - sudden lateral flexion of the neck (motor vehicle or motorcycle accidents)
 - blunt trauma
 - deep tissue massage
 - penetrating injury to the neck
- Presentation



- similar to medial scapular winging
- vague, nonspecific shoulder girdle pain and fatigue

- muscle spasms
- weakness with overhead activity
- discomfort sitting against a chair
- may have neurologic symptoms from traction on the brachial plexus
- subjective shoulder instability
 - failure of the scapula to provide a stable platform for rotation of the glenohumeral joint
- shoulder impingement
 - inferior translation of the coracoacromial arch as scapula depresses secondary to loss of trapezius
- Evaluation
 - physical examination
 - superior medial scapula drops downward and protrudes posterior and lateral
 - worsened by arm abduction and resisted external rotation
 - shoulder girdle appears depressed or drooping
 - asymmetry or visible atrophy of the ipsilateral trapezius
 - weakness of forward arm flexion and abduction
 - scapular stabilization
 - manual stabilization of the scapula often improves pain
 - diagnostic studies
 - electromyography
 - helps distinguish isolated spinal accessory nerve injury from other more extensive neurologic injuries
- Treatment
 - nonoperative
 - **observation, physical therapy and activity modification**
 - indications
 - the role of conservative management is controversial given that most injuries are iatrogenic direct nerve injuries and warrant surgical intervention
 - elderly and sedentary patients and those without an identifiable injury should be initially treated conservatively
 - outcomes
 - predictors of a poor outcome with conservative management include inability to raise the arm above the shoulder at presentation and dominant extremity involvement
 - operative
 - **exploration of the spinal accessory nerve, neurolysis, repair**
 - indications
 - identifiable nerve injury diagnosed early
 - technique
 - should be performed within 20 months of injury
 - **muscle transfer: Eden-Lange transfer**



- indications
 - nerve injury diagnosed late (> 20 months from injury)
- technique
 - transfer of the levator scapulae and rhomboid muscles from the medial border of the scapula to the lateral border, to effectively reconstruct the trapezius
- **scapulothoracic fusion**
 - see above under Medial Scapular Winging

25- Quadrilateral Space Syndrome

• summary

- Quadrilateral space syndrome is a rare source of posterolateral shoulder pain caused by the compression of the axillary nerve and posterior humeral circumflex artery in the quadrilateral space.
- Diagnosis is clinical with point tenderness over the quadrilateral space and possible presence of teres minor atrophy. MRI studies may show axillary nerve compression.
- Treatment involves a course of NSAIDs, activity modification and physical therapy with surgical decompression indicated in refractory cases.

• Epidemiology

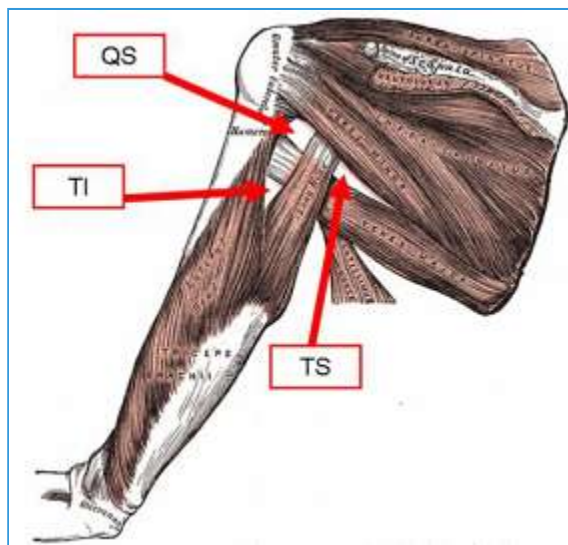
- Incidence
 - rare and often misdiagnosed as subacromial impingement
- Demographics
 - 20-40 years old
- Anatomic location
 - most commonly affects the dominant shoulder
- Risk factors
 - overhead movement athletes (e.g. basketball)
 - contact or throwing sports

• Etiology

- Pathophysiology
 - mechanism of injury
 - compression and reduction of quadrangular space due to
 - iatrogenic (tight fibrous bands, muscular hypertrophy)
 - paralabral cysts (most commonly inferior labral tears)
 - trauma (scapular fracture, shoulder dislocation)
 - benign or malignant masses
 - pathomechanics
 - greatest amount of compression occurs when the arm is positioned in the late cocking phase of throwing (abduction and external rotation)

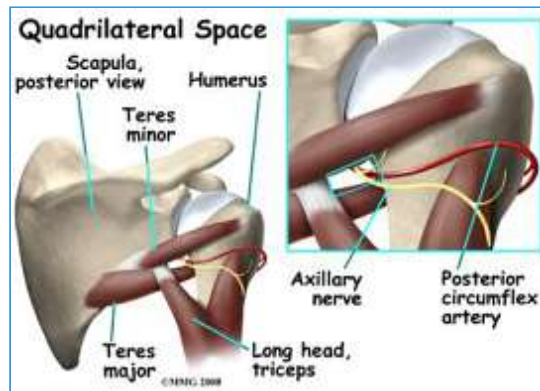
• Anatomy

- Quadrangular space
 - location
 - lateral to triangular space and medial to triangular interval



- boundaries
 - superior - teres minor
 - inferior - teres major
 - medial - long head of triceps brachii
 - lateral - surgical neck of the humerus
- contents

- axillary nerve (C5 nerve root, posterior cord)



- posterior circumflex humeral artery

• Presentation

○ Symptoms

- poorly localized pain of the posterior/lateral shoulder
 - often worse at night
 - worse with overhead activity or late cocking/acceleration phase of throwing
- non-dermatomal distribution of paraesthesia along the lateral shoulder and arm
- shoulder external rotation weakness

○ Physical examination

- inspection
 - may see atrophy of the teres minor and deltoid
- palpation
 - point tenderness over the quadrangular space
- motion and strength
 - external rotation weakness with the arm abducted in throwing position
 - pain exacerbated by active and resisted abduction and external rotation of the arm
- neurological examination
 - usually normal
 - have mild sensory changes in the axillary nerve distribution

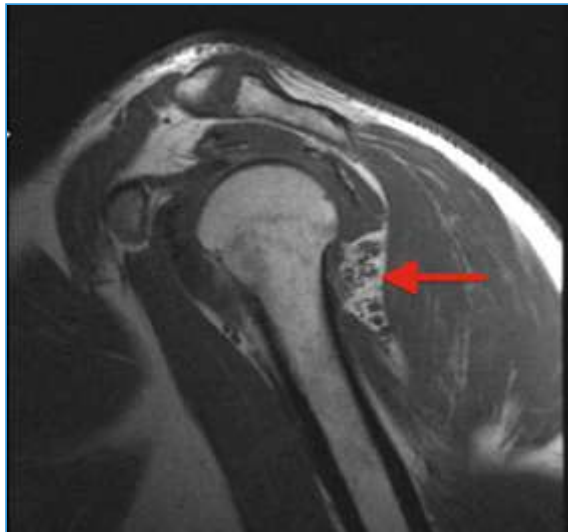
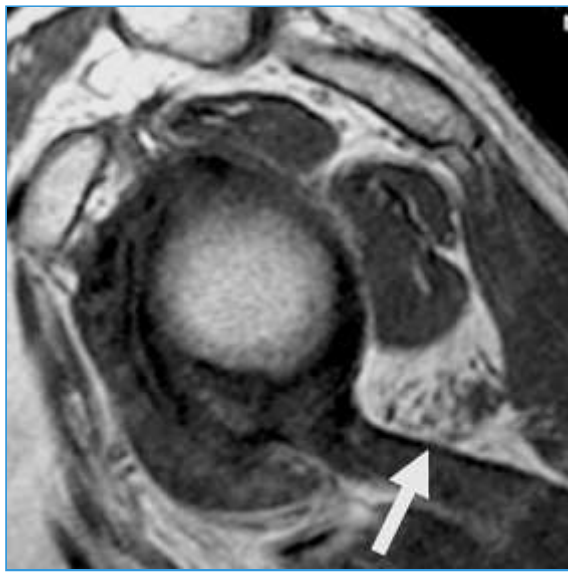
• Imaging

○ Radiographs

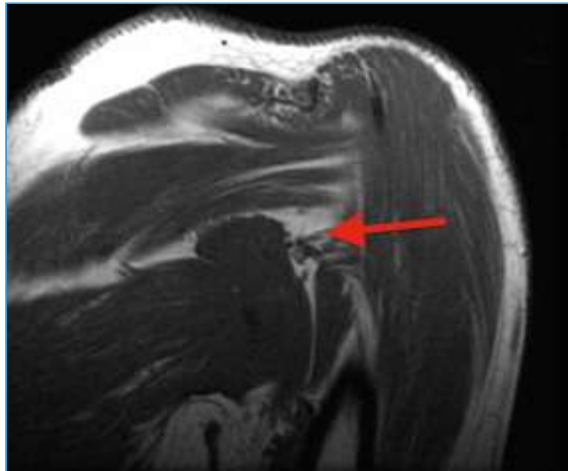
- recommended views
 - shoulder series (AP, lateral, axillary views)
- findings
 - usually normal
 - used to rule out pathologic entities

○ MRI

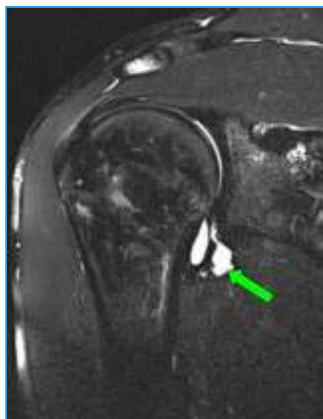
- indications
 - often used to rule out rotator cuff pathology
- findings
 - may show atrophy of teres minor (axillary innervation)



- may show compression of the quadrilateral space



- may show inferior paralabral cyst associated with labral tear



- Arteriogram
 - may show lesion in posterior humeral circumflex artery
- EMG
 - indications
 - used to confirm diagnosis
 - findings
 - will show axillary nerve involvement

• Treatment

- Nonoperative
 - **NSAIDS, activity restriction, physiotherapy**
 - indications
 - first line of treatment
 - techniques
 - glenohumeral joint mobilization and strengthening
 - posterior capsule stretching
 - massage

- outcomes
 - most people improve with 3-6 months of nonoperative treatment
- **diagnostic lidocaine block**
 - indications
 - will help to confirm diagnosis
 - technique
 - inject plain lidocaine directly into the quadrilateral space
 - starting point is 2 to 3 cm inferior to the standard posterior shoulder arthroscopy portal
 - outcomes
 - positive if no point tenderness or pain with full ROM of the shoulder following injection
- Operative
 - **nerve decompression**
 - indications
 - failure of nonoperative management
 - significant weakness and functional disability
 - decompression of space-occupying lesion
 - techniques
 - open release of quadrilateral space +/- arthroscopic repair of labral tear

• Techniques

○ Open Quadrilateral Space Decompression

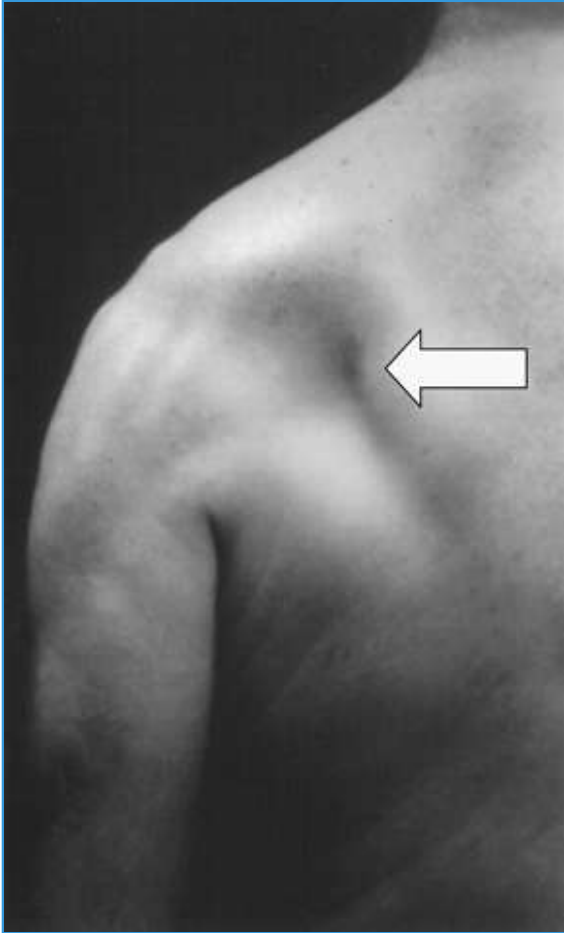
- approach
 - lateral decubitus position
 - 3 - 4 cm incision over the quadrilateral space
 - identify posterior border of deltoid and reflect superolateral
 - expose fat in quadrilateral space between teres minor and teres major
- technique
 - identify the axillary nerve by using the humeral neck as reference
 - avoid cutting the posterior circumflex artery
 - free any fibrous lesions adhering to the nerve
 - ensure the nerve is completely free of compression by moving the arm into abduction and external rotation
- postoperative care
 - immediate sling for comfort
 - early pendulum exercises to avoid new adhesions
 - progress to full active ROM with supervised physiotherapy

• Prognosis

- Long-standing cases often causes atrophy/weakness of teres minor and deltoid

26- Suprascapular Neuropathy

Images



• Summary

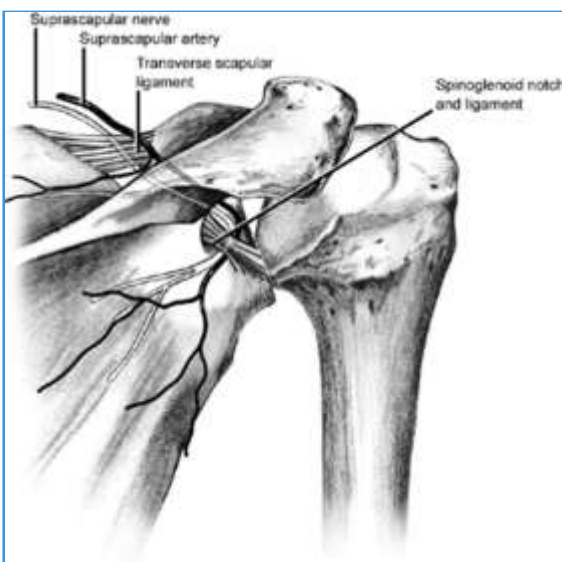
- Suprascapular neuropathy is compression of the suprascapular nerve that most commonly occurs at the suprascapular notch or spinoglenoid notch by a mass (i.e cyst).
- Diagnosis can be suspected clinically with weakness and atrophy of the infraspinatus or supraspinatus and confirmed with MRI studies showing cysts in the suprascapular notch or spinoglenoid notch.
- Treatment of suprascapular nerve compression at the suprascapular notch requires decompression of a cyst when present. Treatment of a spinoglenoid cyst requires either decompression or repair of an associated labral lesion (if present).

• Etology

- Pathophysiology
 - suprascapular notch entrapment
 - weakness of both supraspinatus and infraspinatus
 - spinoglenoid notch entrapment
 - weakness of infraspinatus only
- Associated conditions
 - SLAP tears

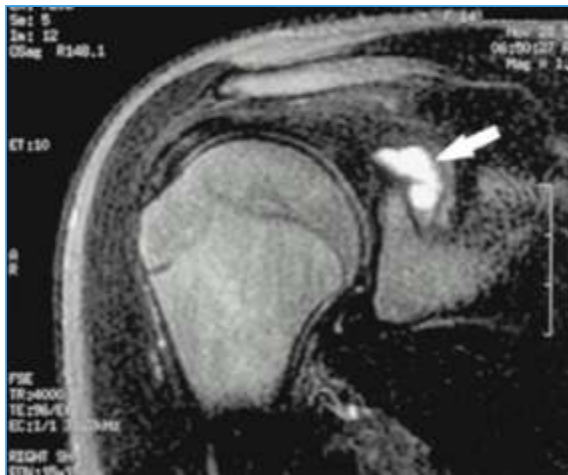• Anatomy

- Suprascapular nerve (C5,C6)



- emerges off superior trunk (C5,C6) of brachial plexus

- travels across posterior triangle of neck to scapula
- innervates
 - supraspinatus
 - infraspinatus
- Suprascapular ligament
 - arises from medial base of coracoid and overlies suprascapular notch
 - suprascapular artery runs above
 - suprascapular nerve runs below
- Spinoglenoid ligament
 - arises near spinoglenoid notch
 - overlies distal suprascapular nerve
- **Suprascapular notch entrapment**
 - Introduction
 - proximal compression of suprascapular nerve in the suprascapular notch
 - leads to weakness of both supraspinatus and infraspinatus
 - Pathoanatomy
 - compression can be from
 - ganglion cyst (often associated with labral tears)
 - transverse scapular ligament entrapment
 - fracture callus
 - Presentation
 - symptoms
 - deep, diffuse, posterolateral shoulder pain
 - physical exam
 - pain with palpation of suprascapular notch
 - weakness of supraspinatus
 - weakness seen with shoulder abduction to 90 degree, 30 degrees forward flexion, and with internal rotation (Jobe test positive)
 - weakness of infraspinatus
 - weakness to external rotation with elbow at side
 - atrophy along the posterior scapula
 - Evaluation
 - MRI
 - important to identify a compressive mass with associated cyst



- EMG/NCV
 - diagnostic
- Treatment
 - nonoperative
 - **activity modification and organized shoulder rehab program**
 - indications
 - no structural lesion seen on MRI
 - technique
 - rehab should be performed for a minimum of 6 months
 - operative
 - **surgical nerve decompression at suprascapular notch**
 - indications
 - structural lesion seen on MRI (cyst)
 - failure of extended nonoperative management (~ 1 year)

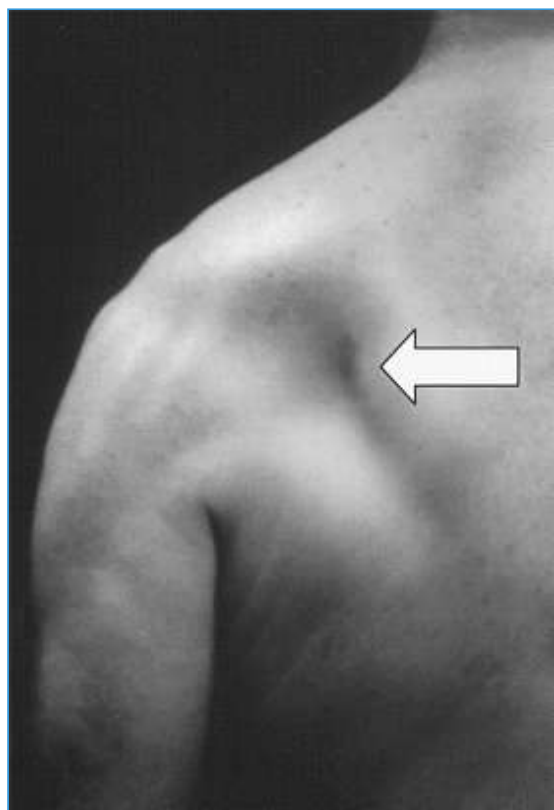- Spinoglenoid notch entrapment

- Introduction

- distal compression of suprascapular nerve
 - affects infraspinatus only
- Pathoanatomy
 - compression can be due to
 - posterior labral tears causing a cyst
 - spinoglenoid ligament
 - spinoglenoid notch ganglion
 - traction injury (seen in 45% of volley ball players)
 - transglenoid fixation
 - lies 1.5cm medial to glenoid labrum

- Presentation

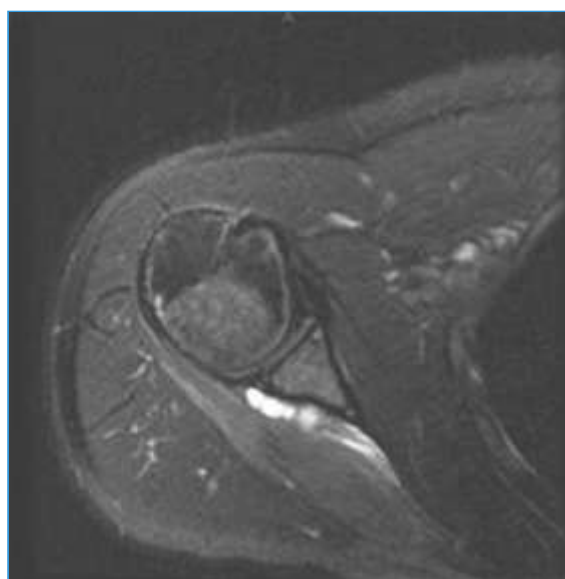
- symptoms
 - deep, diffuse, posterolateral shoulder pain
- physical exam
 - infraspinatus weakness
 - weakness to external rotation with elbow at side
 - infraspinatus atrophy along the posterior scapula



- supraspinatus strength is normal

- Evaluation

- MRI
 - important to identify posterior labral lesions with associated cyst



- EMG/NCV
 - diagnostic

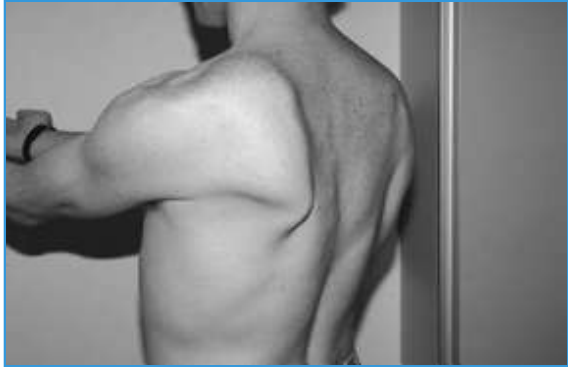- Treatment

- nonoperative
 - **activity modification and organized shoulder rehab program**
 - indications
 - no structural lesion seen on MRI
 - technique

- posterior shoulder capsule stretching
- operative
 - **labral repair with arthroscopic cyst decompression**
 - indications
 - labral lesion with associated cyst seen on MRI
 - **spinoglenoid ligament release with nerve decompression**
 - indications
 - no structural lesion seen on MRI and failure of extended nonoperative management (~ 1 year)
 - technique
 - posterior approach commonly utilized
 - decompress nerve in spinoglenoid notch

27- Brachial Neuritis Parsonage Turner Syndrome

Images



• summary

- Brachial neuritis (Parsonage-Turner syndrome) is an uncommon disorder characterized by severe shoulder pain followed by patchy muscle paralysis and sensory loss involving the shoulder girdle and upper extremity.
- Diagnosis is made clinically with a thorough neurological exam that may vary from moderate motorsensory changes to flaccid paralysis of the upper extremity and can be confirmed by EMG/NCS.
- Treatment is observation and pain control with recovery taking up to 3 years. Operative nerve exploration, neurolysis, nerve transfer or tendon transfer be indicated if there is no evidence of EMG recovery by 9-12 months.

• Epidemiology

- Incidence
 - 1.6-3 cases per 100,000 persons reported per year
 - likely at least 30 cases per year (underdiagnosed)
- Demographics
 - males > females (range 1.5:1 to 11.5:1)
 - middle-age (4th decade)
 - ages 20-60 most common (average age 41), though any age can be affected (range 3-81 years old)
 - unilateral involvement
 - bilateral in 10-30% of patients (16% simultaneously)

• Etiology

- Two clinical types
 - idiopathic neuralgic amyotrophy (INA) (this topic)
 - hereditary neuralgic amyotrophy (HNA) (see associated conditions)
- Various eponyms for this syndrome include:
 - scapular winging (when long thoracic nerve involved)
 - neuralgic amyotrophy (NA) or idiopathic neuralgic amyotrophy (INA)
 - Parsonage-Turner syndrome (PTS)
 - acute brachial neuropathy / neuritis / plexopathy / plexitis
 - idiopathic brachial plexus neuropathy / neuritis
- Pathophysiology
 - pathoanatomy
 - any nerve or branch within the brachial plexus can be involved
 - nerves outside the brachial plexus are affected in 17% of cases
 - nerves most commonly affected
 - long thoracic nerve - can cause scapular winging
 - suprascapular nerve
 - axillary nerve
 - musculocutaneous nerve
 - radial nerve
 - other: cervical roots, anterior interosseous nerve (AIN), posterior interosseous nerve (PIN), lateral antebrachial cutaneous nerve (LABC)
 - pathophysiology

- unclear etiology for idiopathic type, likely multifactorial with autoimmune, genetic, infectious, environmental and biomechanical processes all playing a role
 - autoimmune
 - increased blastogenic activity of lymphocytes
 - transform to larger more active lymphocytes when in contact with brachial plexus tissue
 - increased complement-fixing antibodies to peripheral nerve myelin
 - biomechanical
 - mobility of the upper trunk predisposes to wear-and-tear on the blood-nerve barrier in this region
 - repetitive mobilization of the upper extremity (strenuous exercise, heavy manual labor) may disrupt the blood-nerve barrier that normally prevents immune factors from contacting the peripheral nerve system
 - ultimately, a constellation of processes results in an inflammatory response involving the brachial plexus and its branches
- risk factors
 - infection
 - viral infections (25-55%)
 - Epstein-Barr (EBV), varicella-zoster, Coxsackie B, parvovirus B19, cytomegalovirus (CMV), mumps, smallpox, HIV
 - bacterial infections
 - Leptospira, TB, Yersinia, Salmonella, Borrelia burgdorferi
 - immunizations (15%)
 - Tetanus, hepatitis B
 - stress
 - perioperative and peripartum (14%)
 - strenuous exercise (8%)
 - burns
 - drugs
 - abacavir, streptokinase, heroin, infliximab, interferon
 - iatrogenic
 - interscalene block, surgery, lumbar punctures, irradiation
- Associated conditions
 - hereditary neuralgic amyotrophy (HNA)
 - very rare
 - ~200 families worldwide
 - autosomal dominant
 - mutations in the gene septin 9 on chromosome 17q24
 - cytoskeleton protein highly expressed in glial cells in neuronal tissue
 - differs from idiopathic form by
 - dysmorphic features
 - short stature, hypotelorism, cleft palate, facial asymmetry, unusual skin folds
 - higher incidence of recurrent episodes
 - precipitated similarly to those with INA
 - younger age of onset
 - childhood and adolescent (average age 28)
 - frequent involvement of nerves outside the brachial plexus (56%)
 - most commonly lower cranial nerves (CN VII, IX, X, XI and XII)
 - other: lumbosacral plexus, phrenic and recurrent laryngeal nerves
 - more severe paresis
 - worse functional outcome

- Classification

■ Idiopathic Neuralgic Amyotrophy (INA) vs. Hereditary Neuralgic Amyotrophy (HNA)			
■ <i>Factor</i>	■ <i>INA</i>	■ <i>HNA</i>	
■ Incidence	■ 1-30/100,000/yr	■ Rare	■
■ Gene	■	■ Septin 9 (chromosome 17)	■
■ Age at Onset	■ Middle-age (20-60 y/o)	■ Young (20s)	■
■ Recurrence	■ Uncommon (~1.5 episodes)	■ More frequent (3.5 episodes)	■
■ Appearance	■ Normal features	■ Dysmorphic	■
■ Involvement of Nerves outside Brachial Plexus	■ Uncommon (17%)	■ Common (56%)	■

• Presentation

○ History

- phase I: sudden onset of severe, unrelenting shoulder pain
 - primary symptom in 90% of cases
 - radiates to the proximal arm and/or neck
 - awakens people from sleep
 - lasts days to weeks
 - persists longer in males (45 days vs. 23 days in females)
- phase II: painless flaccid paralysis
 - after the onset of pain, a period of weakness begins within 24 hours (33%) to 4 weeks (80%)
 - most commonly involves the upper brachial plexus and usually more than one nerve branch
 - deltoid, supraspinatus, infraspinatus, serratus anterior and the biceps brachii
 - often will see differential involvement of muscles innervated by the same nerve (patchy paresis)
 - highly characteristic finding
- phase III: slow recovery
 - slow and steady return of motor function over 6-18 months
 - duration over the recovery phase is often directly proportional to duration of pain phase at onset

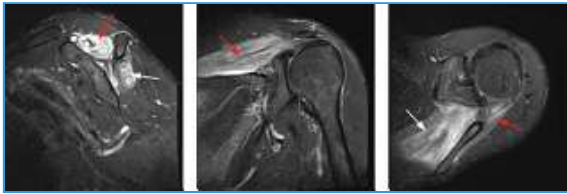
○ Physical examination

- fasciculations and atrophy may be seen
 - signs of denervation
- during the painful phase, the pain is not particularly affected by motion or palpation
- severe weakness of shoulder external rotation and abduction
 - supraspinatus, infraspinatus and deltoid dysfunction
 - hypotonia and areflexia
 - signs of lower motor neuron involvement
- medial scapular winging
 - serratus anterior (long thoracic nerve) involvement
- sensory changes occur in 78% of patients
 - paresthesias and hypoesthesias most common
 - over deltoid, lateral arm and radial forearm
 - may go unnoticed by patient due to overlying pain and weakness
- autonomic dysregulation occur in 15% of patients
 - trophic skin changes
 - temperature dysregulation
 - increased sweating
 - altered nail/hair growth

• Evaluation

- Diagnostic tests can help rule out other conditions and thus support the diagnosis of INA
- Laboratory
 - CBC and ESR are usually normal
 - labs are largely inconclusive, but may show
 - elevated liver enzymes
 - positive antiganglioside antibodies
 - positive antinuclear antibody (ANA) test
- Imaging
 - plain radiographs
 - often normal

- evaluate for calcific tendinitis of the rotator cuff
 - can also present with severe, incapacitating shoulder pain
- magnetic resonance imaging (MRI)



- early findings
 - T2 : diffuse signal hyperintensity (edema) within muscles innervated by the brachial plexus
 - supraspinatus, infraspinatus, deltoid and teres minor muscles most commonly exhibit MRI abnormalities
- late findings
 - T1 : focal intramuscular signal intensity (fatty infiltration) and atrophy of the involved muscles
- Other studies
 - electromyography (EMG)
 - helpful to confirm the diagnosis
 - show findings compatible with INA in 96% of patients
 - findings
 - early (3-4 weeks after symptom onset)
 - acute denervation with positive sharp waves and fibrillation potentials in both peripheral nerve and nerve root distributions
 - late (3-4 months after symptom onset)
 - chronic denervation and early reinnervation with polyphasic motor unit potentials
 - sensory nerve conduction studies (NCS)
 - less useful than EMG
 - findings
 - reduced amplitude, preserved conduction velocity and distal latency
 - may be normal
 - normal NCS does not preclude diagnosis of INA
 - cerebrospinal fluid (CSF) analysis
 - findings
 - usually normal
 - mildly elevated protein levels, slight pleocytosis and oligoclonal bands have been reported

• Differential

- Cervical spine radiculopathy
 - pain and weakness follows a specific nerve root distribution
 - INA involves multiple nerve roots and peripheral nerve distributions
 - starts in the neck and radiates down the arm
 - INA involves the shoulder and occasionally radiates to the neck and proximal arm
 - pain is aggravated by movement
 - in the acute pain phase, motion does not tend to worsen pain
- Rotator cuff pathology
 - shoulder pain persists despite development of shoulder weakness
 - in INA, shoulder weakness tends to develop after acute pain phase and is often painless
 - impingement signs are often present
 - pain usually resolves or improves with subacromial lidocaine injection
 - subacromial lidocaine injection does not affect INA pain, as the pain is neuropathic and not related to impingement
- Entrapment neuropathy
 - shoulder pain with progressive weakness in a specific peripheral nerve distribution (ex. supraspinatus and infraspinatus weakness with suprascapular nerve entrapment)
 - INA usually involves the upper brachial plexus, affecting muscles from multiple peripheral nerve distributions (ex. supraspinatus, infraspinatus, deltoid and biceps weakness)
 - EMG shows involvement of an isolated peripheral nerve
 - EMG in INA shows involvement of nerve roots and peripheral nerves
- Idiopathic hypertrophic brachial neuritis (IHBN)
 - rare disorder characterized by weakness in upper limb muscles and hypertrophy of the brachial plexus
 - brachial plexus hypertrophy can be seen on MRI

- typically painless
 - INA begins with acute painful phase, followed by painless weakness
- EMG and NCS exhibit demyelination (slowed velocity, prolonged distal sensory latencies)
 - NCS in INA shows reduced amplitude related to axonal loss, but preserved conduction velocity and distal sensory latencies (no demyelination)

• Treatment

○ Nonoperative

▪ **observation and pain control**

- indications
 - mainstay of treatment
- technique
 - during the early pain phase, pain control is paramount
 - NSAIDs
 - judicious use of narcotic medications
 - immobilization
 - oral corticosteroids (see below)
- follow patients monthly for improvement
 - can use both physical exam and serial EMGs to follow neurologic recovery
- outcomes
 - at 1 year, observation alone results in similar functional outcomes compared to observation with physical therapy
 - prognosis is good with most patients making a complete recovery, but progress is slow
 - at 1 year, only 35% of patients have recovered
 - at 3 years, 90% of patients have recovered full muscle strength and function with no residual pain or deficits

▪ **physical therapy**

- indications
 - once severe pain has abated and weakness is the primary issue
- technique
 - shoulder girdle strengthening and range of motion
 - pain relief strategies to alleviate traction on the involved nerves
- outcomes
 - reverses atrophy and improves muscle bulk comparable to contralateral unaffected side

▪ **oral corticosteroids**

- indications
 - severe pain during early pain phase
- technique
 - two week course of 1mg/kg/day of prednisone followed by a two week taper
- outcomes
 - some evidence that this regimen may lead to a more rapid resolution of the pain phase, but does not affect the progression or prognosis

○ Operative

▪ **nerve exploration, neurolysis, neurorrhaphy, nerve grafting, nerve transfer or muscle/tendon transfers**

- indications
 - no evidence of regeneration or early recovery in a nerve distribution by 6-9 months on physical examination and EMG studies
- technique
 - neurolysis
 - long thoracic nerve microneurolysis
 - ulnar nerve transposition, Guyon canal release
 - radial tunnel release
 - carpal tunnel release
 - neurorrhaphy and nerve grafting
 - excision of diseased nerve segment and either direct repair (neurorrhaphy) or nerve grafting
 - nerve transfers
 - muscle / tendon transfers
 - split pectoralis major transfer for serratus anterior paralysis

- outcomes
 - surgical exploration of patients with INA without neurologic recovery revealed hourglass-like constrictions in the peripheral nerves with no external compression
 - neurolysis alone was superior to neurorrhaphy and nerve grafting

- Prognosis

- Recurrence is rare in non-hereditary cases
- Factors associated with poor prognosis
 - female gender
 - lower trunk involvement
 - upper trunk has best prognosis
 - persistent pain and no motor function recovery by 3 months
 - hereditary cases
- Age has no effect on prognosis
- Timing of recovery
 - 66% have recovery of motor function within 1 month
 - recovery rated "excellent" in 36% at 1 year, 75% at 2 years and 89% at 3 years
 - may take up to 8 years for full recovery of strength

28- Pectoralis Major Rupture

• SUMMARY

- A rare acute injury caused by avulsion of the pectoralis major tendon and usually seen in weightlifters.
- Diagnosis is generally made clinically and is confirmed with MRI studies.
- Treatment is usually surgical repair when presenting acutely.

• Epidemiology

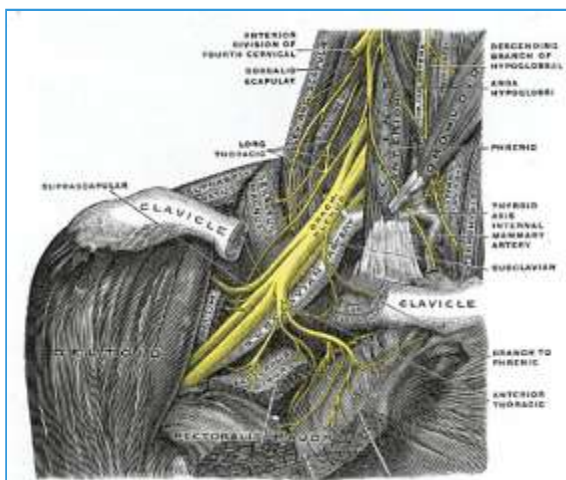
- Incidence
 - rare injury (< 1 per 100,000 per year) that is increasing in incidence
 - 75% of all reported cases have occurred since 1990
- Demographics
 - almost exclusively seen in males (20-40 years of age)
 - often occurs in weightlifters
 - commonly during bench-pressing
- Location
 - most commonly occurs as a tendinous avulsion
 - sternocostal head insertion of the pectoralis major tendon is the most common site of rupture
- Risk factors
 - anabolic steroid use

• Etiology

- Pathophysiology
 - mechanism
 - excessive tension on a maximally eccentrically contracted muscle
 - occurs during the downward portion of a bench press, with the arm in the final 30 degrees of humeral extension while pushing against heavy resistance
 - tendon fails in a predictable sequence
 - inferior fibers of sternocostal head fail first
 - then superior fibers of the sternocostal head
 - finally the clavicular head

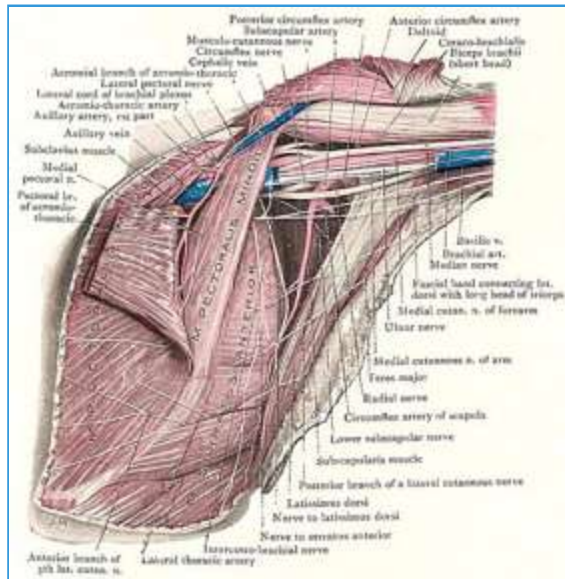
• Anatomy

- Pectoralis major
 - innervation
 - lateral pectoral nerve (C5-C7)



- supplies clavicular head and upper portion of sternocostal head
- medial pectoral nerve (C8-T1)
 - supplies the lower portion of the sternocostal head
- origin (two heads)
 - clavicular head
 - from medial clavicle and proximal sternum
 - sternocostal head
 - from distal sternum, costal cartilage ribs 1-6, external oblique aponeurosis

- sternocostal portion is larger (>80% of muscle volume)
- insertion
 - humeral shaft just lateral to the bicipital groove
- action
 - shoulder adduction and internal rotation, to a lesser extent forward flexion (chiefly the clavicular head)
- other
 - one of four muscles connecting the upper limb to the thoracic wall



- other muscles include
 - pectoralis minor
 - subclavius
 - serratus anterior

○ Biomechanics

- inferior fibers of sternal head at maximal stretch during final 30 degrees of humeral extension
 - position at which pectoralis major is most vulnerable to rupture (as with bench pressing)

• Classification

<ul style="list-style-type: none"> Modified Tietjen (Anatomic) Classification 		
Type	Description	
I	Muscle contusion or sprain	
II	Partial tear	
III	Complete tear (further subclassified by location)	
Location		
III-A	Muscle origin	
III-B	Muscle belly	
III-C	Musculotendinous junction	
III-D	Intra-tendinous rupture	
III-E	Tendon avulsion off humerus (no bone)	
III-F	Bony tendon avulsion off humerus	

- Presentation

- History

- patient may report a sudden pop or tearing sensation with resisted adduction and internal rotation

- Symptoms

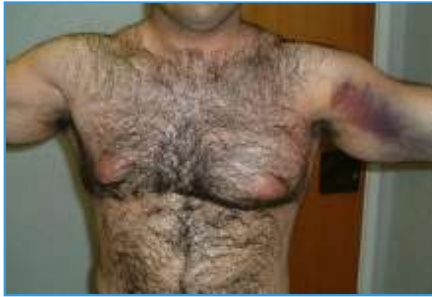- pain and weakness of shoulder

- Physical exam

- inspection & palpation

- swelling and ecchymosis of anterolateral chest wall and/or proximal medial brachium

- if localized to the anterior brachium, then humeral attachment rupture is more likely than a musculotendinous junction rupture



- "dropped nipple" sign
 - ipsilateral nipple will appear lower than the unaffected side due to medial retraction of muscle belly
- palpable defect and loss of anterior axillary contour
 - accentuated by resisted adduction
- motion & strength
 - weakness most pronounced in adduction and internal rotation
 - to a lesser extent forward flexion

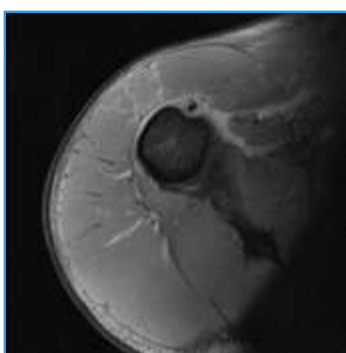
• Imaging

○ Radiographs

- indications
 - limited utility
- recommended views
 - standard shoulder trauma series (true AP , scapular Y , and axillary lateral)
- findings
 - most often normal
 - may show loss of pectoralis major shadow or bony avulsion

○ MRI

- indications
 - investigation of choice
 - can differentiate between complete and partial tears
- views
 - requires dedicated sequence (standard shoulder MRI will not capture adequately)
 - T2 sequence better for acute injuries
 - T1 for evaluating chronic injuries
- findings
 - useful in identifying the location and extent of the rupture (partial versus complete)
 - may show avulsion of the pectoralis major tendon from the humerus



- integrity of clavicular head may mask partial rupture of sternocostal head

• Treatment

○ Nonoperative

- **initial sling immobilization, rest, ice, NSAIDs, physical therapy**

- indications
 - low-demand, sedentary, and elderly patients
 - muscle belly tears , low-grade partial ruptures
- outcomes
 - inferior to operative management for young, active individuals
 - cosmetic disfigurement, significant deficit in strength (most pronounced with isokinetic adduction) and peak torque, delayed recovery, poor patient satisfaction, lower return to competitive sports

○ Operative

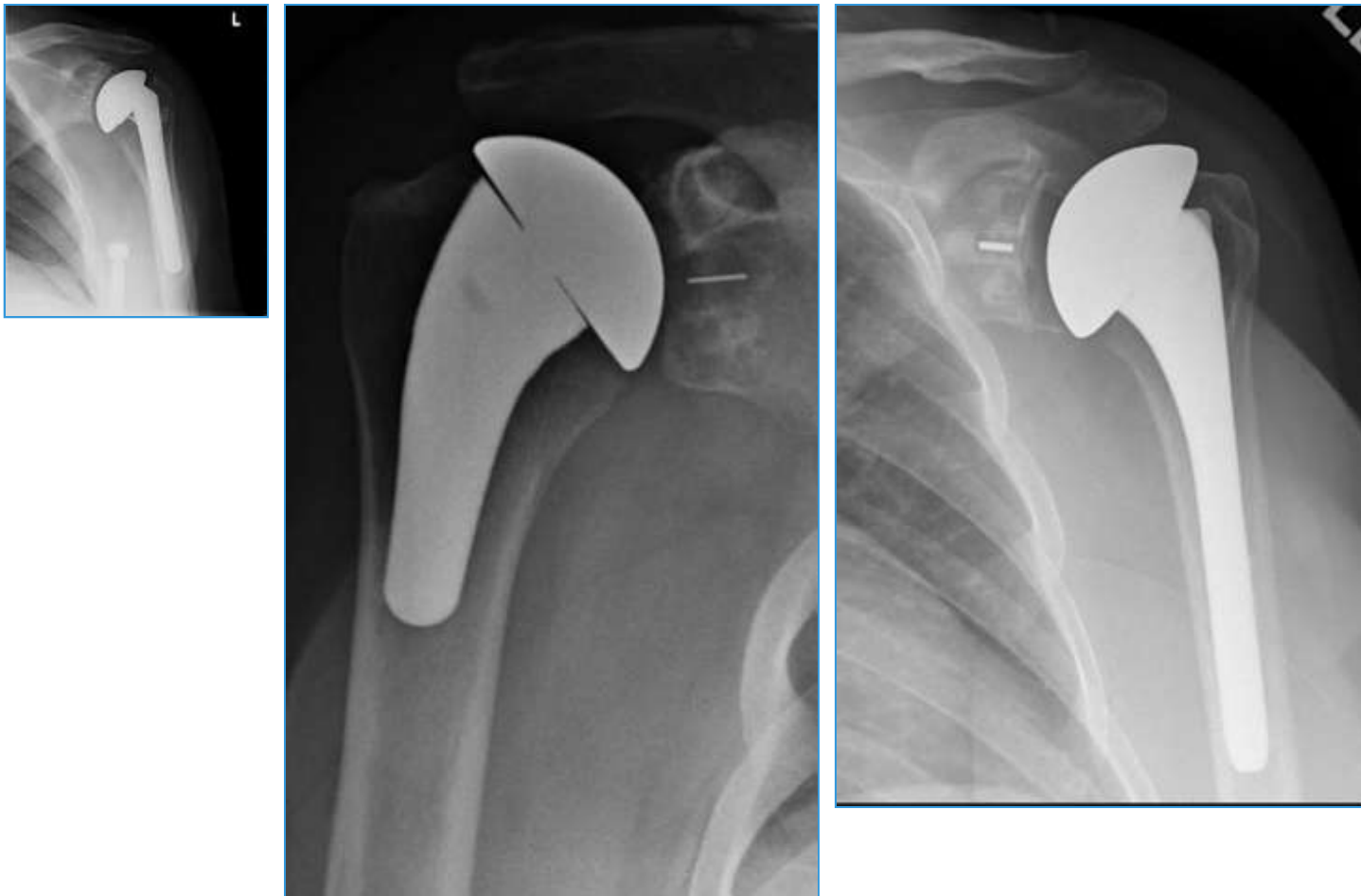
- **open primary repair**

- indications

- gold standard for acute tears in high level athletes, and most young, active patients
 - tendon avulsion, myotendinous junction tears
 - outcomes
 - reliable strength recovery, return to sport, and patient satisfaction
 - may show improvement regardless of location of tear
 - excellent success with all methods
 - **reconstruction**
 - indications
 - chronic tears that cannot be adequately mobilized for primary repair
 - primary repair may still be possible years after the injury
 - persistent strength deficit in chronic tears
 - outcomes
 - reliable strength recovery and patient satisfaction, albeit generally inferior to primary repair
 - still significantly better than nonoperative management in young, active patients
- **Techniques**
 - **Initial sling immobilization, rest, ice, NSAIDs, physical therapy**
 - technique
 - sling in adduction and internal rotation, begin passive range of motion immediately as tolerated
 - active assisted and active motion over the first 6 weeks
 - transition to strengthening and unrestricted activity at 2-3 months
 - **Open primary repair**
 - approach
 - standard deltopectoral approach
 - repair technique
 - all repair techniques have been shown to have comparably excellent success
 - transosseous suture repair with cortical trough
 - cortical button fixation
 - suture anchor repair
 - both PEAK screw and all suture available
 - some evidence suggests that cortical button fixation and transosseous suture repair with cortical trough are superior to suture anchor repair
 - direct repair may be indicated for tears at the muscle belly or myotendinous junction
 - **Reconstruction**
 - approach
 - standard deltopectoral approach
 - mobilization
 - need to release adhesions superficial and deep to pectoralis major
 - careful to avoid injury to the medial and lateral pectoral nerves during deep release
 - supplemental fascial release may be necessary to mobilize the muscle belly in chronic situations
 - graft options
 - Achilles allograft (most common)
 - advantages
 - avoids donor site morbidity, excellent load characteristics, favorable dimensions, and good surgical outcomes reported
 - Gracilis weave (allograft versus autograft)
- **Complications**
 - Re-rupture (5-7%)
 - failure most often occurs at suture-tendon interface
 - Persistent pain
 - incidence
 - most common complication
 - Residual weakness
 - Cosmetic deformity

29- Total Shoulder Arthroplasty

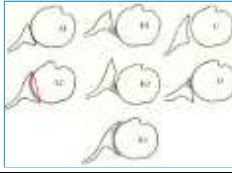

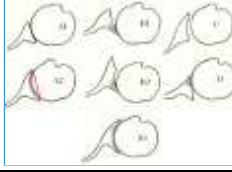

Images



• Introduction

- Replacement of humeral head and glenoid resurfacing
 - cemented all-polyethylene glenoid resurfacing is standard of care
- Total shoulder arthroplasty unique from THA and TKA in that
 - greater range of motion in the shoulder
 - success depends on proper functioning of the soft tissues
 - glenoid is less constrained
 - leads to greater shear stresses and is more susceptible to mechanical loosening
- Factors required for success of TSA
 - rotator cuff intact and functional
 - if rotator cuff is deficient and proximal migration of humerus is seen on x-rays (rotator cuff arthropathy) then glenoid resurfacing is contraindicated
 - if there is an irreparable rotator cuff deficiency then proceed with hemiarthroplasty or a reverse ball prosthesis
 - an isolated supraspinatus tear without retraction can proceed with TSA
 - incidence of full thickness rotator cuff tears in patients getting a TSA is 5% to 10%
 - if positive impingement signs on exam, order a pre-operative MRI
 - glenoid bone stock and version
 - if glenoid is eroded down to coracoid process then glenoid resurfacing is contraindicated
 - see Walch classification below
- Outcomes
 - pain relief most predictive benefit (more predictable than hemiarthroplasty)
 - reliable range of motion
 - good survival at 10 years (93%)
 - good longevity with cemented and press-fit humeral components
 - worse results for post-capsulorrhaphy arthropathy

• Classification

Walch Classification of Glenoid Wear		
<ul style="list-style-type: none"> Type A 	<ul style="list-style-type: none"> Concentric wear, no subluxation of HH, well centered A1 : no or minor central erosion A2 : deeper central erosion, line connects anterior/posterior glenoid rims and transects humeral head (HH) 	
<ul style="list-style-type: none"> Type B 	<ul style="list-style-type: none"> Biconcave glenoid, asymmetric glenoid wear and head subluxated posteriorly B0: pre-osteoarthritic posterior subluxation of HH B1: posterior joint narrowing (no posterior bone loss), osteophytes, subchondral sclerosis B2 : posterior rim erosion, retroverted glenoid B3: mono-concave, posterior wear, at least HH subluxation >70% OR retroversion >15% 	
<ul style="list-style-type: none"> Type C 	<ul style="list-style-type: none"> C1: Glenoid retroversion >25 degrees, regardless of erosion C2: Biconcave, posterior bone loss, posterior translation of HH 	
<ul style="list-style-type: none"> Type D 	<ul style="list-style-type: none"> Glenoid anteversion or anterior HH subluxation (HH subluxation <40%) 	

Indications

Indications

- pain (anterior to posterior), especially at night, and inability to perform activities of daily living
- glenoid chondral wear to bone
 - preferred over hemiarthroplasty for osteoarthritis and inflammatory arthritis
- posterior humeral head subluxation

Contraindications

- insufficient glenoid bone stock
- rotator cuff arthropathy
- deltoid dysfunction
- irreparable rotator cuff (hemiarthroplasty or reverse total shoulder are preferable)
 - risk of loosening of the glenoid prosthesis is high ("rocking horse" phenomenon)
- active infection
- brachial plexus palsy

Preoperative Imaging

Radiographs

- true AP
 - determine extent of arthritis and look for superior migration of humerus
- axillary view
 - look for posterior wear of glenoid

CT scan

- obtain CT scan to determine glenoid version and glenoid bone stock

MRI

- evaluate rotator cuff condition

Approach

Deltopectoral

- detach the subscapularis and capsule from anterior humerus
- dislocate shoulder anteriorly
- tight shoulders may require release of the upper half of the pectoralis tendon to increase exposure and dislocation
 - pectoralis major tendon passes on top of the biceps tendon to attach to the humerus

Complications

- axillary nerve damage is the most common complication
 - axillary nerve and posterior humeral circumflex artery pass beneath the glenohumeral joint in the quadrilateral space

Technical considerations

Capsule

- anterior capsule contracture (passive ER < 40°)

- treatment
 - anterior release and Z-lengthening
 - posterior capsule stretching
 - treatment
 - volume-reducing procedure (plication of posterior capsule)
- Subscapularis
 - no differences in outcomes between subscapularis peel, lesser tuberosity osteotomy, subscapularis tenotomy, partial tenotomy
- Glenoid deficiency and retroversion
 - glenoid deficiency
 - treatment
 - build up with iliac crest autograft or part of the resected humerus
 - do not use cement to build up the deficiency
 - retroverted glenoid
 - treatment
 - build up posterior glenoid with allograft
 - eccentrically ream anterior glenoid
- Glenoid component
 - convex backside superior to flat
 - recreate neutral version
 - peg design is biomechanically superior to keel design
 - polyethylene-backed components superior to metal-backed components
 - glenoid not large enough to accommodate both metal and PE
 - uncemented glenoid has a lower rate of loosening
 - conforming vs. nonconforming
 - both have advantages and neither is superior
 - conforming is more stable but leads to rim stress and radiolucencies
 - nonconforming leads to increased polyethylene wear
- Humeral stem fixation
 - cemented stem or uncemented porous-coated implants
 - position of humeral stem should be 25-45° of retroversion
 - if position of glenoid retroversion is required, then the humeral stem should be less retroverted to avoid posterior dislocation
 - avoid valgus positioning of humeral stem
 - avoid overstuffing the humeral head
 - increases joint reaction forces and tension on the rotator cuff
 - the top of the humeral head should be 5 to 8 mm superior to the top of the greater tuberosity
 - intraoperative humerus fracture
 - greater tuberosity fracture
 - treatment
 - if minimally displaced, insert a standard humeral prosthesis with suture fixation and autogenous cancellous bone grafting of the greater tuberosity fracture
 - humeral shaft fracture
 - treatment
 - remove prosthesis and add longer stem with cement and reinforce with cerclage wiring

- Rehabilitation

- Passive or active-assisted motion only during early rehab
 - limiting factor in early postoperative rehabilitation is risk of injury to the subscapularis tendon repair
- Progress to ER isometrics
- Limit passive external rotation
 - risk of tear and pull-off of subscapularis tendon from anterior humerus
 - tear leads to anterior shoulder instability (most common form of instability after TSA)
 - treatment of subscapularis pull-off is early exploration and repair of tendon
 - test for pull-off of subscapularis
 - weak belly-press test
 - inability to put hand in back pants pockets or tuck shirt behind the back
 - avoid pushing out of chair during acute rehab

- IR eccentric and isometric

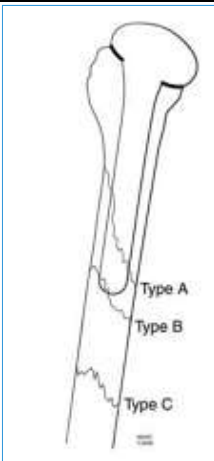
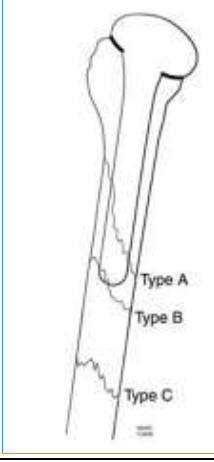
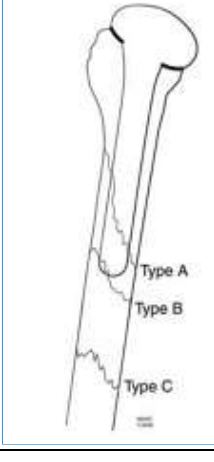
- Complications

- Glenoid loosening
 - most common cause of TSA failure (30% of primary OA revisions)
 - risk factors
 - insufficient glenoid bone stock (posterior glenoid wear associated with glenoid loosening)
 - rotator cuff deficiency
 - 2.9% reoperation rate for loosening (28% with revision)
 - radiographic lines
 - presence of radiographic lines does not correlate with symptoms
 - progression of a radiographic line does correlate with symptoms
 - progression present in 50% of patients as early as 3 to 4 years after TSA
 - radiolucency around the glenoid does not always correlate with clinical failure
 - at 3- and 7-year follow-up did not correlate with poor functional outcomes or pain
- Vascular injury
 - Arcuate artery, branch off the anterior humeral circumflex artery, can be damaged during biceps tendon elevation
- Humeral stem loosening
 - more common in RA and osteonecrosis
 - rule out infection
- Subscapularis repair failure
- Malposition of components
- Improper soft tissue balancing
 - failure due to undiagnosed presence of rotator cuff tears
- Iatrogenic rotator cuff injury/attritional rotator cuff tear
 - can occur if humeral neck osteotomy is inferior to level of rotator cuff insertion
 - overstuffing glenohumeral joint leading to attritional supraspinatus and subscapularis tears
 - common reason for conversion to reverse total shoulder arthroplasty
- Stiffness
- Infection
 - may have normal aspiration results
 - culture
 - arthroscopic tissue culture more sensitive (100% sensitive and specific) than fluoroscopically guided aspiration (17% sensitivity, 100% specific)
 - Propionibacterium acnes (*P. acnes*),
 - now referred to as *Cutibacterium acnes* (*c. acnes*)
 - most common cause of indolent infections and implant failures
 - infection rate 1-2% after primary TSA
 - characteristics
 - gram positive, facultative, aerotolerant, anaerobic rod that ferments lactose to propionic acid
 - has high bacterial burden around the shoulder
 - forms biofilm within 18-90h (found on implant surface and on synovial tissue) >> planktonic (explains why aspiration is only 17% sensitive)
 - *P. acnes* PJI more common in males
 - presentation
 - initial pain & stiffness
 - later swelling & redness
 - diagnosis
 - use anaerobic culture bottles, keep for 10-14days (mean time to detection 6 days)
 - 16s rRNA PCR
 - imaging (XR, CT, ultrasound) positive for subluxation/loosening in 24% of cases
 - if implant is removed, sonicate implant (to dislodge bacteria from surface) for sonication culture
 - treatment
 - early infection (<6 weeks) can be treated with open irrigation and debridement
 - late infection (>6 weeks) should be treated by explant and 2-stage reimplantation after IV antibiotic (penicillin G, ceftriaxone, clindamycin, vanco) x 6wk, followed by 2-6mths of PO antibiotic
- Neurologic injury
 - axillary nerve is most commonly injured

- inferior border of subscapularis tendon can be used as a landmark to identify axillary nerve as it courses from anterior to posterior
- musculocutaneous nerve can be injured by retractor placement under conjoint tendon

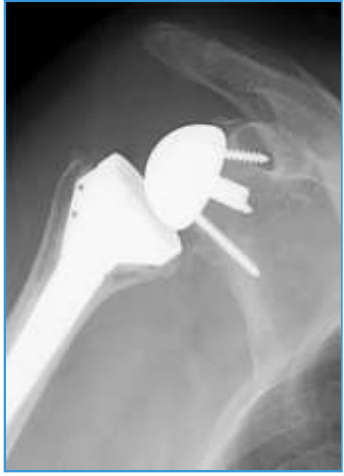○ Periprosthetic fracture

- acceptable fragment alignment $\leq 20^\circ$ flexion/extension, $\leq 30^\circ$ varus/valgus, $\leq 20^\circ$ rotation malalignment
- see table below

■ Wright & Cofield Classification of Periprosthetic fracture				
■ Type	■ Characteristics	■ Treatment of Intraoperative Fracture	■ Treatment of Postop Fracture	■
■ Type A	<ul style="list-style-type: none"> ■ Centered near the tip of the stem and extends proximally 	<ul style="list-style-type: none"> ■ Span fracture with standard length prosthesis (2-3 cortical diameters) or long-stem prosthesis. Transosseous sutures for tuberosity fractures 	<ul style="list-style-type: none"> ■ Usually min displaced/angulated (treat nonop). ■ If significant overlap between prox-distal fragments, treat as if stem loose and revise to long stem prosthesis. 	<ul style="list-style-type: none"> ■ 
■ Type B	<ul style="list-style-type: none"> ■ Centered at the tip of the stem and extends distally. 	<ul style="list-style-type: none"> ■ Span fracture with standard length prosthesis (2-3 cortical diameters) or long-stem prosthesis. ■ Cement in distal canal to engage prosthesis (do NOT let cement escape from fracture site). ■ Cortical strut allograft + cerclage. 	<ul style="list-style-type: none"> ■ Revise to long-stem prosthesis. ■ Cement in distal canal to engage prosthesis 	<ul style="list-style-type: none"> ■ 
■ Type C	<ul style="list-style-type: none"> ■ Located distal to the tip of the stem. 	<ul style="list-style-type: none"> ■ Long-stem prosthesis, or if close to olecranon fossa, plate+screws± cerclage wire, strut allograft 	<ul style="list-style-type: none"> ■ ORIF (plate overlap prosthesis by 2 cortical diameters to avoid stress riser) 	<ul style="list-style-type: none"> ■ 

30- Reverse Shoulder Arthroplasty

Images



• Summary

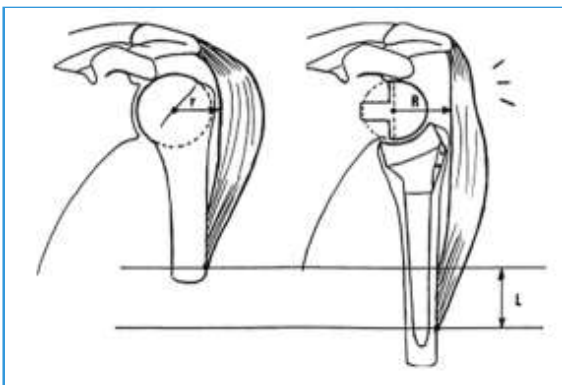
- Reverse Shoulder Arthroplasty is a type of shoulder arthroplasty that uses a convex glenoid hemispheric ball and a concave humerus articulating cup to reconstruct the glenohumeral joint.
- The center of rotation is moved inferiorly and medialized which allows the deltoid muscle to act on a longer fulcrum and have more mechanical advantage.
- Reverse Shoulder Arthroplasty is indicated for conditions such as rotator cuff tear arthropathy, comminuted 4-part proximal humerus fractures and prior failed shoulder arthroplasty.

• Epidemiology

- Epidemiology
 - popularized in Europe and now increasingly used in North America since 1990

• Biomechanics

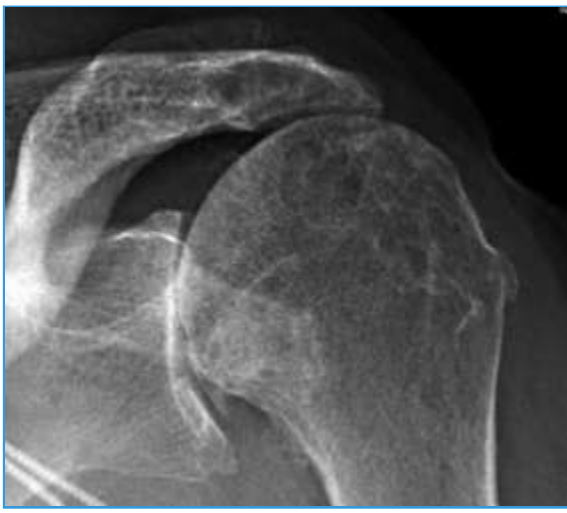
- The advantage of a reverse shoulder arthroplasty is that the center of rotation (COR) is moved inferiorly and medialized



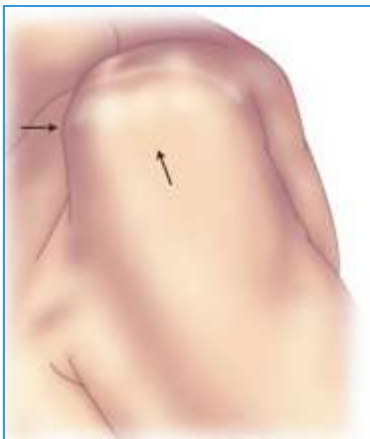
- allows the deltoid muscle to act on a longer fulcrum and have more mechanical advantage to substitute for the deficient rotator cuff muscles to provide shoulder abduction
 - allows increased (but not normal) shoulder abduction
 - does not significantly help shoulder internal or external rotation
- Reverse shoulder arthroplasty can be combined with latissimus dorsi transfer to assist with external rotation

• Indications

- Clinical conditions
 - cuff-tear arthropathy



- severe glenohumeral joint arthritis with superior escape in the setting of a massive rotator cuff tear
- pseudoparalysis
 - an inability to actively elevate the arm in the presence of free passive ROM and in the absence of a neurologic lesion
 - occurs secondary to irreparable rotator cuff tear in setting of glenohumeral arthritis
- antero-superior escape



- incompetent coracoacromial arch
- humeral "escape" in subcutaneous tissue with hemiarthroplasty
- proximal humerus fractures in the elderly
 - 3 or 4-part fractures in patients age > 70
 - head-splitting fractures
 - significant osteopenia or poor bone quality
 - where GT has poor potential for healing
- rotator cuff insufficiency 'equivalent'
 - non-union or mal-union of the tuberosity following trauma or prior arthroplasty
- failed arthroplasty
 - in setting of prior HA or aTSA with cuff insufficiency
 - when all other options have been exhausted
- rheumatoid arthritis
 - only if glenoid bone stock is sufficient
- Patient characteristics (in clinical conditions above)
 - low functional demand patients
 - physiological age >70
 - sufficient glenoid bone stock
 - working deltoid muscle
 - intact axillary nerve

• Contraindications

- Axillary nerve dysfunction
 - important to separate permanent from temporary
- Deltoid deficiency
 - global deficiency is a contraindication
 - partial deltoid deficiency is a relative contraindication but RSA may give reasonable results
- Acromion deficiency
- Glenoid osteoporosis
- Active infection

• Operative Planning

- Radiographs

- recommended views
 - true AP (Grashey)
 - determine extent of arthritis and look for superior migration of humerus
 - axillary lateral
 - look for posterior glenoid wear
 - scapular-Y
 - CT scan
 - indications
 - If unable to obtain an adequate axillary lateral, CT can be useful to determine glenoid version and glenoid bone stock
 - estimate degree of osteopenia
 - MRI
 - indications
 - evaluate rotator cuff integrity and fatty infiltration
- Approach
 - Deltopectoral
 - advantages:
 - preserves deltoid muscle
 - exposure of the lower pole of the glenoid to facilitate glenoid implant positioning
 - can extend inferiorly for increase exposure to proximal humerus if needed
 - can perform a simultaneous latissimus dorsi transfer if needed
 - decreased risk of axillary nerve palsy
 - disadvantages
 - need to take-down subscapularis for adequate exposure
 - need for extensive capsular release which may lead to instability
 - lack of exposure to posterior glenoid
 - potential for stiffness given immobilization required for subscapularis healing
 - Anterosuperior
 - method
 - the anterior deltoid is divided from the anterior edge of the acromioclavicular arch, allowing increased glenoid exposure.
 - advantages
 - increased glenoid exposure
 - able to preserve subscapularis
 - decreased post-operative instability due to preservation of anterior stabilizers
 - ease of axial preparation of the humerus
 - easier fixation of greater tuberosity for fractures
 - disadvantages
 - increased risk of injury to distal branches of axillary nerve
 - violates anterior deltoid muscle
 - risk of excess height or superior tilt of glenoid
- Techniques
 - **Humeral preparation**
 - humeral head typically osteotomized anywhere between 0 and 30 degrees of retroversion (typically 20)
 - more retroversion is gaining popularity as it may improve post-op external rotation
 - humeral head can be saved for autograft if needed
 - osteotomy generally not needed in setting of fracture
 - long head of biceps is tenotomized or tenodesed
 - ream and broach humerus similar to conventional TSA
 - the humeral height and version typically judged by humeral calcar or tuberosity fragment
 - if calcar missing in the setting of fracture, height can be judged by pectoralis insertion which resides 5.6 cm from top of fractured humeral head
 - **Glenoid preparation**
 - labrum is excised and capsule is released circumferentially
 - important to expose inferior glenoid by subperiosteally elevating tissue to ensure proper baseplate positioning
 - accurate central guidewire placement is dictated by availability of the best bone stock for baseplate screw fixation

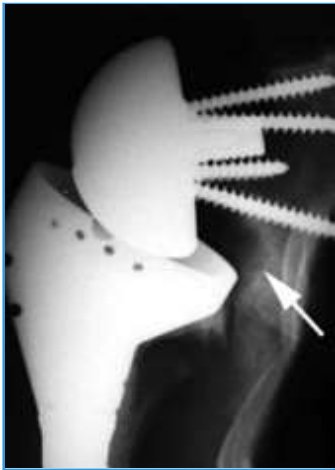- place baseplate as inferiorly as possible with an inferior tilt
 - shown to decrease implant loosening and scapular notching
 - navigation systems increasingly used for accurate baseplate placement
- superior screw is generally aimed toward coracoid base and inferior screw aimed towards scapular body
- mount glenosphere onto baseplate
 - size chosen based on patient size, motion and preservation of stability
 - females/smaller patients typically receive a 36 mm and large men receive a 40 mm.
- **Tuberosity repair**
 - anatomic repair of the greater tuberosity is associated with improved shoulder external rotation, function and patient satisfaction compared to tuberosity resection or malunion

• Rehabilitation

- Immediate
 - patient placed in sling post-op
- Early rehab
 - passive or active-assisted motion only during early rehab
- Sling discontinued at 3 weeks if subscapularis is NOT repaired, and 6 weeks if subscapularis is repaired
 - limit passive ER or active IR during this time
 - avoid pushing out of chair during acute rehab
 - subscapularis re-tear would lead to anterior shoulder instability
 - treatment
 - early exploration and repair

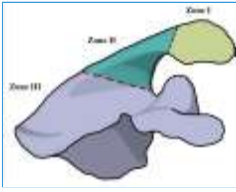
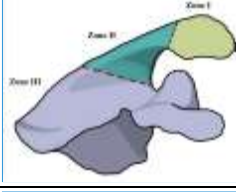
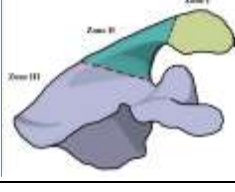
• Complications

- Scapular notching


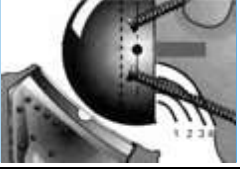




- incidence
 - occurs in 44%-96% of Grammont style prosthesis
 - due to 155° humeral component neck-shaft angle that effectively medializes humeral component
 - decreased incidence with lateralization of baseplate
 - related to impingement by the medial rim of the humeral cup during adduction
- risk factors
 - superiorly placed glenoid component
 - superior tilt of glenoid component
 - medialization of center of rotation
 - high BMI
- Dislocation
 - incidence
 - reported rate between 2% - 3.4%
 - position of dislocation most commonly extension, internal rotation, and adduction
 - most common cause of early failure
 - risk factors
 - irreparable subscapularis (strongest risk)
 - proximal humeral bone loss
 - failed prior arthroplasty
 - proximal humeral nonunion
 - fixed pre-operative glenohumeral dislocation
- Glenoid Loosening
 - incidence
 - glenoid prosthetic loosening is most common mechanism of failure

- incidence significantly increases (~25% at 5-year followup) after revision RSA
 - treatment
 - treat using staged procedure to fill glenoid cavity with autogenous bone and await incorporation with a hemiarthroplasty prior to reimplantation of a new glenosphere
- Deep Infection
 - incidence
 - 1-2% risk of deep surgical site infection following shoulder arthroplasty
 - susceptible to infection due to large subacromial dead space created by reverse prosthesis
 - most common organisms include c.acnes and staphylococci
 - Risk Factors
 - Younger age (less than 65) and male are the greatest risk factors
 - Arthroplasty for traumatic reasons
 - History of failed arthroplasty
 - treatment
 - 2-stage revision is considered gold standard
 - most common antibiotic treatment of choice for c.acnes is vancomycin and clindamycin
- Acromial or scapular spine fractures
 - incidence
 - 4% after RSA
 - risk factors
 - female sex
 - osteoporosis
 - medialized preoperative center of rotation
 - treatment
 - conservative management leads to 40-50% union rate
 - operative management with ORIF or tension band wiring of acromial fractures has increased union rates

Levy Classification for Post-operative Acromial fractures after Reverse Shoulder Arthroplasty		
<ul style="list-style-type: none"> ▪ Type 1 	<ul style="list-style-type: none"> ▪ Acromion anterior to posterolateral acromial corner 	
<ul style="list-style-type: none"> ▪ Type 2 	<ul style="list-style-type: none"> ▪ Mid acromion between base and posterolateral corner 	
<ul style="list-style-type: none"> ▪ Type 3 	<ul style="list-style-type: none"> ▪ Acromial base 	

- Neurapraxia of axillary nerve
 - incidence
 - 0.5-1% rate after RSA
 - risk factors
 - anterosuperior approach
 - humerus lengthening
 - treatment
 - usually transient

<ul style="list-style-type: none"> ■ Sirveaux Classification of Scapular Notching 		
<ul style="list-style-type: none"> ■ Grade 1 	<ul style="list-style-type: none"> ■ Limited to scapular pillar 	<ul style="list-style-type: none"> ■ 
<ul style="list-style-type: none"> ■ Grade 2 	<ul style="list-style-type: none"> ■ In contact with inferior screw of baseplate 	<ul style="list-style-type: none"> ■ 
<ul style="list-style-type: none"> ■ Grade 3 	<ul style="list-style-type: none"> ■ Beyond the inferior screw 	<ul style="list-style-type: none"> ■ 
<ul style="list-style-type: none"> ■ Grade 4 	<ul style="list-style-type: none"> ■ Extends under baseplate approaching central peg 	<ul style="list-style-type: none"> ■ 

- Outcomes

- Overview

- results are dependent on indication, with cuff tear arthropathy (CTA) having the best results

- Radiographic

- radiographic results deteriorate after 6 years and clinical results after 8 years

- Survivability

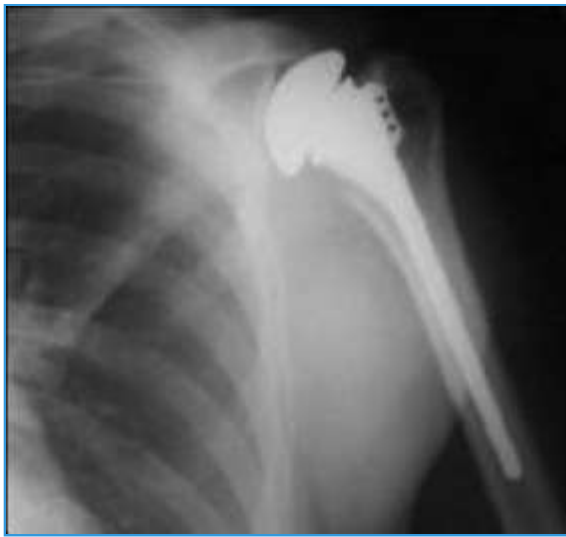
- some cases series' have noted 10 year survivability is approximately 90% for implant retention

- Complications

- various studies have shown that complication rate amongst surgeons decrease after a surgeon has performed at least 18-45 cases

31- Shoulder Hemiarthroplasty

Images



• summary

- A shoulder hemiarthroplasty is a procedure in which the humeral articular surface is replaced with stemmed humeral component.
- The most common indication is glenohumeral arthritis when the glenoid bone stock is inadequate for a total shoulder arthroplasty.
- It is contraindicated in patients with coracoacromial ligament deficiency.

• Indications

- Indications
 - primary arthritis, if:
 - rotator cuff is deficient
 - glenoid bone stock is inadequate
 - risk of glenoid loosening is high
 - young patients
 - active laborers
 - rotator cuff arthropathy
 - hemiarthroplasty > rTSA if able to achieve forward flexion > 90 degrees
 - osteonecrosis without glenoid involvement
 - proximal humerus fractures
 - three-part fractures with poor bone quality
 - four-part fractures
 - head-splitting fractures
 - fracture with significant destruction of the articular surface
- Contraindications
 - infection
 - neuropathic joint
 - unmotivated patient
 - coracoacromial ligament deficiency
 - provides a barrier to humeral head proximal migration in the case of a rotator cuff tear
 - superior escape will occur if coracoacromial ligament and rotator cuff are deficient

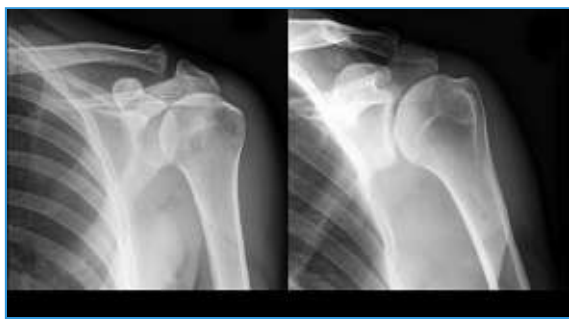• Outcomes

- Rotator cuff deficiency
 - status of the rotator cuff is the most influential factor affecting postoperative function in shoulder hemiarthroplasty
- Proximal humerus fractures
 - provides excellent pain relief in a majority of patients
 - outcome scores inversely proportional to
 - patient age
 - time from injury to operation

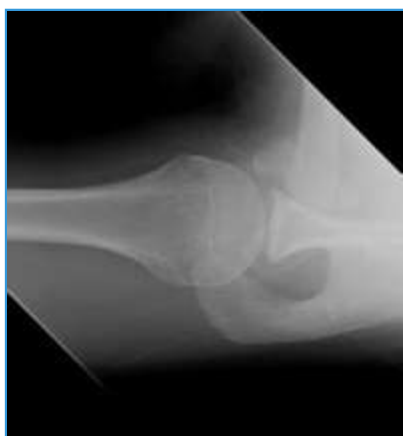• Preoperative Imaging

○ Radiographs

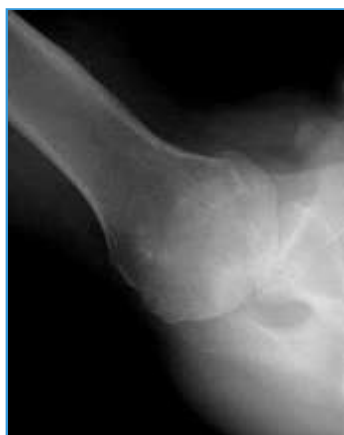- true (Grashey) AP of shoulder



- taken 30-40 degrees oblique to the coronal plane of the body
- findings
 - helps determine extent of DJD
 - delineation of fracture pattern
- axillary view



- findings
 - look for posterior wear of glenoid



- helps quantify displacement in cases of fracture

○ CT scan

- obtain CT scan to determine glenoid version and glenoid bone stock
- useful if fracture pattern is poorly understood after radiographic evaluation

○ MRI

- useful for evaluation of rotator cuff

• techniques

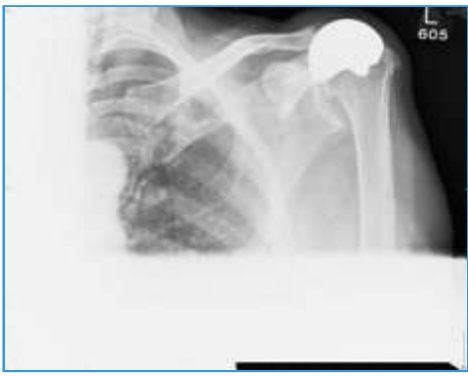○ Approach

- deltopectoral approach

○ Shaft preparation and prosthesis placement

- humeral head resection
 - start osteotomy at medial insertion line of supraspinatus
- determine retroversion, implant height and head size
 - retroversion
 - 30° of retroversion is ideal
 - lateral fin should be slightly posterior to biceps groove
 - excessive anteversion leads to risk of anterior dislocation
 - excessive retroversion leads to risk of posterior dislocation
 - implant height
 - greater tuberosity should be
 - 7 to 8 mm below the top of the prosthetic humeral head
 - functions to
 - maintain cuff and biceps tension

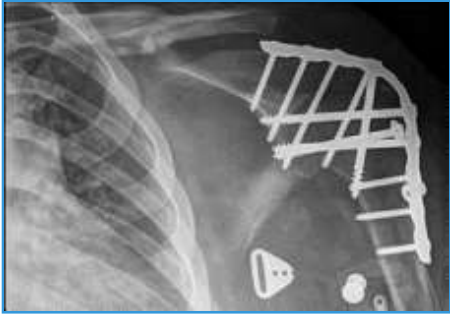
- recreate normal contour of medial calcar
 - technique to achieve
 - cement prosthesis proud
 - distance from top of prosthesis head to upper border of pectoralis major should be 56mm.
 - head size
 - determine size by using
 - radiograph of contralateral shoulder or
 - measuring size of native head removed earlier in procedure
 - using too large of a head may "overstuff" joint
 - Fixation
 - cemented prosthesis
 - standard of care
 - provides better quality of life, range of motion, and strength compared to uncemented humeral component
 - Tuberosity reduction
 - introduction
 - tuberosity migration is one of the most common causes of failure for fractures treated with hemiarthroplasty
 - technique
 - strict attention to securing the tuberosities to each other and to the shaft
 - autogenous bone grafting from the excised humeral head will decrease the incidence of pull-off and improve healing rates
 - tuberosity reduction must be anatomic or it may lead to a deficit in rotation
 - The "Ream and Run" Procedure
 - introduction
 - shoulder hemiarthroplasty with concentric glenoid reaming (non-prosthetic glenoid arthroplasty)
 - avoids the potential limitations associated with a prosthetic glenoid component
 - provides patient with the opportunity for a level of activity beyond that recommended for a total shoulder arthroplasty
 - technique
 - spherical reaming of the osseous glenoid surface to optimize both glenohumeral stability and the distribution of load applied by the humeral prosthesis
 - the glenoid face is reamed to a single smooth concavity using a nubbed spherical reamer
 - outcomes
 - excellent functional and radiographic 2-year outcomes
- Rehab
 - Early passive motion until fracture has healed
 - duration usually 6-8 weeks
 - Strengthening exercises begin once tuberosity has fully healed
- Complications
 - Progressive glenoid arthrosis
 - increased risk with
 - young patients
 - active patient
 - treatment
 - conversion to total shoulder arthroplasty
 - Tuberosity displacement/malunion
 - one of the most common complications of shoulder hemiarthroplasty when used to treat fracture
 - treatment
 - repositioning of the tuberosity with bone grafting
 - Joint overstuffing
 - may lead to
 - stiffness
 - accelerated arthritis of glenoid
 - Subcutaneous (anterosuperior) escape



- occurs when both rotator cuff and coracoacromial arch are deficient
- better outcomes with conversion to reverse shoulder arthroplasty compared to anatomic TSA

32- Shoulder Arthrodesis

Images



• Introduction

- The goal of shoulder arthrodesis is to provide a stable base for the upper extremity optimizing hand and elbow function
 - it remains an important treatment option in appropriately selected patients
- Indications
 - stabilization of paralytic disorders
 - brachial plexus palsy
 - irreparable deltoid and rotator cuff deficiency with arthropathy
 - salvage of a failed total shoulder arthroplasty
 - reconstruction after tumor resection
 - painful ankylosis after chronic infection
 - recurrent shoulder instability which has failed previous repair attempts
 - paralytic disorders in infancy
- Contraindications
 - ipsilateral elbow arthrodesis
 - contralateral shoulder arthrodesis
 - lack of functional scapulothoracic motion
 - trapezius, levator scapulae, or serratus anterior paralysis
 - Charcot arthropathy during acute inflammatory stage (Eichenholtz 0-2)
 - elderly patients
 - progressive neurologic disease

• Anatomy

- Glenohumeral articulation
 - a relatively small amount of surface area exists allowing for predictable fusion
 - to increase the available fusion area, decortication of both the glenohumeral articular surface and the articulation between the humeral head and the undersurface of the acromion is performed
 - only the glenoid fossa and base of the coracoid provide sufficient strength for fixation

• Presentation

- Symptoms
 - specific to the underlying condition necessitating arthrodesis
 - symptomatic dysfunction of the glenohumeral joint

• Imaging

- Radiographs
 - recommended views
 - AP, lateral, and axillary views to assess bone stock available for fusion and deformities
- CT
 - better to evaluate glenoid bone loss especially in the setting of failed arthroplasty

• Studies

- EMG
 - indicated when the neurologic condition of the scapular muscles is ill-defined

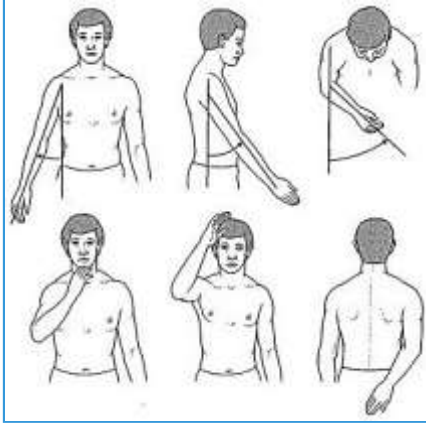
• Surgical Technique

○ Approach

- S-shaped skin incision beginning over the scapular spine, traversing anteriorly over the acromion, and extending down the anterolateral aspect of the arm

○ Fusion position

- goal is to allow patients to reach their mouths for feeding



- think "30°-30°-30°"

- 20°-30° of abduction
- 20°-30° of forward flexion
- 20°-30° of internal rotation

○ Technique

- rotator cuff is resected from the proximal humerus and the biceps tendon is tenodesed
- glenoid and humeral head articular surfaces and the undersurface of the acromion are decorticated
- arm is placed into the position of fusion (30°-30°-30°)
- a 10-hole, 4.5 mm pelvic reconstruction plate is contoured along the spine of the scapula, over the acromion, and down the shaft of the humerus
- compression screws are placed through the plate across the glenohumeral articular surface into the glenoid fossa
- the plate is anchored to the scapular spine with a screw into the base of the coracoid

○ Postoperative care

- a thermoplastic orthosis is applied the day after surgery and is maintained for 6 weeks
- at 6 weeks, may transition to a sling if there are no radiographic signs of loosening
- at 3 months, mobilization exercises and thoracoscapular strengthening are commenced if no radiographic signs of loosening are present
- expected recovery period is 6-12 months

• Complications

- Infection
- Nonunion
- Malposition
- Prominent hardware
- Humeral shaft fracture

33- Glenohumeral Arthritis Shoulder Arthritis

• summary

- Glenohumeral arthritis, or Shoulder Arthritis, is a degenerative joint disease of the shoulder characterized by damage to the articular surfaces of the humeral head and/or glenoid.
- Diagnosis is made radiographically with true AP shoulder ("Grashey") and axillary lateral radiographs.
- Treatment is observation, NSAIDs, and corticosteroids for minimally symptomatic patients. Shoulder arthroplasty is indicated for progressive symptoms with severe degenerative disease.

• Epidemiology

- Incidence
 - increases with age
 - more likely in patients over 60
- Demographics
 - more common in women
- Risk factors
 - 56% of patients who had primary anterior dislocation have arthrosis at 25 years follow up

• Etiology

- Causes
 - primary osteoarthritis
 - secondary arthritis
 - post-traumatic
 - arthritis of dislocation
 - inflammatory/crystalline arthritis
 - osteonecrosis
 - neuropathic (Charcot Arthropathy)
 - rotator cuff arthropathy
- Pathophysiology
 - primary osteoarthritis
 - articular cartilage
 - irreversible progressive loss of articular cartilage with hypertrophic reaction of the subchondral bone ; no known cause
 - humeral head
 - thinning/absence of cartilage, flattening, osteophyte and subchondral cyst formation, posterior humeral subluxation
 - glenoid
 - posterior wear (see: Walch glenoid classification), subchondral cyst formation
 - rotator cuff
 - rotator cuff tears incidence 5-10%, important to rule out
 - post-traumatic arthritis
 - articular surface incongruities following trauma healing can lead to joint deterioration
 - commonly occurs in patients with humeral fractures and chronic dislocations
 - cuff tear arthropathy
 - torn rotator cuff tendons leads to humeral head migration and subsequent abrasive contact between the humeral head and acromion which leads to articular wear
 - dislocation arthropathy
 - repeated dislocation can cause erosion of joint cartilage
 - higher incidence with
 - increased age
 - posterior dislocation
 - not associated with number of dislocations
 - post-capsulorrhaphy arthropathy

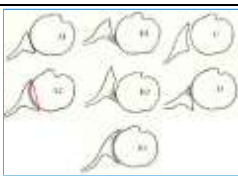
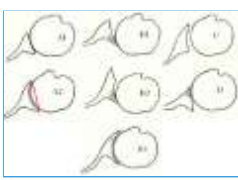
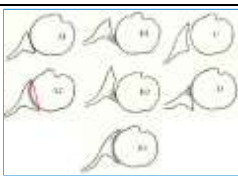
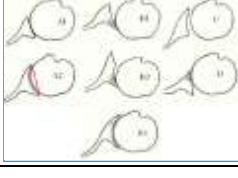
- excessive tightening of soft tissues in stabilization surgeries to treat recurrent dislocation forces humeral head in one direction
 - causes head to wear unevenly on glenoid
- inflammatory/crystalline arthritis
 - rheumatoid arthritis
 - systemic autoimmune disease causes synovial inflammation and degradation of shoulder joint
 - can involve all structures of shoulder including soft tissue
 - affects 90% of patient with RA
 - characterized by central glenoid wear and medialization of humeral head
 - calcium pyrophosphate dihydrate deposition disease (CPPD)
 - accumulation of calcium pyrophosphate crystals within joint space causing synovial inflammatory response and cartilage/bone damage; sometimes referred to as “pseudogout”
 - gout
 - accumulation of sodium urate crystals within joint due to hyperuricemia causing inflammatory attack within joint and cartilage/bone damage
- osteonecrosis/avascular necrosis
 - bone cell death caused by interruption of blood supply to humeral head leads to subchondral bone collapse and morphological/arthritis changes
 - causes
 - traumatic
 - proximal humerus fractures
 - 35% incidence in 3-part
 - 90% incidence in 4-part
 - chronic glenohumeral dislocations
 - repetitive injury
 - rotator cuff repair
 - atraumatic
 - steroid
 - ETOH
 - hemoglobinopathies
 - metabolic (e.g. Gaucher's disease)
- chondrolysis
 - occurs following shoulder arthroscopy
 - exact pathophysiology unknown but associated with
 - radiofrequency energy
 - continuous postop anesthetic infusion
 - bioabsorbable suture anchors
 - contrast
 - leads to the dissolution of articular cartilage
 - has less osteophytes than OA
- Associated conditions
 - rotator cuff tears
 - 5-10% incidence with OA
 - 25-50% incidence with RA

• Anatomy

- Glenohumeral (GH) joint
 - joint comprised of humeral head and glenoid fossa of scapula
 - stability
 - static restraints
 - glenohumeral ligaments
 - glenoid labrum
 - dynamic restraints
 - rotator cuff muscles
 - rotator interval
 - biceps
- Glenoid osteology
 - glenoid is 3 degrees retroverted

- humerus is 20-30 degrees retroverted

• Classification

Walch Classification of Glenoid Wear		
<ul style="list-style-type: none"> ▪ Type A 	<ul style="list-style-type: none"> ▪ Concentric wear, no subluxation of HH, well centered ▪ A1: no or minor central erosion ▪ A2: deeper central erosion, line connects anterior/posterior glenoid rims and transects humeral head (HH) 	
<ul style="list-style-type: none"> ▪ Type B 	<ul style="list-style-type: none"> ▪ Biconcave glenoid, asymmetric glenoid wear and head subluxated posteriorly ▪ B0: pre-osteoarthritic posterior subluxation of HH ▪ B1: posterior joint narrowing (no posterior bone loss), osteophytes, subchondral sclerosis ▪ B2: posterior rim erosion, retroverted glenoid ▪ B3: mono-concave, posterior wear, at least HH subluxation >70% OR retroversion >15 degrees 	
<ul style="list-style-type: none"> ▪ Type C 	<ul style="list-style-type: none"> ▪ C1: Glenoid retroversion >25 degrees, regardless of erosion ▪ C2: Biconcave, posterior bone loss, posterior translation of HH 	
<ul style="list-style-type: none"> ▪ Type D 	<ul style="list-style-type: none"> ▪ Glenoid anteversion or anterior HH subluxation (HH subluxation <40%) 	

• Presentation

○ Symptoms

- shoulder pain
 - worse with activities involving shoulder motion
 - often no pain at rest
- loss of range of motion
 - especially external rotation due to anterior capsule contraction
- difficulty sleeping

○ Physical exam

- functional limitations at glenohumeral joint
 - decreased external rotation, forward flexion, and internal rotation
 - variable and more active patients have better range of motion (ROM)
- crepitus
- catching/squeaking with articulation
- motor
 - a carefully evaluation of the rotator cuff muscles should be performed

○ Functional Outcomes Scores

- ASES Shoulder Score
- Constant Score
- Oxford Shoulder Score
- ASES Shoulder Score
- Constant Score
- Oxford Shoulder Score

○ ASES Shoulder Score

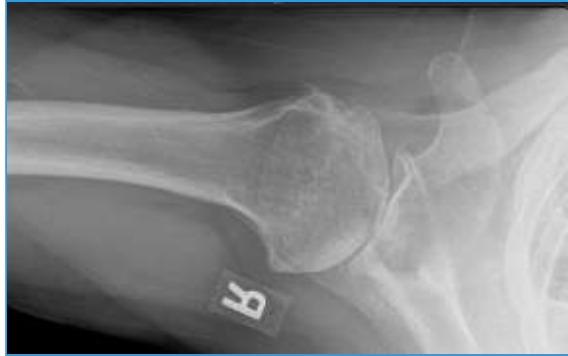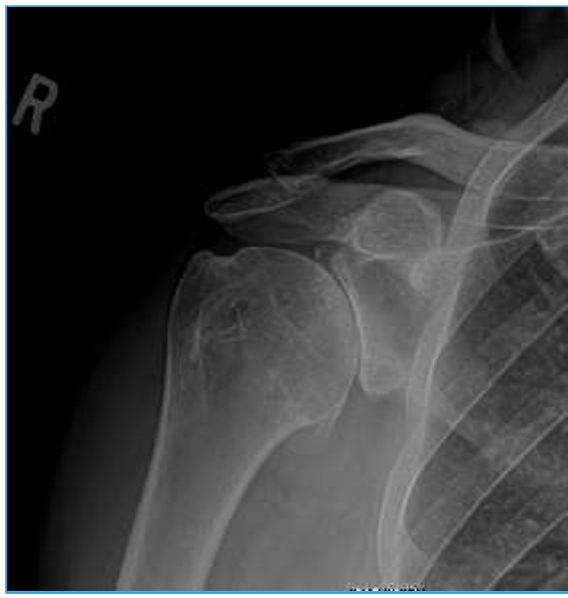○ Constant Score

○ Oxford Shoulder Score

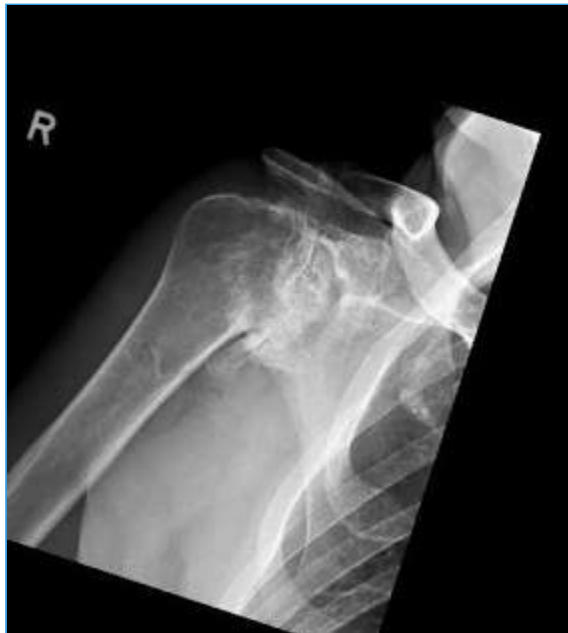• Imaging

○ Radiographs

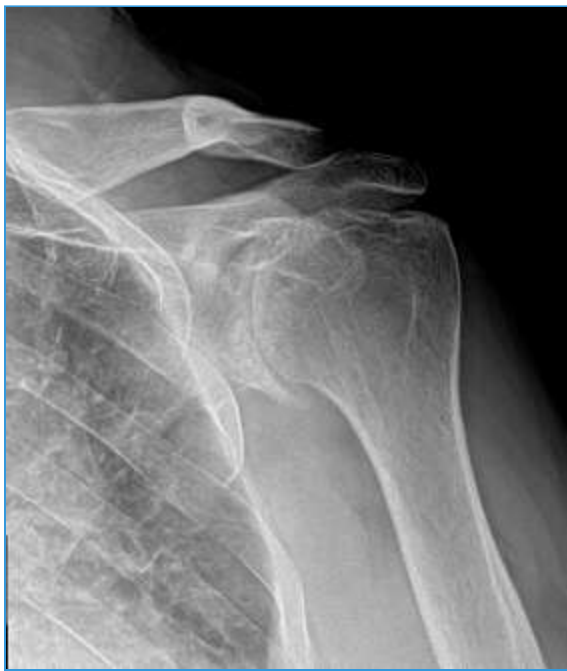- recommended views
 - true anteroposterior (AP) of GH joint
 - AP
 - axillary lateral
- findings often diagnose etiology
 - primary osteoarthritis



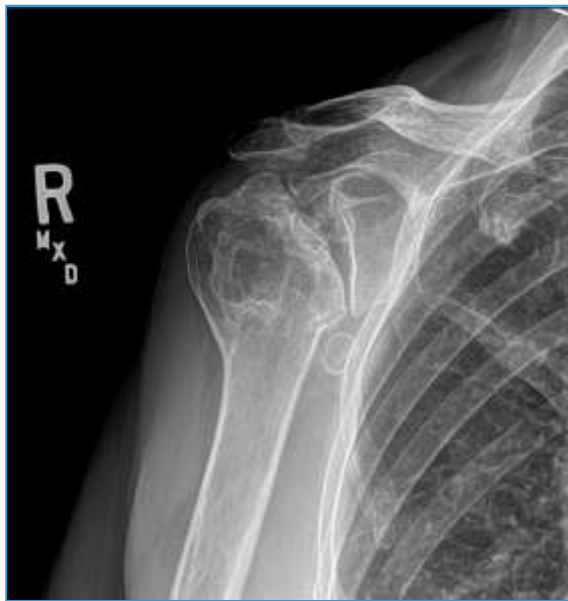- joint space narrowing
- subchondral sclerosis, subchondral cysts
- osteophytes circumferentially at humeral head, “goat's beard”
- posterior glenoid wear
- fixed posterior humeral head subluxation (due to tight anterior capsule)
- post-traumatic arthritis
 - articular surface incongruities due to healed fractures
 - hardware from previous surgeries
- arthritis of dislocation



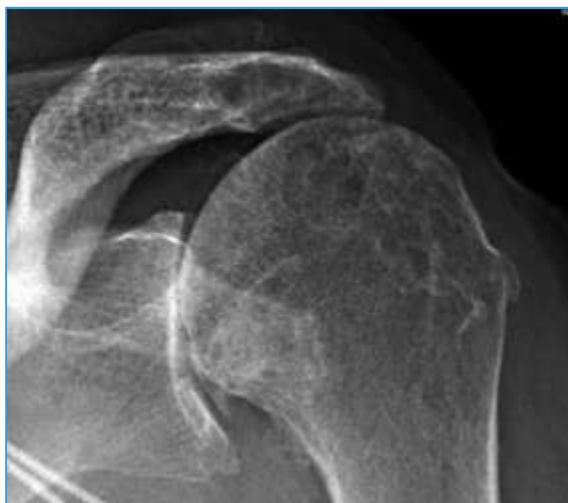- large osteophytes
- hardware from previous surgery
- inflammatory/crystalline arthritis
 - RA
 - joint space narrowing
 - marginal erosions of humeral head
 - reduction in acromiohumeral distance
 - few osteophytes



- central glenoid wear and medialization of humeral head
- osteopenia
- CPPD
 - chondrocalcinosis (calcific deposits in articular/fibrocartilage)
- Gout
 - usually unremarkable
 - repeat attacks may show osteopenia/erosions
- osteonecrosis/avascular necrosis



- normal radiographs early in disease
- resorption of middle of humeral head
- crescent sign (lucency) indicating subchondral collapse
- flattening/collapse in more advanced stages
- rotator cuff tear arthropathy



- osteopenia
- superior migration of humeral head
- narrowing of acromiohumeral interval
- acromial erosions
- superior glenoid bone loss
- “acetabularization” of coracoacromial arch

○ Computed tomography (CT)

- indications
 - evaluate glenoid morphology and rotator cuff pathology for pre-operative planning
 - may underestimate full-thickness RCTs and fatty infiltration/muscle atrophy compared to MRI

- allows for pre-operative templating
 - Magnetic Resonance Imaging (MRI)
 - indications
 - evaluate rotator cuff pathology for pre-operative planning
 - less accurate than CT in distinguishing between glenoid types
- Treatment**
- Nonoperative
 - **physical therapy, NSAIDs**
 - indications
 - first-line of treatment
 - modalities
 - NSAIDs- reduce pain and inflammation
 - physical therapy - improve range of motion with capsular stretching
 - **intraarticular Injections**
 - indications
 - second-line of treatment
 - modality
 - corticosteroid injection - reduce pain/inflammation
 - hyaluronic acid injection - joint lubrication, limited evidence
 - biologics (platelet rich plasma, stem cell) - limited evidence
 - **DMARDs**
 - indications
 - rheumatoid arthritis
 - Operative
 - **total shoulder arthroplasty (TSA)**
 - indications
 - intact rotator cuff
 - unresponsive to non-operative treatment
 - glenoid chondral wear
 - posterior humeral head subluxation
 - contraindications
 - lack of deltoid or rotator cuff function
 - active infection
 - Charcot arthropathy
 - technique
 - concave glenoid (cup) and convex humerus (ball) to reconstruct joint
 - outcomes
 - good pain relief, reliable ROM
 - 10 year survival (92-95%)
 - most common complications: glenoid/humeral component loosening, infection, fracture, nerve injury and rotator cuff tear
 - higher risk of prosthetic joint infection when performed within 3 months of prior arthroscopic procedure
 - **hemiarthroplasty**
 - indications
 - younger patient
 - rheumatoid arthritic patients with irreparable RC tears/insufficient bone stock
 - osteonecrosis without glenoid involvement
 - technique
 - humeral head replacement ± biologic resurfacing
 - ream-and-run technique
 - humeral head prosthesis & glenoid reaming to provide a stabilizing concavity and maximize glenohumeral contact area for load transfer
 - indicated in young patients with intact rotator cuff and no inflammatory arthropathy
 - outcomes
 - early failure rate, not recommended
 - poor pain and functional outcomes
 - **reverse shoulder arthroplasty (RSA)**

- indications
 - irreparable/large rotator cuff tear
 - OA or RA with significant glenoid pathology
 - age
 - rotator cuff arthropathy
 - failed arthroplasty
 - complex fracture
- technique
 - convex glenoid (ball) and concave humerus (cup) to reconstruct joint
- outcomes
 - Good pain relief, improved shoulder function
 - 10 year survival (~90-95%)
 - Common complications: scapular notching, infection, dislocation/instability, nerve injuries; higher reported complication rates than TSA
- **arthroscopic debridement**
 - indications
 - mild to moderate OA without structural alternation
 - mechanical symptoms due to loose bodies or small lesions of humeral head due to AVN
 - synovial chondromatosis
 - outcomes
 - temporizing treatment; improves ROM and pain
 - less successful in those with more rapid degenerative changes
 - higher rates of failure in those with more preoperative joint space narrowing and posterior glenoid wear
 - may see better results in patients who also had subacromial procedures
- **CAM (comprehensive arthroscopic management) procedure**
 - indications
 - younger patient
 - technique
 - combination of arthroscopic glenohumeral debridement, chondroplasty, synovectomy, loose body removal, humeral osteoplasty with excision of the goat's beard osteophyte, capsular releases, subacromial and subcoracoid decompressions, axillary nerve decompression, and biceps tenodesis
- **arthrodesis**
 - indications
 - paralysis
 - recurrent infection
 - severe soft tissue deficiency; poor deltoid function
 - brachial plexus palsy
 - persistent symptomatic instability with failed repair
 - outcomes
 - moderate complications
 - Improved/ acceptable long-term function

- Techniques

- **Total shoulder arthroplasty**
- **Hemiarthroplasty**
- **Reverse ball prosthesis**

34- Adhesive Capsulitis Frozen Shoulder

• Summary

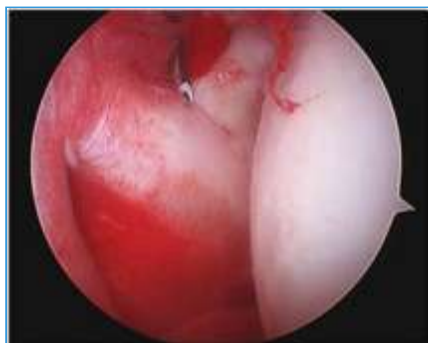- Adhesive capsulitis (also known as frozen shoulder) is a condition of the shoulder characterized by functional loss of both passive and active shoulder motion commonly associated with diabetes, and thyroid disease.
- Diagnosis is made clinically with marked reduction of both active and passive range of motion of the shoulder.
- Treatment is a prolonged course of aggressive physical therapy and medical management of underlying disease if present (i.e diabetes, thyroid disorder). Manipulation under anesthesia or arthroscopic capsular release is indicated in patients with progressive loss of motion having failed a prolonged course of physical therapy.

• Epidemiology

- Demographics
 - more common among women
 - ages 40-60 years

• Etiology

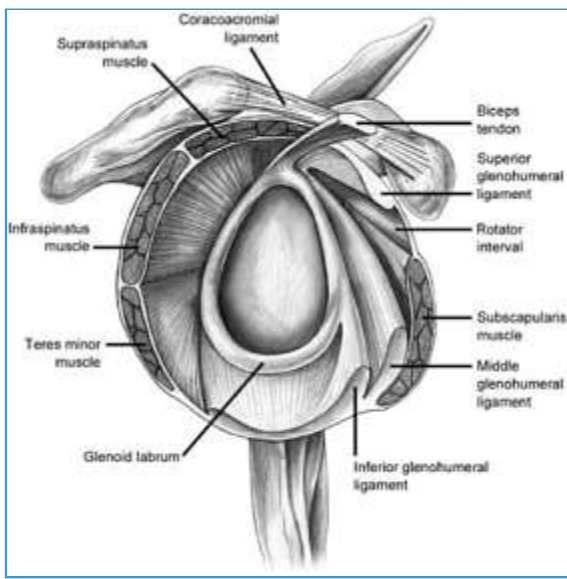
- Pathophysiology
 - mechanism of injury
 - primary, idiopathic form
 - post-traumatic (following proximal humerus fracture or immobilization for other upper extremity injury)
 - post-surgical (following rotator cuff repair or axillary dissection for malignancy)
 - pathoanatomy
 - inflammatory process causing fibroblastic proliferation of joint capsule leading to thickening, fibrosis, and adherence of the capsule to itself and humerus
 - fibroblasts/myofibroblasts with abundant Type III collagen present
 - leads to mechanical block to motion



- essential lesion involves the coracohumeral ligament and rotator interval capsule
- Associated conditions
 - diabetes (both types)
 - stiffness may be first manifestation of diabetes and warrants further workup
 - worse outcomes regardless of treatment
 - increased risk with older age, increased duration of DM, autonomic neuropathy, history of MI
 - thyroid disorders (autoimmune etiology)
 - dupuytren's disease
 - atherosclerotic disease
 - cervical disc disease

• Anatomy

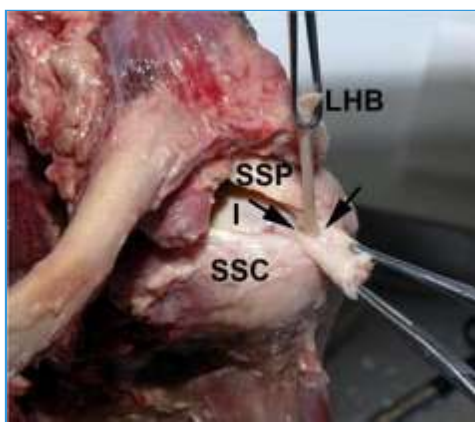
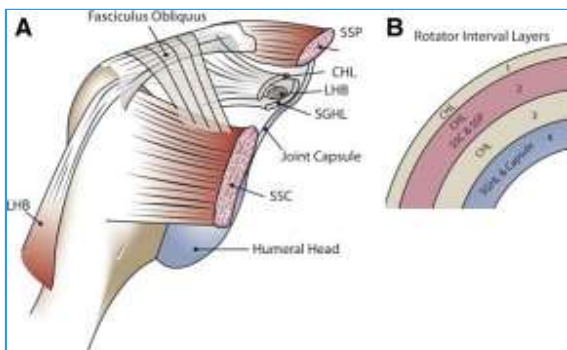
- Capsuloligamentous structures
 - function
 - contribute to stability of the glenohumeral joint
 - act as check reins at extremes of motion in their non-pathologic state
 - glenohumeral ligaments



- superior glenohumeral ligament (SGHL)
- middle glenohumeral ligament (MGHL)
- inferior glenohumeral ligament (IGHL) complex with the following components
 - anterior band
 - axillary fold
 - posterior band

○ Rotator interval

- a triangular region between the anterior border of supraspinatus and the superior border of subscapularis
- contains the SGHL and coracohumeral ligament



• Classification

<ul style="list-style-type: none"> ■ Clinical Stages 		
<ul style="list-style-type: none"> ■ Freezing/Painful 	<ul style="list-style-type: none"> ■ Gradual onset of diffuse pain (6 wks to 9 months) 	■
<ul style="list-style-type: none"> ■ Frozen/Stiff 	<ul style="list-style-type: none"> ■ Decreased ROM affecting activities of daily living (4 to 9 months or more) 	■
<ul style="list-style-type: none"> ■ Thawing 	<ul style="list-style-type: none"> ■ Gradual return of motion (5 to 26 months) 	■
<ul style="list-style-type: none"> ■ Arthroscopic Stages 		
<ul style="list-style-type: none"> ■ Stage 1 	<ul style="list-style-type: none"> ■ Patchy, fibrinous synovitis 	■
<ul style="list-style-type: none"> ■ Stage 2 	<ul style="list-style-type: none"> ■ Capsular contraction and fibrinous adhesions 	■
<ul style="list-style-type: none"> ■ Stage 3 	<ul style="list-style-type: none"> ■ Increasing contraction, synovitis resolving 	■
<ul style="list-style-type: none"> ■ Stage 4 	<ul style="list-style-type: none"> ■ Severe contraction 	■

• Presentation

○ Symptoms

- common symptoms
 - often insidious onset of general shoulder pain preceding any noticeable loss of motion
 - variable character and severity of pain, loss of motion dependent on the stage of disease at presentation
 - freezing- insidious onset of pain at rest and with movement, difficulty sleeping
 - frozen- pain lessens but significant motion limitations affecting ADLs
 - thawing- pain is gone and motion improves but less than normal

○ Physical exam

- inspection
 - note any muscle atrophy or scars denoting prior surgery
- motion
 - symmetric loss of active and passive ROM
 - document all motion planes and compare to contralateral side
 - limitations in motion may be slight, external rotation deficit most common finding
 - tethered endpoint to motion
 - pain throughout motion arc or at terminal motion depending on stage of disease
- provocative tests
 - impingement, biceps, and SLAP maneuvers often positive
 - rotator cuff testing may be limited given loss of motion

• Studies

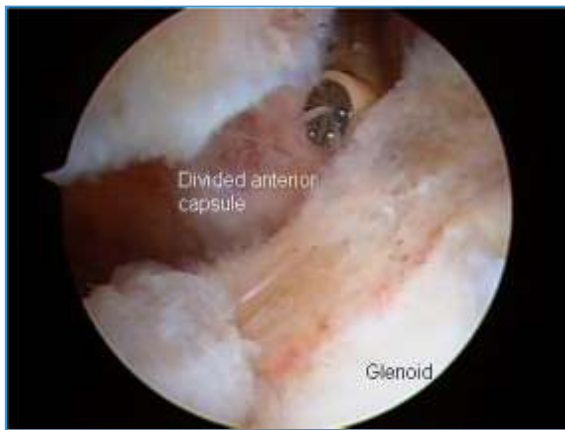- Metabolic panel and endocrine labs (TSH, A1c)

• Imaging

- Radiographs
 - recommended views
 - AP in neutral rotation
 - scapular-Y
 - axillary lateral
 - alternate views
 - AP in internal and external rotation
 - findings
 - disuse osteopenia
 - must be obtained to evaluate for osteoarthritis, posterior dislocation, or surgical hardware
- MRI +/- arthrography
 - indications
 - not necessary for diagnosis but can evaluate for other pathology
 - findings
 - loss of axillary recess indicates contracture of joint capsule

• Treatment

- Nonoperative
 - **physical therapy, NSAIDs and/or intra-articular steroid injections, heat and/or cryotherapy**
 - indications
 - first-line treatment, often effective
 - physical therapy program of gentle, pain-free stretching and moist heat
 - should be supervised and last for 3-6 months
 - **distension arthrography**
 - rarely performed
- Operative
 - **manipulation under anesthesia (MUA)**
 - indications
 - failure to improve with non-operative modalities
 - contraindications
 - controversial if done during freezing/inflammatory phase
 - diabetics- 50% failure rate
 - following rotator cuff or labral repair
 - **arthroscopic or open capsular release**



- indications
 - after extensive therapy has failed (3 months)
 - arthroscopy will spare subscapularis tendon with the advantage of releasing intra-articular and subacromial adhesions

• Techniques

○ Physical therapy

- daily progressive stretching exercises to point of pain
- supervised or home-based programs
- successful for overwhelming majority

○ Manipulation under anesthesia

- assess and document pre-procedure range of motion
- anesthesia
 - complete muscle paralysis required
 - in-dwelling catheter for regional anesthesia often used to aid in therapy
- manipulation
 - steady force applied after full muscle paralysis achieved
- postoperative
 - early physical therapy program initiated
- complications
 - fracture, dislocation, rotator cuff and labral tears
 - brachial plexus palsies

○ Arthroscopic capsular release

- assess and document pre-procedure range of motion
- anesthesia
 - in-dwelling catheter for regional anesthesia often used to aid in therapy
- approach
 - standard skin incisions with portal placement slightly higher than normal given contracted and thickened capsule
- release
 - intra-articular structures may be obscured by adhesions and contractures
 - rotator interval released from anterior biceps tendon to superior edge of subscapularis
 - coracohumeral ligament can then be visualized and released
 - posterior capsular release will increase IR and cross-body adduction
 - subacromial bursectomy and adhesions released as needed, no acromioplasty done
- manipulation
 - MUA may be done before or after release to increase to range of motion
- postoperative
 - early physical therapy program initiated

• Complications

- Residual stiffness
- Axillary nerve injury with capsular release
 - perform inferior release near to glenoid rim
- Proximal humerus fracture, dislocation, rotator cuff tears or brachial plexopathy
 - following overzealous manipulation with osteoporotic bone

• Prognosis

- Self-limited disease

- Worse outcomes among diabetics
- After surgical treatment, gains in range of motion and improved function are maintained at long-term follow

35- Avascular Necrosis Of The Shoulder

• summary

- Avascular necrosis of the shoulder is a condition characterized by interruption of blood supply to the humeral head which may lead to humeral head sclerosis and subchondral collapse.
- Diagnosis is made radiographically with orthogonal radiographs of the shoulder in moderate/late disease. MRI may be needed for detection of early or subclinical avascular necrosis.
- Treatment may be observation for very early and minimally symptomatic disease. Surgical management is indicated for progressive symptoms in the setting of moderate to advanced disease.











• Etiology

- Pathophysiology
 - pathoanatomy
 - decreased blood supply to humeral head leading to death of cells in bony matrix.
 - bone is resorbed and remodeled, causing subchondral bone collapse and may lead to joint incongruity and arthritic changes
 - etiology similar to hip
 - Remember ASEPTIC mnemonic
 - A lcohol, A IDS
 - Steroids (most common), Sickle , S LE
 - Erlenmeyer flask (Gaucher's)
 - P ancreatitis
 - T rauma
 - I diopathic/ Infection
 - C aisson's (the bends)
 - may be atraumatic
 - posttraumatic
 - four-part fracture-dislocations approach 100% AVN
 - displaced four-part fractures ~45% AVN
 - valgus impacted four-part ~11% AVN
 - three-part ~14% AVN

• Anatomy

- Blood supply
 - Humeral head
 - ascending branch of anterior humeral circumflex artery and arcuate artery
 - provides blood supply to humeral head
 - vessel runs parallel to lateral aspect of tendon of long head of biceps in the bicipital groove
 - beware not to injure when plating proximal humerus fractures
 - arcuate artery is the interosseous continuation of ascending branch of anterior humeral circumflex artery and penetrates the bone of the humeral head
 - provides 35% of blood supply to humeral head
 - posterior humeral circumflex artery
 - most current literature supports this as providing the main blood supply to humeral head
 - provides 65% of blood supply

• Classification

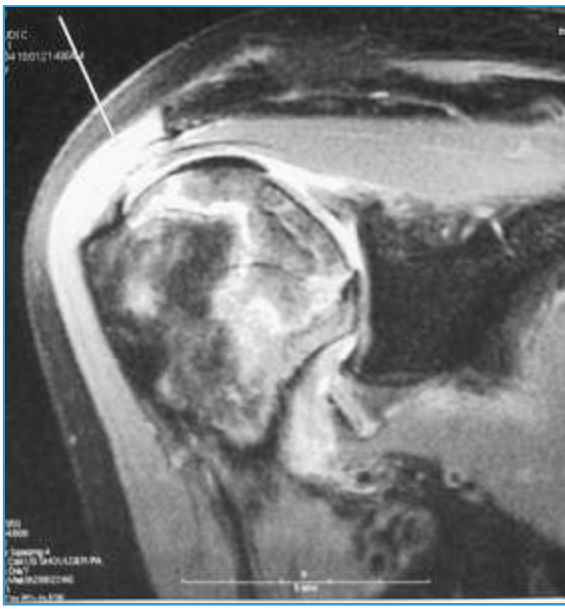■ Cruess Classification (stages)			
	■ <i>Radiographic findings</i>	■ <i>Treatment</i>	
■ Stage I	■ Normal x-ray, c changes on MRI only	■ Core decompression	 
■ Stage II	■ Sclerosis (wedged, mottled) Osteopenia	■ Core decompression	 
■ Stage III	■ Crescent sign indicating a subchondral fracture	■ Resurfacing or hemiarthroplasty	 
■ Stage IV	■ Flattening and collapse	■ Resurfacing or hemiarthroplasty	 
■ Stage V	■ Degenerative changes extend to glenoid	■ Total shoulder arthroplasty	 

• Presentation

- Symptoms
 - insidious onset of shoulder pain
 - often without a clear inciting event
 - pain, loss of motion, crepitus, and weakness
- Physical exam
 - limited range of motion
 - crepitus
 - weakness of the rotator cuff and deltoid muscles

• Imaging

- Radiographs
 - recommended views
 - five views of shoulder (shown best in neutral rotation AP)
 - findings
 - no findings on radiograph at onset of disease process
 - osteolytic lesion develops on radiograph demonstrating resorption of subchondral necrosis
 - most common initial site is superior middle portion of humeral head
 - crescent sign demonstrates subchondral collapse
 - may progress to depression of articular surface and consequent arthritic changes.
- MRI
 - preferred imaging modality
 - ~100% sensitivity in detection
 - will demonstrate edema at the site of subchondral sclerosis



- Treatment

- Nonoperative

- **pain medications, activity modification, physical therapy**

- indications

- first line of treatment

- technique

- physical therapy

- restrict overhead activity and manual labor

- Operative

- **core decompression + arthroscopy (confirm integrity of cartilage)**

- indications

- early disease (precollapse Cruess Stage I and II)

- **humeral head resurfacing**

- indications

- Stage III disease with focal chondral defects, and sufficient remaining epiphyseal bone stock for fixation.

- **hemiarthroplasty**

- indications

- moderate disease (Cruess Stage III and IV)

- **total shoulder arthroplasty**

- indications

- advance stage (Cruess V)

- Prognosis

- Related to stage of disease

36- Shoulder Prosthetic Joint Infection

• summary

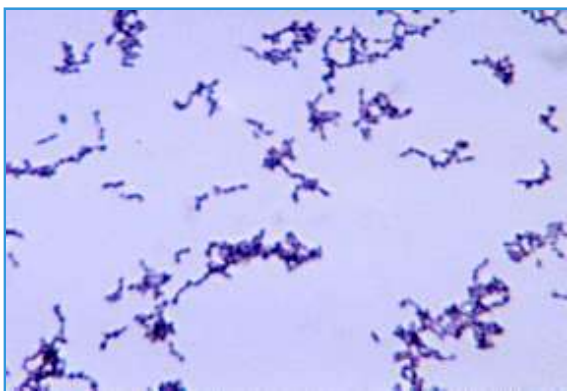
- Shoulder Prosthetic Joint infections are serious complications of shoulder arthroplasty and a major cause for revision within the first 2 years.
- Diagnosis is multifaceted and involves a high index of suspicion given the indolent nature of the most common organism *Cutibacterium acnes*. Elevated inflammatory markers, radiographic changes around the prosthesis and aspiration results can all assist with diagnosis.
- Treatment generally involves prolonged IV antibiotics and two-stage revision arthroplasty.

• Epidemiology

- Incidence
 - ~4% for primary TSA and RSA
 - ~15% for revision TSA and RSA
- Demographics
 - males more likely to be colonized with *Cutibacterium acnes* (formerly known as *Propionibacterium acnes*)
- Risk factors
 - postoperative hematoma
 - intra-articular steroid injection within 3 months of surgery
 - smoking
 - young age
 - male gender
 - arthroplasty for trauma
 - revision surgery

• Etiology

- Pathophysiology
 - pathobiology
 - micro-organisms most commonly isolated:
 - *Staphylococcus aureus*
 - *Staphylococcus epidermidis*
 - *Cutibacterium acnes* (most common)



- characteristics
 - gram-positive, facultative, aerotolerant, anaerobic rod that ferments lactose to propionic acid
 - concentrated in the axilla within the dermal sebaceous glands
 - forms biofilm within 18-90h (found on implant surface and on synovial tissue) >> planktonic
 - explains why aspiration is only 17% sensitive
 - Mean duration of culture incubation between 7-21 days
- Prophylaxis
 - antibiotic prophylaxis
 - administered within 30 minutes of incision
 - continued for 24 hours postoperatively
 - clindamycin for *C. acnes*
 - hair removal by electric clippers
 - preparation of the surgical site

• Classification

- Time of onset
 - acute infection
 - infection <3-6 weeks from surgery
 - CDC definition < 90 days from date of joint replacement
 - biology
 - usually confined to joint space
 - no invasion into prosthetic-bone interface
 - less likely for biofilm production
 - chronic infection
 - infection > 3-6 weeks from surgery
 - CDC definition > 90 days from date of joint replacement
 - biology
 - biofilm created by all bacteria forms on implant within four weeks
 - composition
 - 15% cells and 85% polysaccharide layer (glycocalyx)
 - glycocalyx allows biofilm to adhere to prosthesis and protect bacteria from host immune system
 - consequence
 - no method exists to safely remove biofilm and eradication is difficult
 - prosthetic explant indicated for infection >4 weeks due to biofilm production
 - infection has invaded prosthetic-bone interface
- Source of infection
 - direct invasion
 - sinus tract into joint capsule or wound dehiscence
 - hematogenous infection
 - infection in a longstanding infection-free joint secondary to another infection (eg. dental work, infected gallbladder)

• Presentation

- History
 - may have had a systemic illness or skin penetration
- Symptoms
 - common symptoms
 - persistent shoulder pain (most common)
 - persistent draining sinus (second most common)
 - systemic symptoms of infection (fevers, chills, night sweats)
 - stiffness
 - infection with *C. acnes* does not usually cause swelling, erythema, fever or purulent discharge
- Physical exam
 - inspection
 - sinus tract to joint is diagnostic
 - motion
 - limited by pain and edema

• Imaging

- Radiographs
 - essential to exclude other causes
 - findings
 - normal with early infection
 - osteopenia
 - periprosthetic lucencies
 - pseudosubluxation of the humeral head
 - effusion
 - endosteal scalloping
 - bony resorption
- Bone scan
 - not routinely obtained as their efficacy has not been demonstrated

- Ultrasound
 - findings
 - helpful to identify loculated fluid collections away from the glenohumeral joint
- MRI
 - findings
 - helpful to identify fluid collections
- Positron emission tomography (PET)
 - indication
 - useful adjunct in screening
 - sensitivity and specificity
 - 98% sensitivity and 98% specificity

• Studies

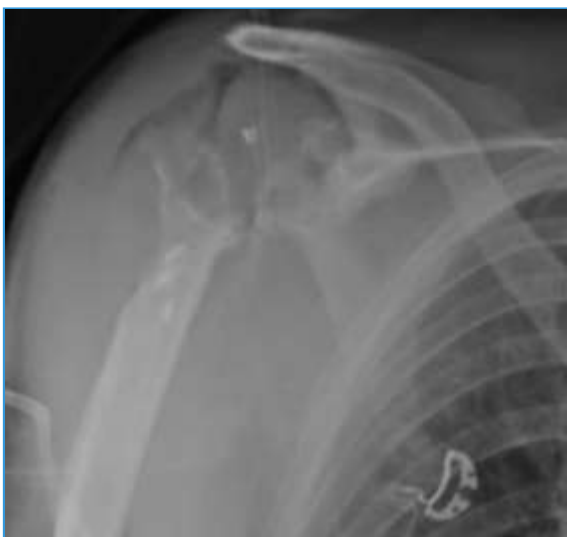- Labs
 - serology
 - WBC
 - physiology
 - not specific or sensitive
 - may be normal in *C. acnes* infection
 - ESR and CRP
 - have not demonstrated sufficient sensitivity or specificity to suggest PJI
 - CRP
 - physiology
 - peaks 2-3 days after surgery
 - returns to normal at 14-21 days
 - may be normal in *C. acnes* infection
 - ESR
 - physiology
 - peaks 5-7 days after surgery
 - returns to normal 90 days (3 months)
 - may be normal in *C. acnes*
 - alpha-defensin is investigational
 - Joint aspiration
 - no universal guidelines on when to aspirate
 - should be considered in all cases of deep infection
 - lab order request
 - cell count and differential
 - WBC > 50,000 (500 cells/uL)
 - crystals
 - presence does not exclude an infectious process
 - gram stain
 - may be negative in cases of infection
 - positive in approximately in 75% of cases
 - cultures and specificity
 - synovial tissue cultures are the gold standard
 - positive in approximately 80% of cases
 - hold cultures for 14-28 days to isolate *C. acnes*
 - cultures should be on aerobic, anaerobic, and broth media
 - at least 4 specimens should be obtained at surgery
 - fungal cultures held for 4 weeks
 - mycobacterial cultures held for 8 weeks

• Treatment

- Nonoperative
 - **antibiotic suppression**
 - indications
 - severely ill patients
 - those unwilling to undergo surgery

- guided by culture results
- consultation with infectious disease
- antibiotic
 - Penicillin is the antibiotic of choice for treatment of C.acnes
- outcomes
 - failure rates of 60-75%
- Operative
 - **irrigation and debridement with component retention**
 - indications
 - acute infections (<4 weeks)
 - **single-stage revision**
 - indications
 - uncommonly performed
 - identified low virulence organism with good antibiotic sensitivity
 - healthy patient and soft tissue
 - advantages
 - reduced hospital stay
 - reduced cost
 - reduced period of antibiotic administration
 - **2-stage implant exchange**
 - indications
 - gold standard
 - medically fit for multiple procedures
 - unknown micro-organism
 - requires adequate bone stock
 - requires microbial eradication prior to second stage

- **resection arthroplasty**



- indications
 - medically complex patients
 - frail patients who are poor surgical candidates
 - insufficient bone stock
 - recalcitrant infection
- outcomes
 - poor functional results, but pain relief in over 50% of cases
- **arthrodesis**
 - indications
 - rarely performed as bone stock is often compromised
- **amputation**
 - indications
 - rarely performed and reserved for life-threatening infection

- Techniques

- **Antibiotic suppression**
 - antibiotic
 - Aspiration cultures may direct antibiotic
 - Penicillin is most common for C. acnes
 - complication
 - inadequate clearance of organism

- **Irrigation and debridement and component retention**
 - approach
 - delto-pectoral approach
 - instrumentation
 - mobile parts of the prosthesis may be exchanged especially in RSA (glenosphere, polyethylene liner and tray)
 - complications
 - inadequate clearance of organism
 - outcomes
 - 50% failure rate
- **Single-stage revision**
 - approach
 - delto-pectoral approach
 - debridement
 - debride all infected soft tissue and bone
 - instrumentation
 - remove infected prosthesis and implant a new one
 - consider replacement with RSA for re-implantation as soft tissue debridement may sacrifice rotator cuff
 - complications
 - inadequate clearance of organism
 - outcomes
 - variable, as high as 90% success in some series
- **2-stage implant exchange**
 - approach
 - delto-pectoral approach
 - debridement
 - debride all infected soft tissues and bone
 - instrumentation
 - removal of implants and implantation of an antibiotic-impregnated cement spacer
 - permits local antibiotic delivery and induces formation of a pseudocapsule that can be mobilized with the cuff
 - benefits
 - maintains soft-tissue tension
 - decreases pain
 - improves functional status
 - allows patient to perform physical therapy
 - technique
 - mix antibiotics with PMMA and form cement by hand or with mold
 - humeral stem may be fabricated from Steinmann pin and chest tube
 - complications
 - recurrent infection
 - outcomes
 - some remain satisfied and elect to leave the spacer
 - variable 60%-90% success rate
- **Resection arthroplasty**
 - approach
 - delto-pectoral
 - debridement
 - debride all infected soft tissue and bone
 - preservation of tuberosities is predictive for better results
 - instrumentation
 - all instrumentation is removed
 - complications
 - poor functional outcome likely
 - antero-superior subluxation of humerus if tuberosities and cuff removed
 - outcomes
 - functional results are poor
 - pain relief is achieved in more than 50%
- **Arthrodesis**
 - approach

- S-shaped incision beginning over the scapular spine, traversing anterior over the acromion, and extending down the anterolateral aspect of the arm
- debridement
 - resect rotator cuff
 - bicep tenodesis
 - decorticate glenoid, humeral head, and undersurface of acromion
- instrumentation
 - a 10-hole 4.5mm pelvic reconstruction plate is commonly used with a goal of 30-30-30
 - 30 degrees of abduction
 - 30 degrees of forward flexion
 - 30 degrees of internal rotation
 - compression screws placed across the glenohumeral joint
- complication
 - infection
 - nonunion
 - malposition
 - prominent hardware
 - humeral shaft fracture
- outcomes
 - improvement in pain with fusion
- **Amputation**
 - approach
 - dependent on the level of amputation or shoulder disarticulation
 - debridement
 - removal of soft tissue and bone to desired level of resection
 - instrumentation
 - removal of all implants
 - complication
 - infection
 - neuromas

- **Complications**

- Failure to eradicate infection
- Humerus or glenoid fracture
- Poor bone stock

37- Elbow Anatomy And Biomechanics

• Introduction

- Joint includes
 - ulnohumeral joint
 - radiocapitellar joint
 - proximal radioulnar joint
- Elbow function
 - crucial for activities of daily living
 - acts as a lever arm when positioning the hand
 - functions as a fulcrum for forearm lever

• ROM

- Functional ROM
 - 30° to 130 flexion/extension
 - total ROM is 0-150 degrees
 - 50° supination/pronation
- Normal carrying angle
 - normal valgus carrying angle
 - 5-10° for males
 - 10-15° for females
 - this diminishes with flexion
- Axial loading
 - in extended elbow
 - 40% of weight is through ulnohumeral joint
 - 60% of weight is through radiohumeral joint

• Osteology & Arthrology

○ Osteology

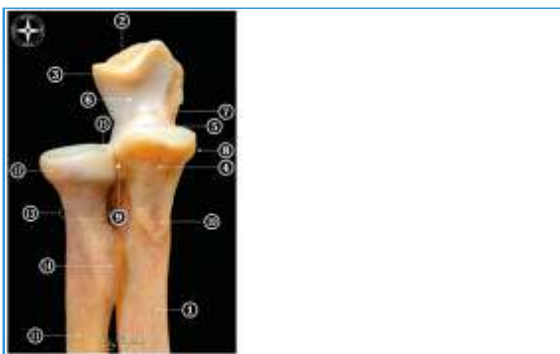

Fig. 9 Anterior view of the proximal radioulnar joint. 1 Ulnar diaphysis, 2 olecranon, 3 tip of the olecranon, 4 coronoid process, 5 tip of the coronoid process, 6 ulnar notch, 7 the ulnar notch is divided by a transverse portion composed of bony tissue and a anterior portion made up of the coronoid process and the posterior olecranon, 8 ulnar tubercle, 9 radial notch, 10 ulnar tuberosity, 11 radial diaphysis, 12 radial head, 13 radial neck, 14 radial tuberosity, 15 typical osteochondral lesion of the radial head at the level of anchiocapitellar groove. © Piva Golano

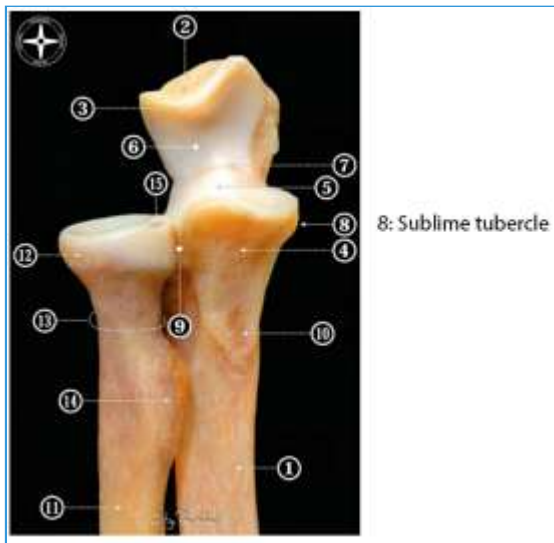
- spiral groove
 - the shaft for humerus has a spiral groove posteriorly (contains radial nerve)
 - this lies approximately 13 cm proximal to the articular surface of trochlea
- distal flare

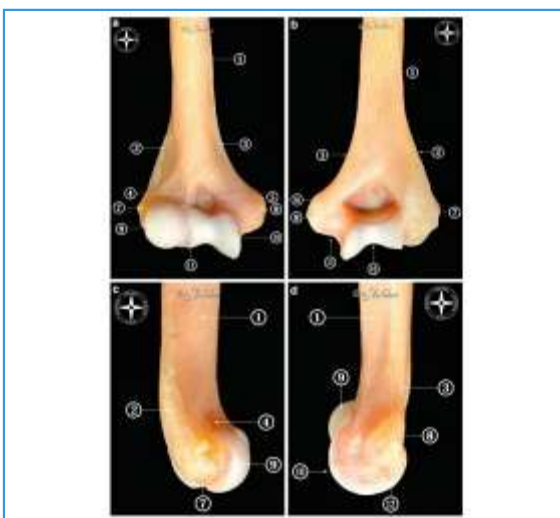

Fig. 7 Humerus bone: (a) Anterior view, (b) posterior view, (c) lateral view, (d) medial view. 1 Humeral diaphysis, 2 lateral supracondylar ridge, 3 medial supracondylar ridge, 4 radial fossa, 5 coronoid fossa, 6 olecranon fossa, 7 lateral epicondyle, 8 medial epicondyle, 9 capitulum, 10 trochlea, 11 trochleoepitellar groove, 12 sulcus for ulnar nerve. © Piva Golano

- the distal flare of humerus includes the medial and lateral epicondyles

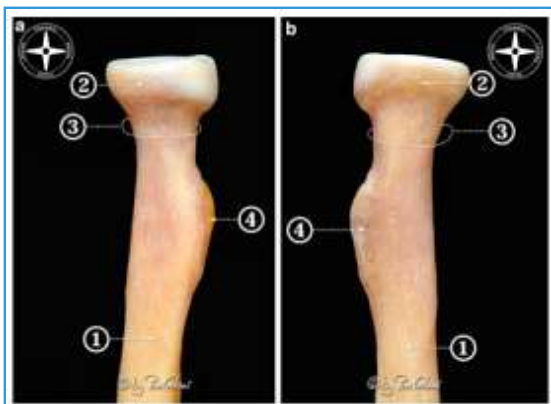
- the flare accounts for half of the elbow joint
- trochlea
 - is spool shaped and is located medially
- capitellum
 - located laterally
- sublime tubercle



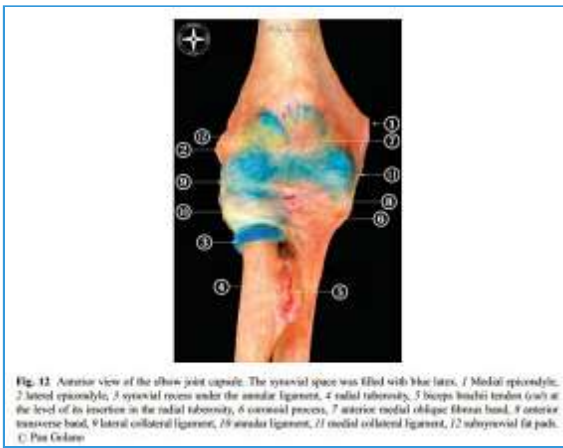
- the sublime tubercle on the ulna is where the anterior bundle of the medial ulnar collateral ligament attaches distally
- columns
 - distal humerus contains medial and lateral column

○ Arthrology

- axis and alignment
 - anterior tilt
 - the joint surface is anteriorly tilted approximately 30 deg relative to shaft of humerus
 - varus/valgus
 - 6 deg of valgus
 - rotation
 - internally rotated by 5 deg
 - axis of rotation
 - is centered at trochlea and capitellum
 - it passes through anteroinferior medial epicondyle
- joint type
 - pivot joint - the radiohumeral articulation is a pivot joint
 - radial head is covered by cartilage for approximately 240 degrees



- the lateral 120 degrees contains no cartilage
 - this is crucial for internal fixation of radial head fractures
- hinge joint - the ulnohumeral articulation is a hinge joint
 - coronoid fossa
 - coronoid fossa on distal humerus receives the coronoid tip in deeper flexion
 - coronoid tip
 - the coronoid tip has a buttress effect in the prevention of posterior dislocations
- capsule



- capsule is maximally distended at 70-80 deg of flexion
- distal attachment of anterior capsule is found 6 mm distal to tip of coronoid
 - coronoid is an intra-articular structure

• Muscles of the Elbow

○ Flexors

- biceps
 - the distal biceps attachment is at the level of the radial tuberosity
- brachialis
 - the attachment of the brachialis 11 mm distal to the tip of the coronoid
- brachioradialis

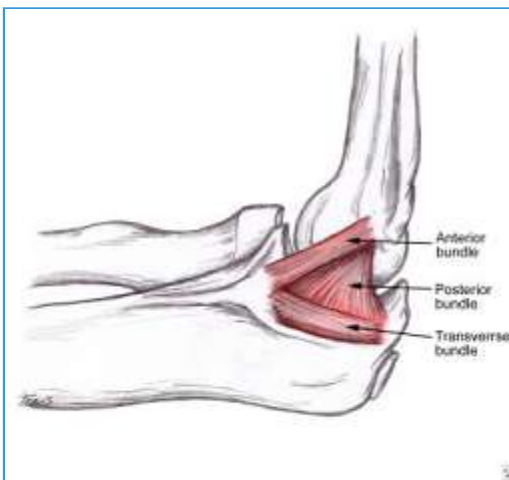○ Extensors

- triceps

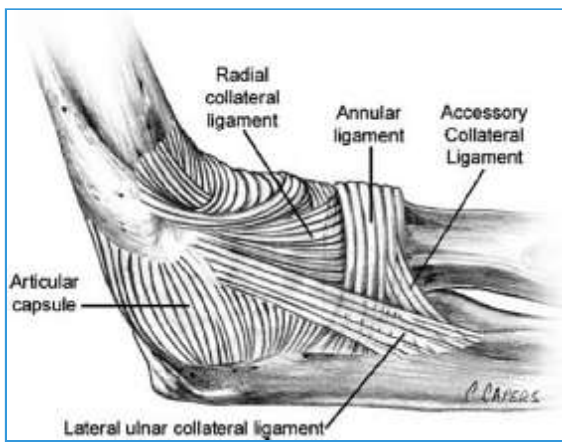
• Ligaments & Stability of Elbow

○ Primary static stabilizers

- ulnohumeral joint (coronoid)
 - loss of 50% or more of coronoid height results in elbow instability
- medial (ulnar) collateral ligament (MCL)



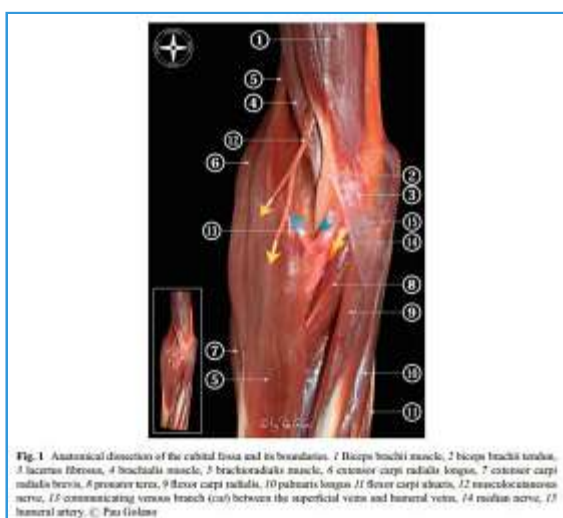
- overview
 - the MCL is composed of the anterior, posterior and transverse bundles
 - the MCL provides resistance to valgus and distractive stresses
- anatomy
 - origin
 - anteroinferior aspect of medial epicondyle
 - insertion
 - sublime tubercle of medial coronoid process
- components
 - anterior bundle of MCL
 - most important restraint against valgus stresses
 - radial head is second most important
 - posterior bundle of MCL
 - the posterior bundle forms the floor of the cubital tunnel
 - primary restraint to valgus stress in maximal elbow flexion
 - if this is contracted, flexion may be limited
 - transverse bundle of MCL
- lateral collateral ligament complex (LCL)



- overview
 - consists of the
 - radial collateral ligament (RCL)
 - lateral ulnar collateral ligament (LUCL)
 - function
 - primary restraint to varus and external stress during full arc of elbow motion
 - origin
 - posterior lateral epicondyle
 - insertion
 - crista supinatoris of proximal ulna
 - accessory collateral ligament
 - some believe that the the accessory collateral ligament and the radial collateral ligament contribute substantially to lateral elbow stability
 - annular ligament
 - provides stability to the proximal radioulnar joint
 - anatomy
 - the LCL arises from isometric point on lateral aspect of capitellum
 - function
 - optimal stability is conferred with an appropriately tensioned LCL repair
- Secondary static stabilizers
 - radiocapitellar joint
 - this functions as an important constraint to valgus stress
 - the radial head provides approximately 30% of valgus stability
 - this is most important at 0-30 deg of flexion/pronation
 - capsule
 - greatest contribution the capsule on stability occurs with the elbow extended
 - origins of the flexor and extensor tendons
- Dynamic stabilizers
 - includes muscles crossing elbow joint
 - anconeus
 - brachialis
 - triceps
 - biceps
 - they provide compressive stability

• Nerve of the Elbow

- Musculocutaneous nerve



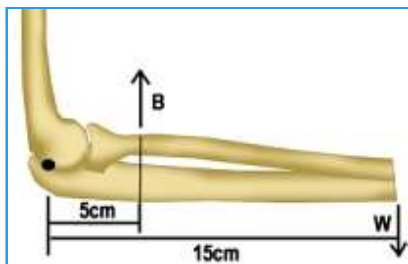
- origin
 - lateral cord of the brachial plexus

- anatomy at elbow
 - it exits laterally, distal to the biceps tendon
 - it will terminate as the LABC (forearm), which is found deep to the cephalic vein
- innervation at elbow
 - it supplies the biceps and brachialis
 - the nerve runs between these muscles
- Radial nerve
 - origin
 - posterior cord of the brachial plexus
 - anatomy at elbow
 - it leaves the triangular interval (teres major, long head of triceps and humeral shaft)
 - found in spiral groove 13 cm above the trochlea
 - pierces lateral intermuscular septum 7.5 cm above the trochlea
 - this is usually at the junction of the middle and distal third of the humerus
 - lies between the brachialis and the brachioradialis
 - distally it is located superficial to the joint capsule, at the level of the radiocapitellar joint
- Median nerve
 - origin
 - medial/lateral cords of the brachial plexus
 - anatomy at elbow
 - it courses with brachial artery, running from lateral to medial
 - lies superficial to brachialis muscle at level of elbow joint
 - innervation at elbow
 - it gives branches to elbow joint
 - it has no branches in upper arm
- Ulnar nerve
 - origin
 - medial cord of brachial plexus
 - anatomy at elbow
 - runs medial to brachial artery, pierces medial intermuscular septum (at the level of the arcade of Struthers) and enters posterior compartment
 - it traverses posterior to the medial epicondyle through the cubital tunnel
 - innervation at elbow
 - it gives branches to elbow joint
 - it has no branches in upper arm
 - first motor branch to FCU is found distal to the elbow joint
- Blood Supply of Elbow
 - Brachial artery
 - is located medially in the upper arm
 - it enters cubital fossa laterally
 - contents-- biceps tendon (lateral), brachial artery, median nerve (medial)
 - lateral border--brachioradialis
 - medial border--pronator teres
 - proximal border --distal humerus
 - at the level of elbow it splits into the radial and ulnar arteries
 - Principle branches
 - superior/inferior ulnar collateral
 - nutrient/muscular
 - supratrochlear
- Kinematics
 - Motion vectors
 - flexion and extension
 - the axis of rotation is found at the center of trochlea
 - pronation (pronator teres and quadratus) & supination (biceps and supinator)
 - the axis of motion is found at the capitellum through to the radial/ulnar heads
 - this effectively forms a cone

- Joint reaction force
 - there are large joint reaction forces due to short and inefficient lever arms around elbow (biceps inserts not far from center of rotation)
 - this contributes to degenerative changes of the elbow
- Center of rotation (COR)
 - is a line through isometric points on the capitellum about trochlea
 - the axis of pronation / supination is a line drawn from capitellum, through radial head, to distal ulna

Free Body Diagram

- Free body diagram demonstrate inefficiencies of elbow



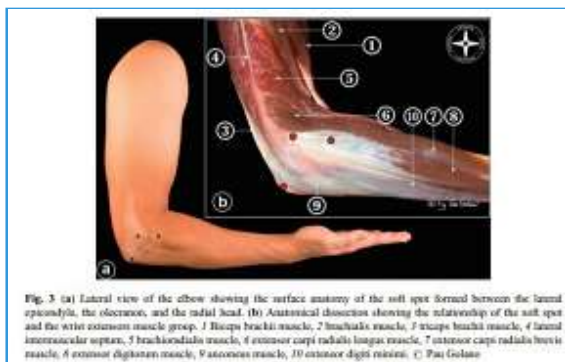
- $\sum M = 0$
- $5B = 15W$
- $B = 3W$
- Static loads are close to body weight
- Dynamic loads are greater than body weight

Arthrodesis

- Optimal position
 - in a unilateral arthrodesis
 - 90° of flexion
 - 0-7° of valgus
 - in a bilateral arthrodesis
 - one elbow in 110° of flexion for feeding
 - one elbow in 65° of flexion for perineal hygiene

Diagnostic Injections

- Intra-articular injection best given in soft spot formed by



- lateral epicondyle
- the olecranon
- radial head

Sports

Injuries:

Prevention,

Diagnosis,

Treatment and

Rehabilitation

[Sports Injuries: Prevention, Diagnosis, Treatment and Rehabilitation. CHAPTER: ELBOW ANATOMY](#)

[Francesc Malagelada](#)

[Miki Dalmau-Pastor](#)

[Jordi Vega](#)

[Pau Golano](#)

- [Shoulder & Elbow](#)
- [- Elbow Anatomy & Biomechanics](#)

[Francesc Malagelada,](#)

38- Elbow Stiffness And Contractures

• Summary

- Elbow Stiffness and Contractures of the elbow result in loss of motion and difficulty performing activities of daily living and may occur as a result of trauma, osteoarthritis, elbow surgery, or a congenital condition.
- Diagnosis is made clinically with assessment of active and passive elbow range of motion with a comparison to the contralateral side.
- Treatment is a trial of aggressive physical therapy to achieve functional range of motion. Operative management is indicated in the event of bony block to motion, congenital disease and lack of improvement with physical therapy.

• Etiology

- Pathophysiology
 - causes of elbow stiffness and contractures include
 - osteoarthritis
 - trauma (fractures)
 - surgery
 - cerebral palsy
 - traumatic brain injury
 - burns
 - prolonged immobilization
 - congenital conditions
 - arthrogryposis
 - congenital radial head dislocation
 - pathoanatomy
 - intrinsic causes
 - joint incongruity
 - synovitis
 - loose bodies
 - intra-articular fractures
 - malunions
 - osteochondritis dissecans
 - post-traumatic arthritis
 - coronoid osteophytes
 - olecranon tip osteophytes
 - radiocapitellar joint space narrowing
 - extrinsic causes
 - formation of eschar following a burn
 - heterotopic ossification
 - adhesions/contraction of the capsule
 - ligament contractures
 - scarring of posterior oblique portion of medial ulnar collateral ligament
 - mixed (intrinsic + extrinsic)
 - late effects of intrinsic conditions can lead to extrinsic stiffness

• Anatomy

- ROM
 - functional motion
 - 30° - 130° (extension-flexion)
 - most activities require a 100 degree arc of motion at the elbow to be functional
 - a 30 degree loss of extension is well tolerated by most patients
 - 50° - 50° (pronation/supination)
- Elbow ligaments and biomechanics
 - primary ligaments of elbow include
 - medial ulnar collateral ligament

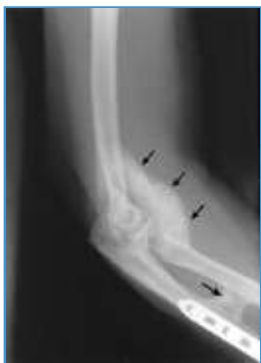- anterior bundle
 - is most important stabilizer to both valgus and distraction forces
 - posterior bundle
 - posterior oblique portion of medial ulnar collateral ligament
 - radial collateral ligament
 - annular ligament
- Nerves
 - ulnar nerve
 - proximity to the elbow joint places nerve at risk if joint is contracted

• Presentation

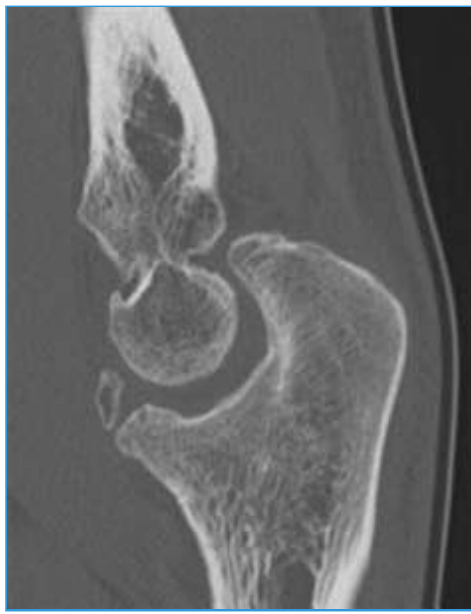- Symptoms
 - pain
 - pain in mid-arc of motion may indicate intra-articular pathology
 - extrinsic soft tissue contractures typically painful at the extremes of flexion and extension where bone impingement and soft tissue stretching may occur
 - decreased motion
 - often limits activities of daily living
- Physical exam
 - inspection
 - examine the skin around the elbow
 - look for scars from previous surgeries
 - inflammation
 - range of motion
 - measure elbow
 - flexion/extension
 - if $<90-100^\circ$ of flexion, posterior band of MCL is likely contracted and should be released
 - pronation/supination
 - neurological
 - assess median, radial, and ulnar nerve function

• Imaging

- Radiographs
 - recommended view
 - AP, lateral and oblique views
 - serial radiographs
 - if heterotopic ossification is noted



- findings
 - dependent on pathology causing stiffness/contractures
- CT scan
 - indications
 - loose bodies in joint



- non-unions
- joint incongruity
- abnormal bony anatomy

- MRI

- rarely indicated

- Treatment

- Nonoperative

- **NSAIDs, physical therapy with active and passive range of motion exercises**

- indications
 - first line of treatment in most cases
 - contractures <40°

- **static splinting**

- indications
 - failed trial of physical therapy with
 - elbow flexion contractures greater than 30° OR
 - elbow flexion less than 130°

- Operative

- **capsular release +/- release of posterior band of MCL**

- indications
 - extrinsic capsular contractures with normal joint surface congruency
 - most predictable beneficial results
 - patients with arthritis
 - less predictable once joint surface is incongruous
- outcomes
 - compliance with postoperative rehabilitation is critical
 - less predictable outcomes when ankylosis present preoperatively
- contraindications
 - charcot elbow joint
 - neurologic elbow disorder
 - poor skin
 - relative contraindication, may need plastic surgery (rotational flap)

- **osteophyte excision**

- indications
 - intrinsic contractures with arthritis confined to olecranon fossa
 - perform in conjunction with capsular release of bony block to terminal range of motion
 - bone typically should be removed from coronoid, coronoid fossa, olecranon, olecranon fossa

- **distraction interpositional arthroplasty**

- indications
 - intrinsic contractures with diffuse arthritis in high demand younger patients

- **total elbow arthroplasty**

- indications
 - intrinsic contractures with diffuse arthritis in low demand elderly patients
- outcomes
 - high failure rate in young, active patients
 - permanent 5-lb lifting restriction

- **musculocutaneous neurectomy**

- indications
 - neurogenic contractures with a flexion deformity of less than 90 degrees

- **Techniques**

- **Capsular release +/- release of posterior band of MCL**

- approaches
 - arthroscopic
 - technically demanding, radial nerve most at risk with portal placement, followed by ulnar and median nerves
 - posterior compartment - debridement of olecranon fossa/osteophytes with posterior capsular release
 - caution using suction medially due to proximity of ulnar nerve
 - anterior compartment - debridement of coronoid fossa/osteophytes with anterior capsulotomy or capsulectomy
 - open
 - lateral column approach (Morrey)
 - can be performed through lateral or posterior skin incision
 - elevate ECRL and BR anteriorly, triceps posteriorly
 - mobilize brachialis off of anterior capsule
 - debride/release anteriorly and posteriorly, including coronoid tip/fossa, olecranon tip/fossa, anterior and posterior capsule, and radiocapitellar joint
 - medial "over the top" column approach (Hotchkiss)
 - best for patients with extrinsic contractures, MCL calcifications, and/or baseline ulnar nerve symptoms
 - perform with decompression or transposition of ulnar nerve
 - release posterior band of MCL to increase flexion
 - working anterior to flexor-pronator mass, debride/release anteriorly, including coronoid tip/fossa and anterior capsule
 - combined medial and lateral approach
 - single posterior incision allows for medial and lateral column approaches
 - if <90-100° of flexion, posterior band of MCL is likely contracted and should be released with consideration of concomitant ulnar nerve decompression or transposition
 - timing of contracture release
 - consider contracture release 4 to 6 months post-injury/surgery if range of motion has plateaued and appropriate splinting/therapy has been performed
 - heterotopic ossification can be resected at maturity
 - determine based on visualization of well-corticalized margins of new bone (with lack of changes on serial radiographs)
 - laboratory studies not necessary to determine heterotopic bone maturity
 - rehabilitation
 - surgery performed under regional block can be helpful for pain control postoperatively
 - continuous passive motion through full range of motion
 - compressive dressing to help with swelling
 - therapy with active, and active-assist range of motion
 - use extension splinting as needed
 - use dynamic or static progressive splinting as needed
 - outcomes
 - improvement in range of motion can be variable
 - Most patients will retain two-thirds of the motion gained at the time of surgical release

- **Complications**

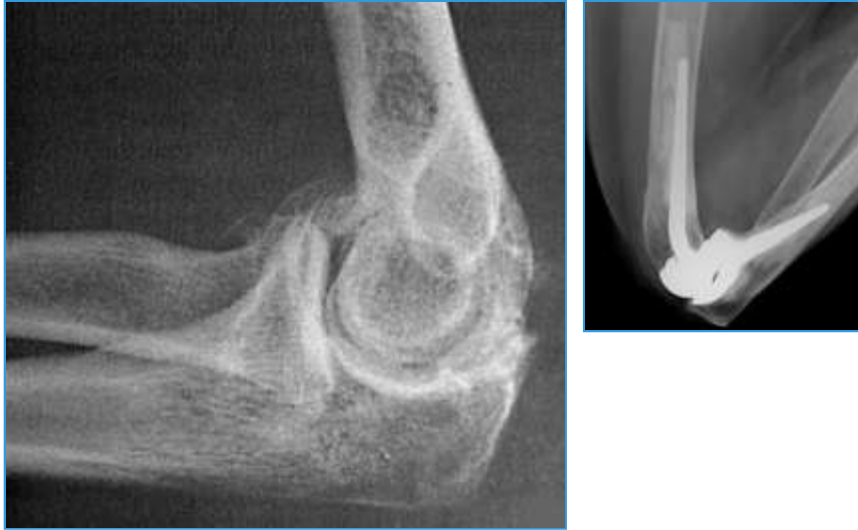- Post-operative heterotopic ossification
 - may treat prophylactically with low-dose radiation therapy or indomethacin
 - low-dose radiation may be contra-indicated with acute fractures due to risk of nonunion
- Transient ulnar neuropraxia
- Ulnar nerve damage
 - ulnar nerve transposition should be considered to reduce risk of ulnar nerve injury if preoperative flexion is less than 100 degrees
- Recurrent contracture

- Prognosis

- Patients are able to perform activities of daily living if elbow ROM of 30° (extension) to 130° (flexion) is achieved
 - most activities require a 100° arc of motion at the elbow to be functional
 - a 30° loss of extension is well tolerated by most patients
 - flexion loss causes more dysfunction than extension loss

39- Elbow Arthritis

Images



- Elbow Arthritis is degenerative joint disease of the elbow that can be broken into three main types: osteoarthritis, post-traumatic arthritis and inflammatory arthritis.
 - Diagnosis can be made with plain radiographs of the elbow.
 - Treatment can be nonoperative or operative depending on patient activity demands, severity of elbow pain and degree of elbow dysfunction.
- ### Etiology
- Osteoarthritis
 - epidemiology
 - incidence
 - clinically symptomatic primary osteoarthritis rare (2% prevalence)
 - demographics
 - men to women 4:1
 - middle-aged male laborers
 - can present from 20 to 70 years of age (average 50 years)
 - location
 - association with dominant hand
 - risk factors
 - strenuous manual labor
 - pathophysiology
 - etiologies include
 - primary arthritis
 - secondary causes
 - post-traumatic arthritis
 - osteochondritis dissecans
 - synovial osteochondromatosis
 - MUCL or ligamentous insufficiency, valgus extension overload
 - pathoanatomy
 - osteophytosis
 - capsular contracture
 - loose bodies
 - periarticular osteophytes block motion
 - preferentially involves radiocapitellar joint, sparing ulnohumeral articulation
 - Post-traumatic arthritis
 - epidemiology
 - second most common etiology of arthritis (rheumatoid historically the most common)
 - common after nonoperatively treated radial head fractures, elbow/fracture dislocations, and traumatic instability.
 - more common in younger patients compared to other etiologies (inflammatory and primary arthritis)
 - pathoanatomy
 - direct articular cartilage damage

- surface incongruity alters load distribution across the bearing surface
- may encompass entire joint or may be isolated to specific areas of the ulnohumeral and/or radiocapitellar articulation
- degenerative changes and early onset arthritis result as a consequence of the above
- may be accompanied by stiffness, chronic instability, malunion, or nonunion
- Inflammatory arthritis
 - epidemiology
 - rheumatoid arthritis
 - most common inflammatory arthropathy in adults
 - most prevalent elbow arthritis
 - elbow affected in 20% to 50%
 - causes progressive bone resorption and osteopenia
 - other causes
 - psoriatic arthritis
 - systemic lupus erythematosus
 - pigmented villonodular synovitis
 - pathophysiology
 - inflammation, chronic synovitis, ligament attenuation, periarticular osteopenia, capsular contracture
 - pathoanatomy
 - fixed flexion contracture
 - instability
 - ulnar or (less commonly) radial neuropathy
 - articular cartilage erosion
 - cyst formation
 - deformity
 - joint space loss
 - progressive instability

• Anatomy

- Primary stabilizing factors of elbow
 - anterior band MCL
 - anterior oblique fibers most important
 - stabilizes to both valgus and distraction forces
 - LCL
 - articular congruity between the olecranon, coronoid, and trochlea
- Secondary stabilizers
 - radial head
 - most important
 - provides 30% of valgus stability
 - most important in 0-30° of flexion and pronation
 - capsule
 - primary restraint to distraction forces in full extension
 - anconeus, and lateral capsule
 - secondary stabilizer to varus force
- Complete elbow anatomy and biomechanics

• Presentation

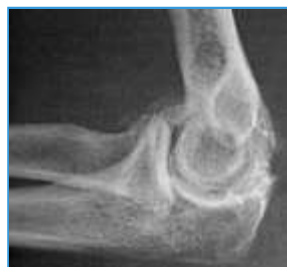- Elbow osteoarthritis
 - symptoms
 - progressive pain, typically at end range of motion, not mid-range
 - loss of terminal extension
 - painful locking or catching of elbow
 - night pain unusual
 - physical exam
 - loss of elbow range of motion (terminal extension)
 - forearm rotation relatively preserved early
 - ulnar neuropathy in up to 50% of patients
- Elbow inflammatory arthritis

- symptoms
 - hand and wrist involvement usually precedes elbow
 - pain and loss of motion
- physical exam
 - may have fixed flexion contracture
 - ligamentous incompetence can be seen
 - +/- ulnar neuropathy
 - evaluate cervical spine in all rheumatoid arthritis patients

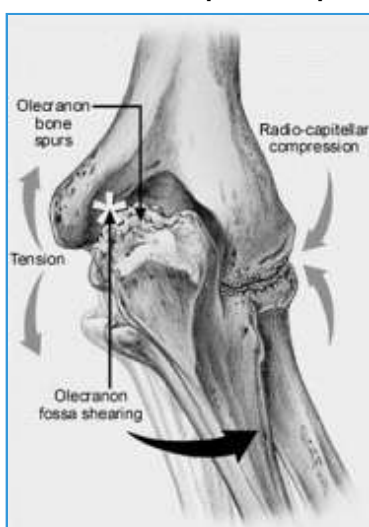
• Imaging

○ Radiographs

- recommended views
 - ap/lateral of elbow, cervical radiographs recommended for RA patients prior to surgery
- findings
 - elbow joint space narrowing



- ulnohumeral joint space relatively preserved
- osteophytes found at
 - coronoid process and fossa
 - radial head and fossa
 - olecranon tip and posteromedial olecranon fossa



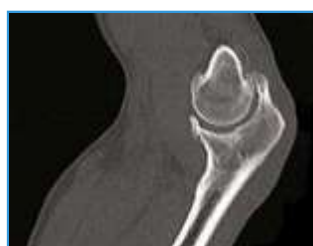- loose bodies (underestimated on plain radiography)
- periarticular erosions and cystic changes seen in RA
 - radiographic changes in RA graded by Larsen system

Stage	Description
1	Involves the soft tissues and has near-normal radiographs
2	Presents with periarticular erosions and mild cartilage loss; there may be evidence of soft-tissue swelling and osteopenia on radiographs
3	Radiographs show marked joint space narrowing
4	Progresses to advanced erosions penetrating the subchondral bone plate
5	Radiographs show advanced joint damage and loss of articular contour

Data from Traft AH. Arthropathy in seropositive arthritis of the elbow. In: Miller GR, Jr, Yamaguchi K, Remick ML, Gearty JB, eds. Shoulder and Elbow Arthropathy. Philadelphia, PA: Lippincott Williams & Wilkins; 2005. pp 301-310.

○ CT scan

- useful for surgical planning
- can help better define osteophytes and loose bodies

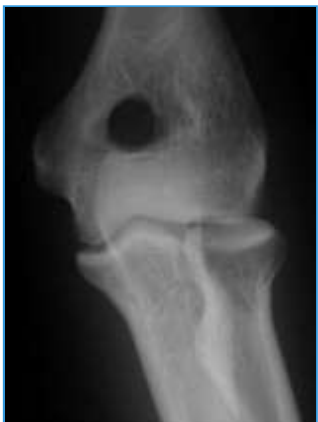
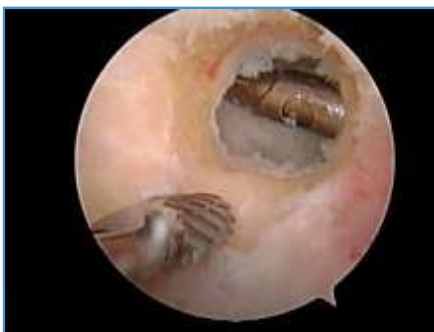
• Treatment

○ Nonoperative

- NSAIDs, cortisone injections, resting splints, and activity modification

- indications
 - mild to moderate symptoms
- Operative
 - **arthroscopic debridement and capsular release**
 - indications
 - mechanical symptoms from loose bodies
 - stiffness related to capsular contracture
 - stiffness related to bony block to motion
 - preferred in patients with $>90^\circ$ of motion
 - contraindications
 - Prior ulnar nerve transposition
 - severe contracture or arthrofibrosis
 - technique
 - removal of osteophytes and loose bodies (osteocapsular arthroplasty)
 - Capsular release
 - complications
 - neurologic injury
 - synovial fistula
 - recurrence of stiffness
 - **ulnohumeral distraction interposition arthroplasty**
 - indications
 - young, high demand patients with END STAGE arthritis (OA, RA, post-traumatic arthritis who would otherwise have received TEA if they were older)
 - does not require lifting restrictions like TEA
 - elbow instability is a contraindication
 - technique
 - can use
 - autogenous tensor fascia lata
 - achilles tendon allograft
 - complications
 - patients with severely limited preoperative motion (max extension $> 60^\circ$ and flexion $< 100^\circ$ are at risk for ulnar nerve dysfunction postoperatively)
 - should undergo a concomitant ulnar nerve decompression/transposition
 - **olecranon fossa debridement (Outerbridge-Kashiwagi procedure)**



- indications
 - younger patients with decreased ROM
- technique
 - burr hole through olecranon fossa
 - removes osteophytes and arthritic bone
 - increases range of motion
 - be sure to decompress the ulnar nerve if there is an flexion contracture preoperatively
- complications
 - failure to address anterior osteophytes or peripheral osteophytes on medial and lateral olecranon.

- **column procedure - medial or lateral open capsular release and bony resection**
 - indications
 - extrinsic contracture of the elbow that causes functional loss of extension and/or flexion
 - most common technique; go medial if need to gain flexion by excising posterior band of MCL
- **total elbow arthroplasty**
 - indications
 - older patients >65 years with severe elbow arthritis (Larsen stage 3-5)
 - complex distal humerus fracture in elderly with poor bone stock
 - distal humerus nonunion or malunion in elderly, lower demand
 - post-traumatic arthritis
 - contraindications
 - highly active patient <65
 - infection
 - Charcot joint
 - complications (as high as 43%)
 - infection
 - instability
 - loosening
 - wound healing problems
 - triceps insufficiency
 - ulnar neuropathy

• Techniques

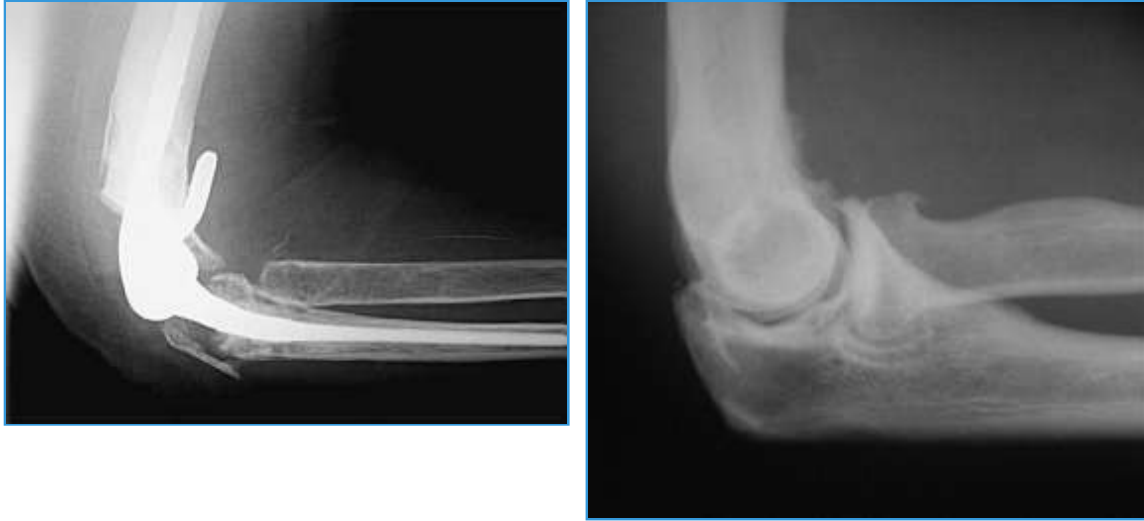- **Total Elbow Arthroplasty**
 - technique guide
- **Column procedure - limited lateral open capsular release and bony resection**
 - approach
 - a limited lateral based incision along the lateral distal supracondylar ridge
 - arthrotomies
 - anterior arthrotomy accomplished through ECRL/Common extensor interval
 - stay anterior to LUCL to avoid iatrogenic injury
 - anterior capsule released and coronoid and coronoid fossae debrided
 - posterior arthrotomy accomplished by elevating triceps from the posterior aspect of the humerus
 - posterior capsule is released, the olecranon and olecranon fossae are debrided

• Complications

- Total complication rate may be as high as 43%
- Infection and/or wound healing complications
 - Risk factors
 - prior elbow surgery
 - prior infection (esp. *S. epidemidis*)
 - psychiatric co-morbidity
 - rheumatoid arthritis
 - wound drainage
 - re-operation (any reason)
 - poor skin quality (e.g. long term steroid use)
 - **Two-stage revision arthroplasty: poor survival**
- Injury to ulnar nerve
- Triceps avulsion
- Fracture
- Aseptic loosening
 - Risk factors
 - linked implants
 - post-traumatic osteoarthritis
- Implant failure (mechanical)
- Instability
 - Risk factors
 - unlinked implants

40- Total Elbow Arthroplasty

Images



• summary

- Total Elbow Arthroplasty (TEA) is an increasingly used motion-preserving modality for the treatment of many debilitating elbow pathologies.
- Primary indications include rheumatoid arthritis, post-traumatic arthritis, and intra-articular distal humeral fractures in the elderly with poor bony quality.
- Semiconstrained implants have the best longevity and most optimal functional outcomes.

• Epidemiology

- TEA for trauma is one of the fastest-growing indications

• Etiology

- Forms of elbow arthroplasty
 - total elbow arthroplasty
 - hemi elbow arthroplasty
 - radiocapitellar
 - distal humeral
 - ulnohumeral distraction & interpositional arthroplasty
 - olecranon fossa debridement
 - radial head arthroplasty

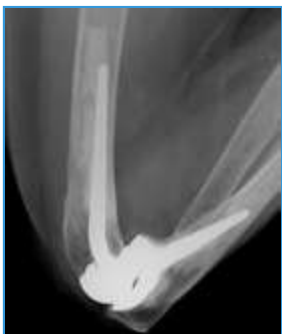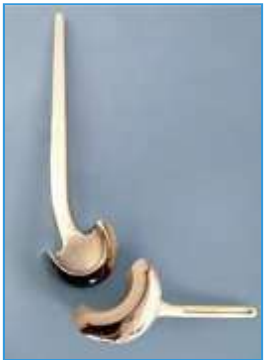• Indications

- Indications
 - rheumatoid arthritis (RA)
 - indication
 - 10-20% of patients with RA will have arthritic changes in the elbow
 - TEA considered for Larsen stages 3 to 5 with:
 - functional loss
 - pain
 - instability
 - ideally, patient should be older than 65 years old
 - outcomes
 - longest survivorship when TEA is performed for RA compared to other indications
 - most reliable with advanced, refractory RA
 - primary osteoarthritis (advanced)
 - indication
 - patient should be older than 65 years old
 - mid-arc pain with activity resulting from ulnotrochlear joint cartilage loss
 - outcomes
 - 10-year implant survival about 80-85% for TEA for primary OA
 - fracture

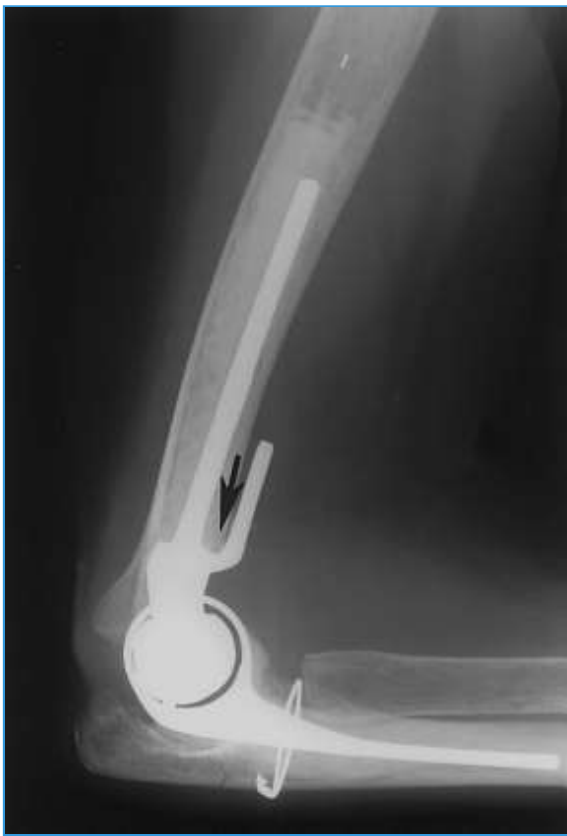- indication
 - physiologically elderly patient (e.g., > 70 years) with:
 - acute complex, unreconstructable intra-articular distal humerus fracture
 - missed elbow fracture dislocation
 - poor quality bone
 - outcomes
 - faster recovery with more predictable functional outcomes compared to fixation strategies
 - limitations of lifting weight more than 5 to 10 pounds to avoid implant loosening
- posttraumatic osteoarthritis (advanced)
- chronic instability
- Contraindications
 - absolute
 - active infection (arthrodesis favored)
 - Charcot joint
 - relative
 - poor neurologic control of affected extremity
 - active patient younger than <65 years old
 - olecranon osteotomy

• Implants

- Designs
 - unconstrained or unlinked components

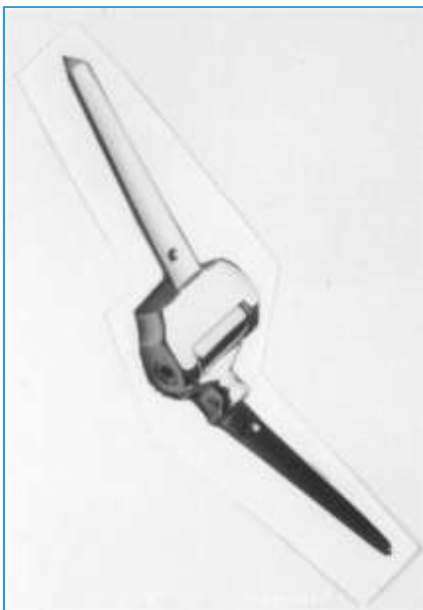


- example
 - Ewald capitello-condylar design
- technical aspects
 - requires competent collateral ligaments and soft tissue envelope
 - requires good bone quality
- outcomes
 - instability is most common complication (5-10% dislocation)
 - precise component alignment is required
 - no proven superiority or clear indication compared with semiconstrained/linked
- semiconstrained or linked components



- examples
 - Coonrad-Moorey design
- technical aspects
 - "sloppy hinge" allows for some varus-valgus and rotational laxity
 - reduces stress on bone-cement interface, which reduces incidence of component loosening
- outcomes
 - best results of all the designs
 - complication of early humeral loosening with designs without an anterior flange

- constrained



- example
 - Dee design
- technical aspects
 - rigid hinged design
 - theoretically most stable design (versus unlinked)
- outcomes
 - highest loosening rates compared to semiconstrained and unconstrained designs

- Design pearls

- component stems (ulna and humerus) have improved fixation and reduced loosening
- humeral component extracortical anterior flange resists posteriorly directed and rotational forces
- radial head not needed for stability in linked TEA designs
 - radial head often debrided or resected in RA, due to mechanical symptoms or pain

- Key Technical Concepts

- Preoperative care

- clinical evaluation
 - age > 65
 - low demand patient
 - able to comply with post-operative weight-bearing restriction (none do so be careful who you operate on)
 - medical optimization
- imaging

- standard radiographs
 - AP and lateral views of elbow
 - assess bone stock
 - ensure medial and lateral columns are intact
 - assess canal diameter for implant design
 - cervical spine
 - flexion-extension views
 - rheumatoid arthritis patients
- CT scan
- Surgical
 - positioning
 - supine
 - arm draped free
 - requires an assistant to hold the arm over the patients chest
 - surgeon must take care to avoid the endotracheal tube
 - lateral decubitus
 - arm positioned over a bolster
 - minimizes the need for an assistant to hold arm
 - decreases the ability to manipulate the arm
 - approach
 - triceps-reflecting, triceps-splitting, and triceps-sparing
 - triceps-reflecting (Bryan-Morrey)
 - triceps reflected from medial to lateral in continuity with the anconeus
 - triceps re-attached to ulna with nonabsorbable suture through bone tunnels
 - There can be associated weakness or loss of elbow extension due to the detachment of the triceps brachii insertion from the olecranon.
 - triceps tongue
 - raise fascial tongue from olecranon back proximally
 - release collateral ligaments proximally and distally
 - can be used for fractures or TEA
 - triceps-splitting
 - triceps is longitudinally divided in continuity with forearm fascia over dorsal ulna
 - triceps can also be split proximally with a V-shaped turndown of the tendon, leaving insertion onto olecranon intact
 - allows for extensor mechanism lengthening if needed
 - triceps-sparing
 - triceps preserved intraoperatively, but exposure can be challenging
 - medial and lateral borders of triceps are mobilized
 - best for using TEA to manage acute distal humerus fractures
 - triceps "on"
 - direct midline, posterior incision
 - identify, release and protect the ulnar nerve
 - release the flexor-pronator mass and medial collateral ligament from medial epicondyle
 - elevate the triceps off the posterior humerus towards the lateral intermuscular septum
 - release the common extensors and lateral collateral ligament complex
 - disarticulate the ulno-humeral joint
 - technique
 - bone preparation
 - preparation of humeral component
 - resect the olecranon fossa of distal humerus
 - keep medial and lateral column intact
 - broaching to appropriate sized component
 - preparation of ulnar component
 - resect the olecranon tip of proximal ulna
 - resect tip of coronoid to avoid impingement on anterior flange which will cause axial pistoning of ulna and loosening
 - broaching to appropriate sized component
 - implant insertion

- component design
 - semiconstrained most common
 - modern cement preparation and technique
 - humerus component
 - prepare a wedge-shaped piece of bone for placement behind the humeral flange
 - maintain component orientation relative to the posterior flat surface of the distal humerus
 - ulnar component
 - orient the implant perpendicular to the dorsal flat surface of the olecranon
- Postoperative care
 - early period of immobilization
 - early motion after TEA is associated with wound complications, instability, and hardware loosening
 - typically immobilize for 4 weeks after surgery
 - lifelong weightlifting restriction of less than 5-10 lbs

• Outcomes

- Rheumatoid arthritis TEA outcomes
 - 10 year survivorship
 - 92.4% rate of survivorship free of revision at 10 years
 - however very high complication rate (14%)
 - triceps avulsion
 - deep infection
 - periprosthetic fracture
 - aseptic loosening
- Post traumatic arthritis TEA outcomes
 - 5 year survivorship
 - most achieve functional ROM and patient satisfaction
 - high complication rate (27-43%)
 - high re-operation rate (25%)

• Complications

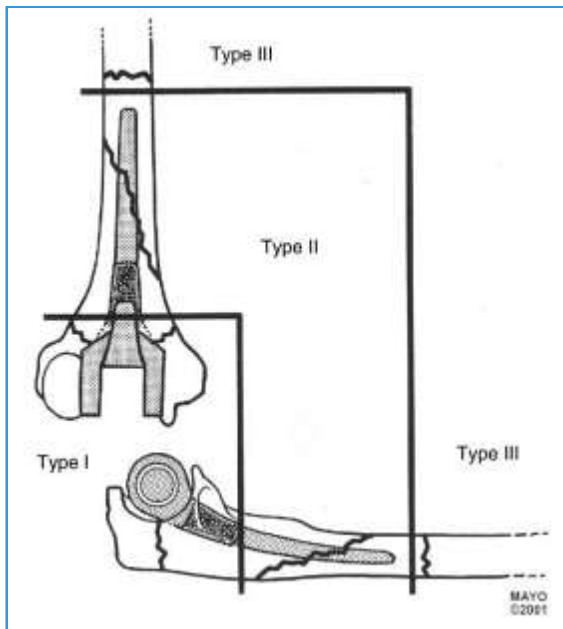
- Aseptic loosening (radiographic 17%, clinical 6%)
 - most common mode of failure for constrained
- Infection (8%)
 - acute infection (< 30 days)
 - treatment
 - aggressive serial irrigation and debridement and antibiotic bead placement
 - success depends on organism
 - staphylococcus epidermidis is associated with persistent infection because it is an encapsulating organism, and it is best treated with implant removal and IV antibiotic
 - chronic infection
 - treatment
 - two staged reimplantation versus resection arthroplasty in medically ill patients or those with inadequate bone stock.
- Instability (7-19%)
 - most common mode of failure for semiconstrained
- Bushing wear (obtain AP xrays and varus/valgus angle of > 10 degrees is concerning)
 - common mode of failure for constrained
- Wound healing (higher with longterm steroid use)
- Ulnar neuropathy
- Triceps insufficiency
- Bone loss

Grading Scale for Humeral Bone Loss²⁹

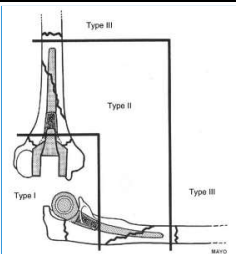
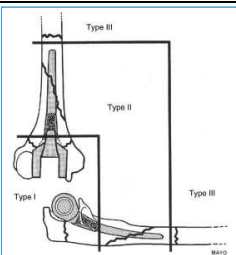
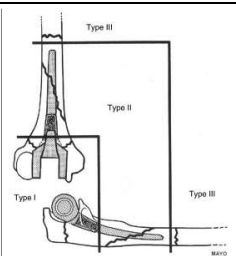
Grade	Humeral Bone Stock
I	Damage to the articular surface only; intact subchondral bone
II	Absence of trochlea; intact medial and lateral epicondyles
III	Absence of medial or lateral epicondyle
IV	Loss of medial and lateral epicondyle or resection proximal to the level of the olecranon fossa

- from multiple revisions, fractures, osteolysis
- graded based on humeral bone stock
- treatment
 - up to 8cm of distal humeral loss can be replaced with longer prosthesis with extended anterior flange or endoprosthesis (total humerus)
 - salvage options include flail elbow, amputation, arthrodesis

○ Periprosthetic fracture

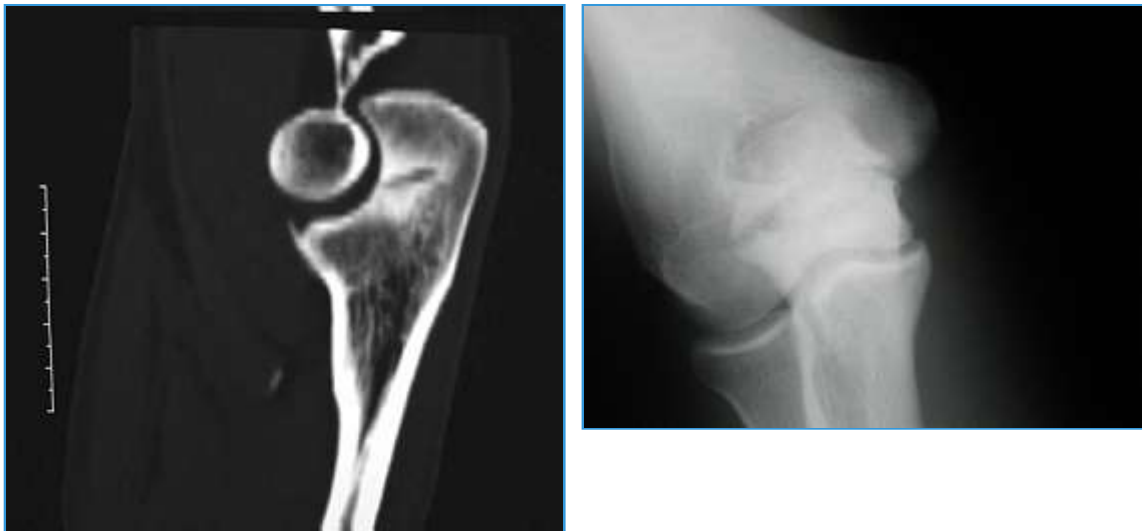

- in 5-30% of primary TEAs
- causes
 - trauma
 - osteoporosis
 - aseptic loosening
 - stress shielding
 - poor technique
 - non compliance with activity restriction
- classification based on that for periprosthetic femoral fractures (see table below)

■ Mayo (O'Driscoll & Morrey) Classification of Periprosthetic fracture			
	■ Characteristics	■ <i>Treatment</i>	
■ Type I	<ul style="list-style-type: none"> ■ Periarticular fracture involving the humeral condyle or olecranon. ■ Caused by osteolysis around hinge components and distracting forces from muscle attachments 	<ul style="list-style-type: none"> ■ Undisplaced - Immobilization /soft tissue repair is sufficient to achieve fibrous union (Rigid fixation not required). ■ Displaced - ORIF with heavy nonabsorbable sutures or tension band wiring (if limited periprosthetic bone) 	
■ Type II	<ul style="list-style-type: none"> ■ Fracture along length of humeral or ulnar stem. Subtypes: ■ II1: well-fixed implant ■ II2 : loose implants, good bone stock ■ II3 : loose implants, severe bone loss 	<ul style="list-style-type: none"> ■ I1 : ORIF with component retention +/- strut allograft ■ II2 : Revision arthroplasty using long-stem prosthesis ± strut allograft and impaction bone grafting. Locking plates/ cerclage wires may be added for added stability. ■ II3 : Require revision arthroplasty with extensive allograft supplementation. Often times require resection arthroplasty 	
■ Type III	<ul style="list-style-type: none"> ■ Distal to prosthesis. ■ Treated like routine fractures. ■ Radiographs/CTs to ensure implants are not loose, cement mantle not cracked. 	<ul style="list-style-type: none"> ■ If implants are well-fixed, immobilization for humerus and ORIF for ulna. ■ If implants are loose, treat as Type II2 fractures. 	

41- Olecranon Stress Fracture

Images



• summary

- Olecranon Stress Fractures are rare elbow injuries that predominately affects throwing athletes.
- Diagnosis can usually be made with plain radiographs of the elbow but may require an MRI or CT scan to confirm the diagnosis in the early stages.
- Treatment is generally rest from pitching, pain control, and brief period of immobilization.

• Epidemiology

- Anatomic location
 - predominantly involves the epiphyseal plate
 - fractures line may propagate to be either transverse or oblique in orientation

• Etiology

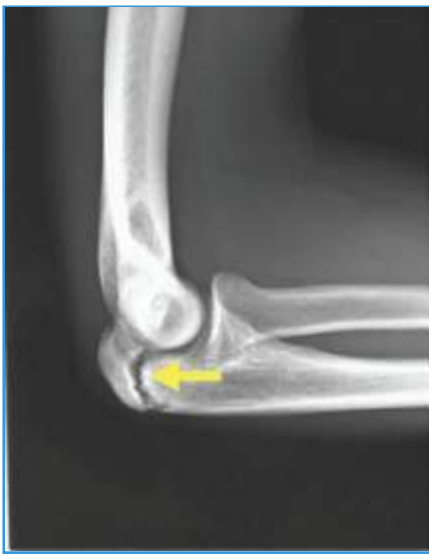- Pathophysiology
 - mechanism of injury
 - three commonly accepted theories
 - olecranon posteromedial impingement
 - triceps traction force
 - valgus extension overload
- Associated injuries with throwing movements
 - ulnar collateral ligament tears
 - medial epicondyle avulsion fracture

• Presentation

- Symptoms
 - posteromedial olecranon pain of the throwing arm
 - improves with rest
 - worse with throwing movements
- Physical exam
 - inspection
 - mild swelling over olecranon
 - localized tenderness
 - motion
 - valgus instability stress test
 - may indicate associated UCL injury

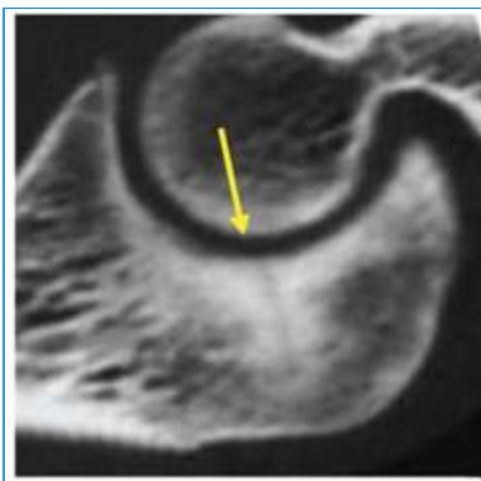
• Imaging

- Radiographs



- recommended views
 - AP, lateral, oblique views of elbow
- optional views
 - valgus stress views
 - contralateral elbow for comparison
- findings
 - physeal widening, delayed fusion, or fragmentation
 - widening of the medial joint space with UCL injuries

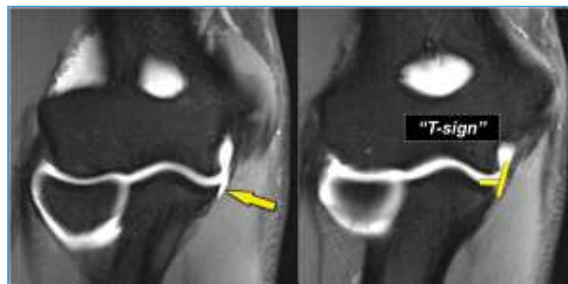○ CT



- views
 - best seen on lateral views
- findings
 - typical fracture pattern
 - originates from the articular surface
 - runs toward the dorsal-proximal direction

○ MRI

- indications
 - suspected UCL tear
- views
 - coronal T2 fat-saturated views
- findings
 - T-sign indicative of UCL tears



• Treatment

○ Nonoperative

- **short-term administration of NSAIDs, rest +/- temporary splinting**
 - indications
 - first-line treatment
 - modalities
 - initial 4-6 weeks of rest (removal from sport for up to 3 months)
 - progressive ROM exercises
 - avoiding valgus loading forces (e.g. throwing)

- electrical bone stimulation may also be considered
- consider vitamin D and calcium supplementation
- Operative
 - **open internal fixation**
 - indications
 - delayed fracture union
 - modalities
 - large compression screw
 - tension band wire

42- Medial Ulnar Collateral Ligament Injury

• Summary

- Medial Ulnar Collateral Ligament Injuries are characterized by attenuation or rupture of the ulnar collateral ligament of the elbow leading to valgus instability in overhead throwing athletes.
- Diagnosis is usually made by a combination of physical exam and MRI studies.
- Treatment for most individuals is rest and physical therapy. Surgery is reserved for high level overhead athletes such as pitchers.

• Epidemiology

- Incidence
 - literature shows increasing occurrence of UCL injuries and reconstructions
 - becoming more common among high school and amateur pitchers
- Demographics
 - overhead athletes who place significant valgus stress on their elbows
 - originally described among javelin throwers, now much more common in baseball pitchers
 - relatively uncommon in skeletally immature throwing athletes
 - little leaguers' elbow
 - more common cause of medial elbow pain with decreased throwing effectiveness and distance
- Risk factors
 - exceeding youth baseball pitch count and inning restrictions
 - higher pitch velocity
 - deficits along kinetic chain (shoulder and core weakness, loss of shoulder motion, etc.)

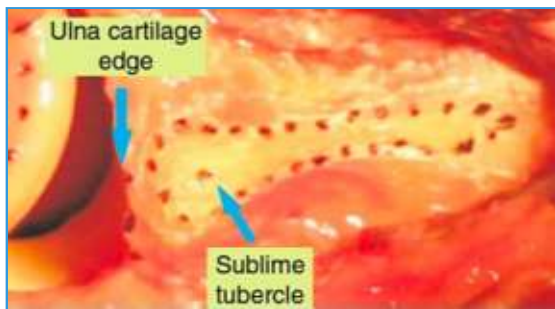
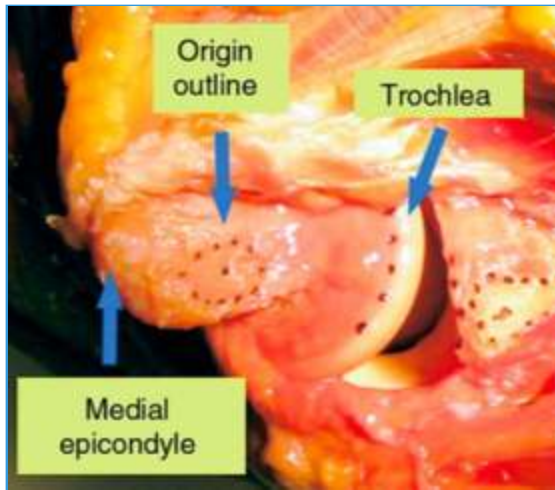
• Etiology

- Pathophysiology
 - mechanism of injury
 - acute trauma
 - often associated with elbow dislocations
 - overuse injury
 - biomechanical forces
 - microtrauma from repetitive valgus stress leads to rupture of the anterior band of the medial UCL
 - baseball pitchers place significant valgus stress on the elbow in the late cocking and early acceleration phase of throwing
 - elbow valgus load increases with poor throwing mechanics and decreases with trunk-scapular kinesis, forearm pronation, dynamic flexor-pronator stabilization
 - valgus load is highest in the late cocking/acceleration phase of throwing
 - iatrogenic
 - excessive olecranon osteophyte resection places the MCL at risk
- Associated conditions
 - traction-related ulnar neuritis
 - olecranon (posteromedial) impingement
 - elbow arthritis

• Anatomy

- Osseous
 - elbow is complex hinge composed of ulnohumeral, radiocapitellar, and radioulnar joints
 - valgus carrying angle ranging from 6 to 11 degrees
- Ligaments
 - medial ulnar collateral ligament (UCL)
 - divided into three components
 - anterior oblique ligament
 - strongest and most significant stabilizer to valgus stress

- courses from anteroinferior ridge on medial epicondyle to 2.8 mm distal to the ulna articular margin on the sublime tubercle

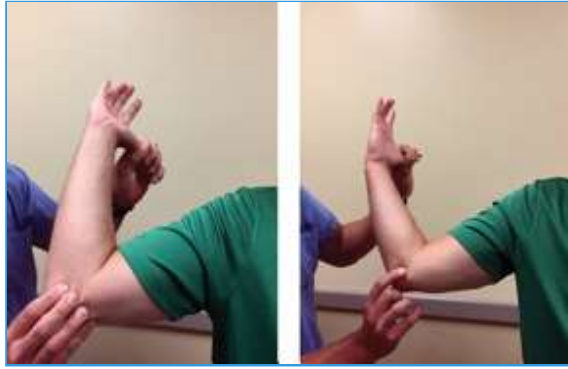

- mean length of 54 mm
- subdivides into anterior and posterior bands.
 - anterior band is primary restraint to valgus stress, exhibiting nearly isometric strain during elbow ROM
 - posterior band exhibits increasing strain during higher degrees of elbow flexion
- posterior oblique ligament (posterior bundle)
 - demonstrates the greatest change in tension from flexion to extension
 - tighter in flexion
- transverse ligament
 - no contribution to stability
- Biomechanics
 - elbow stability evenly split between osseous and soft tissue structures
 - UCL primary restraint to valgus stress from 30 to 120 degrees of flexion
 - flexor-pronator and joint capsule also contribute

• Presentation

- History
 - acute injuries may present with a "pop" associated with pain and difficulty throwing
- Symptoms
 - decreased throwing performance
 - loss of velocity
 - loss of control and accuracy
 - pain
 - medial or posterior elbow pain during late cocking and acceleration phases of throwing
 - many throwers also have posteromedial pain due to valgus extension overload felt during the deceleration phase
 - ulnar nerve symptoms
 - paresthesias down ulnar arm into ring and small fingers
- Physical examination
 - inspection
 - tenderness along elbow at or near MCL origin
 - posteromedial tenderness may be due to valgus extension overload
 - evaluate the integrity of the flexor-pronator mass
 - evaluate for presence of palmaris longus tendon
 - range of motion
 - seasoned throwers may lack full extension
 - evaluate shoulder and rest of kinetic chain
 - neurovascular
 - evaluate for ulnar neuropathy and/or subluxation
 - provocative tests
 - valgus stress test

- flex elbow to 20 to 30 degrees (unlocks the olecranon), externally rotate the humerus, and apply valgus stress
- 50% sensitive
- milking maneuver

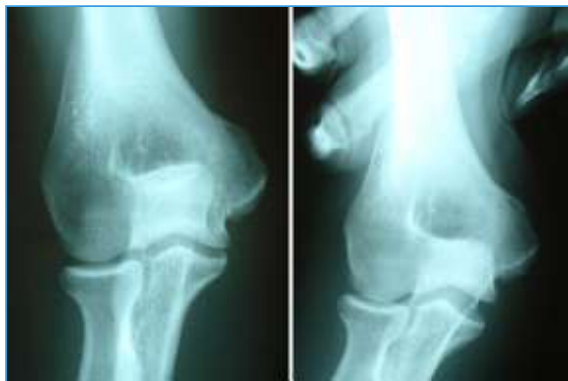

- creates valgus stress by pulling on the patient's thumb with the forearm supinated and elbow flexed at 90 degrees
- patient may be supine or seated/standing
- positive test is a subjective apprehension, instability, or pain at the MCL origin
- moving valgus stress test
 - place elbow in same position as the "milking maneuver" and apply a valgus stress while the elbow is ranged through the full arc of flexion and extension
 - positive test is a subjective apprehension, instability, or pain at the MCL origin between 70 and 120 degrees
 - 100% sensitive and 75% specific

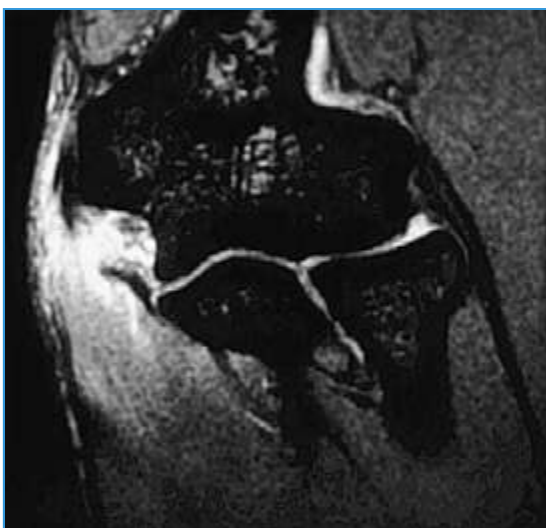
• Imaging

○ Radiographs

- recommended views
 - AP and lateral of the elbow
 - static x-rays are often normal
 - may show loose bodies or calcifications of UCL
- optional views
 - oblique views to evaluate the olecranon
 - gravity or manual stress radiographs of both elbows



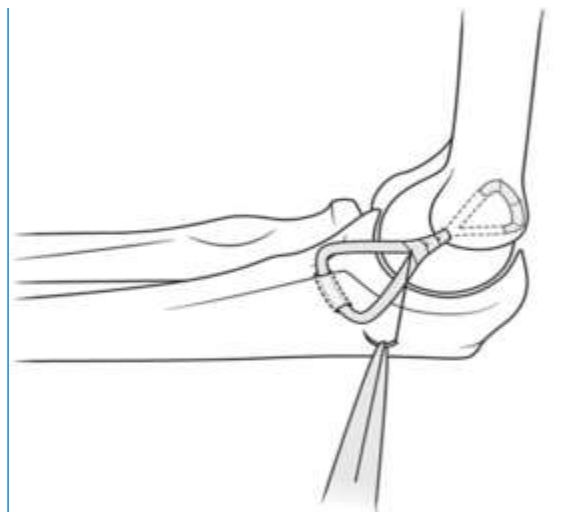
- may show medial joint-line opening >3 mm (diagnostic)
- findings
 - assess for a posteromedial osteophyte (due to valgus extension overload)
- MRI
 - indications
 - high suspicion for UCL injury and/or intra-articular pathology
 - MR-arthrogram - diagnostic



- use of dye more accurate
- sensitivity 92%, specificity 100%
- findings

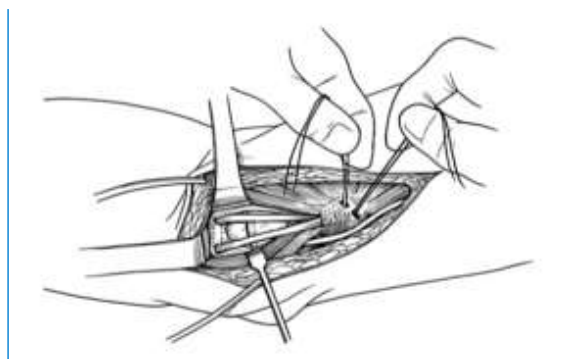
- thickened ligament (chronic injury), calcifications, and tears
 - midsubstance tears or proximal/distal avulsions
 - full-thickness or partial undersurface tears
 - capsular "T-sign" with contrast extravasation
- Dynamic ultrasound
 - can evaluate laxity with valgus stress dynamically
 - sensitivity and specificity operator dependent
- **Differential**
 - Medial epicondylitis
 - Flexor-pronator strain
 - Ulnar neuropathy
 - Valgus extension overload
- **Treatment**
 - Nonoperative
 - **rest and physical therapy**
 - indications
 - first line treatment in most cases
 - partial tears
 - outcomes
 - 42% return to preinjury level of sporting activity at an average of 24 weeks
 - Operative
 - **UCL anterior band ligament reconstruction (Tommy John Surgery)**
 - indications
 - high-level throwers that want to continue competitive sports
 - failed nonoperative management in partial tears and willing to undergo extensive rehabilitation
 - outcomes
 - 90% return to preinjury levels of throwing with newer reconstruction techniques
 - humeral docking associated with better patient outcomes and lower complication rate compared to figure-of-8 fixation
 - humeral docking has shown higher rates of return to sport compared to Jobe and modified Jobe techniques
 - humeral docking and cortical button techniques are biomechanically stronger than figure-of-8 and interference screw fixation
 - humeral docking with interference screw fixation on the ulnar side showed 95% strength of the native UCL
 - **UCL repair**
 - indications
 - not clarified in the literature
 - mostly performed in young athletes with avulsion-type tear patterns
 - outcomes
 - originally performed with poor results, replaced by reconstruction
 - multiple, recent case series show promising results with novel, augmented techniques
- **Techniques**
 - **Rest and physical therapy**
 - technique
 - 6 weeks of cessation from throwing
 - initiate physical therapy for flexor-pronator strengthening and improving throwing mechanics (after 6 weeks and symptoms/pain have resolved)
 - progressive return to throwing program
 - **UCL anterior band ligament reconstruction**
 - overview
 - various modifications of original Jobe technique exist
 - all create an anatomic reconstruction of the native ligament from medial epicondyle to ulnar sublime tubercle
 - none are stronger than native ligament
 - approach
 - flexor-pronator muscle-splitting approach (decreased morbidity of historic flexor-pronator mass detachment)
 - some surgeons elevate flexor-pronator mass when performing modified Jobe technique

- in-situ ulnar nerve decompression
 - patients without pre-operative ulnar nerve symptoms should not undergo routine ulnar nerve decompression or transposition
 - patients with pre-operative ulnar nerve symptoms may be treated with isolated ulnar nerve decompression with or without transposition
 - patients with ulnar nerve subluxation should be treated with ulnar nerve transposition
 - UCL and joint capsule identified, ligament repaired in side-to-side fashion
- soft tissue
 - palmaris longus autograft most common graft (gracilis autograft or allograft also options)
 - single, distal transverse incision centered over palmaris
 - tendon identified and tagged with suture, underlying median nerve protected
 - tendon followed proximally with additional incision made centered over tendon
 - confirming enough length obtained, tendon harvested, and wounds closed
- bony work and reconstruction
 - modified Jobe technique



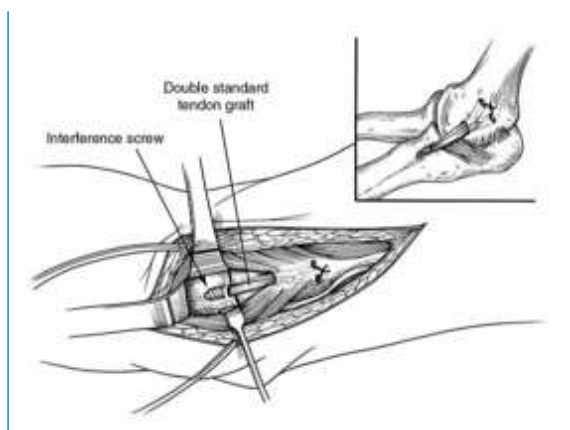
- two connected bone tunnels made in medial epicondyle of humerus in "Y" configuration
- single bone tunnel created by connecting two angled drill holes in ulnar sublime tubercle
 - alternatively, commercially available drill guides may be used
- graft passed through ulnar tunnel, then graft ends through humeral tunnels
- graft sutured to itself in figure-of-8 configuration
 - extra strands may be added if graft accommodates this

- docking technique



- single bony socket made in medial epicondyle
- single bone tunnel created by connecting two angled drill holes in ulnar sublime tubercle
- graft passed through ulnar tunnel, suture limbs passed through two bone punctures, graft shuttled into humeral socket
- graft suture ends tied over bony bridge on medial epicondyle

- hybrid interference-screw technique



- docking tunnel/socket made on the humerus
- single longitudinal bone socket made into ulna with interference-screw fixation
 - felt to decrease risk of iatrogenic fracture
- cortical suspensory fixation, ex. "Endo-button" (Smith & Nephew) reconstruction

- used on ulna to stabilize graft
 - more commonly used in revision setting
 - postoperative care
 - early
 - early active wrist, elbow, and shoulder range of motion
 - incorporation of shoulder girdle, core, and hip strengthening exercises
 - strengthening exercises beginning four to six weeks post-op
 - mid-term
 - initiate a progressive throwing program at four months
 - avoid valgus stress until 4 months post-op
 - return to competitive throwing at 9-12 months post-op
 - **UCL repair**
 - approach
 - as above
 - soft tissue
 - ulnar nerve in-situ release or transposition
 - ligament dissected and avulsion identified
 - bony work
 - ligament sutured and secured to either humerus or ulna with suture anchor
 - repair can be augmented with high-strength suture
 - postoperative care
 - similar to UCL reconstruction
- **Complications**
 - Ulnar neurapraxia
 - most common, 3-26% incidence
 - treatment
 - observation as majority resolve within a few months
 - Medial antebrachial cutaneous (MABC) nerve injury
 - crosses at distal aspect of the incision
 - Fracture of ulna or medial epicondyle
 - risk factors
 - small bone bridge during tunnel placement
 - treatment
 - may require internal fixation of fracture, or switch to larger graft fixation device
 - Elbow stiffness
 - risk factors
 - heterotopic ossification
 - treatment
 - early directed therapy focusing on obtaining motion
 - HO excision around 6 months, if present
 - Inability to regain preinjury level throwing ability
 - more common following revision reconstructions
- **Prognosis**
 - Formerly a career-ending injury
 - UCL reconstruction provides high rates of return to throwing and sport
 - worse outcomes following revision reconstructions
 - Outcomes and return to sport following surgical MUCL reconstruction (Tommy John surgery) depend on precise recreation of the MUCL and diligent rehabilitation.

43- Valgus Extension Overload Pitchers Elbow

• summary

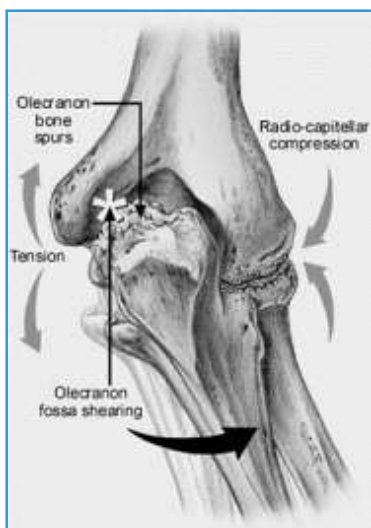
- Valgus Extension Overload, also known as Pitcher's elbow, is a condition characterized by posteromedial elbow pain related to repetitive microtrauma in throwing athletes.
- Diagnosis is made clinically with posteromedial elbow pain that worsens with elbow extension, and confirmed with radiographs or advanced imaging showing osteophyte formation on the posteromedial olecranon.
- First line treatment is nonoperative with rest, activity modifications, and injections. Operative resection of osteophytes and loose bodies are indicated in patients with persistent symptoms.

• Epidemiology

- Incidence
 - overall prevalence is unknown, however, may be as high as 65% in elite baseball players with symptomatic elbows
- Demographics
 - dominant arm in throwing athletes
 - can be seen in non-throwing athletes: swimmers, volleyball players, gymnasts, racquet-sport athletes, and golfers
- Location
 - posteromedial olecranon
 - posterior trochlea
 - olecranon fossa

• Etiology

○ Pathophysiology

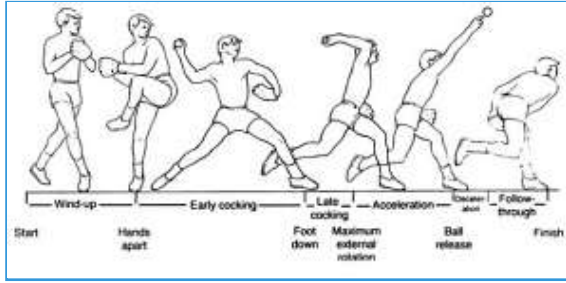


- repetitive stress of pitching leads to
 - excessive shear forces on medial aspect of olecranon tip and olecranon fossa
 - lateral radio-capitellar compression
 - posterior extension overload
 - medial tension at MCL
- pathologic biomechanics leads to
 - cartilage injury from repetitive impaction of olecranon into olecranon fossa
 - osteochondral lesions of the capitellum
 - osteophyte formation
 - posteromedial humerus
 - olecranon
 - loose bodies from fragmentation
 - UCL can become attenuated with repetitive strain
- Associated conditions
 - cubital tunnel syndrome
 - concurrent cubital tunnel syndrome in ~25% of cases

• Presentation

- Symptoms
 - pain in posteromedial elbow with full extension of elbow

- pain typically occurs in deceleration / follow-through phase of pitching (rarely during acceleration phase)



- loss of terminal elbow extension

- Physical exam

- palpation
 - tender to palpation over posteromedial olecranon
- motion
 - flexion contracture
- provocative tests
 - crepitus due to loose bodies and synovitis in the posterior compartment
 - pain with forced elbow extension
 - sustained elbow extension - "arm bar test"
 - repeated terminal elbow extension - "bounce test"

- Imaging

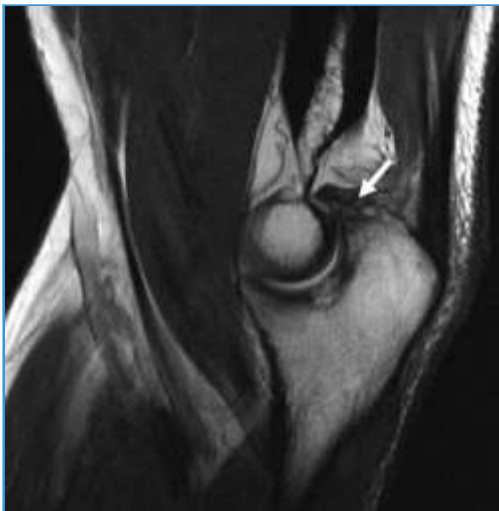
- Radiographs

- recommended views
 - AP, lateral, oblique of the elbow
- findings
 - often show osteophyte formation on the posteromedial olecranon
 - loose bodies from fragmentation of capitellum
 - possible calcium deposits on the substance of the MCL
 - hypertrophy of the humerus
 - results in decreased space for articulation of olecranon process within the fossa

- CT

- best for demonstrating detailed osseous anatomy
- 3D reconstructions can be helpful for surgical planning

- MRI



- helpful in evaluating associated injuries including partial/complete MCL tears

- Treatment

- Nonoperative

- **anti-inflammatory medications, cessation of throwing or offending activities, improvement of throwing mechanics, +/- steroid injections**
 - indications
 - first line of treatment
 - patients who are currently mid-season or are at the end of their competitive careers
 - technique
 - flexor-pronator strengthening
 - pitching instruction to correct poor mechanics

- Operative

- **arthroscopic osteophyte resection +/- ulnar nerve decompression**
 - indications

- persistent symptoms that fail to improve with nonoperative treatment
- contraindications
 - MCL insufficiency is a relative contraindication for olecranon debridement alone
- technique
 - arthroscopy procedures can include debridement or drilling of chondromalacia, debridement of lateral meniscoid lesion or posterolateral plica, osteophyte excision, loose body excision
 - care must be taken to only remove osteophyte and not normal olecranon as this may result in a loss of bony restraint and increase stress on the MCL
- ulnar nerve release vs. transposition
 - indications
 - significant ulnar nerve symptoms
 - ulnar nerve can be subluxed over medial epicondyle

• TECHNIQUES

- **anti-inflammatory medication, cessation of throwing activities, improvement of throwing mechanics +/- steroid injection**
 - duration
 - first-time symptomatic patients
 - 10-14 days of active rest
 - followed by graduated throwing program
 - repeat symptomatic patients
 - 4-6 weeks of active rest
 - followed by a lengthened gradual return to throwing activities
- **Arthroscopic Osteophyte Resection**
 - positioning
 - can be performed
 - lateral decubitus
 - prone
 - supine
 - consider supine positioning with articulating arm holder when performing arthroscopic resection in conjunction with MCL reconstruction to ease in transition to open procedure
 - technique
 - mark relevant surface anatomy
 - bony landmarks, portal sites, course of the ulnar nerve and approximate location of posteromedial osteophyte
 - perform routine diagnostic arthroscopy
 - removing any loose bodies encountered and note sites of chondromalacia or osteochondral lesions
 - begin posteromedial osteophyte resection by establishing a posterolateral viewing portal if not already created during diagnostic arthroscopy
 - create direct posterior portal using spinal needle localization passing through skin and triceps tendon
 - identify posteromedial osteophyte and remove overlying fibrous tissue using a combination of radiofrequency ablation and mechanical shaving
 - in cases where the osteophyte is fractured, use an elevator, probe or osteotome to free the fractured osteophyte from the native olecranon
 - when removing the fractured osteophyte, consider switching your working and viewing portals to allow removal of the fragment through the posterolateral portal thus avoiding losing the fragment in the dense triceps tissue
 - using a shaver or burr, contour the olecranon down to its native margin taking care not to over-resect too much bone which can lead to increased stress on the MCL
 - perform an arthroscopic valgus stress test to identify medial gapping which may be indicative of an incompetent MCL
- **Ulnar Nerve Decompression**
 - Decompression and Partial Release
 - Transposition for symptomatic, unstable nerves

• Complications

- Valgus instability

- over-resection of the posteromedial osteophyte past its native margin or >3mm may lead to increased stress on the MCL and valgus instability
- Ulnar nerve injury
 - identify course of the ulnar nerve prior to creation of medial portals and use "nick and spread" technique to avoid iatrogenic ulnar nerve injury
 - when using the shaver or radiofrequency ablation device in the posteromedial gutter, consider judicious use of suction or remove the suction altogether from shaver to avoid iatrogenic ulnar nerve injury

44- Little League Elbow

• summary

- Little league elbow refers to a continuous spectrum of injuries to the medial side of the elbow seen in adolescent pitchers, which includes: medial epicondyle stress fractures, ulnar collateral ligament (UCL) injuries and flexor-pronator mass strains.
- Diagnosis is made clinically with tenderness over the medial elbow made worse with valgus stress and supplemented with MRI studies.
- Treatment is a trial of rest, activity modification, decrease in innings pitched, and physical therapy.

• Epidemiology

- Demographics
 - younger patients are more likely to have apophysitis or avulsion injuries, rather than UCL sprains

• Etiology

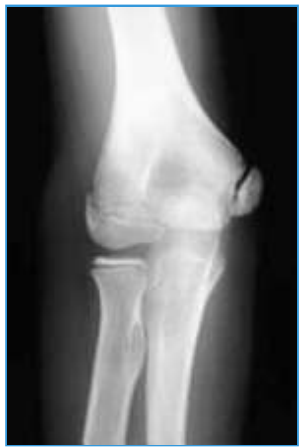- Pathophysiology
 - consists of 3 potential sites of injury
 - medial epicondyle stress fractures
 - ulnar collateral ligament (UCL)
 - flexor-pronator mass strains
 - due to repetitive valgus loading with throwing causing repetitive microtrauma to the immature skeleton
 - causes tension overload of the medial structures
- Risk factors
 - Greater than 80 pitches per game
 - More than 8 months of competitive pitching per year
 - Fastball speed > 85mph
 - Continued pitching despite arm fatigue/pain
 - Participating in showcases

• Presentation

- Symptoms
 - elbow pain in throwing arm
 - decreased throwing speed, accuracy, and distance
- Physical exam
 - tenderness to palpation about medial elbow
 - pain with valgus stress
 - instability with valgus stress notes more severe involvement
 - should be checked in varying degrees of elbow flexion to extension

• Imaging

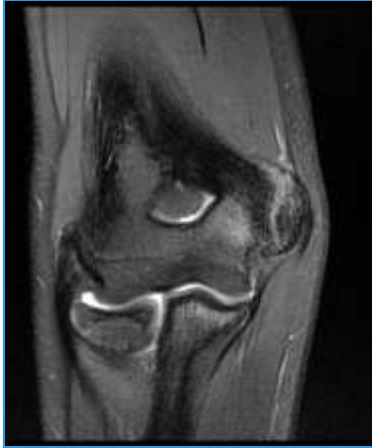- Radiographs
 - recommended views
 - AP/lateral elbow
 - findings
 - may show physeal widening



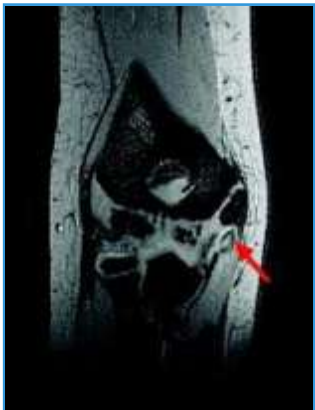- may show fragmentation or avulsion of the medial epicondyle

- MRI

- will show increased edema of the medial epicondyle apophysis



- can be used to confirm UCL insufficiency



- Treatment

- Nonoperative

- **rest, activity modifications, PT**

- indication

- is the mainstay of treatment

- technique

- coach and parent education is critical to limit number of innings pitched per week

- use minimal immobilization to maintain elbow ROM

- Operative

- **ORIF of medial epicondyle**

- indication

- for medial epicondyle avulsion fractures

- **UCL reconstruction**

- indication

- for UCL disruption and insufficiency

- Technique

- **Pediatric UCL reconstruction**

- similar to adult treatment

- commonly using palmaris longus autograft

- Complications

- Ulnar nerve neuropathy

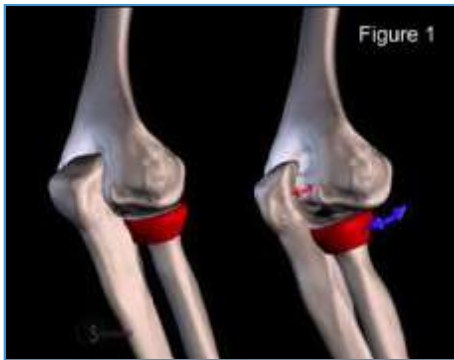
- Continued pain and instability

- Loss of motion

- Inability to return to same level of play

45- Lateral Ulnar Collateral Ligament Injury Ppri

Images

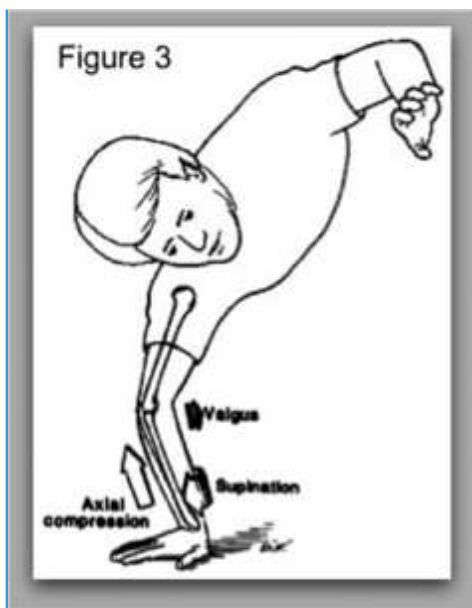


summary

- Lateral Ulnar Collateral Ligament Injury is a ligamentous elbow injury usually associated with a traumatic elbow dislocation, and characterized by posterolateral subluxation or dislocation of the radiocapitellar and ulnohumeral joints.
- Diagnosis can be made with plain radiographs of the elbow which may show an isolated elbow dislocation or an elbow dislocation with a radial head and coronoid tip fracture.
- Treatment may be nonoperative or operative depending on presence of concomitant elbow fractures, as well as elbow stability following reduction.

Etiology

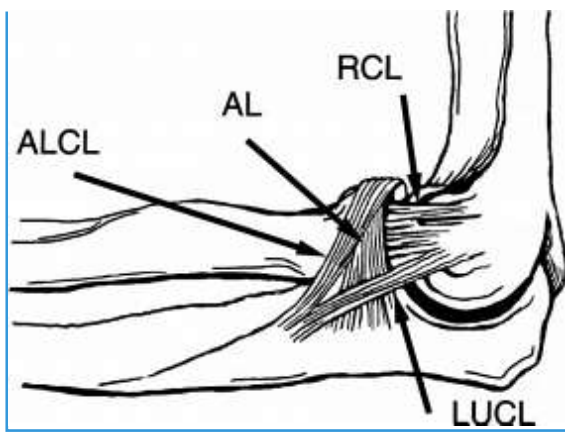
- Pathophysiology
 - traumatic
 - most often discussed as a result of elbow dislocation
 - combination of forearm supination, axial loading, valgus (posterolateral) stress, and elbow extension causes progressive failure of the lateral collateral ligament complex and anterior capsule, resulting posterolateral subluxation of the radial head and external rotation of the semilunar notch away from trochlea



- common extensor origin can also be avulsed
- radioulnar articulation remains intact
- iatrogenic injury
 - from arthroscopic or open procedures of the lateral elbow that go posterior to equator of radial head (e.g. debridement of lateral epicondylitis)
 - arthroscopic debridement should be kept anterior to equator of the radial head
- chronic attenuation
 - secondary to chronic cubitus varus malunion
 - abnormal lateral thrust stretches out the LUCL with time
 - abnormal triceps vector further stretches LUCL
- Associated conditions
 - elbow dislocations

Anatomy

- Lateral collateral ligament complex consists of 4 components



- accessory lateral collateral ligament
- annular ligament
- lateral radial collateral ligament (LCL)
- lateral ulnar collateral ligament (LUCL)
 - LUCL is the primary stabilizer to varus & ER stress
 - origin
 - lateral humeral epicondyle
 - insertion
 - the tubercle of the supinator crest of the ulna

• Presentation

○ Symptoms

- pain is the primary symptom
- mechanical symptoms (clicking, catching, etc.)
 - often with elbow extension and when pushing off from arm of chair

○ Physical exam

- inspection and palpation
 - tenderness over LUCL
- motion and stability
 - varus instability
- provocative tests
 - lateral pivot-shift test
 - patient lies supine with affected arm overhead; forearm is supinated and valgus stress is applied while bringing the elbow from full extension to 40 degrees of flexion
 - with increased flexion, triceps tension reduces the radial head
 - often more reliable on anesthetized patient
 - posterior drawer test
 - patient lies supine with affected arm overhead; forearm is supinated and the examiner's index finger is placed under the radial head and the thumb over it.
 - application of a posterior force will cause posterior subluxation of the radial head
 - apprehension test
 - patient lies supine with affected arm extended overhead; forearm is supinated and valgus stress is applied while flexing the elbow
 - chair rise test
 - table-top relocation test
 - floor push-up test
 - patient cannot do push-ups with forearm supinated

• Imaging

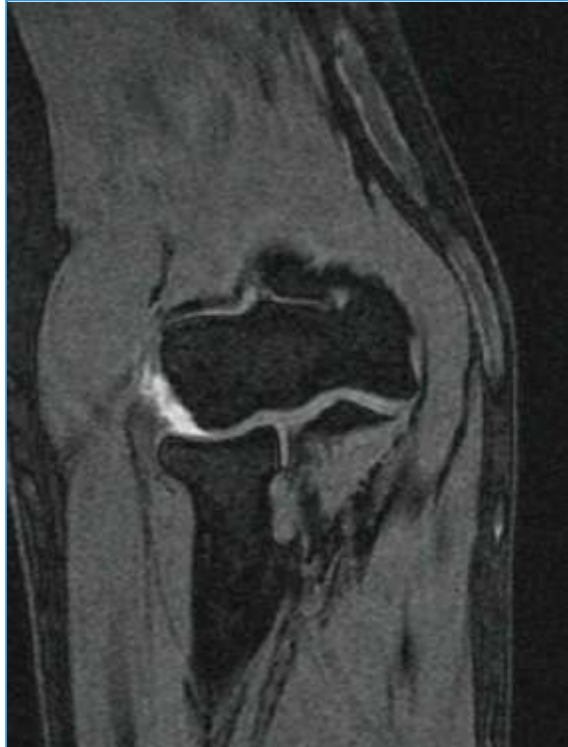○ Radiographs

- recommended views
 - AP and lateral views of elbow
- findings
 - important to rule out associated fractures and confirm concentric reduction in setting of acute dislocation
 - standard radiographs are often of little value in evaluating PLRI
 - fluoroscopic imaging during provocative testing (e.g. pivot-shift) may demonstrate radial head subluxation

○ MRI

- indications

- may not be helpful in the setting of recurrent instability and LUCL attenuation as visualizing ligament difficult due to oblique course
- findings
 - can identify acute avulsion of LUCL in acute instability



- sensitivity and specificity
 - LUCL pathology identified in 50% of patients

Differential

Varus Posteromedial Rotatory Instability (VPMRI) vs. Valgus Posterolateral Rotatory Instability (VPLRI)			
	VPMRI	VPLRI	
Radial head	No radial head fracture	Radial head fracture	■
Coronoid fracture	> 15% (anteromedial facet)	< 15% (coronoid tip)	■
MCL	Posterior band of MCL ruptured, anterior band intact (attached to anteromedial facet)	Anterior band of MCL ruptured	■
LCL	LCL complex (includes LUCL) avulsion	LCL complex (includes LUCL) avulsion	■
Physical exam	Valgus stress, moving valgus, milking maneuver	Varus stress, chair rise, lateral pivot shift	■

Treatment

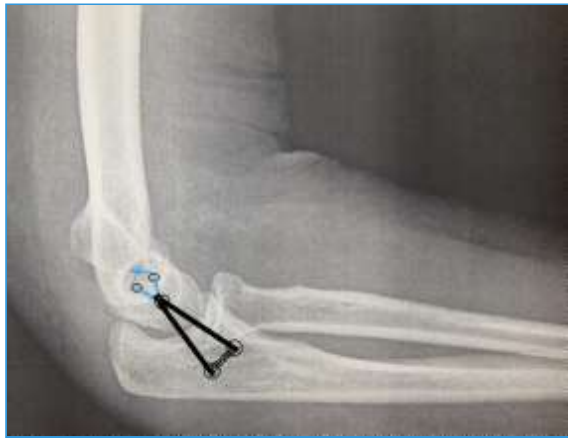- Nonoperative
 - **acute reduction followed by immobilization at 90° flexion for 5-7 days**
 - indications
 - acute elbow dislocations
 - technique
 - following reduction assess post-reduction stability
 - place in posterior splint for 5-7 days, with elbow at 90 degrees of flexion and forearm appropriately positioned based on post-reduction stability
 - LCL disrupted, but MCL intact
 - splint in full pronation (tightens lateral structures)
 - LCL + MCL disrupted
 - splint in neutral
 - will not splint in full supination (for MCL rupture only) as the LCL is always disrupted in PLRI
 - early active ROM following splint removal (+/- extension block)
 - full supination/pronation from 90° to full flexion
 - progress with increasing extension by 30° weekly, but with the forearm in full pronation; after 6 weeks full supination in extension allowed
 - **bracing, extensor strengthening, activity modification w/ avoidance of gravity varus positions**
 - indications
 - mild, chronic PLRI
 - low-demand patients
 - Operative
 - **open reduction, fracture fixation, LUCL repair**
 - indications
 - osteochondral fragment or soft-tissue entrapment prevents concentric reduction

- complex dislocation (associated fractures are present)
- acute instability
 - open & arthroscopic techniques described
- **LUCL reconstruction w/ graft**
 - indications
 - chronic PLRI

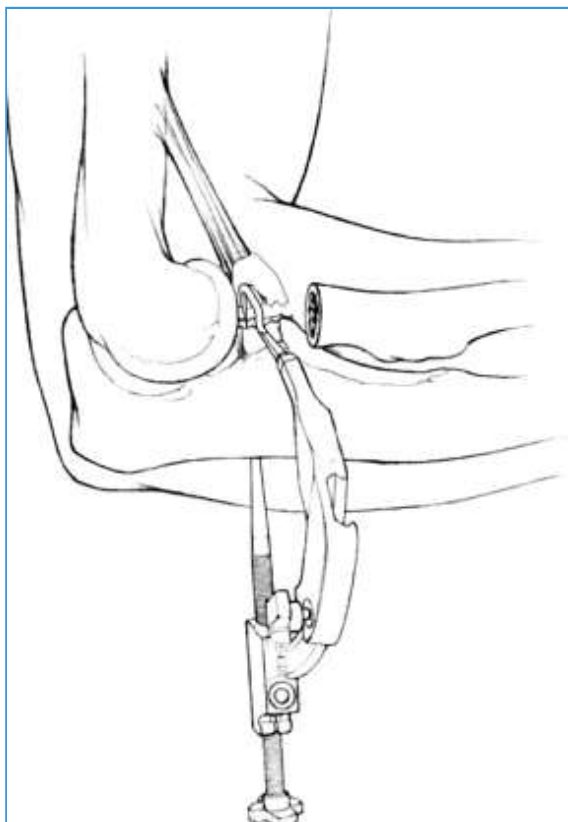
• Techniques

○ Reconstruction of LUCL complex

- approach
 - posterior mid-line
 - Kocher approach
- graft types
 - autograft or allograft tissue may be used
 - palmaris longus most common
 - gracilis and triceps fascia also utilized
- graft configuration
 - tendon graft tied to itself over lateral column after placing through tunnel in supinator crest & then weaving through "Y" tunnel configuration in humerus
 - it is critical that the graft covers > posterior 25% of the radial head to create a sling
 - graft can be plicated to capsule to maintain position and capsule plicated to augment repair
 - graft secured with arm in neutral rotation and 45° of flexion
- graft fixation
 - graft may be "docked" on humerus with sutures exiting "Y" tunnels or on both humeral and ulnar sides with interference screws (or sutures tied over bone - overlay technique)



- coronoid fracture ORIF / anterior capsular laxity
 - large fragments should be fixed with screw from dorsal ulnar surface (aided by ACL type guide to improve accuracy)
 - small fragments should be excised but a suture plication of the anterior capsule to the broken tip increases stability and can be placed with the aid of ACL type guide



- postoperative
 - protected from varus stress across the elbow and shoulder abduction post-operatively (locked hinge brace)

- early range-of-motion encouraged (+/- extension block with progressive gain to full extension and supination by 6-8 weeks)
- important to keep forearm in full pronation during ROM until after 6 weeks (as above)

- Complications

- Recurrent instability
 - 3-8% incidence
- Infection
- Cutaneous nerve injury
 - decreased risk with posterior mid-line approach
- Decreased ROM

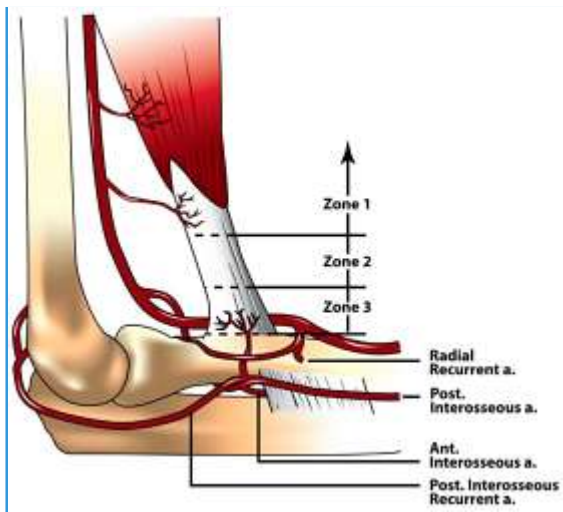
46- Distal Biceps Avulsion

• summary

- Distal Biceps Avulsions are injuries to the biceps tendon at the radial tuberosity insertion that generally occurs due to a sudden excessive eccentric contraction of the biceps brachii.
- Diagnosis can be made clinically in the setting of complete tears with a hook test. MRI studies can be used to discern between a complete tear and a partial tear.
- Treatment can be nonoperative or operative depending on patient age, patient activity demands, chronicity of tear, and degree of tear.

• Epidemiology

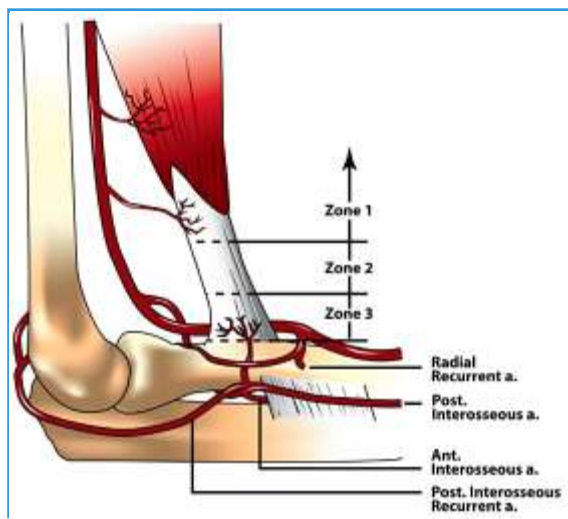
- Incidence
 - rare
 - distal biceps tendon rupture represents about 10% of biceps ruptures.
- Demographics
 - ruptures tend to occur in the dominant elbow (86%) of men (93%) in their 40s.
- Anatomic location



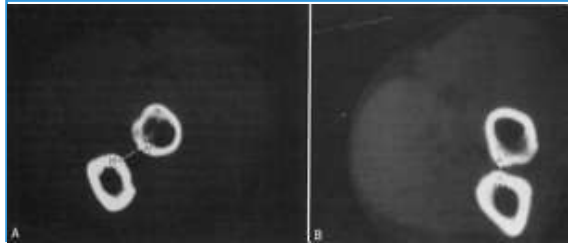
- complete distal biceps avulsion
- partial distal biceps avulsion
 - partial distal biceps tendon tears occur primarily on the radial side of the tuberosity footprint.
- intersubstance muscle transection
 - seen when rope wrapped around arm (tug-of-war)
- Risk factors
 - anabolic steroids
 - smoking has 7.5x greater risk than nonsmokers
 - hypovascularity
 - intrinsic degeneration
 - mechanical impingement in the space available for the biceps tendon

• Etiology

- Pathophysiology
 - mechanism
 - excessive eccentric tension as the arm is forced from a flexed to an extended position "flexed elbow unacceptably challenged"
 - vascular watershed



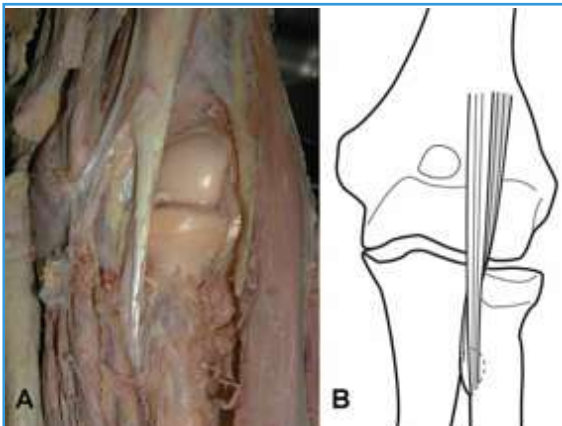
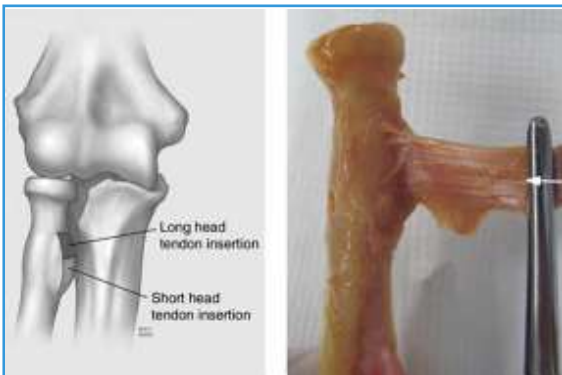
- mechanical attrition (abrasion during pronosupination)



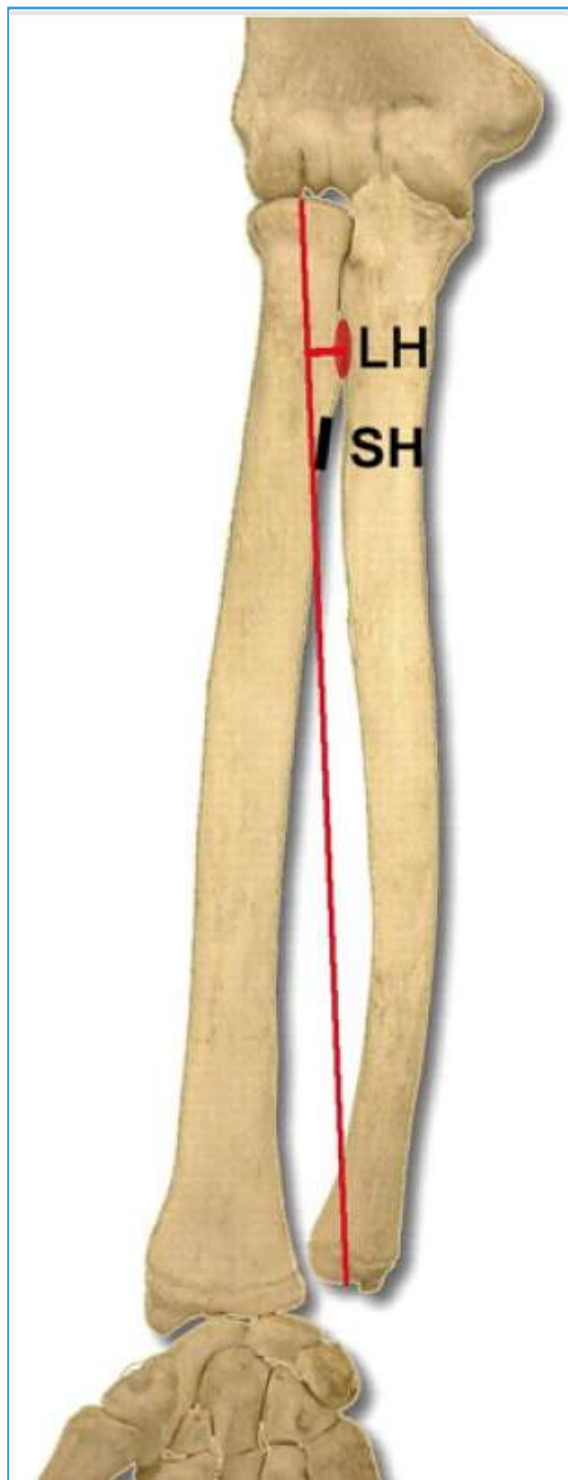
- Associated conditions
 - rarely it can lead to symptoms of median nerve compression

• Anatomy

- Biceps tendon inserts onto the radial tuberosity.
- Contents of antecubital fossa (medial to lateral)
 - median nerve (most medial structure), brachial artery, biceps tendon, radial nerve (most lateral structure)
 - radial recurrent vessels lie superficial to biceps tendon
- Distal biceps tendon possesses two distinct insertions

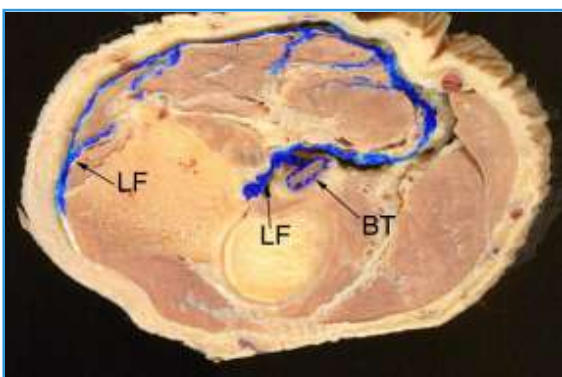
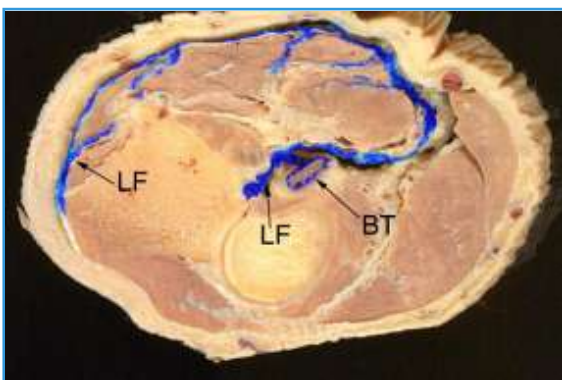


- short head attaches distally on radial tuberosity (thin sliver)
 - origin is coracoid process
 - is a better flexor
- long head attaches proximally on radial tuberosity (oval footprint)
 - origin is the superior lip of the glenoid and glenoid labrum
 - is a better supinator as attachment is furthest from axis of rotation (attaches to apex of radial tuberosity)



- independent function to prevent anterior, inferior and superior translation of humeral head against proximal pull of short head of biceps

- Lacertus fibrosus



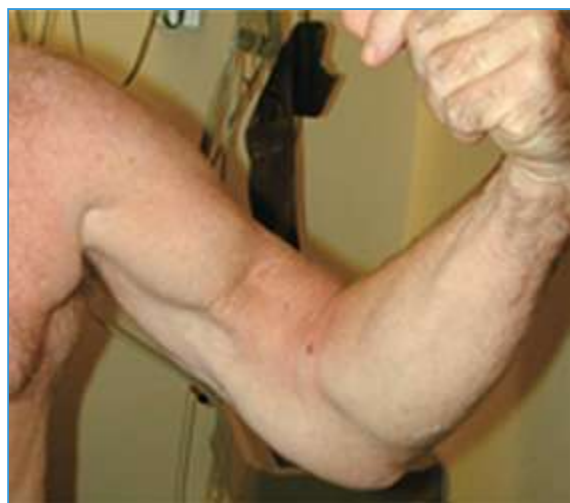- distal to the elbow crease, the tendon gives off, from its medial side, the lacertus fibrosus (bicipital aponeurosis or biceps fascia)
- originates from the distal short head of the biceps tendon
- lacertus passes obliquely across the cubital fossa, running distally and medially, helping to protect the underlying brachial artery and median nerve
- it is continuous with the deep fascia of the flexor tendon origin, envelopes flexor muscle bellies
- may be mistaken for an intact distal biceps tendon on clinical exam

- Presentation

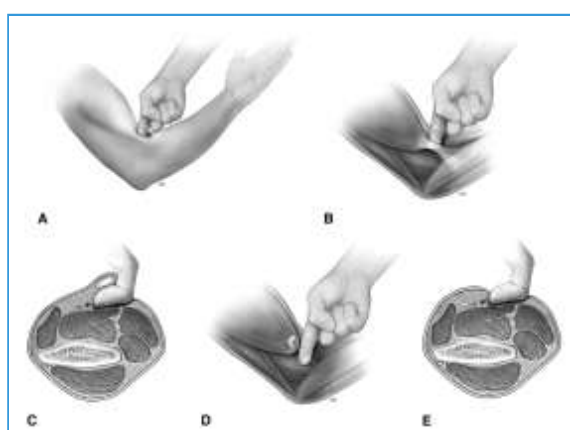
- History

- patient often experiences a painful “pop” as the elbow is eccentrically loaded from flexion to extension.

- Symptoms
 - weakness and pain, primarily in supination, are hallmarks of the injury.
- Physical exam
 - inspection and palpation
 - varying degree of proximal retraction of the muscle belly



- “reverse Popeye sign”
 - change in contour of the muscle, proximally
 - medial ecchymosis
 - a palpable defect is often appreciated
- motor exam
 - loss of more supination than flexion strength
 - loss of 50% sustained supination strength
 - loss of 40% supination strength
 - loss of 30% flexion strength
- provocative tests
 - Hook test

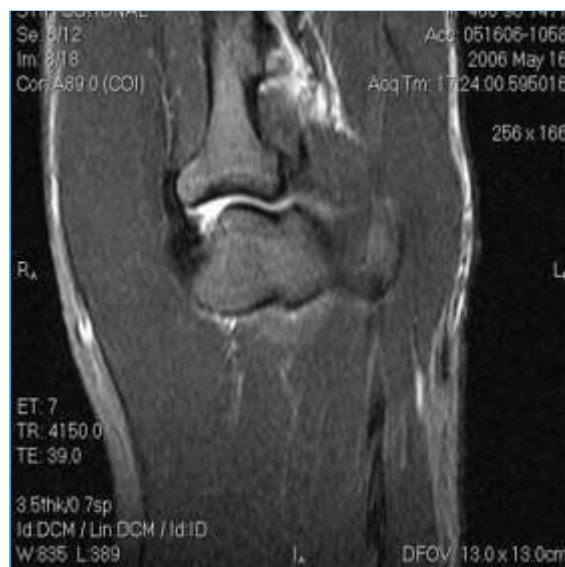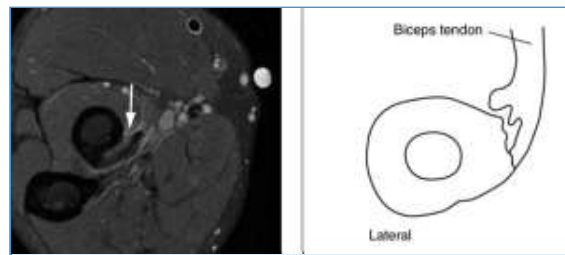
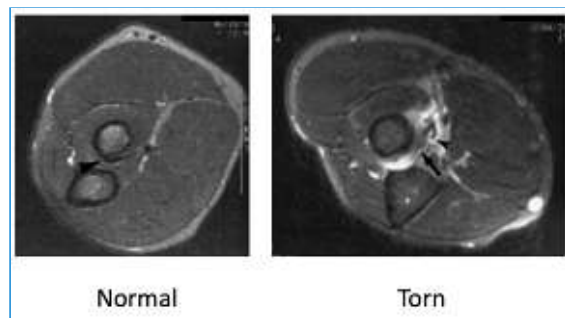


- performed by asking the patient to actively flex the elbow to 90° and to fully supinate the forearm
- examiner then uses index finger to hook the lateral edge of the biceps tendon.
 - with an intact / partially torn tendon, finger can be inserted 1 cm beneath the tendon
- false positive
 - partial tear
 - intact lacertus fibrosis
 - underlying brachialis tendon
- sensitivity and specificity 100%
- Ruland biceps squeeze test (akin to the Thompson/Simmonds test for Achilles rupture)
 - elbow held in 60-80° of flexion with the forearm slightly pronated.
 - one hand stabilizes the elbow while the other hand squeezes across the distal biceps muscle belly.
 - a positive test is failure to observe supination of the patient's forearm or wrist.
 - sensitivity 96%
- challenge is to distinguish between complete tear and partial tear.
 - biceps tendon is absent in complete rupture and palpable in partial rupture (otherwise they have a very similar clinical picture)

• Evaluation

- Radiographs
 - usually normal
 - occasionally show a small fleck or avulsion of bone from the radial tuberosity
- MRI
 - positioning in elbow flexion, shoulder abduction, forearm supination increases sensitivity
 - is important to distinguish between

- complete tear vs. partial tear



- muscle substance vs. tendon tear
- degree of retraction

Treatment

Nonoperative

supportive treatment followed by physical therapy

- indications
 - older, low-demand or sedentary patients who are willing to sacrifice function
 - if the lacertus fibrosis is intact, the functional deficits of biceps rupture may be minimized in a low-demand patient.
- outcomes
 - will lose 50% sustained supination strength
 - will lose 40% supination strength
 - will lose 30% flexion strength
 - will lose 15% grip strength

Operative

surgical repair of tendon to tuberosity



- indications
 - young healthy patients who do not want to sacrifice function
 - partial tears that do not respond to nonoperative management
 - subacute/chronic ruptures may be treated successfully with direct repair (without allograft)
 - may need to hyperflex elbow to achieve fixation
 - hyperflexion does NOT lead to loss of elbow ROM or flexion contracture
- timing
 - surgical treatment should occur within a few weeks from the date of injury
 - further delay may preclude a straightforward, primary repair.
 - a more extensile approach may be required in a chronic rupture to retrieve the retracted and scarred distal biceps tendon.

Techniques

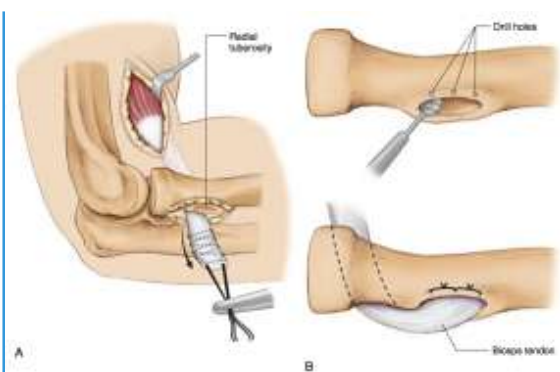
Anterior Single-Incision Technique

- single incision technique was developed to reduce the incidence of HO and synostosis seen with the double incision technique
- technique
 - limited antecubital fossa incision
 - interval between the brachioradialis and pronator teres
 - radial (lateral) retraction of the brachioradialis and medial retraction of the pronator teres
 - lateral antebrachial cutaneous nerve (LABCN) is identified as it exits between the biceps and brachialis at antecubital fossa.
 - recurrent radial vessels encountered and either coagulated or carefully dissected and retracted
 - protect PIN by limiting forceful lateral retraction and maintaining supination
- complications
 - injury to the LABCN is most common

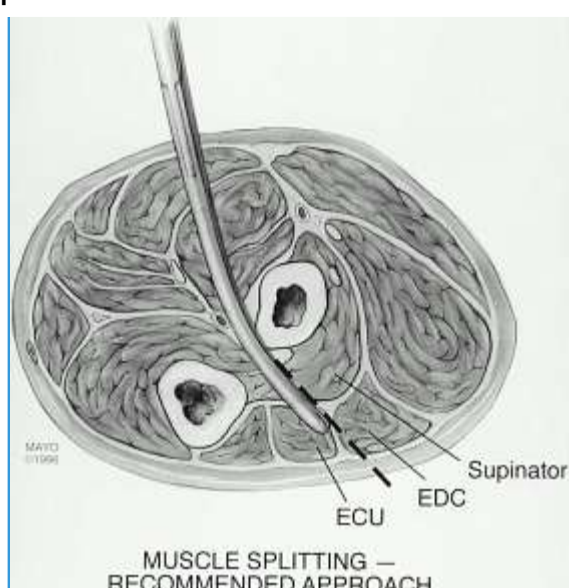


- more LABCN injury than 2-incision approach
- radial nerve or PIN injury is most severe
 - risk has decreased with new tendon fixation techniques that require less dissection in the antecubital fossa
- synostosis and resulting loss of pronation/supination
 - avoid exposing periosteum of ulna
 - avoid dissection between the radius and ulna
- heterotopic ossification
 - less common than with 2 incision technique
- postoperative
 - immobilize in 110° of flexion and moderate supination

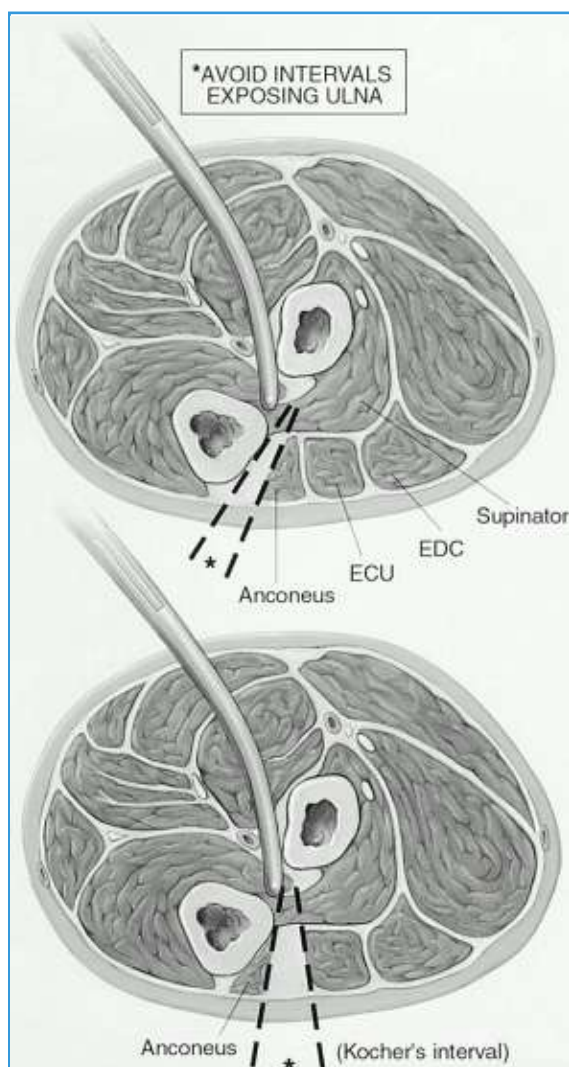
○ Dual Incision Technique



- developed to avoid injury to radial nerve/PIN
- technique
 - uses smaller anterior incision over the antecubital fossa and a second posterolateral elbow incision
 - posterior interval is between ECU and EDC



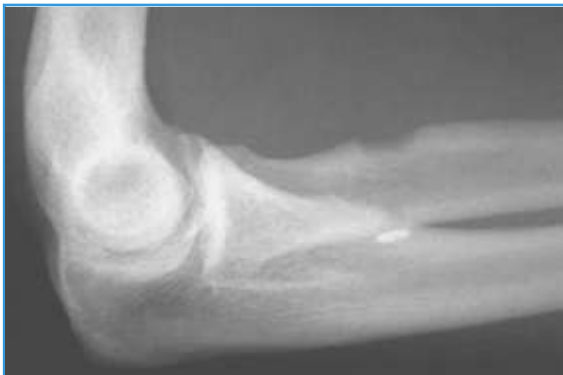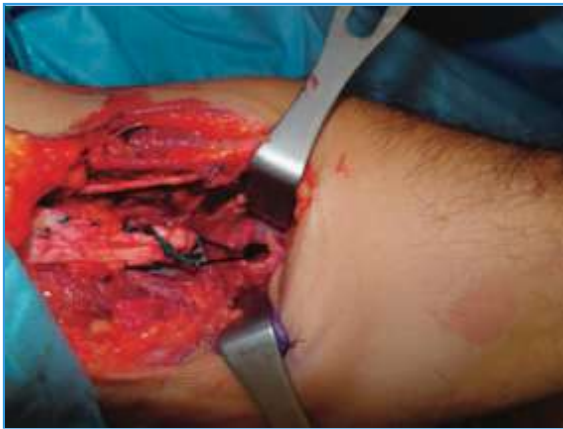
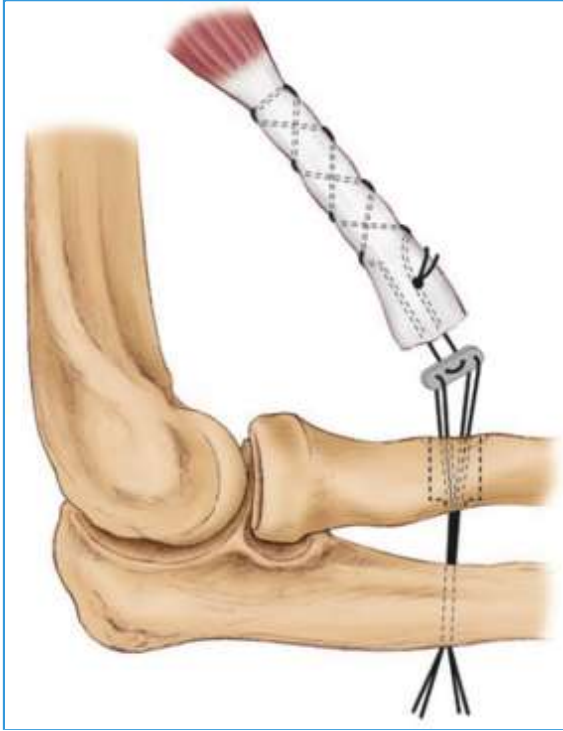
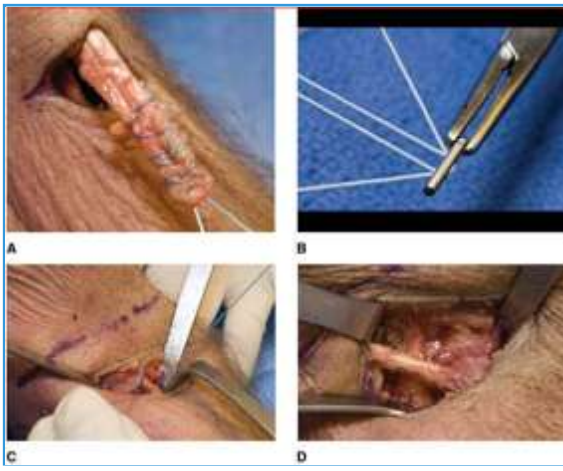
- avoid exposing ulna
 - do NOT use interval between ECU/anconeus (Kocher's interval) or anconeus and ulna



- anterior dissection is same as single incision described above
- after the biceps is identified, the radial tuberosity is palpated, and a blunt, curved hemostat is placed in the interosseous space along the medial border of the tuberosity and palpated on the dorsal proximal forearm
- hemostat pierces anconeus and tents the skin indicating where the posterolateral incision should be made
- complications
 - LABCN injury is most common
 - synostosis and heterotopic ossification more common with 2 incision than single incision

○ Distal Biceps Fixation Techniques

- comparison
 - tolerances
 - elbow at 90°, no load, distal biceps sustains 50N
 - elbow at 90°, with 1kg load, distal biceps sustains 112N
 - force to rupture = 200N
 - repair needs to be able to withstand 50N
 - suture button (400N) > suture anchor (380N) > bone tunnel (310N) > interference screw (230N)
 - combination technique (suture button + interference screw) stronger than single technique
- bone tunnel
 - 2-incision approach
 - tuberosity is exposed and a guide pin drilled through the center of the tuberosity
 - acorn reamer is used to ream through anterior cortex to recreate a slot of varying depth
 - two or three 2-mm diameter holes are drilled 1 cm apart through the lateral, far side of the radius
 - no. 2 sutures sown to the distal tendon are passed and tied across the bone bridge.
- suture anchors
 - single-incision approach
 - radial tuberosity is debrided to prepare for bone-to-tendon healing
 - 2 suture anchors inserted into the biceps tuberosity, one distal and one proximal.
 - the distal anchor is tied first to bring the tendon out to length.
 - next, the sutures of the proximal anchor are tied
 - this repair sequence maximizes tendon-to-bone contact and surface area.
- intraosseous screw fixation
 - single-incision approach
 - similar to the bone tunnel technique, except the No. 2 suture (whip-stitched through the tendon) is passed through a bioabsorbable tenodesis screw.
- suspensory cortical button

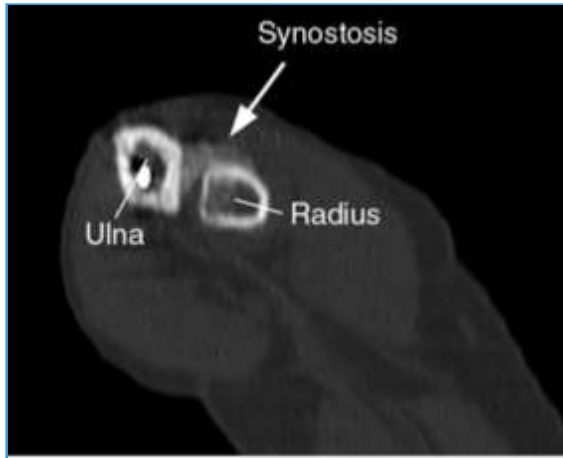


- single-incision approach
- tendon end is whip-stitched with the suture ends placed into two central holes of the button.
- similar to bone tunnel technique, an acorn reamer is used to ream through the anterior cortex after exposing tuberosity.
- a smaller hole is then drilled through the far cortex to allow the button to be passed across the far cortex.
- button is flipped to lie on far cortex, and suture ends are tensioned (tension slide) to bring tendon into tunnel

• Complications

- LABCN injury
 - most common complication overall (9% incidence)
 - because of overaggressive retraction
 - more common with single incision technique
 - usually resolved in 3-6mth
- PIN injury
 - more common in single incision than 2 incision technique
 - most commonly injured motor nerve (1-2% incidence)
 - usually resolve in 3-6mth
- Superficial radial nerve injury
 - 2nd most common cutaneous nerve injured (2-3%)

- Heterotopic ossification
 - if interosseous membrane and ulnar periosteum disrupted
 - a risk of the 2 incision technique
- Synostosis



- Proximal radius fracture
 - from large tunnels or those proximal to the radial tuberosity
- Suture rupture (if bone tunnel method used)

47- Lateral Epicondylitis Tennis Elbow

• summary

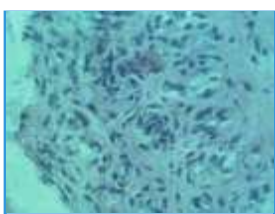
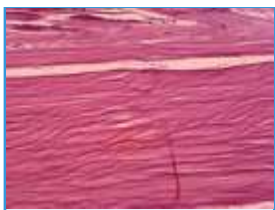
- Lateral Epicondylitis (also known as Tennis Elbow) is an overuse injury caused by eccentric overload at the origin of the common extensor tendon, leading to tendinosis and inflammation of the ECRB.
- Diagnosis is made clinically with tenderness over the lateral epicondyle made worse with resisted wrist extension.
- Treatment is primarily nonoperative with NSAIDs, activity modification and bracing. Rarely, operative management is indicated for patients with persistent symptoms who fail nonoperative management.

• Epidemiology

- Incidence
 - most common cause for elbow symptoms in patients with elbow pain
 - affects 1-3% of adults annually
 - commonly in dominant arm
- Demographics
 - up to 50% of all tennis players develop
 - risk factors
 - poor swing technique
 - heavy racket
 - incorrect grip size
 - high string tension
 - common in laborers who utilize heavy tools
 - workers engaged in repetitive gripping or lifting tasks
 - most common between ages of 35 and 50 years old
 - men and women equally affected

• Etiology

- Pathophysiology
 - mechanism
 - tenodesis effect to optimize grip causes overuse of ECRB
 - precipitated by repetitive wrist extension and forearm pronation
 - common in tennis players (backhand implicated)
 - pathoanatomy
 - usually begins as a microtear of the origin of ECRB
 - may also involve microtears of ECRL and ECU
 - pathohistology
 - microscopic evaluation of the tissue reveals
 - angiofibroblastic hyperplasia

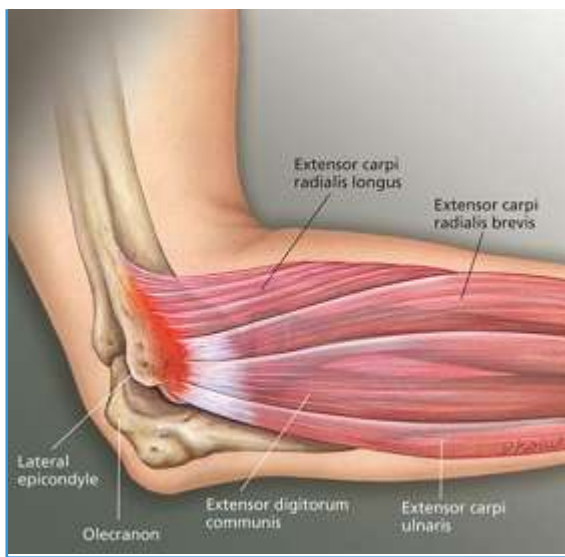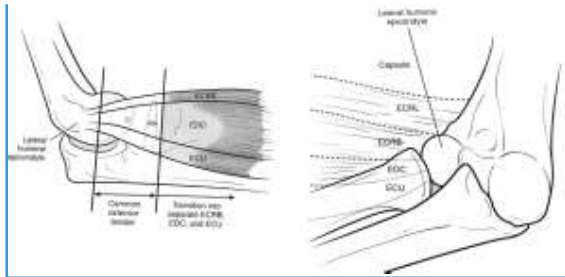

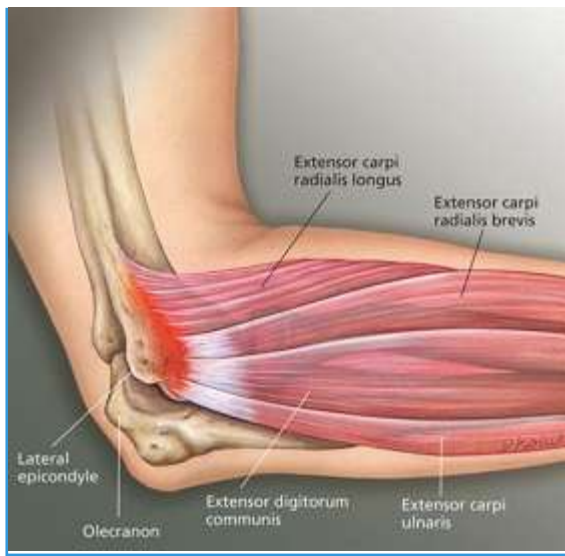
- disorganized collagen

- Associated conditions
 - radial tunnel syndrome
 - is present in 5%

• Anatomy

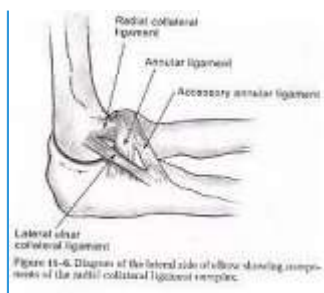- Common extensor origin



- muscles that originate from lateral supracondylar ridge
 - extensor carpi radialis longus
- muscles that originate on lateral epicondyle
 - extensor carpi radialis brevis
 - extensor carpi ulnaris
 - extensor digitorum
 - extensor digiti minimi
 - anconeus
 - shares same attachment site as ECRB

○ Ligaments

- lateral ulnar collateral ligament



○ Nerves

- posterior interosseus nerve (PIN) enters the supinator just distal to the radial head
 - compression can lead to radial tunnel syndrome (may co-exist with lateral epicondylitis)

• Presentation

○ Symptoms

- pain with resisted wrist extension
- pain with gripping activities
- decreased grip strength

○ Physical exam

- palpation & inspection
 - point tenderness at ECRB insertion into lateral epicondyle
 - few mm distal to tip of lateral epicondyle
- neuromuscular

- may have decreased grip strength
- neurological exam helps to differentiate from entrapment syndromes
- provocative tests
 - the following maneuvers exacerbate pain at lateral epicondyle
 - resisted wrist extension with elbow fully extended
 - resisted extension of the long fingers
 - maximal flexion of the wrist
 - passive wrist flexion in pronation causes pain at the elbow

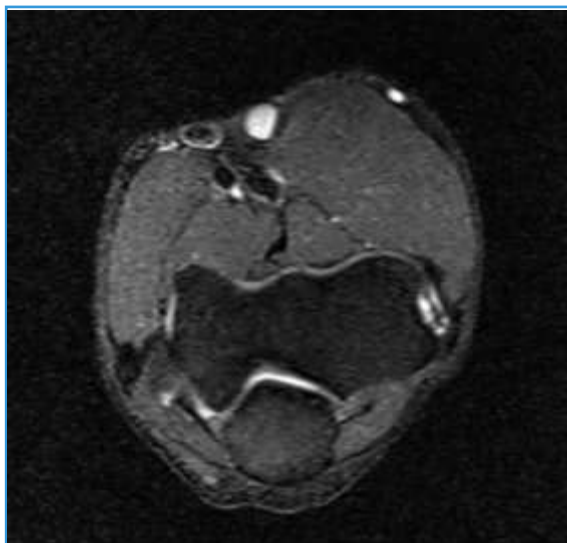
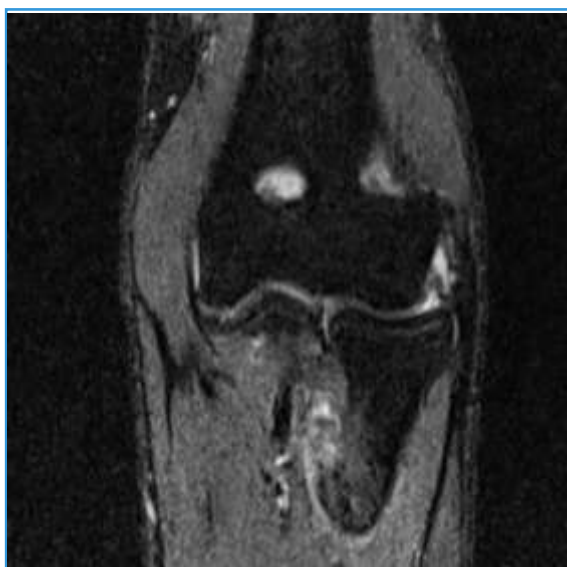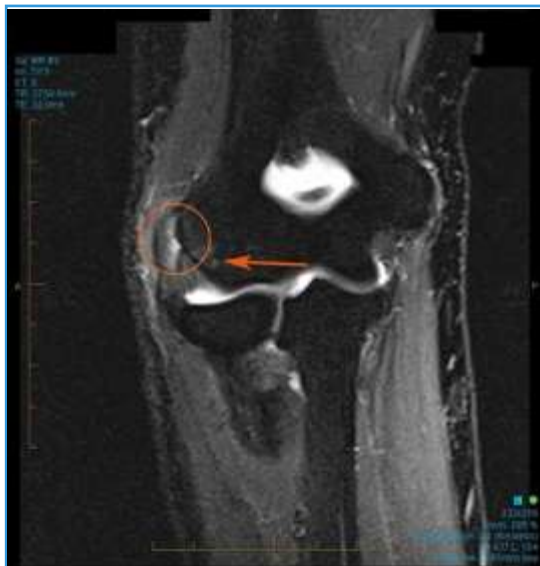• Imaging

○ Radiographs

- recommended views
 - AP/Lateral of elbow
- findings
 - usually normal
 - may reveal calcifications in the extensor muscle mass (up to 20% of patients)
 - may reveal signs of previous surgery

○ MRI

- not necessary for diagnosis
- increased signal intensity at ECRB tendon origin may be seen (up to 50% of cases)



- thickening
- edema
- tendon degeneration

○ Ultrasonography

- requires experienced operator (variable sensitivity/specificity)

- most useful diagnostic tool in experienced operator hands
- ECRB tendon appears thickened and hypoechoic

• Studies

- Histology
 - histopathological studies of the ECRB tendon tissue shows
 - fibroblast hypertrophy
 - disorganized collagen
 - vascular hyperplasia
- Diagnosis
 - diagnosis is primarily based on symptoms and physical exam

• Differential

- Posterolateral plica
- Posterolateral rotatory instability
- Radial tunnel syndrome
 - palpation 3-4 cm distal and anterior to the lateral epicondyle
 - pain with resisted third-finger extension
 - pain with resisted forearm supination
- Occult fracture
- Cervical radiculopathy
- Capitellar osteochondritis dissecans
- Triceps tendinitis
- Radiocapitellar osteoarthritis
- Shingles

• Treatment

- Nonoperative
 - **activity modification, ice, NSAIDS, physical therapy, ultrasound**
 - indications
 - first line of treatment
 - techniques
 - tennis modifications (slower playing surface, more flexible racquet, lower string tension, larger grip)
 - counter-force brace (strap)
 - steroid injections (up to three)
 - physical therapy regimen
 - acupuncture
 - iontophoresis/phonophoresis
 - extracorporeal shock wave therapy
 - outcomes
 - up to 95% success rate with nonoperative treatment, but patience is required
- Operative
 - **release and debridement of ECRB origin**
 - indications
 - if prolonged nonoperative (6-12 months) fails
 - clear diagnosis (isolated lateral epicondylitis)
 - intra-articular pathology
 - contraindications
 - inadequate trial of nonsurgical treatment
 - patient noncompliance with the recommended nonsurgical treatment

• Techniques

- **Release and debridement of ECRB origin**
 - **open**
 - incision is positioned over the common extensor origin
 - lift ECRL off of ECRB (located deep and posterior to ECRL)
 - excise degenerative tissue

- decorticate epicondyle
- repair capsule if breached
- side-to-side closure of tendon
- **arthroscopic**
 - advantages include visualization and ability to address and intraarticular pathology
 - resect lateral capsule anteriorly (do not pass midradial head to protect LUCL)
 - release ECRB from origin (where muscle tissue begins)
 - decorticate lateral epicondyle

• Complications

- Iatrogenic LUCL injury
 - excessive resection of the LUCL
 - should not extend beyond equator of radial head
 - may lead to posterolateral rotatory instability (PLRI)
- Missed radial nerve entrapment syndrome
 - common in up to 5% of patients with lateral epicondylitis
- Iatrogenic neurovascular injury
 - radial nerve injury
- Heterotopic ossification
 - decrease risk with thorough irrigation following decortication
- Infection
- Missed concomitant pathology (i.e. PLRI, radial tunnel)

• Prognosis

- Non-operative treatment effective in up to 95% of cases
- Factors associated with increased likelihood of requiring operative management
 - ipsilateral radial tunnel syndrome
 - history of prior injection (any kind)
 - workers' compensation

48- Triceps Rupture

• summary

- Triceps Ruptures are rare injuries to the elbow extensor mechanism that most commonly occurs as a result of a sudden forceful elbow contraction in weightlifters or older males with underlying systemic illness.
- Diagnosis can be made clinically with the inability to extend the elbow against resistance. MRI studies can help discern between partial and complete tears.
- Treatment is either immobilization or primary repair depending on patient age, patient underlying systemic disease, chronicity of injury and patient activity demands.

• Epidemiology

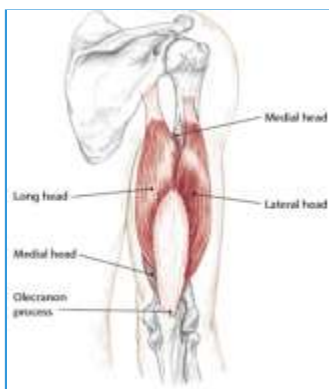- Incidence
 - accounts for 0.8% of tendon ruptures
- Demographics
 - more common in males 2:1
 - age 30-50 most common
 - commonly seen in
 - competitive weightlifting
 - body building
 - football players
- Risk factors
 - systemic illness (hyperparathyroidism, renal osteodystrophy, OI, RA, type I DM)
 - anabolic steroid use
 - local steroid injection
 - fluoroquinolone use
 - chronic olecranon bursitis
 - previous triceps surgery
 - Marfan syndrome

• Etiology

- Pathophysiology
 - mechanism of injury
 - results from forceful eccentric contraction or FOOSH
 - pathoanatomy
 - rupture most commonly occurs at the osseous insertion of the medial or lateral head
 - less frequently occurs through the muscle belly or at the musculotendinous junction

• Anatomy

- Triceps brachii
 - pennate muscle comprised of 3 heads



- lateral
 - originates from the posterior humerus between the insertion of the teres minor and the superior aspect of spiral groove, the lateral border of humerus, and the lateral intermuscular septum
- long
 - originates from the infraglenoid tuberosity
- medial

- originates from the posterior humerus distal to spiral groove, the medial humerus, and the medial intermuscular septum
- insertion occurs over a wide area/footprint
 - inserts on average 1.1 cm distal to the tip of the olecranon
 - width ranges from 1.9-4.2cm
 - consists of
 - triceps tendon proper
 - confluence of tendon from all three heads
 - inserts on the olecranon
 - lateral triceps expansion
 - medial aspect inserts on the posterior crest of the ulna, adjacent to the medial head
 - lateral aspect inserts on the fascia of the extensor carpi ulnaris muscle and the deep fascia of the anconeus muscle
 - distal aspect inserts on the antebrachial fascia
- only muscle in the posterior compartment of the arm
- innervated by radial nerve (C6-C8)

• Classification

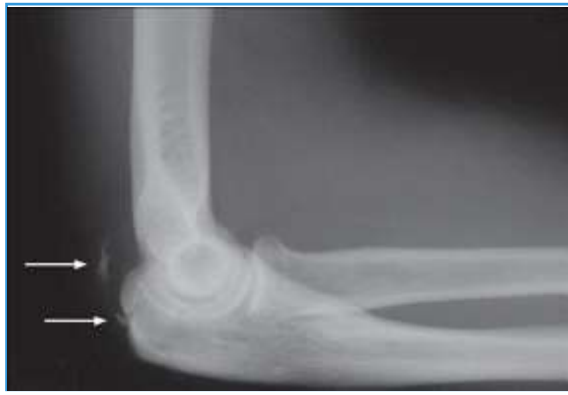- No formal classification system exists
- Can describe the characteristics of the rupture
 - degree of tear
 - complete
 - partial
 - intact
 - location of tear
 - muscle belly
 - musculotendinous junction
 - tendinous insertion
 - avulsion
 - integrity of lateral expansion
 - intact
 - torn

• Presentation

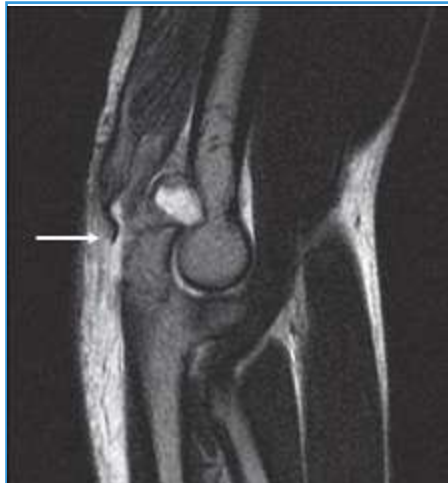- History
 - patients often note a painful pop
- Physical exam
 - inspection
 - pain, swelling, and ecchymosis over the posterior aspect of the elbow
 - may have palpable defect
 - motion
 - inability to extend elbow against resistance
 - not always present -- some patients are able to extend elbow against resistance if intact lateral expansion or compensating anconeus muscle
 - provocative tests
 - modified Thompson squeeze test
 - patient lies prone with the elbow at the end of the table and forearm hanging down
 - triceps muscle is firmly squeezed
 - inability to extend the elbow against gravity suggests complete disruption of triceps proper and lateral expansion

• Imaging

- Radiographs
 - recommended views
 - AP
 - lateral
 - findings
 - may show "flake sign" on lateral view



- MRI
 - indications
 - useful for determining location and severity



- findings
 - partial rupture
 - small fluid-filled defect within distal triceps tendon
 - complete rupture
 - large fluid-filled gap (paratricipital edema)

• Treatment

- Non-operative
 - **splint immobilization**
 - indications
 - partial tears and able to extend against gravity
 - low demand patients in poor health
 - techniques
 - immobilize elbow in 30 degrees of flexion for 4 weeks
- Operative
 - **primary surgical repair**
 - indications
 - acute complete tears
 - partial tears (>50%) with significant weakness
 - technique
 - transosseous tunnels
 - suture anchor
 - studies have shown no difference in biomechanical strength or functional outcomes between transosseous bone tunnels and suture anchors
 - higher re-rupture rate and complication rate noted with transosseous repair compared to suture anchor repair
 - delayed reconstruction may need tendon graft

• Techniques

- **Primary surgical repair**
 - approach
 - posterolateral approach
 - techniques
 - based of location of tear
 - myotendinous junction
 - V-Y triceps tendon advancement
 - can augment using plantaris tendon

- tendinous insertion
 - Bunnell or Krackow whipstitch technique using non-absorbable sutures secured via
 - transosseous tunnels
 - direct repair to periosteal flap from the olecranon
 - intraosseous suture anchors
 - avulsion
 - tension-band construct
 - screw and washer
- post-op
 - immobilization in 30-45 degrees of flexion for 2 weeks
 - active ROM initiated at 4 weeks
 - avoid weightlifting for 4-6 months
- complications specific to this treatment
 - olecranon bursitis
 - flexion contractures
 - re-rupture

- **Complications**

- Elbow stiffness/weakness
- Ulnar nerve injury
- Failure of repair

49- Medial Epicondylitis Golfers Elbow

• summary

- Medial Epicondylitis, also known as Golfer's elbow, is an overuse syndrome caused by eccentric overload of the flexor-pronator mass at the medial epicondyle.
- Diagnosis is made clinically with tenderness around the medial epicondyle made worse with resisted forearm pronation and wrist flexion.
- Treatment is generally nonoperative with rest, icing, activity modifications and bracing. Rarely, operative management is indicated for patients with persistent symptoms who fail nonoperative management.

• Epidemiology

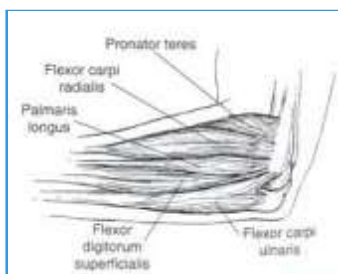- Incidence
 - 5 to 10 times less common than lateral epicondylitis
- Demographics
 - affects men and women equally
 - dominant extremity in 75% of cases
 - age 30s to 60s, most commonly in 30s to 40s.

• Etiology

- Pathophysiology
 - risks
 - sports that require repetitive wrist flexion/forearm pronation during ball release
 - common in golfers, baseball pitchers, javelin throwers, bowlers, weight lifters, racquet sports
 - tennis
 - late ball strike (racquet head behind elbow at ball contact)
 - poor forehand stroke mechanics
 - failure to use vibration dampeners attached to strings
 - in athletes, may develop in response to large valgus forces on elbow
 - flexor-pronators reduce force seen by anterior band of medial ulnar collateral ligament (MUCL)
 - anterior band MUCL
 - primary static restraint to valgus force at elbow
 - lies deep to pronator teres and FCR
 - jobs involving lifting >20kg, forceful grip, exposure to constant vibration at elbow (plumbers, carpenters, construction workers)
 - can also occur post-traumatically
 - pathoanatomy
 - micro-trauma to insertion of flexor-pronator mass caused by repetitive activities
 - traditionally thought to affect pronator teres (PT) > flexor carpi radialis (FCR)
 - new studies show all muscles of common flexor tendon (CFT) affected except palmaris longus
 - stages
 - peritendinous inflammation
 - angiofibroblastic hyperplasia
 - breakdown/fibrosis/calcification
- Associated conditions
 - ulnar neuropathy
 - inflammation may affect ulnar nerve
 - ulnar collateral ligament insufficiency
 - should rule this out, especially in throwing athletes
 - associated occupational conditions (present in 84% of occupational medial epicondylitis)
 - carpal tunnel syndrome
 - lateral epicondylitis
 - rotator cuff tendinitis

• Anatomy

- Common flexor tendon (CFT)
 - 3 cm long
 - attaches to medial epicondyle (anterior aspect), anterior bundle of MCL
 - fibers run parallel to MCL
 - ulnar head of PT becomes confluent with hyperplastic part of anteromedial joint capsule
- Flexor-pronator mass includes



- pronator teres (median n.)
- flexor carpi radialis (median n.)
- FDS (median n.)
- palmaris longus (median n.)
- flexor carpi ulnaris (ulnar n.)

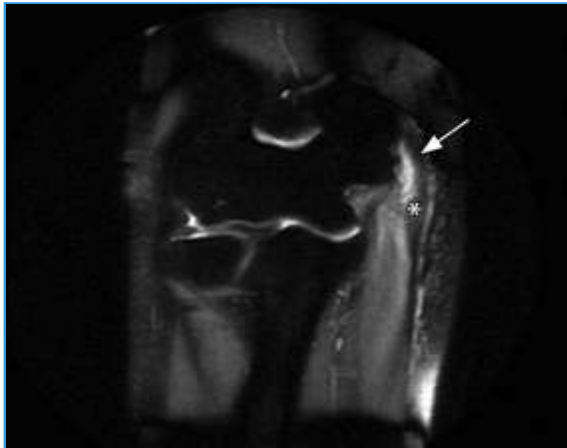
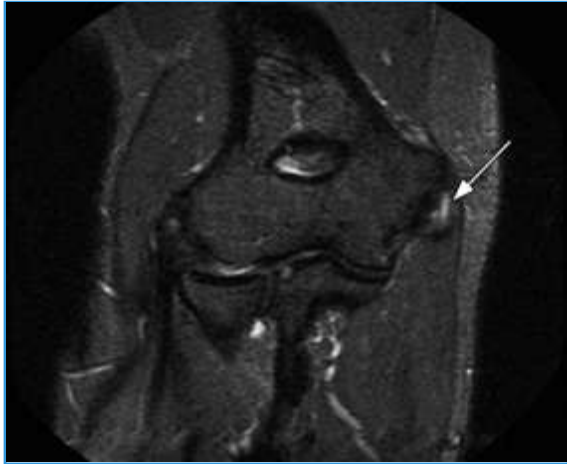
• Presentation

- History
 - may include acute traumatic blow to elbow causing avulsion of CFT
 - repetitive elbow use, repetitive gripping, repetitive valgus stress
 - +/- numbness or tingling in ulnar digits
- Symptoms
 - insidious onset pain over medial epicondyle
 - worse with wrist and forearm motion
 - worse with gripping
 - during late cocking/early acceleration
- Physical exam
 - tenderness 5-10 mm distal and anterior to medial epicondyle
 - soft tissue swelling and warmth if inflammation present
 - provocative tests
 - pain with resisted forearm pronation and wrist flexion
 - examine for associated conditions
 - valgus instability in overhead athlete (milking maneuver, valgus stress, moving valgus stress test)
 - ulnar neuritis (2-pt discrimination in ulnar distribution, hypothenar bulk, Tinel's along length of nerve)
 - elbow flexion test involves maximal flexion, forearm pronation, wrist hyperextension x 30-60s
 - ulnar subluxation
 - flexion contracture in chronic cases

• Imaging

- Radiographs
 - usually unremarkable
 - 25% have calcification of CFT or UCL
 - can identify posterior-medial osteophytes or degenerative changes
 - stress radiography used in some centers for assessing valgus instability
- Ultrasound
 - characteristics
 - >90% sensitivity, specificity, positive and negative predictive values
 - allows dynamic examination
 - findings
 - hypoechoic/anechoic areas of focal degeneration
- MRI
 - standard of care
 - indications
 - evaluate concomitant pathology (e.g. UCL injury in overhead thrower)
 - unclear source of medial elbow pain
 - evaluate for loose bodies

- rule out rupture of flexor pronator origin
- findings
 - tendinosis / tendon disruption of CFT
 - increased signal on T2 images



- peritendinous edema
- **UCL or osteochondral injuries**
- EMG/NCS
 - may be used to further evaluate for ulnar nerve compression if identified on history and physical
- Angiofibroblastic hyperplasia, as described for lateral epicondylitis
- Inflammation uncommon

• Differential

- MCL injury
- Cubital tunnel syndrome
- Fracture
- Cervical radiculopathy
- Triceps tendinitis
- Herpes zoster (shingles)

• Treatment

- Nonoperative
 - **rest, ice, activity modification (stop throwing x 6-12wks), PT (passive stretching), bracing, NSAIDS**
 - indications
 - first line of treatment
 - prolonged trial of conservative management appropriate due to less predictable success of operative treatment (compared to lateral epicondylitis)
 - technique
 - counter-force bracing / kinesiology taping
 - ultrasound shown to be beneficial
 - multiple corticosteroid injections should be avoided
 - **extracorporeal shockwave therapy (ESWT)**
 - no definitive recommendations at present
 - promotes angiogenesis, tendon healing, short term analgesia
 - **corticosteroid injections into peritendinous tissue**
 - complications
 - skin depigmentation (if dark skinned)
 - subcutaneous atrophy
 - tendon weakening
 - ulnar nerve injury
 - acupuncture

- Operative
 - **open debridement of PT/FCR, reattachment of flexor-pronator group**
 - indications
 - up to 6 months of nonoperative management that fails in a compliant patient
 - symptoms severe and affecting quality of life
 - clear diagnosis
 - outcomes
 - good to excellent outcomes in 80% (less than lateral epicondylitis)
 - worse outcomes when ulnar nerve symptoms present pre-operatively

• Techniques

- **Open debridement and reattachment of flexor-pronator mass**
 - approach
 - medial approach to elbow
 - technique
 - use the PT-FCR interval
 - excise regions of pathologic tissue near flexor-pronator mass
 - followed by side-to-side repair at site
 - can perform epicondyle microfracture to enhance vascular environment
 - reattach flexor-pronator mass to medial epicondyle
 - if proximal origin involved
 - can also perform cubital tunnel release or transposition
 - for concomitant ulnar nerve symptoms
 - rehabilitation
 - short period of immobilization x 1-2 weeks in sling
 - avoid volar flexion of wrist immediately postoperatively
 - ROM exercises after 2 weeks
 - strengthening at 6-8 weeks
 - return to sport at 3-6 months

• Complications

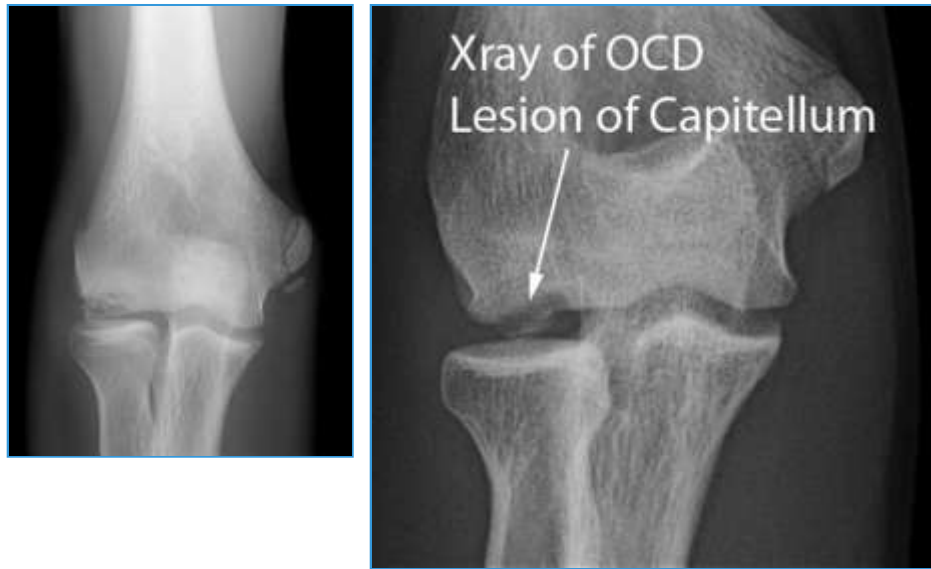
- Medial antebrachial cutaneous nerve neuropathy
 - may result from avulsion or transection
 - if injury noticed during surgery, transpose nerve into brachialis muscle
- Ulnar nerve injury
- Infection

• Prognosis

- More difficult to treat than lateral epicondylitis
- Less well-studied than lateral epicondylitis

50- Osteochondritis Dissecans Of Elbow

Images



• summary

- Osteochondritis Dissecans of Elbow is a localized injury and subsequent separation of articular cartilage and subchondral bone of the capitellum, most commonly seen in gymnasts and pitchers.
- Diagnosis can be made with plane radiographs but MRI studies can be helpful to evaluate for the size of lesion and extent of bony edema.
- Treatment can be nonoperative or operative depending on size of the lesion, stability of the lesion, and presence of loose bodies.

• Epidemiology

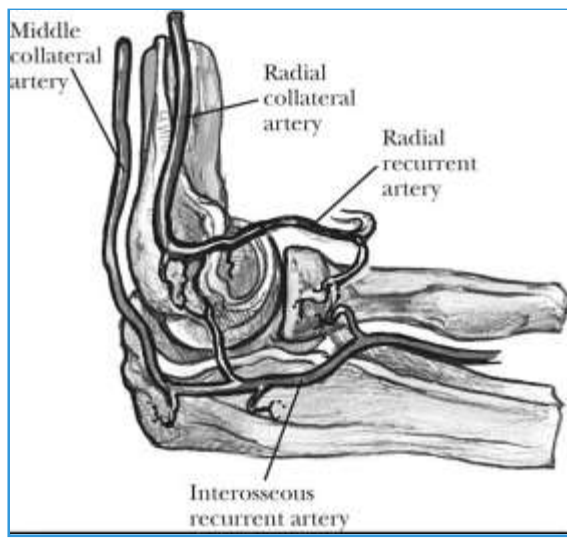
- Demographics
 - usually occurs after age 10 (typically adolescents)
 - juvenile OCD better prognosis than adult
 - boys more common than girls
- Anatomic location
 - typically located in capitellum of dominant upper extremity
- Risk factors
 - repetitive overhead and upper extremity weight bearing activities
 - gymnasts and throwing

• Etiology

- Pathophysiology
 - theorized to result from repetitive compression-type injury (overhead or upper extremity weight bearing activities) of the immature capitellum causing
 - vascular insufficiency
 - repetitive microtrauma
- Associated conditions
 - Panner's disease (osteochondrosis of the capitellum)
 - typically presents in first decade of life (<10 years old)
 - usually benign self-limiting course
 - same mechanism of injury as OCD
 - surgery is contraindicated for Panner disease (unlike OCD elbow)




• Anatomy

- Capitellum is supplied by 2 end arteries



- radial recurrent artery
- interosseous recurrent artery

• Classification

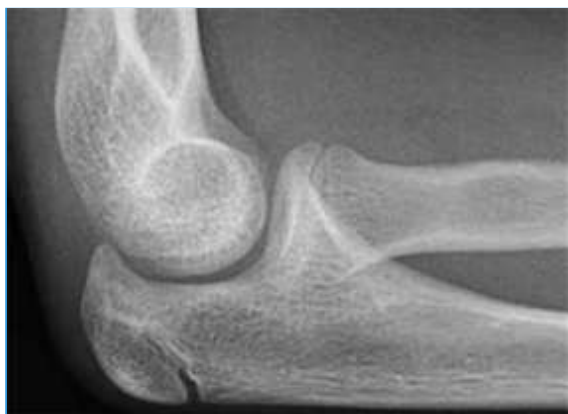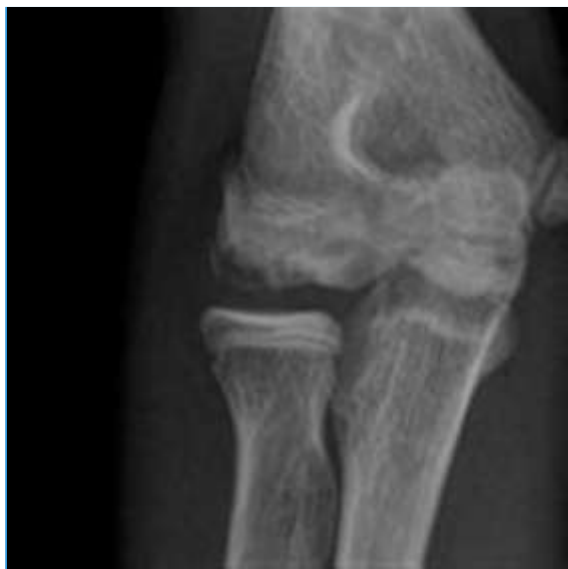<ul style="list-style-type: none"> o Radiographic and Arthroscopic Classification 		
<ul style="list-style-type: none"> ▪ Type I 	<ul style="list-style-type: none"> ▪ Intact cartilage ▪ Bony stability may or may not be present 	<ul style="list-style-type: none"> ▪ 
<ul style="list-style-type: none"> ▪ Type II 	<ul style="list-style-type: none"> ▪ Cartilage fracture with bony collapse or displacement 	<ul style="list-style-type: none"> ▪ 
<ul style="list-style-type: none"> ▪ Type III 	<ul style="list-style-type: none"> ▪ Loose bodies present in joint 	<ul style="list-style-type: none"> ▪ 

• Presentation

- o Symptoms
 - elbow pain
 - insidious, activity-related onset of lateral elbow pain in dominant arm
 - mechanical symptoms
 - loss of extension
 - early sign
 - catching / locking / grinding
 - late signs if loose bodies present
- o Physical exam
 - lateral elbow tenderness
 - mild loss of extension
 - possible effusion of elbow joint
 - usually mild
 - may or may not present with crepitus

• Imaging

- o Radiographs
 - recommended views
 - AP and lateral of the elbow
 - findings
 - plain radiographs can confirm the diagnosis based on bone defect



- capitellum is most commonly involved
- Panner disease exhibits an irregular epiphysis, OCD a well-defined subchondral lesion

- MRI

- most useful for assessing:
 - size
 - extent of edema
 - cartilage status

- Treatment

- Nonoperative

- **cessation of activity +/- immobilization**
 - indications
 - type I lesions (stable fragments)
 - technique
 - 3-6 weeks followed by slow progression back to activities over next 6-12 weeks
 - outcomes
 - >90% success rate

- Operative

- **arthroscopic microfracture or drilling of capitellum**

- indications (separated fragments)
 - unstable type I lesions
 - stable type II lesions
- technique
 - microfracture of chondral lesion
 - extra- or transarticular drilling of defects
- post op care
 - protected early range of motion
 - strengthening at 2 months
 - throwing and weight bearing at 4-6 months
- outcomes
 - good success rate

- **fixation of lesion**

- indications
 - large lesions that are incompletely displaced
- technique
 - arthroscopic reduction and fixation
- post op care
 - protected early range of motion
 - strengthening at 2 months

- throwing and weight bearing at 4-6 months
- outcomes
 - highly variable
- **arthroscopic debridement and loose body excision**
 - indications
 - unstable type II lesion
 - type III lesions
 - post op care
 - early range of motion +/- brace
 - begin strengthening when range of motion is painfree
 - no throwing or weight bearing activities X 3 months
- **osteochondral autograft or allograft transplantation surgery (OATS)**
 - indications
 - large type II and III capitellar lesions which engage the radial head
 - uncontained lesions may require size-matched fresh allograft
 - post op care
 - early range of motion
 - resistive/strengthening exercises at 3 months
 - progressive throwing program begins at 5 months through 7 months

- **Complications**

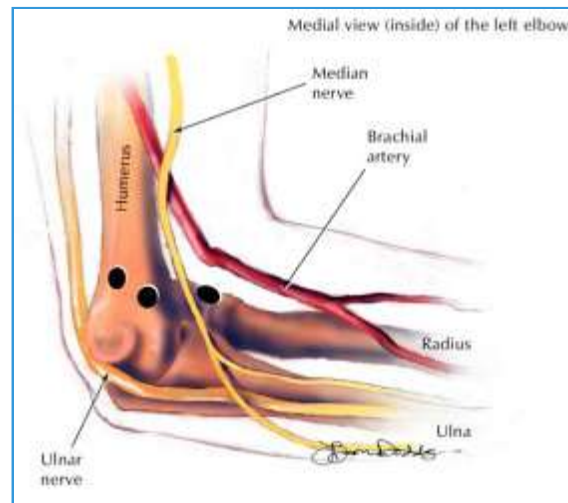
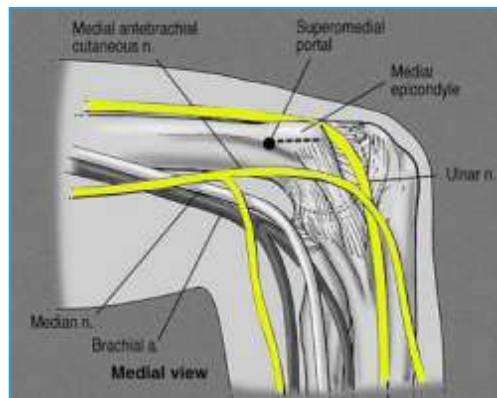
- Elbow stiffness
- Pain
- Unable to return to sports
- Arthritis

- **Prognosis**

- Prognosis based on physcal status
- Most heal between 6 to 18 months of nonoperative treatment
- Wide range of potential disability
 - inability to participate in sports at same level
 - up to 50% develop arthritic changes long term

51- Elbow Arthroscopy Indications And Approach

Images



• Introduction

○ Indications

- loose body removal
- osteophyte debridement
- synovectomy
- capsular releases for stiffness
- osteochondritis dissecans of capitellum
- lateral epicondylitis
- debridement for septic arthritis

○ Contraindications

- prior trauma
- surgical scarring
- previous ulnar nerve transposition
 - ulnar nerve subluxation is not an absolute contraindication, but it should be identified prior to surgery, especially with prior submuscular or intramuscular transposition

○ Advantages

- improved articular visualization
- decreased postoperative pain
- faster postoperative recovery

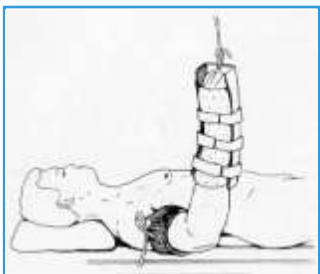
○ Disadvantages

- technically demanding
- high risk of damage to neurovascular structures due to proximity to the joint

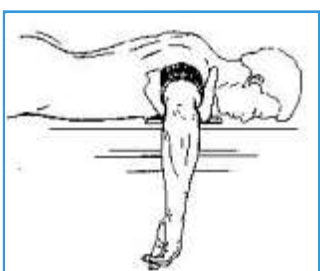
• Positioning

○ Patient position may be

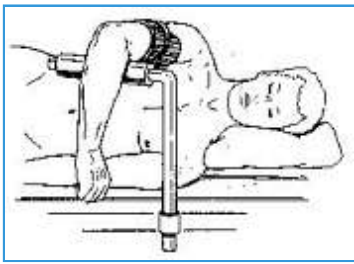
- supine



- prone



- lateral decubitus



- Anesthesia

- general anesthesia (allows muscle relaxation and placement of patient in prone or lateral decubitus position)
- regional anesthesia may be used; it does not allow for immediate evaluation of nerve function after surgery and patients may not tolerate the uncomfortable position for a prolonged period

- Technique and Portals

- Portal placement technique

- fully distend joint through lateral soft spot before placing portals
 - capsule distension moves NV structures away from the joint when trocar is introduced
- careful "nick and spread" technique using hemostat
- posterior medial portal usually avoided due to proximity to ulnar nerve

- Elbow position

- establish anterior portals with elbow flexed 90deg
- establish posterior portals in some extension

- Standard 30deg arthroscope

- Tourniquet

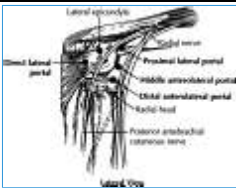
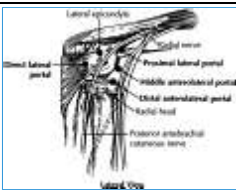
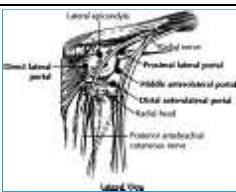
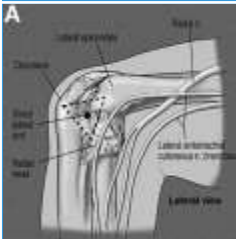
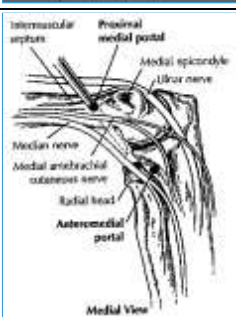
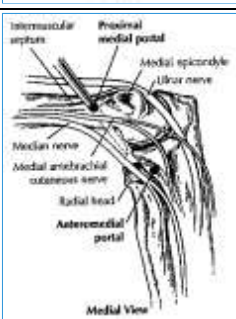
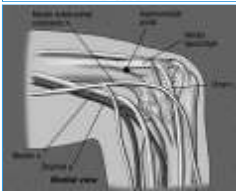
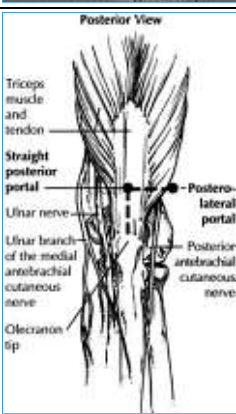
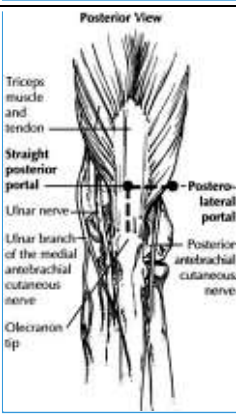
- Solid cannulas are helpful to maintain fluid distension and avoid fluid extravasation into soft tissue (versus trephinated)

- Landmarks: olecranon, lateral and medial epicondyles, radiocapitellar joint, ulnar nerve

- mark out before insufflating joint as distension can alter position

- Summary of portals

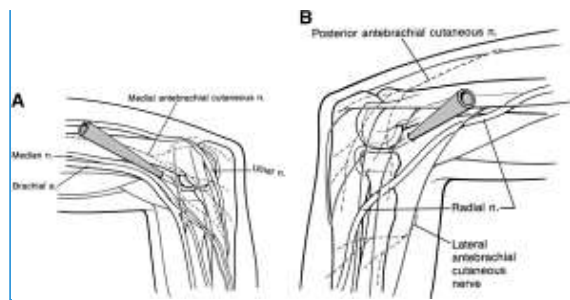
- portal selection depends on the underlying pathology
- after joint insufflation, establish either medially- or laterally-based viewing portal, then establish working portal under direct visualization via needle localization.
 - establishing a medially-based portal first, prior to joint/soft-tissue swelling, may be advantageous to avoid neurovascular injury

Elbow arthroscopy portals				
Portal	Location	Use	Nerves at risk	
Proximal anterolateral	1-2cm proximal, 1cm anterior to lateral epicondyle		Radial (risk decreases as portal moved more proximally)	
Distal anterolateral	1-3 cm distal, 1 cm anterior to lateral epicondyle	1st portal for supine position See radial head, medial side of elbow, coronoid, trochlea, brachialis insertion, coronoid fossa	PIN Lateral antebrachial cutaneous	
Direct lateral (or mid lateral)	"soft spot" portal (in triangle formed by olecranon, radial head, epicondyle)	Initial site for joint distension before scope is inserted For viewing posterior compartment (capitellum, radial head, radioulnar articulation)	Relatively safe Lateral antebrachial cutaneous nerve	 
Anteromedial	2 cm anterior and 2cm distal to medial epicondyle.	Used most often to augment the proximal anteromedial portal to access medial recess. Place under direct visualization.	Medial antebrachial cutaneous Median	
Proximal anteromedial (superomedial)	2cm proximal to medial epicondyle, anterior to intermuscular septum	Viewing entire anterior compartment, radial head, capitellum, coronoid, trochlea	Medial antebrachial cutaneous Ulnar (7 mm away) Median	 
Straight posterior (transtriceps)	3cm proximal to olecranon, triceps midline (musculotend. junction)	Elbow partially extended Good for removing impinging olecranon osteophytes and loose bodies from posteromedial compartment	Posterior antebrachial cutaneous Ulnar nerve	
Posterolateral	2-3 cm proximal to olecranon and just lateral to triceps center of anconeus triangle	Elbow 20-30 deg flexion (to relax triceps) Best access to posterior compartment, radiocapitellar joint (debridement of OCD capitellum), olecranon fossa and posterior structures	Posterior antebrachial cutaneous Medial brachial cutaneous Ulnar	

Complications

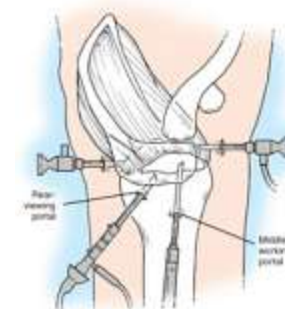
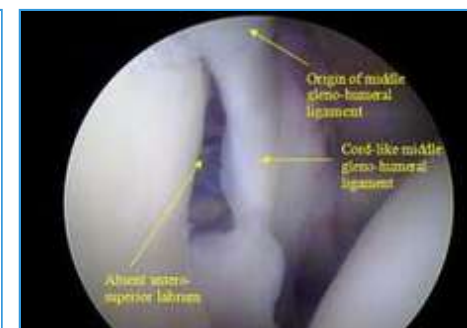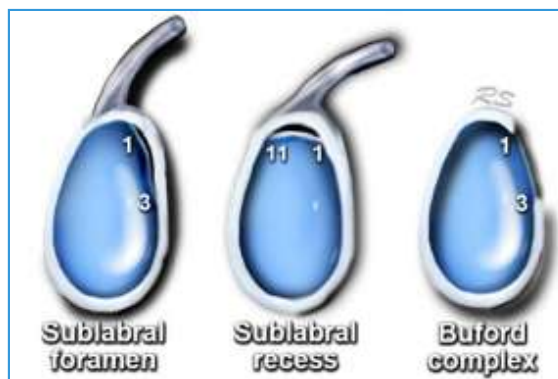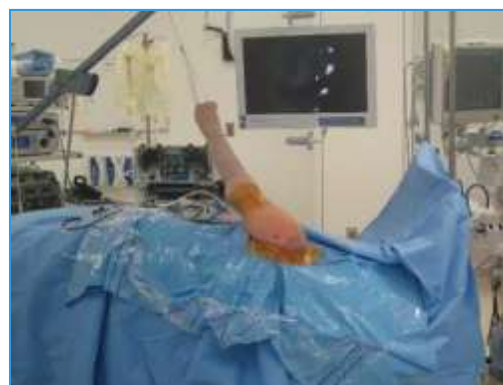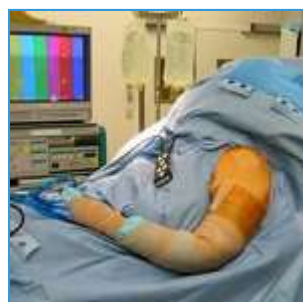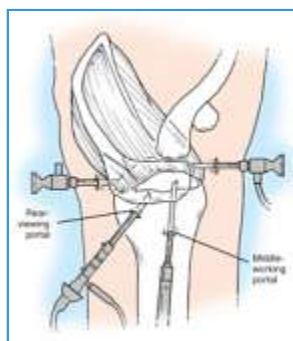
Nerve palsy (1-5%)

- greatest risks for nerve palsy
 - underlying rheumatoid arthritis
 - elbow contracture
- nerves
 - transient ulnar nerve palsy (most common)



- radial nerve palsy (second most common) - at risk from standard anterolateral portal
- medial antebrachial cutaneous and median nerves - at risk from anteromedial portal
- PIN palsy - at risk from anterolateral portal
- mechanism
 - direct injury
 - trocars and instrumentation
 - failure to use blunt dissection (neuromas)
 - indirect injury
 - compartment syndrome (aggressive distension, fluid extravasation)
 - local anesthesia extravasation (transient)
- Joint ankylosis/ heterotopic ossification
 - less than open surgery
 - minimize bleeding
- Infection
 - sinus tract formation (posterolateral portal)
 - higher risk with intra-articular steroid injection at the time of arthroscopy

52- Shoulder Arthroscopy Indications And Approach

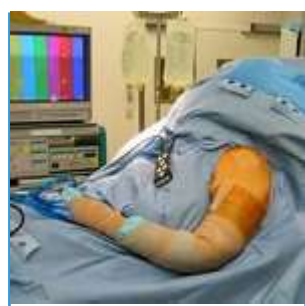

Indications

- Diagnostic surgery
- Loose body removal
- Rotator cuff repair or debridement
- Labral/SLAP and instability repair
- Subacromial decompression
- AC joint pathology
- Distal clavicle resection
- Release of suprascapular nerve entrapment
- Release of scar tissue/contractures
- Synovectomy
- Biceps tenotomy/tenodesis

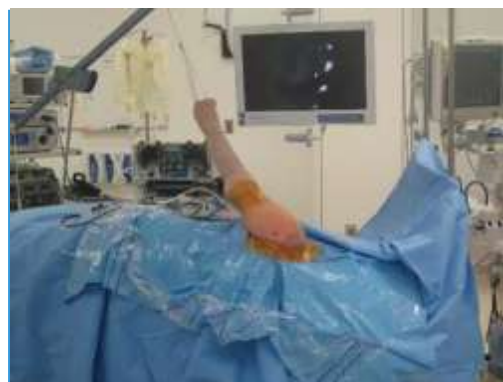Positioning

• Beach chair



- advantages
 - easy conversion to open deltopectoral approach if needed
 - decreased venous pressure and bleeding
- disadvantages
 - failure to properly position and pad the patient can result in neuropraxia
 - **supraorbital nerve** : face mask too tight or poorly padded across forehead
 - paresthesias over forehead and anterior scalp
 - **great auricular nerve** : face mask straps too tight or poorly padded at mastoid process
 - paresthesias over ear, posterior auricular area and angle of mandible
 - **lateral femoral cutaneous nerve** : lateral abdominal support poorly positioned and padded
 - paresthesias over anterolateral thigh
 - higher risk in obese patients due to weight of pannus
 - failure to position the neck in neutral
 - hyperextension: increased risk of stroke and cranial nerve palsy (CN12 hypoglossal)
 - hyperflexion: increased risk of spinal cord ischemia and resultant paraplegia
 - increased risk of **cerebral hypoperfusion** compared to lateral position

• Lateral decubitus



- advantage of joint distraction
 - can be associated with neuropraxias from traction

Primary Portals

• Posterior portal

- function
 - primary viewing portal used for **diagnostic arthroscopy**
- location and technique

- located 2 cm inferior and 1 cm medial to posterolateral corner of acromion
- portal may pass between infraspinatus (suprascapular nerve) and teres minor (axillary nerve) or pass through the substance of infraspinatus
- this is usually the first portal placed
- direct anteriorly towards tip of coracoid

• Anterior portal

- function
 - viewing and subacromial decompression
- location & technique
 - lateral to coracoid process and anterior to AC joint
 - portal passes between pectoralis major (medial and lateral pectoral nerves) and deltoid (axillary nerve)
- this portal is usually placed under direct supervision from the posterior portal with aid of spinal needle

• Lateral portal

- function
 - subacromial decompression
- location & technique
 - located 1-2 cm distal to lateral edge of acromion
 - portal passes through deltoid (axillary nerve)

Secondary Portals

• Anteroinferior (5 o'clock) portal

- function
 - placement of anchors in [anterior labral repair](#)
- location & technique
 - located slightly inferior to coracoid
 - this portal is usually placed under direct supervision from the posterior portal with aid of spinal needle

• Posteroinferior (7 o'clock) portal

- function
 - placement of anchors for [posterior labral repair](#)
- location & technique
 - this portal is usually placed under direct supervision from the posterior portal with aid of spinal needle

• Nevasier (supraspinatus) portal

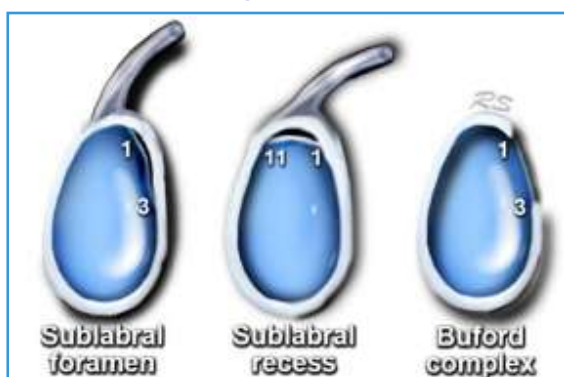
- function
 - anterior glenoid visualization and [SLAP repairs](#)
- location & technique
 - located just medial to lateral acromion
 - goes through supraspinatus muscle (suprascapular nerve)

• Port of Wilmington (posterolateral) portal

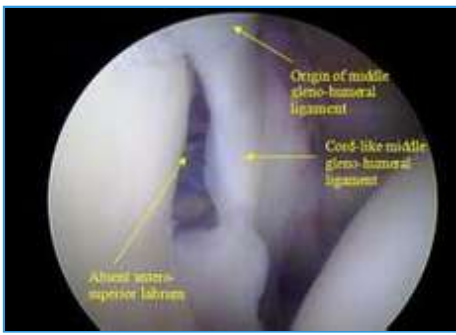- function
 - Used to evaluate/repair [posterior SLAP and RTC](#) lesions
- location & technique
 - just anterior to posterolateral corner of acromion
 - this portal is usually placed under direct supervision from the posterior portal with aid of spinal needle

Diagnostic Scope

- Performed with 30° scope through the posterior portal to identify
 1. Biceps tendon
 2. Supraspinatus
 3. Infraspinatus and teres minor.
 4. Rotator interval (formed by biceps tendon, superior edge of subscapularis, and glenoid)
 5. Anterior ligamentous complex (MGHL, IGHL)
 6. Subscapularis recess (loose bodies)
 7. Anterior labrum
 8. Glenoid
 9. Humeral head
- Anatomic variations
 - region of [anterosuperior labrum and MGHL](#) has wide anatomic variability



- **attached labrum** with broad MGHL is most common
- **sublabral hole** with cordlike MGHL
- **Buford complex**



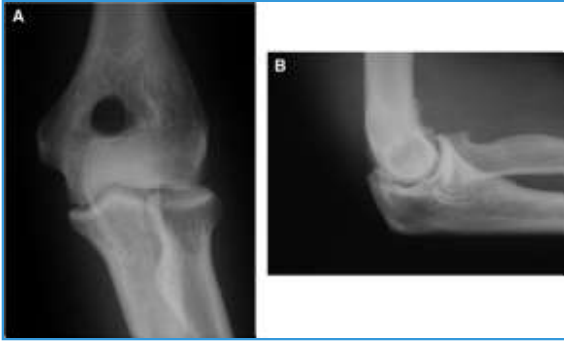- has absent labrum and cordlike MGHL
- **bare areas of cartilage** are normal on
 - central glenoid
 - posterior humeral head

Dangers

- **Posterior portal**
 - **axillary nerve**
 - leaves axilla through quadrangular space and winds around humerus on deep surface of the deltoid muscle and passes ~ 7 cm below tip of acromion
 - at risk if the posterior portal is made too inferior
 - **suprascapular nerve**
 - runs through suprascapular fossa and infraspinatus fossa before innervating both of these muscles.
 - at risk if the posterior portal is made too medial
- **Anterior portal**
 - **cephalic vein**
 - runs in deltopectoral groove & at risk if portal is too lateral
 - **musculocutaneous nerve**
 - enters muscles 2-8 cm distal to tip of coracoid
 - at risk if anterior portal is made too inferior
- **Anesthesia**
 - **phrenic nerve**
 - with intrascapular block (anesthesia)

53- Partial Elbow Arthroplasty

Images

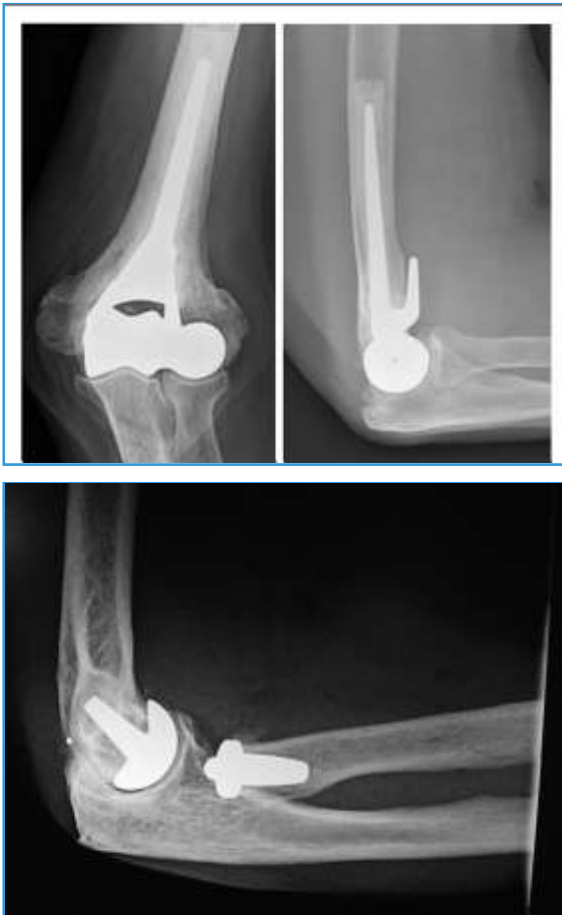

• Introduction

- Forms of elbow arthroplasty
 - total elbow arthroplasty
 - elbow hemiarthroplasty
 - radiocapitellar
 - distal humeral (not FDA approved)
 - ulnohumeral distraction & interpositional arthroplasty
 - ulnohumeral debridement arthroplasty
 - radial head excision
 - radial head arthroplasty

• Elbow Hemiarthroplasty

○ Introduction



- non-FDA approved hemiarthroplasty of either radiocapitellar joint or distal humerus
- thought to avoid capitellar degeneration

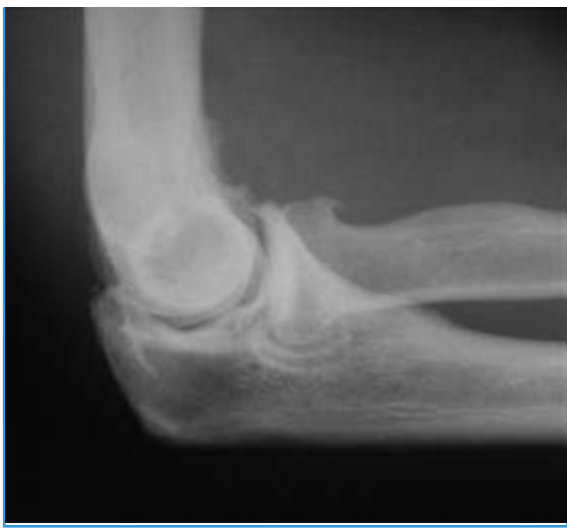• Ulnohumeral Arthroplasty (distraction interposition)

○ Introduction

- resection followed by contouring of articular surfaces with fascial interposition
- addition of distraction external fixator allows early motion

○ Indications

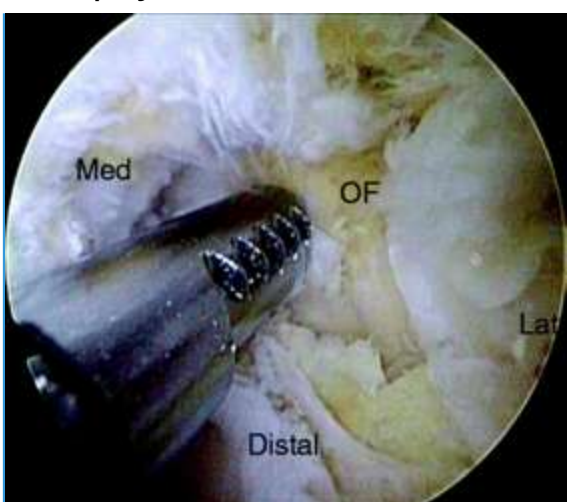
- young active patients with posttraumatic arthritis too young to follow TEA restrictions



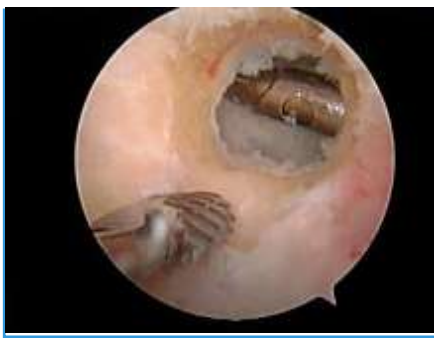- ligamentously stable elbow
- Approach
 - posterior midline skin incision
 - Kocher's interval
 - extensor musculature and LUCL complex released
 - if aconeus is to be used, release ulnar attachment
 - triceps released from lateral olecranon attachment, ulnar subluxated and elbow flexed to expose distal humerus
- Bone work
 - distal humerus and ulnar surfaces prepared with saw or rongeur to create congruent surface
 - all osteophytes and cartilage removed to expose subchondral bone
- Soft tissue
 - ulnar nerve transposed if symptomatic or prone to subluxate
 - capsular release performed to address contractures
- Instrumentation
 - local aconeus autograft, tensor fascia autograft or Achilles allograft interposed in joint, sutured into place to cover distal humerus
 - graft may be pulled through bone tunnels to address collateral insufficiency
 - hinged external fixator placed to distract joint and allow early motion
- Complications
 - bony resorption, joint subluxation, heterotopic ossification
- Outcomes
 - less predictable than TEA
 - reasonable pain relief achieved in short-term and intermediate-term
 - worse outcomes if residual instability present

• Ulnohumeral Debridement Arthroplasty (Outerbridge-Kashiwagi procedure)

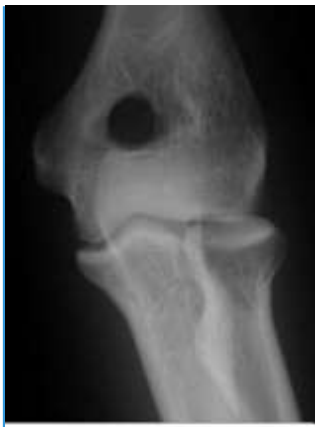- Indications
 - joint space narrowing
 - osteophytes (especially in posteromedial olecranon)
- Approach
 - arthroscopic debridement for mild disease and no prior ulnar nerve transposition
 - open debridement for severe disease with inaccessible joint space
 - posterior triceps-splitting approach
 - lateral column approach allows better access to anterior joint
- Bone work
 - osteophytes and soft tissues removed from olecranon tip and fossa



- olecranon fossa opened with burr or trephine to access coronoid fossa



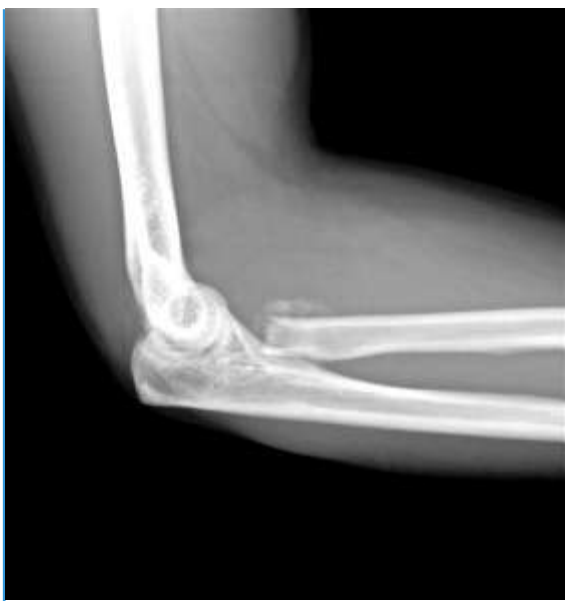- osteotome to resect coronoid osteophytes



- Soft tissue
 - capsular release may be done in conjunction if contracture present
 - generally the ulnar nerve is transposed if pre-operative range of motion less than 90 degrees
- Complications
 - lesser outcomes with failure to release all causative osteophytes
 - failure to recognize and address ulnar neuropathy with release or transposition leads to inferior outcomes
- Outcomes
 - improvements in motion and pain with both arthroscopic and open procedures

• Radial Head Excision

- Indications
 - rheumatoid arthritis isolated to the radiocapitellar joint
 - unreconstructable radial head fracture in ligamentously stable elbow
- Approach
 - performed using either Kocher or Kaplan's interval
 - supinator muscle fibers and capsule split longitudinally
- Bone work
 - resect any bony fragments
 - resect as little radial neck as possible



- use fluoroscopy to evaluate stability of elbow and distal radioulnar joint following resection
- Instrumentation
 - none
- Complications
 - progressive degenerative changes in ulnohumeral joint of unclear significance
 - radial shortening and wrist pain, likely secondary to unrecognized interosseous injury
- Outcomes
 - increase in valgus elbow carrying angle

• Radial Head Arthroplasty

- Indications



- unreconstructable radial head fracture
- radial head malunion or nonunion
- radiocapitellar arthritis
- Approach
 - performed using either Kocher or Kaplan's interval
 - supinator muscle fibers and capsule split longitudinally
- Soft tissue
 - LACL complex may be taken down for visualization but must be repaired
- Bone work
 - level of saw cut at the base of radial neck
 - proximal canal broached to anatomic fit
- Instrumentation
 - size the native radial head if intact
 - trial implant to assess for gapping or overstuffing of joint
 - lesser sigmoid notch can serve as landmark if using fluoroscopy
 - assess fit in both extension and flexion
- Complications
 - capitellar degeneration due to overstuffing joint

54- Flexor Pronator Strain

• Summary

- Flexor Pronator Strains are acute or chronic muscle strains of the flexor pronator mass, distal to its origin on the medial epicondyle.
- Diagnosis is made clinically with medial elbow swelling and ecchymosis in acute strains with tenderness distal to the medial epicondyle. MRI studies can be used to help identify complete tears or UCL injuries.
- Treatment is generally nonoperative with rest, activity modifications and physical therapy.

• Epidemiology

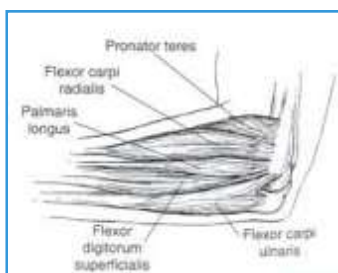
- Demographics
 - golfers
 - cricket players
 - throwing athletes

• Etiology

- Pathophysiology
 - acute muscle tear
 - single event of a large, eccentric force during resisted wrist flexion, forearm pronation, and valgus at the elbow
 - chronic overuse can lead to acute flexor pronator rupture
 - sudden onset of pain and flexor weakness
 - chronic tendonitis
 - repetitive elbow valgus, wrist flexion, and forearm pronation
- Associated conditions
 - ulnar collateral ligament insufficiency
 - should be ruled out in throwing athletes

• Anatomy

- Flexor pronator mass provides dynamic support to the medial elbow against valgus stress
- Flexor pronator mass includes (proximal to distal)



- Pronator Teres (median n.)
- Flexor Carpi Radialis (median n.)
- Palmaris Longus (median n.)
- FDS (median n.)
- Flexor Carpi Ulnaris (ulnar n.)

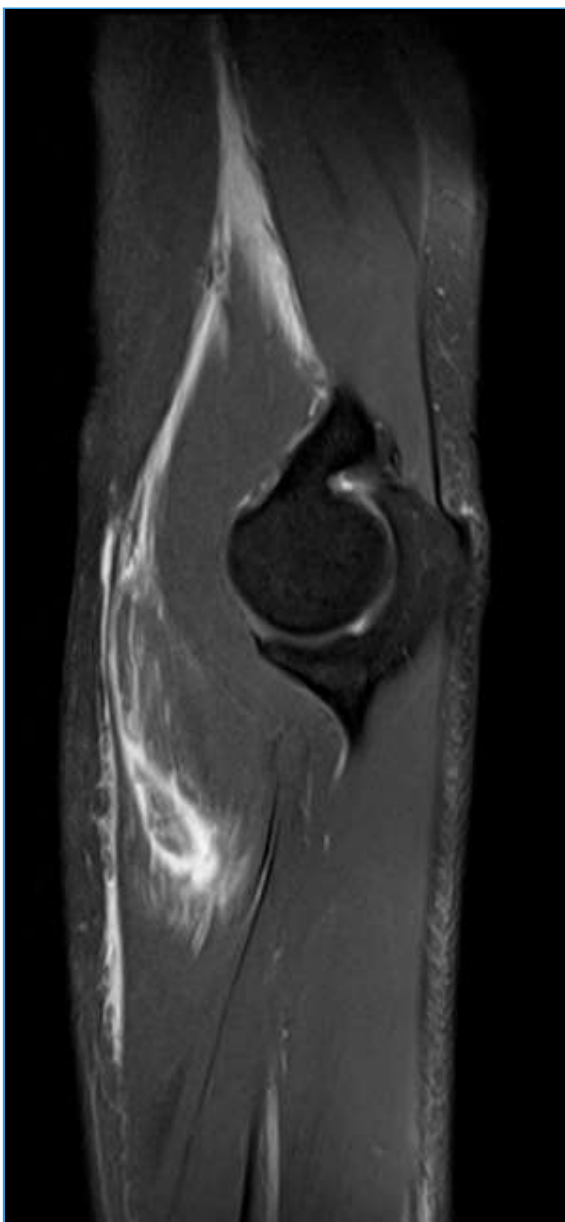
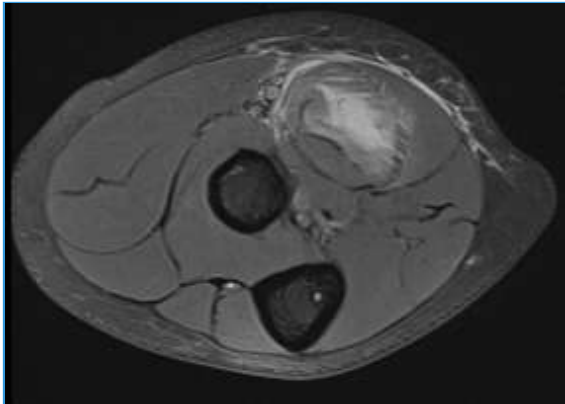
• Presentation

- History
 - acute event of hitting the ground during golf, bat, or racquet swing
 - history of throwing or racquet sports
 - repetitive gripping and/or elbow valgus stress activities
- Symptoms
 - pain
 - medial elbow pain distal to the medial epicondyle
 - chronic pain during late cocking/early acceleration
- Physical exam
 - medial elbow swelling and ecchymosis in acute strain
 - tenderness distal to medial epicondyle

- provocative tests
 - pain with elbow extension and resisted wrist flexion or pronation
- examine for associated conditions
 - negative moving valgus stress test
 - normal neurovascular exam

• Imaging

- Radiographs
 - usually normal
- MRI
 - indications
 - unclear source of medial elbow pain
 - grade severity of muscle strain
 - rule out other causes of medial elbow pain such as UCL rupture
 - findings



- edema in flexor pronator mass
- partial tearing or complete rupture of flexor pronator mass

• Differential

- Medial epicondylitis
- UCL injury
- Valgus extension overload with posteromedial olecranon impingement

• Treatment

- Nonoperative
 - **NSAIDS, rest, physical therapy, steroid injections**

- indications
 - first line of treatment
- technique
 - ROM and flexor pronator strengthening x 4-6 weeks
 - corticosteroid injection for chronic flexor pronator tendonitis
 - rarely needed
 - avoid UCL due to risk of rupture
- outcomes
 - typical resolution and return to sport in 4-6 weeks
- Operative
 - **primary surgical repair**
 - indications
 - significant (>2.5 cm) retraction

- Complications

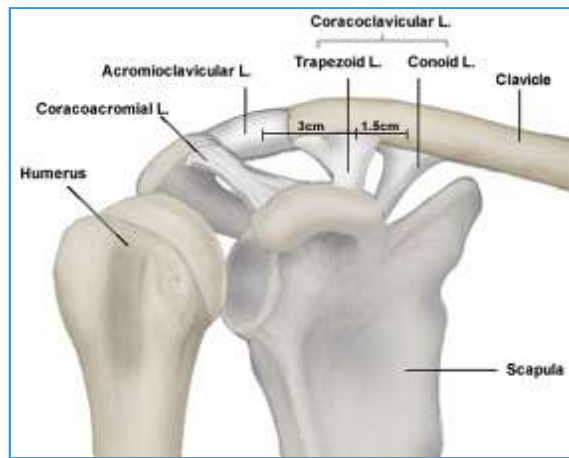
- Continued medial elbow pain and valgus instability
 - unrecognized UCL insufficiency

- Prognosis

- Typically resolves with 4-6 weeks of activity restriction

55- Acromioclavicular Joint

Images



• AC joint

○ Osteology

- the AC joint is a diarthrodial joint
- fibrocartilaginous intraarticular disc is located between the osseous segments

○ Motion

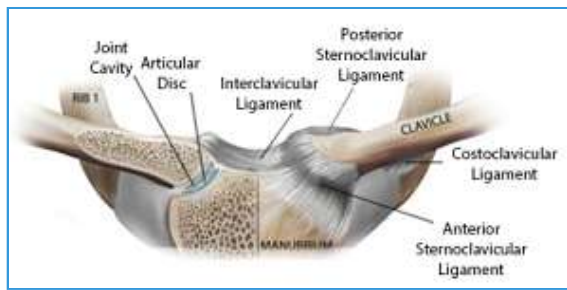
- majority of motion is from the bones, not through the joint
 - clavicle rotates 40-50° posteriorly with shoulder elevation
 - 8° of rotation through AC joint
 - remainder from scapular rotation and sternoclavicular motion
- joint itself is limited to gliding motions only

○ Stability

- acromioclavicular ligament
 - provides horizontal stability
 - has superior, inferior, anterior, and posterior components
 - superior ligament is strongest, followed by posterior
- coracoclavicular ligaments (trapezoid and conoid)
 - provides vertical stability
 - trapezoid inserts 3 cm from end of clavicle
 - stabilizer against horizontal and vertical loads
 - conoid inserts 4.5 cm from end of clavicle in the posterior border
 - more important ligament
 - vertical stabilizer of AC joint
 - normal CC distance (superior coracoid to inferior clavicle) is 11-13mm
- deltotrapezial fascia, capsule, deltoid and trapezius
 - act as additional stabilizers

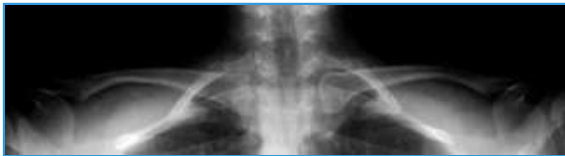
56- Sternoclavicular Joint

Images

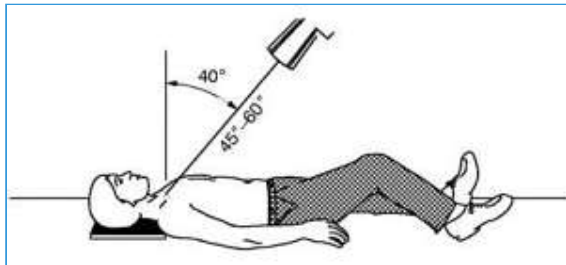


• Introduction

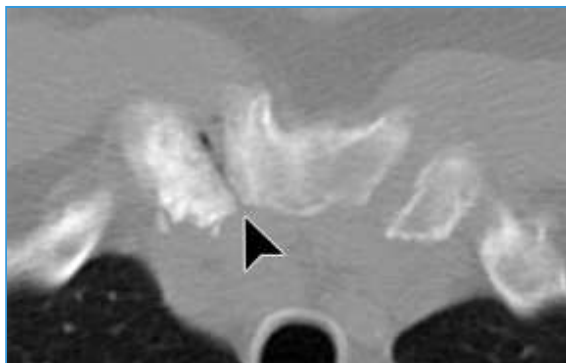
- Diarthrodial saddle joint incongruous (~50% contact)
 - fibrocartilage (not synovial cartilage)
 - contains an intra-articular disc
- Motion
 - elevation of arm to 90° leads to rotation of the sternoclavicular joint of 30°
- Imaging
 - best assessed radiographically by Serendipity view



- involves 40° cephalic tilt view of sternum and clavicle



- CT scan is most sensitive and specific



• Stabilizing Ligaments of Sternoclavicular Joint

- Posterior sternoclavicular capsular ligament
 - primary restraint for anterior-posterior stability
- Anterior sternoclavicular ligament
 - primary restraint to superior displacement of medial clavicle
- Costoclavicular (rhomboid) ligament
 - anterior fasciculus resists superior rotation and lateral displacement
 - posterior fasciculus resists inferior rotation and medial displacement
- Intra-articular disk ligament
 - prevents medial displacement of clavicle
 - secondary restraint to superior clavicle displacement

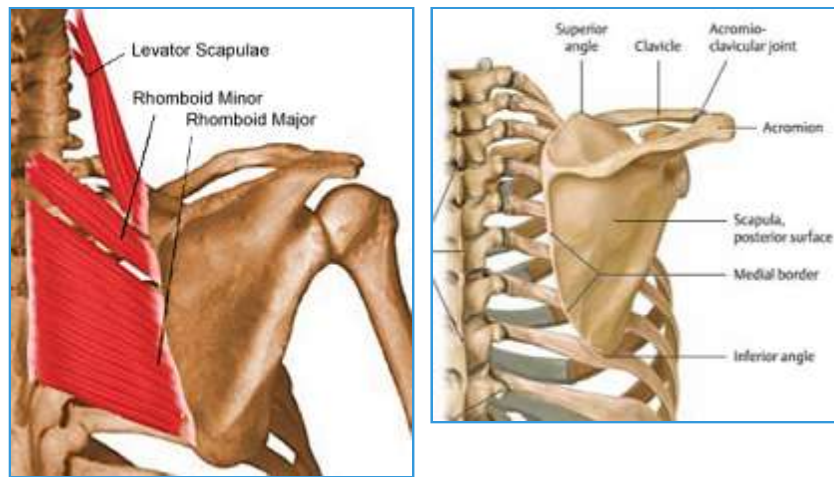
• Medial Clavicle Anatomy

- Clavicle is the first bone to begin the ossification process
 - ossifies between 5th and 6th weeks of gestation
- Clavicle is the last bone to complete the ossification process
 - medial epiphysis of clavicle is last physis to close at 20-25 yrs
- Important to distinguish SC dislocations from physeal fractures

- most injuries at this location involve the medial clavicular physis before age of 25

57- Scapulothoracic Joint

Images



• Introduction

○ Function

- allows scapular motion against the rib cage

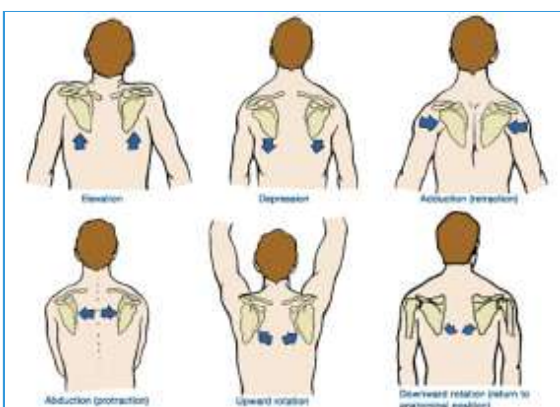
○ Osteology

- not a true joint; actually an articulation between the scapula and the thorax
- is a sliding "joint" between medial border of scapula and ribs 2-7
- resting position angulation (although these are variable even in healthy adults)
 - anteriorly 10-20°
 - internally rotated 30°-45° from the coronal plane
 - upward tilt of 3°

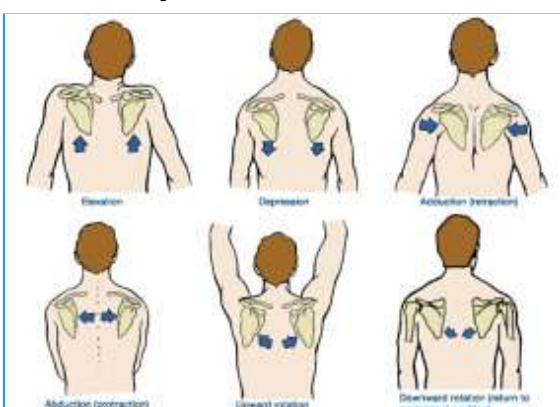
• Biomechanics

○ Motion

- primary motion



- elevation & depression
 - movement up and down along the rib cage
- secondary motions



- protraction & retraction
 - movement away from or toward the vertebral column
- upward & downward rotation
 - upward rotation with arm elevation
 - downward rotation with arm returning to side from raised position
- internal & external rotation
- anterior & posterior tipping
- shoulder abduction

- the ratio of glenohumeral motion to scapulothoracic motion is 2:1
 - GH does 120°, then ST does 60°

- Stability





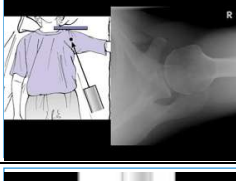


- 17 different muscles attach to or originate from the scapula
 - trapezius
 - serratus anterior
 - deltoid
 - latissimus dorsi
 - levator scapulae
 - rhomboid major
 - rhomboid minor
 - omohyoid - inferior belly
 - pectoralis minor
 - teres major
 - teres minor
 - triceps brachii
 - biceps brachii
 - coracobrachialis
 - infraspinatus
 - subscapularis
 - supraspinatus






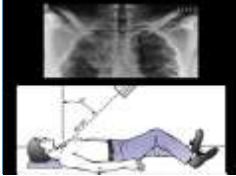
- Clinical

- Scapulothoracic dissociation
- Scapular winging
- Scapulothoracic dyskinesis

58- Shoulder Imaging

- Radiographs

<ul style="list-style-type: none"> Complete trauma series 		
View	Focus	
<ul style="list-style-type: none"> Shoulder AP 	<ul style="list-style-type: none"> Glenohumeral joint space, DJD 	<ul style="list-style-type: none"> 
<ul style="list-style-type: none"> Grashey view (True AP) 	<ul style="list-style-type: none"> Glenohumeral joint space, DJD, and proximal migration of humerus 	<ul style="list-style-type: none"> 
<ul style="list-style-type: none"> AP in ER 	<ul style="list-style-type: none"> Hill Sachs lesion 	<ul style="list-style-type: none"> 
<ul style="list-style-type: none"> AP in IR 	<ul style="list-style-type: none"> Hill Sachs lesion 	<ul style="list-style-type: none"> 
<ul style="list-style-type: none"> Axillary lateral 	<ul style="list-style-type: none"> Anterior and posterior dislocation, acromion 	<ul style="list-style-type: none"> 
<ul style="list-style-type: none"> Velpeau view 	<ul style="list-style-type: none"> Axillary lateral modification if unable to abduct the arm 	<ul style="list-style-type: none"> 
<ul style="list-style-type: none"> Scapular Y lateral 	<ul style="list-style-type: none"> Anterior and posterior dislocation 	<ul style="list-style-type: none"> 

Additional views		
View	Focus	
Supraspinatous Outlet	Allows classification of acromion (Type I-flat, Type II-curved, Type III-hooked). Hooked acromion is associated with impingement and rotator cuff pathology.	
Zanca	Help visualize the AC joint. Shows AC joint disease and distal clavicle osteolysis.	
Stryker notch	Hill-Sachs lesion	
West point axillary	Anteroinferior glenoid, bony bankart, proximal humerus fx	
Garth	Anteroinferior glenoid, bony bankart	
Hobbs	Anterior and posterior sternoclavicular dislocation	
Serendipity	Anterior and posterior sternoclavicular dislocation	

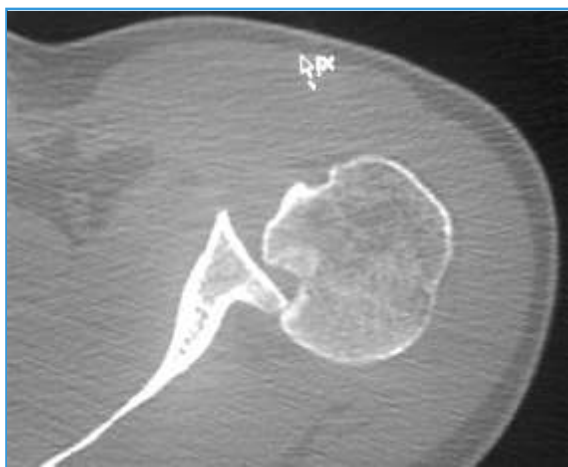
• Computed Tomography

○ Overview

- provides better detail of cortical and trabecular bone structures than MRI at cost of higher radiation exposure
- there for optimal for visualization of bony defects
- magnification artifacts that are associated with radiographs do not occur with CT

○ Axial Shoulder Images

- useful to visualize
 - Reverse Hill Sachs



○ Coronal Shoulder Images

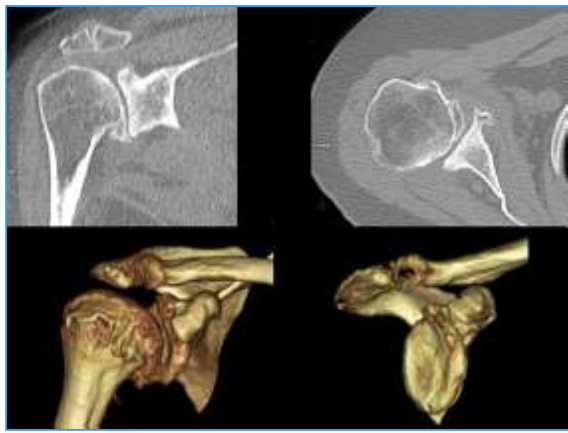
- useful to visualize
 - fractures

○ Sagittal Shoulder Images

- useful to visualize
 - anterior-inferior glenoid insufficiency

○ 3D Reconstructions

- useful to visualize
 - glenoid version for total shoulder arthroplasty



- Magnetic Resonance Imaging

- Overview

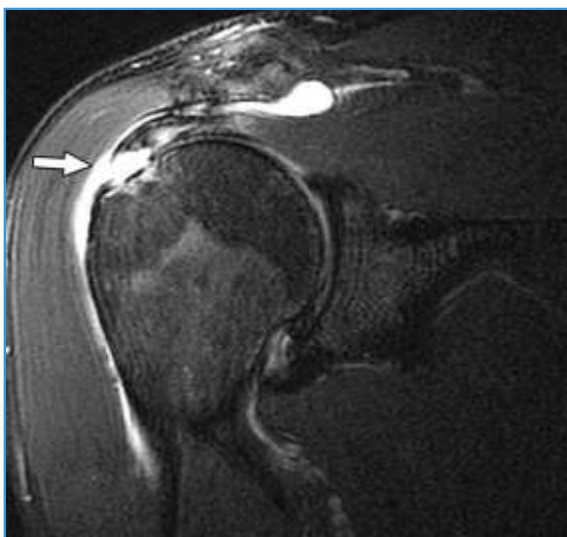
- MRI is best for evaluating soft tissue structures and evaluating bone contusions or trabecular microfractures
 - the stronger the magnet, the higher the intrinsic signal-to-noise ratio (e.g. a 3 Tesla MRI machine has 9x the proton energy of a 1.5 Tesla MRI machine)

- T1-weighted sequence

- uses a short repetition time (TR) and short echo time (TE)
 - bright= fat
 - dark= fluid, bone, ligament, bone marrow, and fibrocartilage
 - often combined with MR arthrograms
 - useful to visualize
 - Hill Sachs Lesion

- T2-weighted sequence

- uses a long TR and long TE
 - bright= fluid (inflammation) and bone marrow
 - dark= bone, ligament, muscle, and fibrocartilage
 - useful to visualize
 - rotator cuff pathology
 - full thickness tear

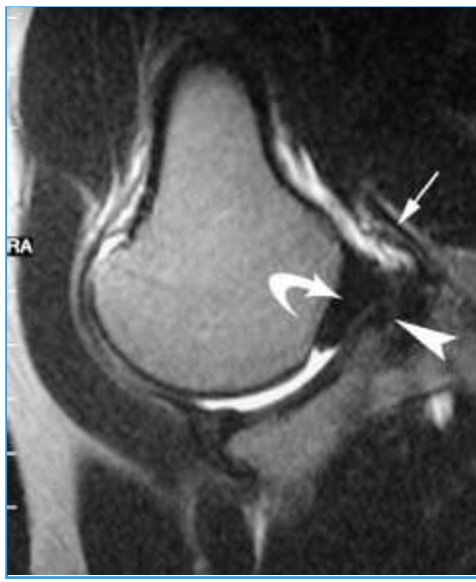


- Short tau inversion recovery (STIR)

- Fat saturation (e.g. suppression) technique
 - technique that reduces signal from fat and increases signal from fluid and edema
 - helps to determine edema versus fatty infiltration in the rotator cuff muscles
 - useful to visualize
 - rotator cuff pathology

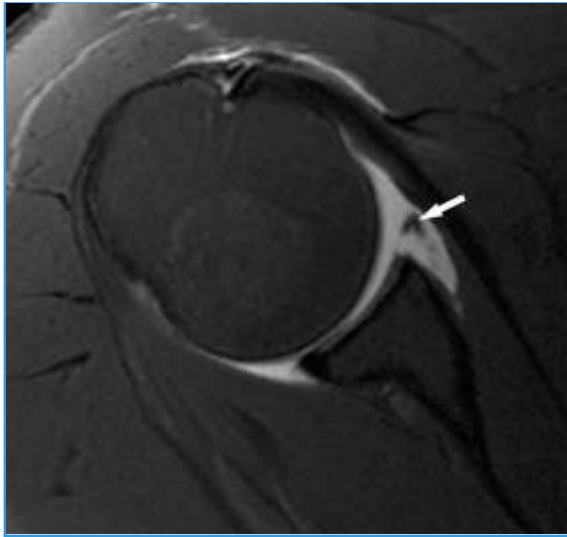
- ABER (abduction external rotation) position

- sequence beyond the conventional 3 sequences (coronal, sagittal, and axial)
 - patient places affected hand behind their head instead of a true 90-90 degree abduction-external rotation position
 - position tensions the anteroinferior glenohumeral ligament and labrum and relaxes the capsule
 - useful to visualize
 - Bankart lesions
 - partial- and full-thickness tears of the rotator cuff tendons
 - internal impingement

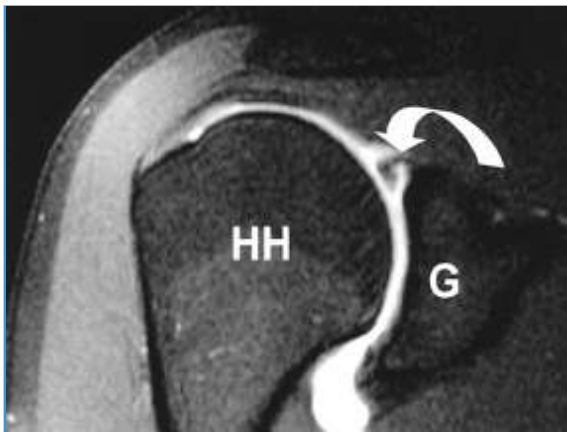


○ MR arthrogram

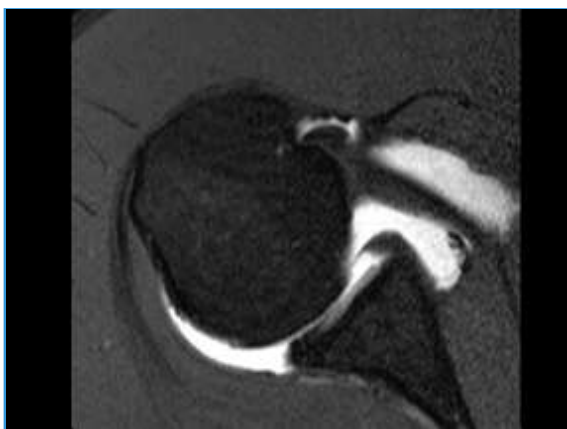
- commonly used to augment MRI to diagnose soft-tissue problems such as SLAP tears
 - dilute gadolinium-containing solution is percutaneously injected into the joint.
- optimal for
 - labral and ligament pathology
 - Bankart lesion



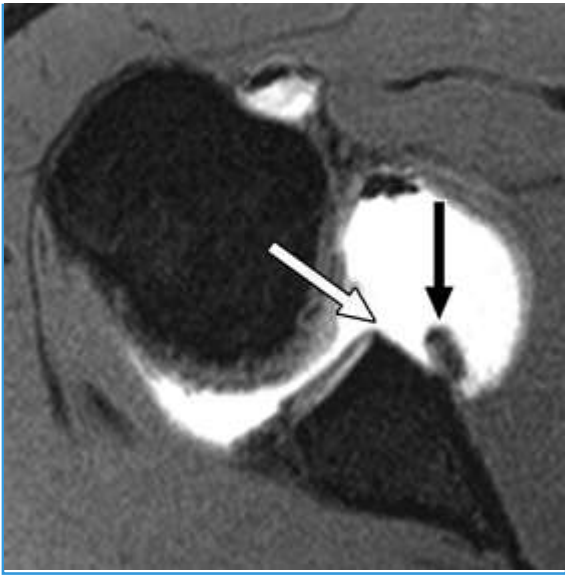
- Superior labrum anterior-posterior tear (SLAP)



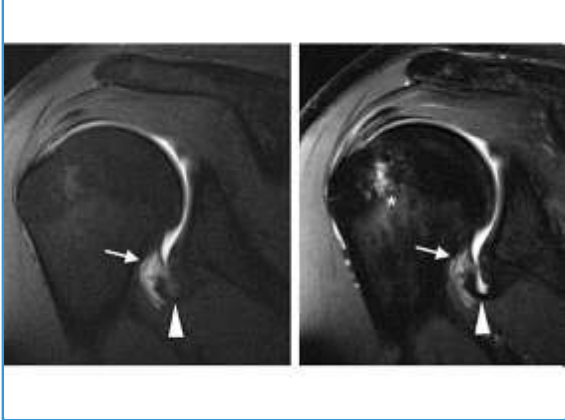
- Glenoid labral articular disruption (GLAD)



- Anterior labral periosteal sleeve avulsion (ALPSA)



- Humeral avulsion of the glenohumeral ligament (HAGL)



59- Subcoracoid Impingement

• summary

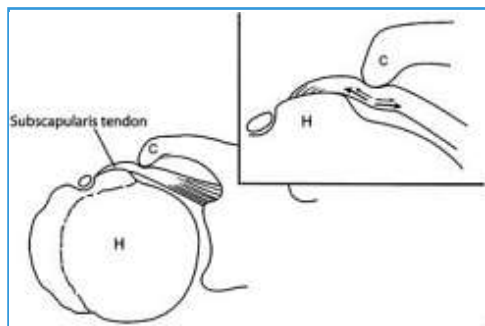
- Subcoracoid impingement is the impingement of the subscapularis between the coracoid and lesser tuberosity which can lead to anterior shoulder pain and possibly tearing of the subscapularis.
- Diagnosis can be made clinically with tenderness over the anterior coracoid which is made worse with shoulder flexion/internal rotation and supplemented with CT scan showing decreased coracohumeral interval.
- Treatment is a course of conservative measures including NSAIDs, physical therapy and corticosteroid injections. Arthroscopic or open coracoplasty is indicated for patients with progressive symptoms having failed conservative measures.

• Etiology

○ Pathoanatomy

▪ mechanism

- position of maximal impingement is arm adduction , flexion , and internal rotation



▪ risk factors

- patients with a long or excessively lateral coracoid process
- prior surgery that caused posterior capsular tightening and loss of internal rotation

○ Associated conditions

- combined subscapularis, supraspinatus, and infraspinatus tears

• Anatomy

○ Glenohumeral joint anatomy and biomechanics

○ Coracoid

▪ muscle attachments

- coracobrachialis, pectoralis minor, and short head of the biceps attach to the coracoid

▪ ligamentous attachments

- coracohumeral ligament, coracoacromial ligament attach to coracoid
- coracoclavicular ligament which is composed of the conoid and the trapezium

○ Subscapularis tendon

- inserts onto lesser tuberosity

• Presentation

○ Symptoms

- pain in anterior shoulder worsened by various degrees of flexion, adduction, and rotation

○ Physical exam

- tenderness over anterior coracoid
- position of maximal pain is 120-130° of arm flexion and internal rotation

• Imaging

○ Radiographs

▪ recommended views

▪ findings

- may show a decreased coracohumeral distance

○ CT scan

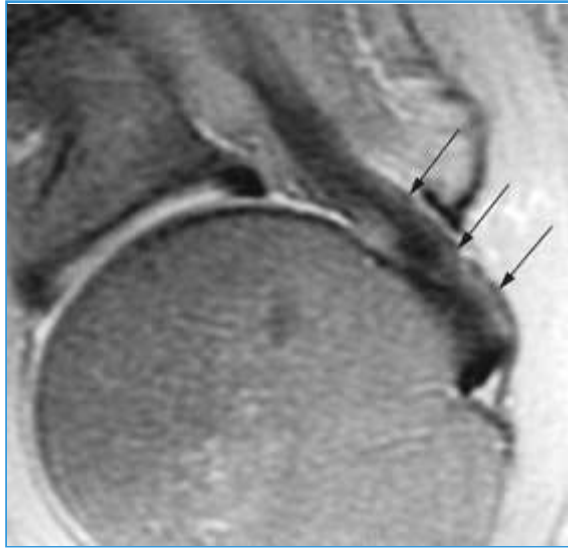
▪ views

- obtained with the arms crossed on chest is helpful to make the diagnosis

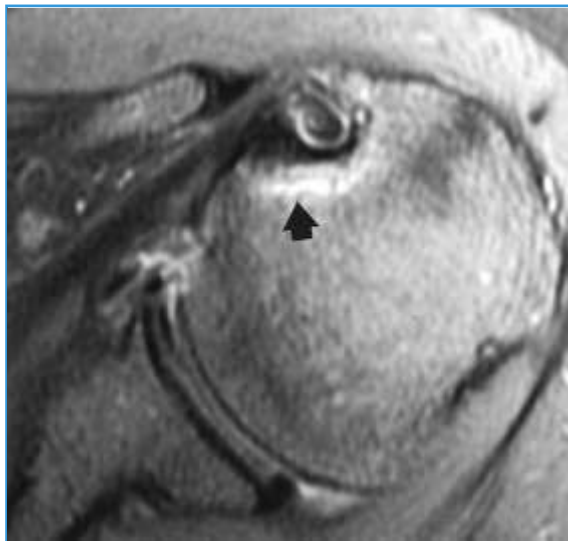
- findings
 - a coracohumeral distance of < 6 mm is considered abnormal
 - normal is 8.7 mm in the adducted arm 6.7 mm in the flexed arm

- MRI

- indications
 - used to evaluate degree of rotator cuff pathology
- findings
 - increased signal in subscapularis

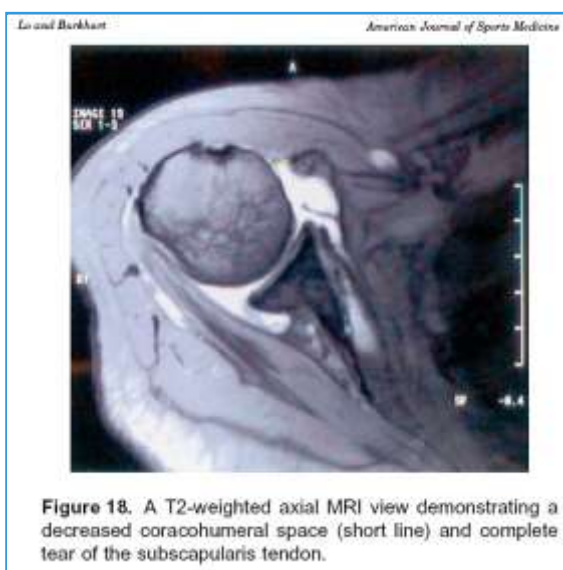
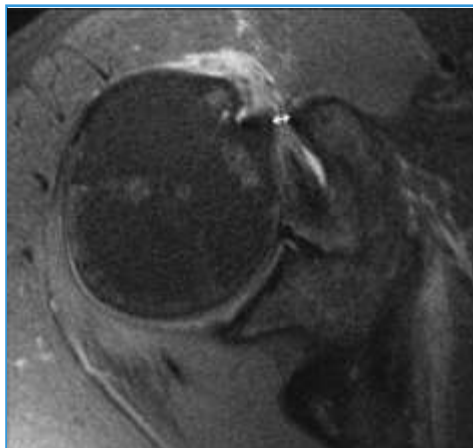


- increased signal in lesser tuberosity



- views

- axial view also effective to look for a decreased coracohumeral distance



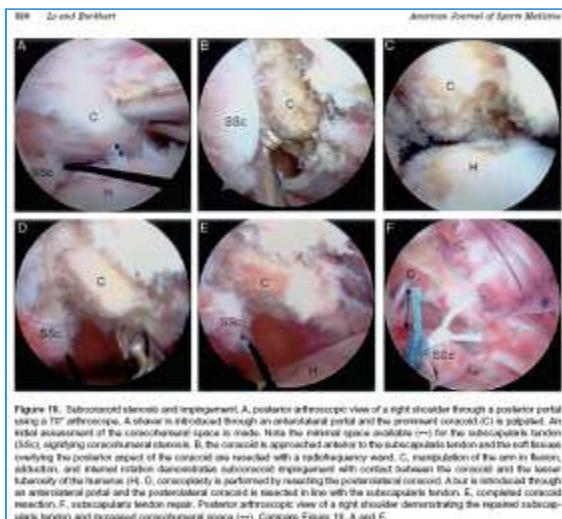- Studies

- Diagnostic injection

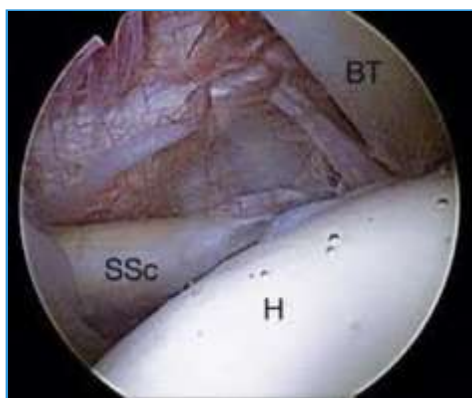
- local corticosteroid injections should eliminate symptoms and can be diagnostic

- Treatment

- Nonoperative
 - rest, ice, activity modification, NSAIDs, corticosteroid injections
 - indications
 - first line of treatment
 - techniques
 - local corticosteroid injections can be diagnostic and therapeutic
 - PT focuses on stretching
- Operative
 - arthroscopic coracoplasty ± subscapularis repair



- indications
 - symptoms refractory to conservative treatment
 - subscapularis tearing secondary to impingement
- technique
 - resect posterolateral coracoid to create 7 mm clearance between coracoid and subscapularis
 - if significant subscapularis tendon tear then repair



- open coracoplasty
 - indications
 - symptoms refractory to conservative treatment
 - subscapularis tearing secondary to impingement
 - technique
 - resect lateral aspect of coracoid process and reattach the conjoined tendon to the remaining coracoid

60- Ac Arthritis

• Summary

- AC arthritis is the most common cause of AC joint pain with repetitive microtrauma leading to the development of osteoarthritis in the AC joint.
- Diagnosis is made with dedicated shoulder radiographs that reveal osteophytes and joint space narrowing in the AC joint.
- Treatment is a trial of NSAIDs, activity modifications, and corticosteroid injections. Arthroscopic versus open distal clavicle excision is indicated for patients with persistent symptoms that have failed nonoperative treatment.

• Epidemiology

- Demographics
 - more common with age but can occur by second decade of life
 - more common in weight-lifters and other sports
- Risk factors
 - trauma
 - post-traumatic (i.e. clavicle fractures, AC instability)
 - distal clavicle osteolysis
 - inflammatory arthropathy (i.e. RA)
 - post-infectious arthropathy (i.e. septic arthritis)
 - Commonly associated with individuals who engage in constant heavy overhead activities
 - especially in weight-lifters and overhead throwing athletes

• Etiology

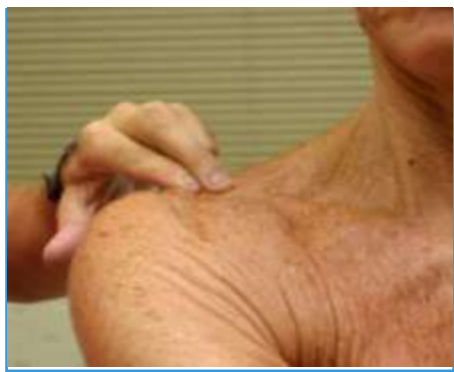- Pathophysiology
 - AC joint arthritis is caused by transmission of axial large loads through a small contact area resulting in repetitive microtrauma (same mechanism as distal clavicle osteolysis)

• Anatomy

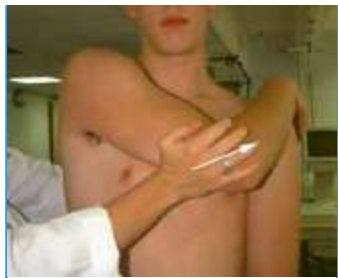- Acromioclavicular Joint Anatomy
 - diarthrodial joint
 - articulation scapula to clavicle
 - contains a fibrocartilaginous intraarticular disc analogous to the meniscus of the knee
 - Small articular surface area with relatively high axial and rotational loads leads to high contact forces across AC joint
 - Exacerbated by articular disk degeneration and oblique joint surface orientation
 - Ligaments
 - acromioclavicular (AC) ligaments
 - provide anterior-posterior stability
 - posterior and superior AC ligaments are most important for stability
 - coracoclavicular (CC) ligaments
 - provide superior-inferior stability

• Presentation

- Symptoms
 - activity related superior shoulder pain
 - with overhead activity
 - with cross body arm adduction
 - with O'Brien's active compression test (at 90 degrees forward flexion)
 - exacerbated with pressing motion (i.e. bench press, push-up) and leaning on affected side (i.e. while sleeping)
- Physical examination
 - palpation
 - pain with direct palpation of AC joint



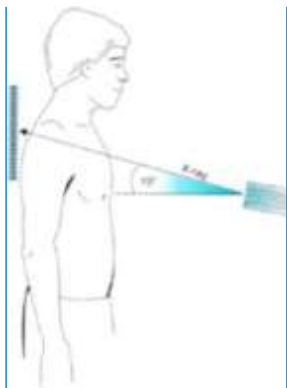
- prominence of the distal clavicle (osteophytes)
- provocative tests
 - pain with cross body adduction test



• Imaging

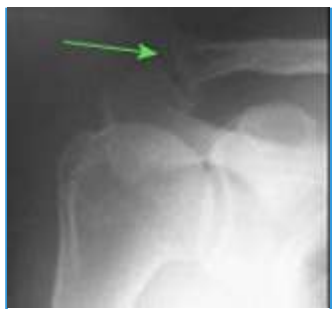○ Radiographs

- recommended views
 - best evaluated using Zanca view (15° cephalic tilt)



▪ Findings

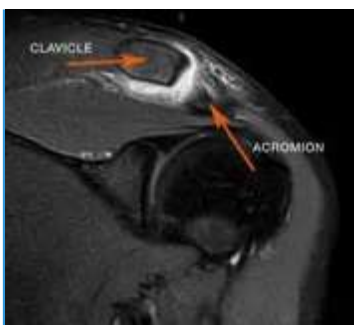
- osteophytes and joint space narrowing



- distal clavicle osteolysis
- imaging findings do not always correlate with patient symptoms (often present on radiographs without clinical signs or symptoms)

○ MRI

- increased signal and edema in AC joint

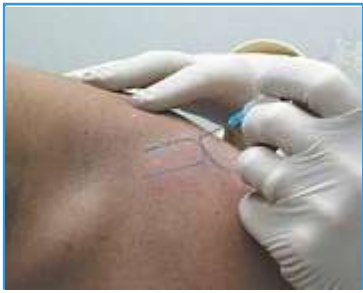

- visualize associated pathology (i.e. rotator cuff, long head of biceps tendon)

• Treatment

○ Nonoperative

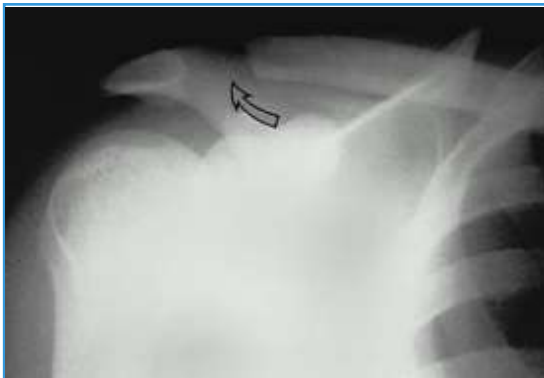- **activity modification and physical therapy**
 - first line of treatment
 - avoid aggravating activity such as pushing/pressing activities
 - physical therapy should focus on strengthening and stretching of shoulder girdle
- **AC joint injection with corticosteroids**



- can be both diagnostic and therapeutic modality
- access to the AC joint is challenging
- AC joint injections often miss the joint
 - ultrasound improves accuracy of injection
- most patients do not experience long term relief after injections

- Operative

- **arthroscopic vs. open distal clavicle resection (Mumford procedure)**



- indications
 - severe symptoms that have failed nonoperative treatment
- outcomes
 - open vs. arthroscopic based on surgeon preference and comfort
 - arthroscopic resection has the advantage of allowing evaluation of the glenohumeral joint and treatment of any associated injuries (rotator cuff, long head of biceps and glenoid labrum)
 - can combine diagnostic arthroscopy with open distal clavicle resection
 - open procedures require meticulous repair of deltotrapezial fascia

- Techniques

- **Arthroscopic distal clavicle resection**

- should only resect 0.5-1cm of distal clavicle

- Complications

- AC joint instability

- anterior-posterior instability
 - can be due to aggressive surgical distal clavicle resection ($>1-1.5\text{cm}$)
 - aggressive debridement sacrificing posterior and superior AC ligaments
- superior-inferior instability
 - usually iatrogenic due to aggressive surgical resection compromising coracoclavicular ligaments

- Persistent pain

- most commonly due to incomplete resection of distal clavicle
 - posterior-superior area of the distal clavicle

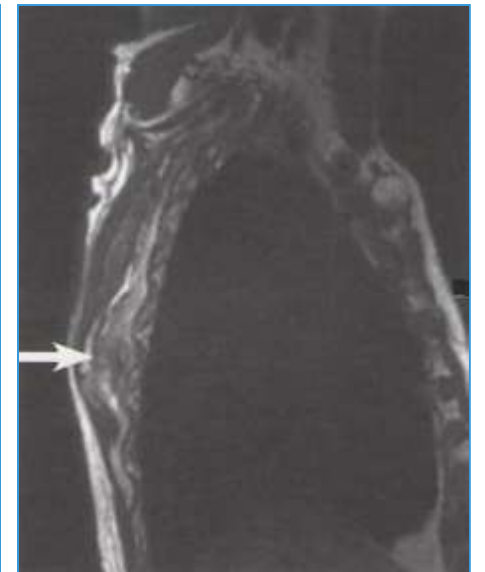
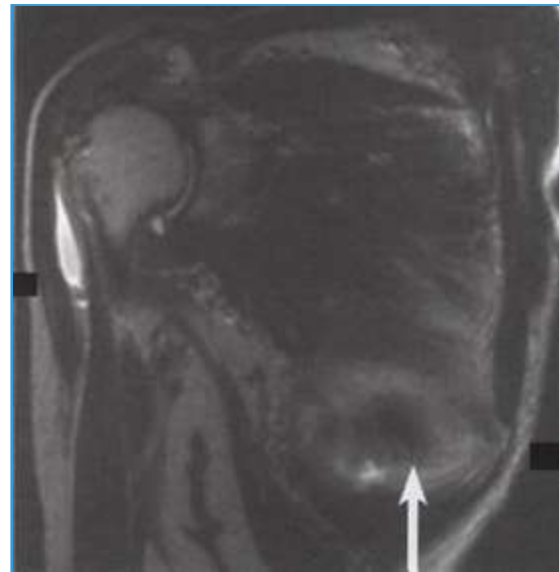
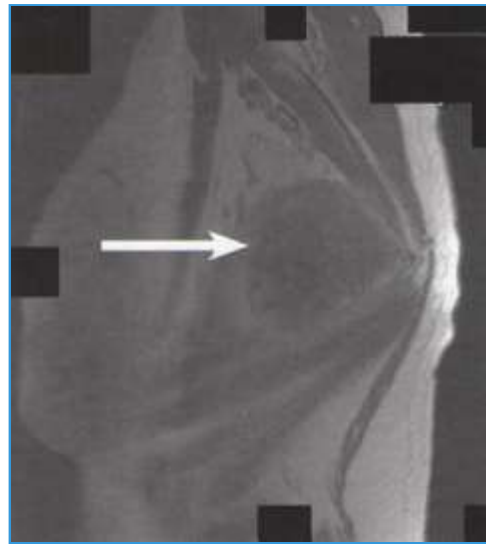
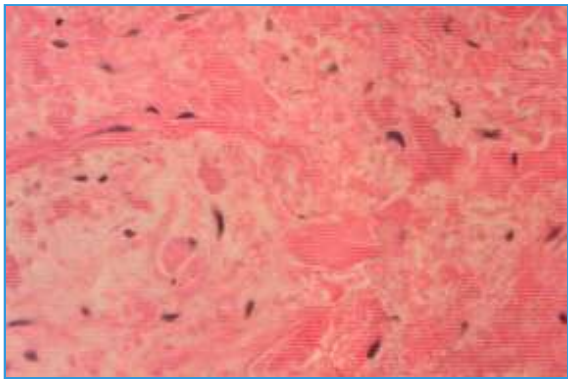
- Heterotopic ossification

- Deltoid dehiscence

- inadequate deltotrapezial fascia repair after open distal clavicle resection

61- Scapulothoracic Crepitus

Images

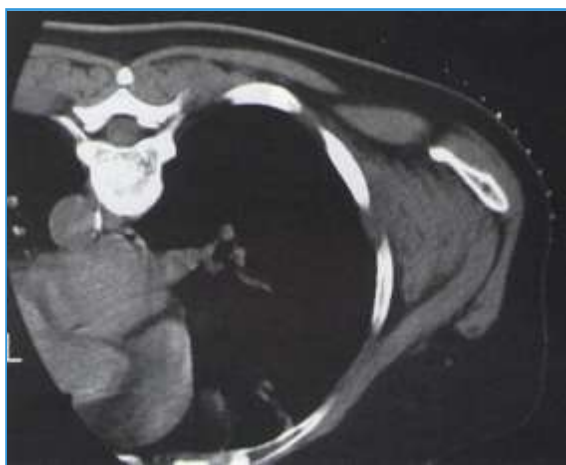

• summary

- Scapulothoracic crepitus, or snapping scapula syndrome, manifests as pain at the scapulothoracic junction with overhead activity.
- Diagnosis is made clinically with painful crepitus of the scapulothoracic joint with forward flexion and improvement of pain with stabilization of the scapula.
- Treatment is mainly nonoperative with NSAIDs, scapular strengthening exercises, postural training and activity modifications.

• Etiology

- Pathophysiology
 - predisposing abnormal anatomy
 - 6% of scapulae have some superomedial hooking
 - malunion of scapula or rib fractures
 - history of resection of 1st rib for thoracic outlet syndrome
 - overuse with normal anatomy
 - inflammation from overuse results in chronic inflammation, causing bursal fibrosis, bursitis, snapping
 - bony or soft tissue masses
 - osteochondroma
 - elastofibroma dorsi

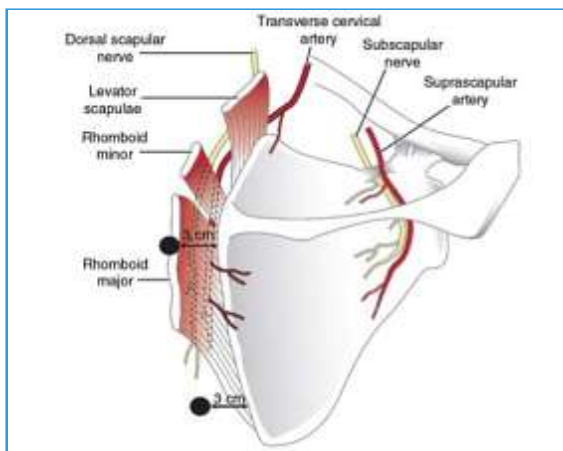


- a benign soft tissue tumor
- scapular chondrosarcoma
- Associated conditions
 - Scoliosis, kyphosis
 - scapulothoracic dyskinesia

• Anatomy

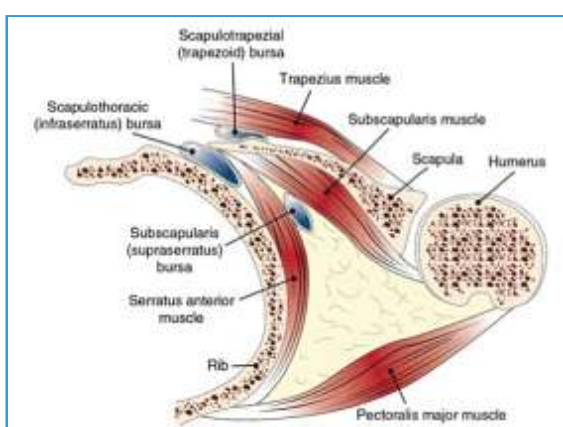
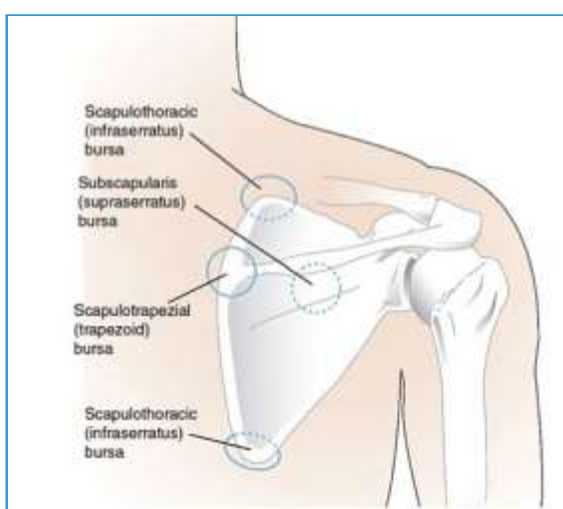
- Osteology - Scapula
 - spans ribs 2 to 7
 - three borders (superior, lateral, medial)
 - three angles (superomedial, inferomedial, lateral)

- no direct bony articulation
- no true synovial articulation
- Muscles
 - trapezius
 - serratus anterior
 - subscapularis
 - levator scapulae
 - rhomboids
 - supraspinatus
 - infraspinatus
 - teres minor
 - teres major
 - triceps brachii (long head)
 - biceps brachii
 - coracobraccialis
 - deltoid
 - pectoralis minor
 - latissimus dorsi (small slip of origin)
 - omohyoid
- Ligaments
 - transverse scapular ligament - separates suprascapular artery (above) from suprascapular nerve (below, in suprascapular notch)
- Blood Supply



- dorsal scapular artery runs deep to rhomboids and levator 1 to 2 cm medial to scapula

- Bursae



- Anatomic
 - infraserratus
 - supraserratus
- Adventitial (pathologic)
 - near superior or inferior angles
 - inconsistently identified

• Presentation

- History
 - presentation ranges from mild discomfort to significant disability
 - trauma and overuse have both been reported
- Symptoms
 - patient complains of "popping" of scapula
 - painful crepitus with elevation of arm
 - pain relieved with stabilization of scapula
- Physical exam
 - fixed or postural kyphosis may be present
 - tenderness or fullness of symptomatic bursa
 - ask patient to demonstrate symptomatic motions
 - passive scapulothoracic motion by examiner may also reproduce crepitus
 - scapulothoracic dyskinesia may be present
 - evaluate for winging
 - test muscle strength
 - trapezius
 - serratus
 - rhomboids
 - levator
 - latissimus

• Imaging

- Radiographs
 - recommended
 - AP, lateral and axillary
 - findings
 - look for osseous abnormalities
- CT scan
 - indications
 - osseous lesion on plain radiographs
- MRI
 - indications
 - soft tissue masses
 - inflamed bursae

• Studies

- Diagnostic injections
 - selective injection of local anesthetic and/or corticosteroid to point of maximal tenderness can be diagnostic and therapeutic

• Differential

- Cervical pathology
 - can be referred to shoulder girdle

• Treatment

- Nonoperative
 - **NSAIDs, scapular strengthening exercises, postural training, activity modification**
 - indications
 - first line of treatment
 - no mass or aggressive lesion
 - **local corticosteroid injections**
 - indications
 - second line of treatment
- Operative
 - **bursectomy (open or arthroscopic), resection of osseous lesion, resection of scapular border**
 - indications

- cases refractory to nonoperative treatment
- outcomes
 - improvement in symptoms reported with both open and arthroscopic
 - better results in patients who responded well to injection
 - incomplete resolution of symptoms common despite improvement
 - better results with addition of partial scapulectomy (vs bursectomy alone)

• Techniques

○ Open

- position
 - prone, extremity draped free
- approach
 - vertical incision over medial border of scapula, centered on symptomatic bursa
 - trapezius split in line with fibers
 - rhomboids and levator elevated subperiosteally
- technique
 - bursa excised
 - angle of scapula can be excised
 - detached muscles repaired through drill holes
- postoperative care
 - sling immediate post op
 - must protect repaired muscle attachments
 - immobilize x 4 weeks
 - active motion at 8 weeks
 - strengthening at 12 weeks
- pros and cons
 - pros: wide exposure
 - cons: morbid

○ Arthroscopic

- position
 - prone, extremity draped free, arm in maximum internal rotation with hand over lumbar spine
- approach
 - portals: 3 cm medial to medial border of scapula (avoids dorsal scapular nerve and vessels) and below scapular spine (avoids spinal accessory nerve)
 - superior (Bell's) portal: junction of medial one third and lateral two thirds of superior border of scapula
 - trochar as parallel to chest wall as possible
- technique
 - skeletonize superomedial angle with cautery
 - resect superomedial angle if desired using burr
 - can place spinal needle at superior scapular border to mark lateral limit of resection
- postoperative care
 - sling immediate post op used for comfort x 1 week
 - active motion and strengthening based on tolerance
- pros and cons
 - pros: no muscle detachment
 - cons: technically demanding

• Complications

○ Neurovascular injury

- suprascapular nerve and vessels
- dorsal scapular nerve and vessels
- spinal accessory nerve

○ Chest wall penetration

- pneumothorax

62- Deltoid Rupture

• Summary

- Deltoid ruptures are very rare injuries that generally occur secondary to massive rotator cuff tears, repeated corticosteroid injections into the deltoid, or acute trauma.
- Diagnosis is made clinically with depression over the deltoid in acute ruptures with deltoid strains and partial ruptures presenting with localized tenderness and ecchymosis.
- Treatment of partial tears is rest, NSAIDs and observation. Early surgical repair is indicated for complete tears.

• Epidemiology

- Incidence
 - rare
- Risk factors
 - repeated corticosteroid injections about the shoulder
 - rotator cuff tear
 - trauma

• Etiology

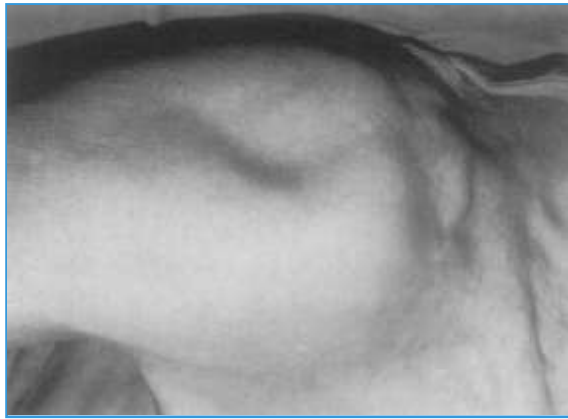
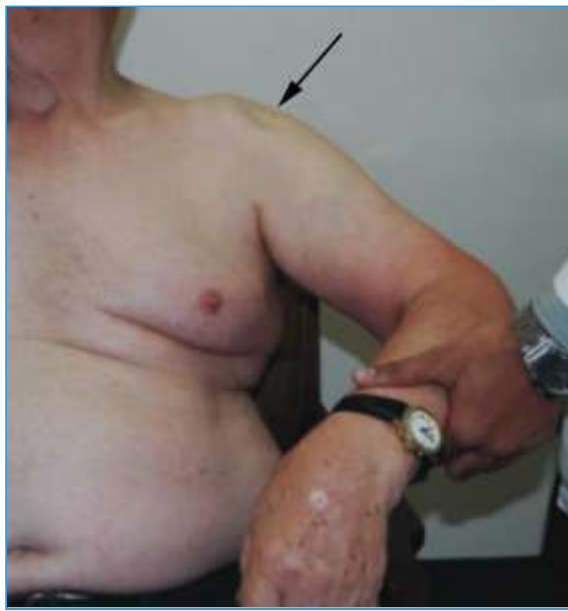- Pathophysiology
 - mechanism
 - secondary to repeated corticosteroid injections about the shoulder
 - massive rotator cuff tear
 - proximal migration of the humeral head leads to compression/abrasion of undersurface of deltoid by greater tuberosity
 - iatrogenic injury
 - during open rotator cuff repair
 - trauma
 - sudden deltoid contracture
 - shoulder contusion
- Associated conditions
 - rotator cuff tear

• Anatomy

- Deltoid anatomy

• Presentation

- Symptoms
 - shoulder pain
- Physical exam
 - inspection
 - depression over deltoid



- soft tissue mass distal to depression (contracted muscle)

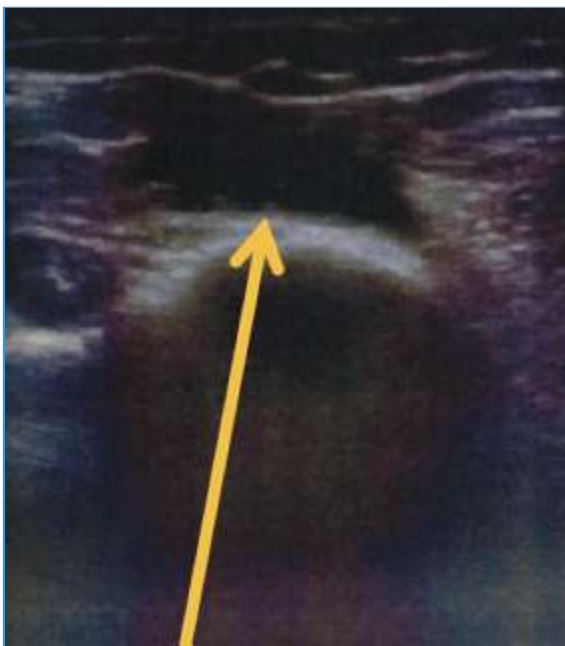• Imaging

○ Radiographs

- recommended views
 - shoulder radiographs
- findings
 - associated with cuff tear arthropathy
 - proximal humeral head migration

○ Ultrasound

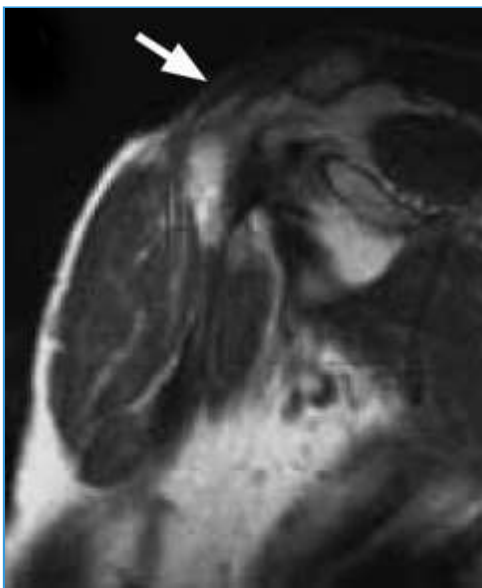
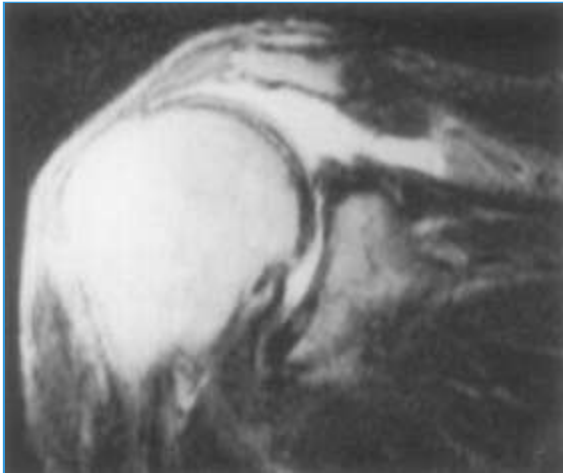
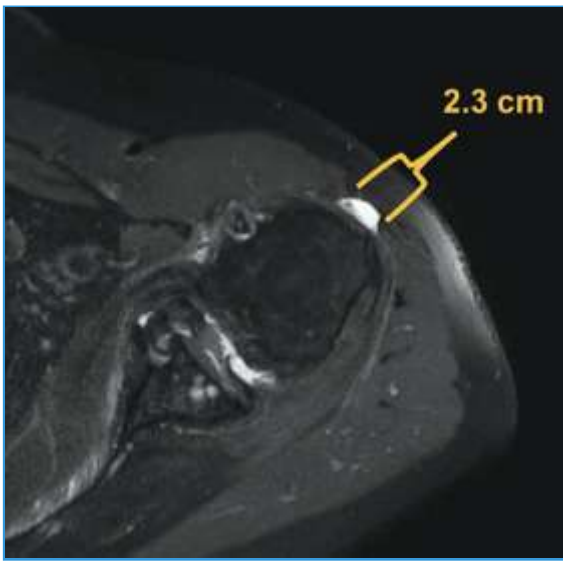
- indications
 - noninvasive method of detection
- findings



- shows deltoid gap with intact surrounding fibers

○ MRI

- indications
 - differentiate partial vs complete deltoid tears
 - associated rotator cuff pathology
- findings



- deltoid defect
- associated rotator cuff tear

• Treatment

- Nonoperative
 - **observation only**
 - indications
 - chronic injuries in elderly patients
- Operative
 - **early surgical repair**
 - indications
 - complete rupture
 - **deltoplasty with mobilization and anterior transfer of the middle third of the deltoid**
 - indications
 - iatrogenic injury during rotator cuff repair

63- Latissimus Dorsi Rupture

• Summary

- Latissimus dorsi rupture is a very rare condition that has been reported as a cause of pain in the thrower's shoulder.
- Diagnosis is suspected with pain over the latissimus dorsi made worse with shoulder adduction/internal rotation and confirmed with an MRI.
- Treatment is nonoperative for the majority of patients. Surgery is indicated in competitive athletes with completed tears.

• Epidemiology

- Incidence
 - very rare condition

• Etiology

- Mechanism
 - felt to be eccentric overload during the follow-through of the throwing motion

• Anatomy

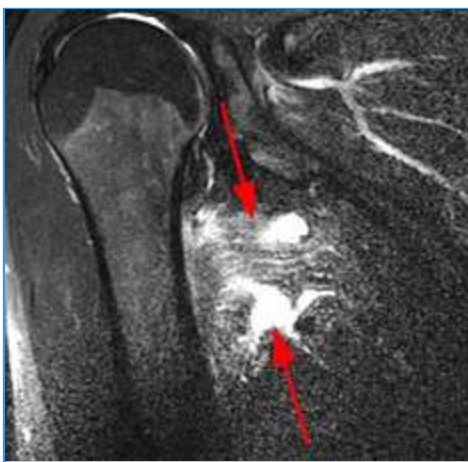
- Latissimus dorsi muscle

• Presentation

- Physical exam
 - local tenderness and deformity over latissimus dorsi muscles
 - pain with shoulder adduction and internal rotation

• Imaging

- MRI
 - shows increased T2 signal and retraction of latissimus dorsi muscle



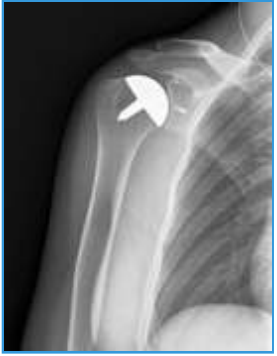• Treatment

- Nonoperative
 - **short period of rest followed by PT**
 - indications
 - allow resumption of activities in low demand patients
 - technique
 - physical therapy goals are to restore shoulder motion and strength
 - throwing can be allowed
 - after full, pain-free motion and good strength
 - balance of the rotator cuff and scapular rotator muscles
- Operative
 - **primary repair vs reconstruction**
 - indications
 - for high demand athletes (currently there are no defined indications for surgical repair)
 - technique

- early primary repair is favored to prevent retraction and scarring

64- Shoulder Resurfacing

Images



• Prosthetic Resurfacing

- Definition
 - humeral head arthroplasty with a non-stemmed, metal prosthesis
 - may or may not be mated with glenoid prosthesis or biologic resurfacing
- Advantages over conventional stemmed prosthesis
 - no osteotomy is needed
 - no change in anatomic offset or version
 - improved restoration of normal biomechanics
 - minimal bone resection
 - shorter operative time
 - low prevalence of humeral periprosthetic fracture
 - easy revision to conventional arthroplasty if needed
- Indications
 - cases in which the humerus anatomy is abnormal, causing:
 - difficulty with dislocation
 - difficulty with stem insertion
 - examples
 - humeral dysplasia
 - developmental
 - secondary
 - Apert's disease
 - epiphyseal dysplasias
 - chronic Erb's palsy
 - prior humerus fracture
 - proximal, metaphyseal, or diaphyseal malunion
 - hardware in place which blocks stem implantation
- Outcomes
 - has demonstrated success in pain relief
 - does not reliably improve motion
 - at one year, considered inferior to outcomes of traditional stemmed prostheses
- Complications
 - implant loosening is most common

• Biologic Resurfacing

- Also known as interpositional allografting
- Concept of putting soft tissue in glenoid to reduce symptoms and obviate need for TSA
- Frequently combined with hemiarthroplasty of the humerus or humeral prosthetic resurfacing
- Indications
 - young patients
 - rotator cuff arthropathy
 - GH narrowing following hemiarthroplasty
 - GH arthritis following arthroscopic stabilization procedures
- Interpositional allografts include
 - fascia lata

- meniscal allograft
- achilles allograft
- acellular dermal matrix
- Outcomes
 - short-term outcomes (2-year)
 - improvement:
 - VAS pain score
 - ASES score
 - questionable improvement:
 - active forward elevation
 - active external rotation
 - active internal rotation
 - long-term outcomes
 - the rate of failure by 36-months has been reported at 44%
- Complications
 - difficulty converting to TSA due to scarring within the glenohumeral joint

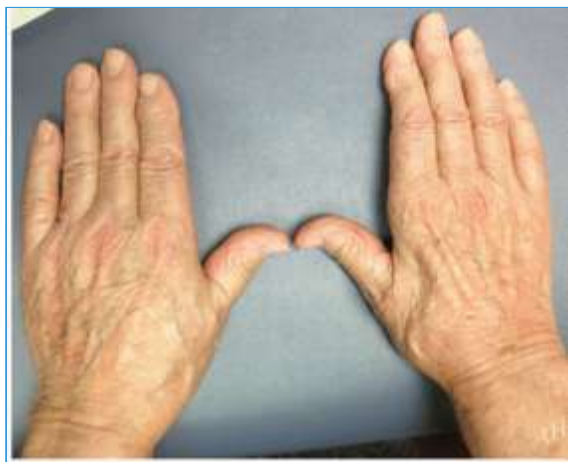65- Elbow Physical Exam

- Introduction

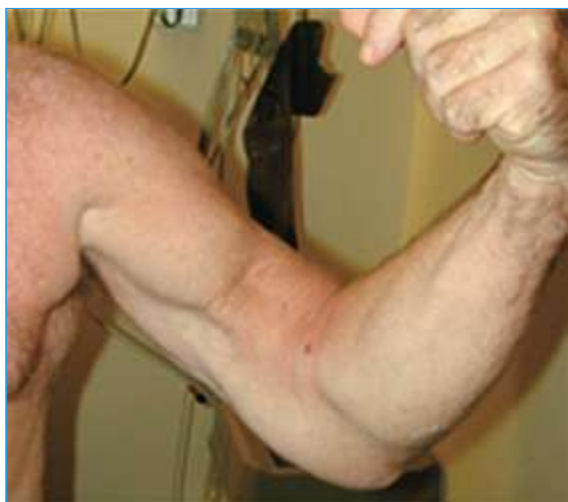- Steps to physical exam
 - Inspection
 - Palpation
 - Range of Motion
 - Stability
 - Motor
 - Sensory
 - Vascular
 - Provocative tests

- Inspection

- Skin
- Swelling
 - patients with elbow effusion will generally hold elbow flexed at 70-80 degrees flexion at rest
 - position of maximal elbow capsular distension
 - fullness of the elbow soft spot (confluence of the radial head, lateral epicondyle and olecranon)
- Hypertrophy
- Elbow carrying angle
 - in full extension, normal carrying angle is ~11 degrees in men and ~13 degrees in women
 - will be higher in the throwing athlete
- Olecranon bursitis
- Clinical pearls
 - cubital tunnel syndrome
 - 1st dorsal interossei/1st webspace atrophy



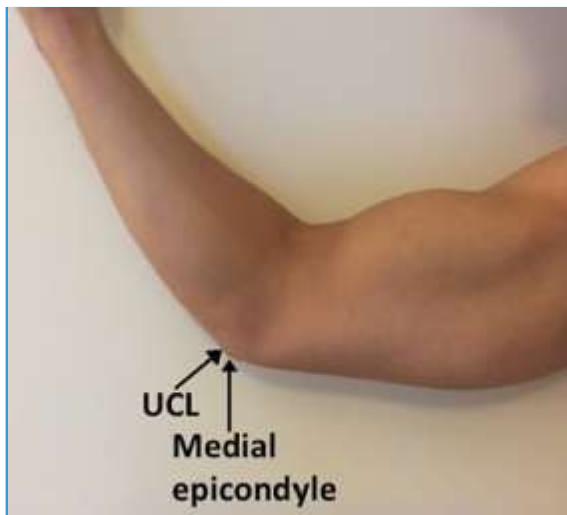
- clawing of small and ring finger
 - more commonly seen with Guyon's canal compression due to unopposed FDP flexion
- distal biceps tendon rupture
 - medial ecchymosis and swelling
 - change in contour of muscle, proximally
 - varying degree of proximal retraction of the muscle belly



- “reverse Popeye sign”

• Palpation

- Bony prominences
 - olecranon
 - medial epicondyle
 - lateral epicondyle
 - radial head
 - best palpated while rotating forearm from pronation to supination
- Muscles and soft tissues including
 - flexor-pronator mass
 - extensor mass origin
 - olecranon bursa
 - MCL insertion
 - palpated just distal to medial epicondyle with elbow in 50-70 degree flexion to move flexor-pronator mass anterior
 - LCL insertion
- Clinical pearls
 - MCL injuries
 - tenderness over MCL origin (just inferior to medial epicondyle)
 - best assessed with elbow at 50-70 degrees in flexion to move the flexor pronator mass anterior to MCL



- Valgus extension overload
 - tender to palpation over posteromedial olecranon
- Cubital tunnel syndrome
 - subluxation of ulnar nerve over medial epicondyle with elbow coming from extension to flexion
 - this hypermobility occurs in 33% of adults and is not necessarily associated with cubital tunnel syndrome
 - important to differentiate from snapping medial head of triceps over medial epicondyle (which occurs in resisted elbow extension from a fully flexed elbow)
- Radial tunnel syndrome
 - maximal tenderness is 3-5cm distal to lateral epicondyle
 - more distal than lateral epicondylitis
- Lateral epicondylitis
 - point tenderness at ECRB insertion into lateral epicondyle
 - few mm distal to tip of lateral epicondyle
 - unlike radial tunnel syndrome which exhibits tenderness 3-5 cm distal to epicondyle
- Medial epicondylitis
 - tenderness 5-10 mm distal and anterior to medial epicondyle
 - soft tissue swelling and warmth if inflammation present

• Range of Motion

- Check passive and active motion of both sides
- Check for crepitus and mechanical blocks
- Flexion-extension
 - normal: 0-140
 - loss of full extension can be seen in professional throwers even in absence of pathology
 - functional: 30-130
 - soft end point indicates effusion or capsular tightness
 - firm end point indicates mechanical block (loose body, fracture, osteophyte)
- Pronation-supination

- check with shoulders fully adducted and elbow at 90 degrees
- normal pronation: 75
- normal supination 85
- functional: 50 pronation, 50 supination

• Stability

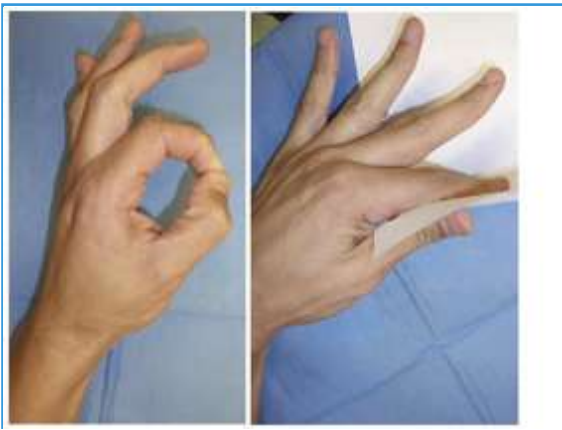- Varus Stability
- Valgus Stability
 - flex elbow to 20 to 30 degrees (unlocks the olecranon), externally rotate the humerus, and apply valgus stress
 - tests integrity of MCL

• Motor Strength

- Elbow Flexion
 - in full supination
 - primary brachialis and biceps (C5 and C6)
 - in neutral rotation (thumb pointing to ceiling)
 - primarily brachioradialis (C6)
- Elbow Extension
 - triceps (C7)
- Wrist Pronation
 - flexor-pronator mass (C7, C8)
- Wrist Supination
 - primarily biceps (C6)
- Wrist Extension
 - ECRL, ECRB, ECU (C6-C8)
- Wrist Flexion
 - FCR, FCU (C6-C8)
- Finger and thumb extension
 - EDC, EPL (C7, C8)
- Finger and thumb flexion
 - FDS, FDP, FPL (C7, C8)
- All small intrinsic movements of hand
 - Lumbricals, interossei (T1)
- Clinical pearls
 - cubital tunnel syndrome
 - weak pinch
 - from loss of thumb adduction (as much as 70% of pinch strength is lost)
 - Froment sign



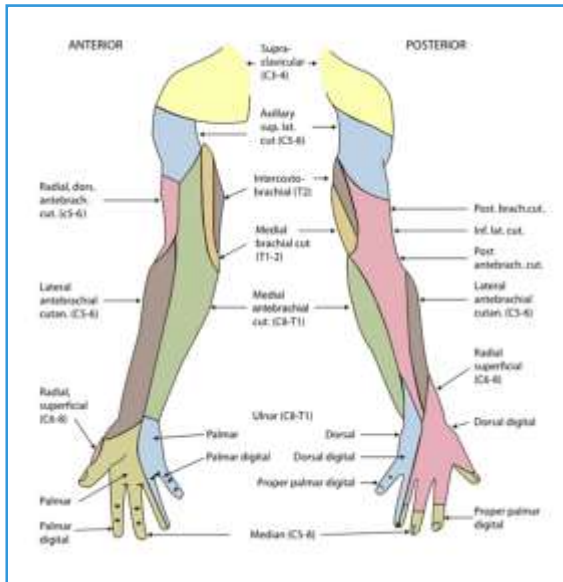
- compensatory thumb IP flexion by FPL (AIN) during key pinch
 - compensates for the loss of MCP flexion by adductor pollicis (ulna n.)
- PIN syndrome
 - finger metacarpal extension weakness
 - wrist extension weakness
 - inability to extend wrist in neutral or ulnar deviation
 - the wrist will extend with radial deviation due to intact ECRL (radial n.) and absent ECU (PIN)
- AIN syndrome
 - positive OK sign (test FDP and FPL)



- patient unable to make OK sign
- pronator quadratus weakness
 - shown with weak resisted pronation with elbow maximally flexed

• Sensory

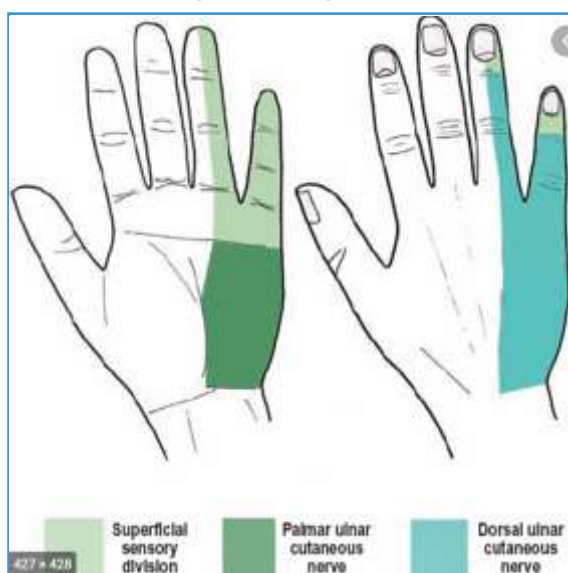
○ Sensation



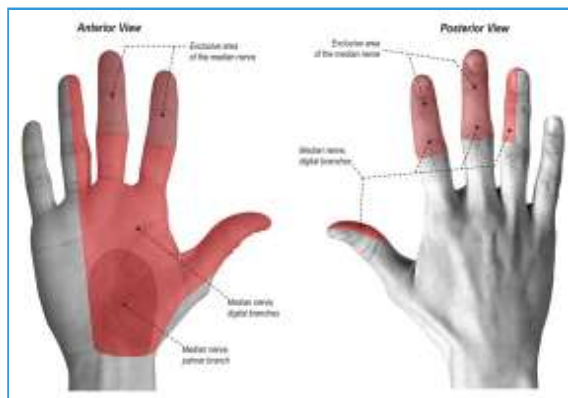
- medial antebrachial cutaneous
- lateral antebrachial cutaneous
- posterior antebrachial cutaneous
- ulnar
- median
- superficial radial

○ Clinical pearls

- cubital tunnel syndrome
 - decreased 2-point discrimination over small finger and ulnar half of ring finger
 - decreased 2-point discrimination over ulnar aspect of dorsal hand may discriminate cubital tunnel from more distal entrapment (dorsal branch of ulnar nerve branches 5 cm proximal to wrist)



- pronator syndrome
 - sensory disturbances over the distribution of palmar cutaneous branch of the median nerve which arises 4 to 5 cm proximal to carpal tunnel



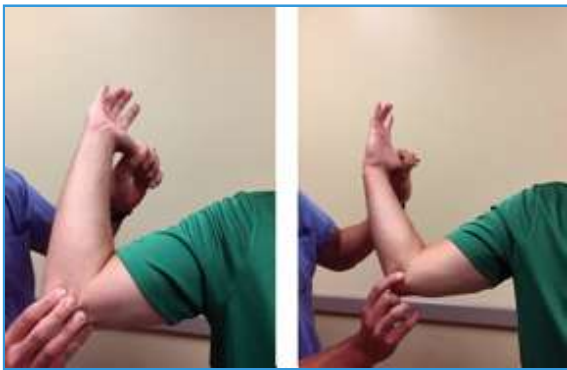- unlike in carpal tunnel syndrome which does not exhibit sensory disturbances over palmar cutaneous nerve distribution

• Vascular

- Brachial artery
 - palpable on the anterior aspect of the elbow, medial to the tendon of the biceps
- Radial artery
- Ulnar artery

• Provocative Tests - Stability

- MCL injuries
 - milking maneuver

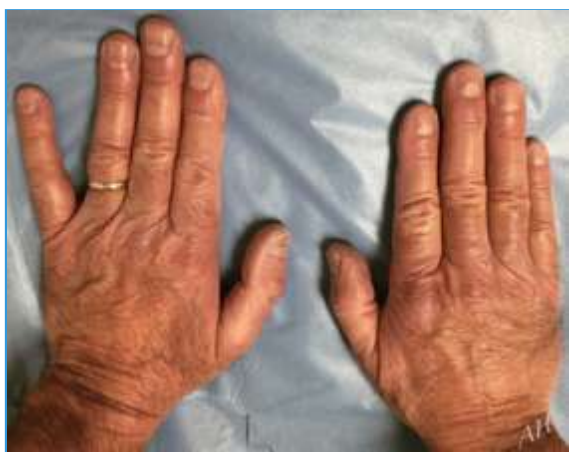

- creates valgus stress by pulling on the patient's thumb with the forearm supinated and elbow flexed at 90 degrees
- patient may be supine or seated/standing
- positive test is a subjective apprehension, instability, or pain at the MCL origin
- 87.5% sensitive with a negative predictive value of 100%
- moving valgus stress test
 - place elbow in same position as the "milking maneuver" and apply a valgus stress while the elbow is ranged through the full arc of flexion and extension
 - shoulder should be fully externally rotated during entire test
 - positive test is a subjective apprehension, instability, or pain at the MCL origin between 70 and 120 degrees
 - correlates in throwers to location of early acceleration (70 degrees flexion), and location of late cocking (120 degrees flexion)
 - 100% sensitive and 75% specific
- LCL injuries
 - lateral pivot-shift test
 - patient lies supine with affected arm overhead; with shoulder fully externally rotated, forearm is supinated and valgus stress is applied while bringing the elbow from full extension to flexion
 - at 40 degrees flexion, patient may feel pain and apprehension
 - clunk appreciated at 40 degrees represents dislocated radiocapitellar joint
 - with increased flexion, triceps tension reduces the radial head and another clunk may be appreciated
 - often more reliable on anesthetized patient
 - posterolateral rotatory drawer test
 - with patient supine and elbow flexed to 40 degrees, forearm is supinated and the examiner's index finger is placed under the radial head and the thumb over it.
 - application of an anterior-to-posterior force if performed over the lateral proximal forearm
 - positive test is indicated by apprehension or presence of a skin dimple (indicating posterior subluxation of radial head)
 - chair push-up test
 - sitting on a chair, patient attempts to perform a pushup while holding on to handles with forearm supinated
 - inability to do pushup or apprehension indicates a positive test.
 - 87.5% sensitivity (100% when combined with prone push-up test)

- table-top relocation test
 - 3-part test
 - 1st part: patient places hand of symptomatic elbow around edge of table and is asked to perform press-up maneuver with elbow pointing laterally and forearm supinated
 - pain and apprehension as elbow is gradually flexed indicates a positive test
 - 2nd part: same maneuver as 1st part but examiner places thumb over patient's radial head during the maneuver
 - relief of pain and apprehension indicates a positive test (as examiner's thumb should be preventing radial head subluxation)
 - 3rd part: same as 1st part without examiner's thumb
 - pain and apprehension during 1st and 3rd part with relief during 2nd part indicate posterolateral instability
 - with an intra-articular radial head fracture, pain would be present in all 3 parts.
 - prone push-up test
 - patient unable to perform push-ups with forearm supinated
 - 87.5% sensitivity (100% when combined with chair push-up test)
- Valgus extension overload
 - pain with forced elbow extension
 - valgus loading during terminal extension reproduces pain
 - varus loading reduces pain

• Provocative Tests - Nerve

- Cubital tunnel syndrome
 - Jeanne sign
 - compensatory thumb MCP hyperextension and thumb adduction by EPL (radial n.) with key pinch
 - compensates for loss of IP extension and thumb adduction by adductor pollicis (ulna n.)
 - Wartenberg sign

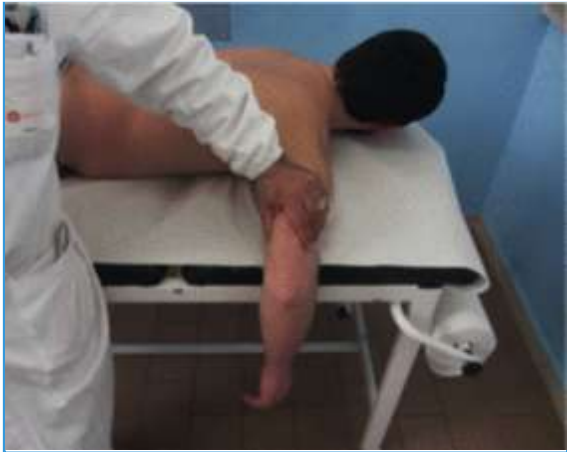

- persistent small finger abduction and extension during attempted adduction secondary to weak intrinsics and unopposed action of EDM
- Masse sign
 - palmar arch flattening and loss of ulnar hand elevation secondary to weak opponens digiti quinti and decreased small finger MCP flexion
- Tinel sign positive over cubital tunnel with elbow extended
- elbow flexion test
 - positive when flexion of the elbow for > 60 seconds reproduces symptoms
- Radial tunnel syndrome
 - resisted long finger extension test
 - reproduces pain at radial tunnel (weakness because of pain)
 - resisted supination test (with elbow and wrist in extension)
 - reproduces pain at radial tunnel (weakness because of pain)
 - passive pronation with wrist flexion
 - reproduces pain at radial tunnel
 - passive stretch of supinator muscle increases pressure inside radial tunnel to 250mmHg (normal 50mmHg)
- PIN syndrome
 - resisted supination
 - will increase pain symptoms
 - normal tenodesis test
 - tenodesis test is used to differentiate from extensor tendon rupture
- Pronator syndrome
 - positive Tinel sign in the proximal anterior forearm but no Tinel sign at wrist

- provocative symptoms with wrist flexion as would be seen in CTS
- tests for specific sites of entrapment
 - resisted elbow flexion with forearm supination (compression at bicipital aponeurosis)
 - resisted forearm pronation with elbow extended (compression at two heads of pronator teres)
 - resisted contraction of FDS to middle finger (compression at FDS fibrous arch)
- AIN syndrome
 - distinguish from FPL attritional rupture (seen in rheumatoid) by passively flexing and extending wrist to confirm tenodesis effect in intact tendon
 - if tendons intact, passive wrist extension brings thumb IP joint and index finger DIP joint into relatively flexed position

• Provocative Tests - Tendon

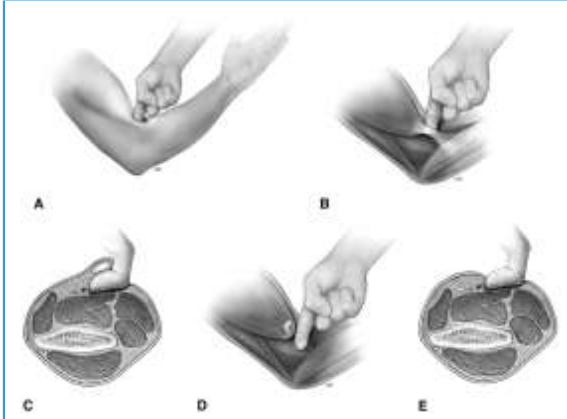
- Triceps tendon rupture
 - modified Thompson squeeze test



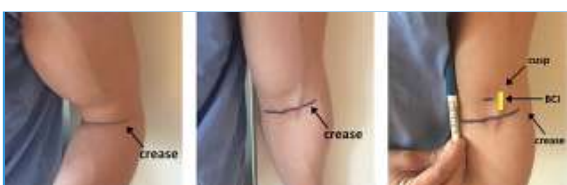- patient lies prone with the elbow at the end of the table and forearm hanging down
- triceps muscle is firmly squeezed
- inability to extend the elbow against gravity suggests complete disruption of triceps proper and lateral expansion

- Distal biceps tendon rupture

- Hook test



- performed by asking the patient to actively flex the elbow to 90° and to fully supinate the forearm
- examiner then uses index finger to hook the lateral edge of the biceps tendon.
 - with an intact / partially torn tendon, finger can be inserted 1 cm beneath the tendon
- false positive
 - partial tear
 - intact lacertus fibrosis
 - underlying brachialis tendon
- sensitivity and specificity 100%
- Ruland biceps squeeze test (akin to the Thompson/Simmonds test for Achilles rupture)
 - elbow held in 60-80° of flexion with the forearm slightly pronated.
 - one hand stabilizes the elbow while the other hand squeezes across the distal biceps muscle belly.
 - a positive test is failure to observe supination of the patient's forearm or wrist.
 - sensitivity 96%
- biceps crease interval (BCI)



- measurement of the distance between palpable and anatomic biceps insertion
- patient elbow is brought from flexion to extension with forearm supinated and main crease in antecubital fossa is marked (crease)

- next, location of where distal biceps tendon turns most sharply toward antecubital fossa is marked (cusp)
- the distance between the crease and the cusp is the BCI
 - values > 6 cm or 1.2x the value of contralateral arm are positive for biceps tendon rupture
 - 92% sensitivity, 100% specificity
- passive forearm pronation test
 - observation that the biceps muscle belly moves proximally with forearm supination and distally with forearm pronation (actively and passively)
 - performing the hook test, passive forearm pronation test and BCI test in sequence results in 100% sensitivity and 100% specificity for complete biceps tendon rupture
 - loss of more supination than flexion strength
- Lateral epicondylitis
 - the following maneuvers exacerbate pain at lateral epicondyle
 - resisted wrist extension with elbow fully extended and pronated
 - resisted extension of the middle finger (Maudsley Test)
 - selectively recruits fibers of the ECRB
 - maximal flexion of the wrist
 - passive wrist flexion in pronation causes pain at the elbow
 - chair Test
 - with elbow fully extended, forearm pronated and shoulder forward flexed, patient is asked to lift a chair
 - lateral elbow pain is positive for lateral epicondylitis.
- Medial epicondylitis
 - pain with resisted forearm pronation and wrist flexion
 - no instability or apprehension with valgus stress or milking maneuver
 - used to differentiate from MCL injuries.

66- Humeral Avulsion Glenohumeral Ligament Hagl

• Summary

- Humeral Avulsion of the Glenohumeral Ligament (HAGL) is an injury to the inferior glenohumeral ligament causing instability and/or pain and a missed cause of recurrent shoulder instability.
- Diagnosis requires suspicions of injury and can be noted as an inferior pouch irregularity on MRI.
- Non-operative first-line treatment for acute presentation includes sling immobilization and physical therapy while operative treatment is recommended for recurrent instability.

• Epidemiology

- Incidence
 - 1.6% of patients with shoulder pain
- Demographics
 - male > female (94% male)
 - average age 25-30
- Anatomic location
 - anterior band most common (93%)
 - medial (glenoid) versus lateral (humerus)
 - failure IGHL at labral complex - 40%
 - intrasubstance tear - 35 %
 - humeral insertion - 25%
- Risk factors
 - 10% of recurrent anterior shoulder dislocators have HAGL
 - 27% of shoulder instability patients without bankart have HAGL
 - 18% of failed anterior stabilization have HAGL

• Etiology

- Pathophysiology
 - mechanism of injury
 - hyperabduction and external rotation is the main mechanism
 - diving, Football, Basketball, Volleyball, Surfing, skiing, MVC
- Associated conditions
 - orthopedic conditions
 - labral tears - 25%
 - rotator Cuff tears - 23%
 - Hill-Sachs Deformity - 17%
 - bony Bankart

• Anatomy

- Static stabilizers
 - glenohumeral ligaments
 - glenoid labrum
 - attachment of glenohumeral ligaments
 - deepens glenoid cavity
 - articular congruity and version
 - negative intraarticular pressure
- Dynamic stabilizers
 - rotator cuff muscles
 - the primary biomechanical role of the rotator cuff is stabilizing the glenohumeral joint by compressing the humeral head against the glenoid
 - rotator interval
 - biceps long head
 - periscapular muscles
 - deltoid

- Capsuloligamentous Complex
 - coracohumeral Ligament
 - superior glenohumeral ligament (SGHL)
 - middle glenohumeral ligament (MGHL)
 - inferior glenohumeral ligament (IGHL)
 - hammock-like Structure
 - anterior band - between 2 and 4 o'clock
 - posterior Band - between 7 and 9 o'clock
 - axillary pouch
 - 2 types of Insertion on Humerus
 - collar like attachment close to articular margin
 - V-shaped attachment close to cartilage rim with apex distal on metaphysis
- Blood Supply
 - anastomosis of branches of humeral sided and scapular sided vessels
 - lateral: Anterior humeral circumflex artery, Posterior humeral circumflex artery
 - medial: Suprascapular artery, Circumflex scapular arteries
 - watershed area anterolaterally: near humeral insertion anterior capsule 3 cm medial to intertubercular groove
- Nervous system
 - axillary nerve
 - close to HAGL lesion at 6 o'clock position (2-7mm, overestimated on MRI by 2mm)
- Biomechanics
 - most taught between 45 - 90 degrees abduction
 - anterior band of IGHL - anterior and inferior restraint
 - taught at 90 degrees abduction and external rotation
 - posterior band of IGHL- posterior and inferior restraint
 - taught at 90 degrees abduction and internal rotation

• Classification

- West Point Classification - by Bui-Mansfield

West Point Classification		
	<ul style="list-style-type: none"> ▪ Based on 3 Factors: ▪ Anterior or Posterior Involvement ▪ Presence or Absence of Bony Avulsion ▪ Presence of Associated Labral Pathology (Floating) 	
Anterior		93%
	Anterior HAGL	55%
	Anterior Bony HAGL	17%
	Floating AIGHL	21%
Posterior		6%
	Posterior HAGL	2%
	Posterior Bony HAGL	0%
	Floating PIGHL	4%

• Presentation

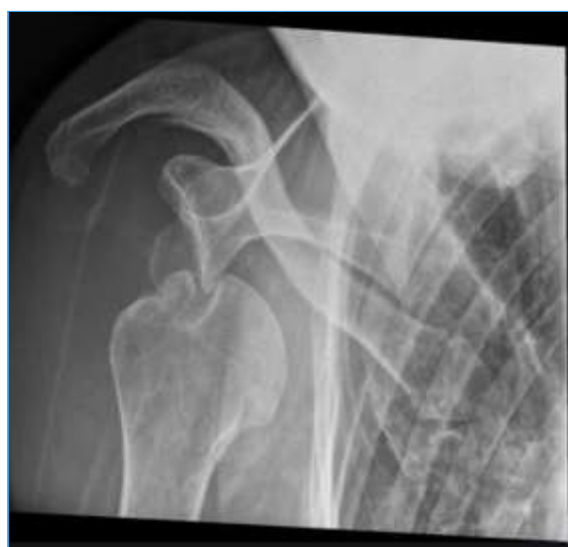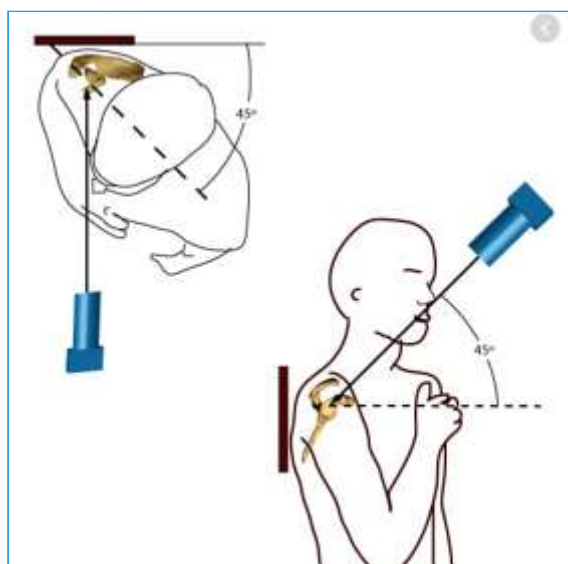
- History
 - position of arm at injury
 - direction of instability
 - recurrent instability
 - failed surgery to correct instability
- Symptoms
 - severe persistent pain after instability event
 - recurrent instability
- Physical exam
 - provocative tests
 - apprehension and relocation tests
 - load and shift
 - posterior stress and posterior jerk tests

- sulcus sign in neutral and external rotation
- Neurovascular
 - check axillary nerve function

• Imaging

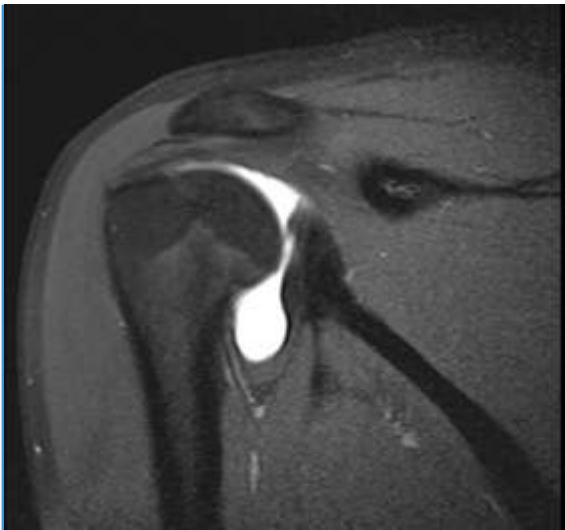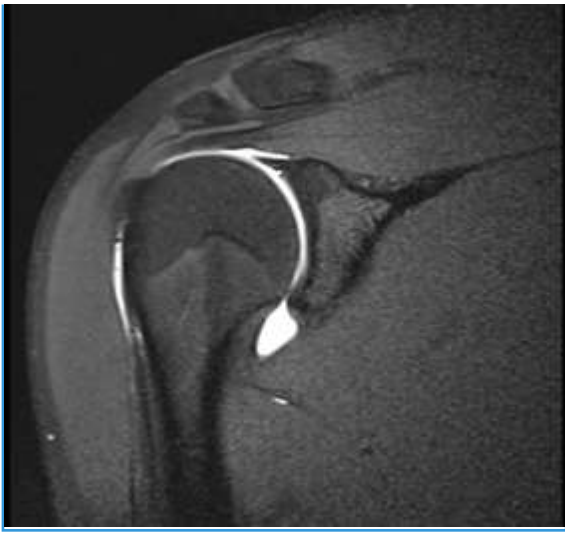○ Radiographs

- recommended views
 - true AP radiographs in neutral and internal rotation
 - scapular Y
 - axillary lateral
- findings
 - glenoid rim fractures, hypoplasia, fractures of humeral head
- optional views
 - Garth View

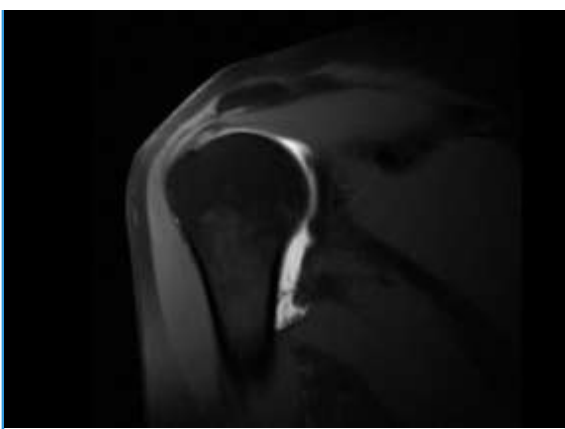
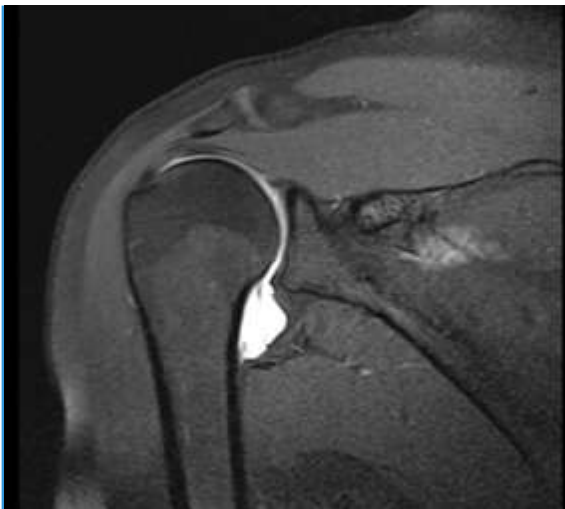


- 45-degree oblique radiograph in anterior plane
- fleck of bone inferior to anatomic neck - avulsion of medial cortex
- arthrogram
 - normally dye appears in axillary pouch, biceps sheath, subcoracoid recess
 - HAGL - dye escapes inferiorly in crescent shape
- CT
 - indications
 - lower utility than MRI
 - consider combination with arthrogram for contraindication to MRI
 - views
 - best seen on sagittal
 - findings
 - Oberlander described bony HAGL lesion posterior to MGHL
- MRI
 - indications
 - gold standard for diagnosis of HAGL
 - recurrent instability or persistent pain after instability event
 - MR Arthrogram if more than 7 - 10 days from injury
 - views
 - coronal oblique T2 weighted fat suppressed MRI
 - sagittal oblique T2 weighted fat suppressed MRI
 - findings:

- J Sign
 - pathognomonic for HAGL
 - inferior pouch normally appears U - Shaped



- HAGL has appearance of J - Shaped inferior pouch



- dye may leak through tear inferiorly
- chronic lesions may be difficult to see due to scar of IGHL to capsule

• Differential

- Anterior Bankart Tear/ Anterior Inferior Labrum tear
- Posterior Bankart/ Posterior Inferior Labrum tear

• Treatment

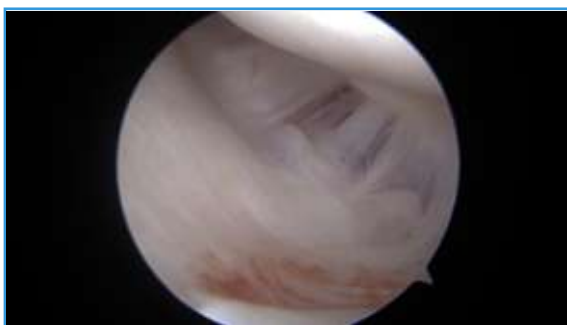
- Nonoperative
 - **sling immobilization and physical therapy**
 - indications
 - first-line treatment when no instability present
 - outcomes
 - 90% recurrence rate of instability with non-operative treatment

- Operative
 - **open HAGL repair**
 - indications
 - young person with primary shoulder dislocation, high recurrence rate
 - associated injuries
 - failed non-operative management
 - recurrent instability
 - persistent pain or instability after missed HAGL with Bankart repair
 - techniques
 - open anterior repair
 - indications
 - anterior HAGL
 - open posterior repair
 - indications
 - posterior HAGL
 - prognosis
 - low incidence of post-operative instability following open repair
 - no reported difference between open and arthroscopic repair
 - **arthroscopic HAGL repair**
 - indications
 - same as open repair
 - techniques
 - anterior arthroscopic repair
 - Indications
 - anterior HAGL
 - less soft tissue dissection compared to open
 - less damage to subscapularis compared to open
 - posterior arthroscopic repair
 - Indications
 - posterior HAGL
 - avoid splitting rotator cuff muscles
 - prognosis
 - no reported difference between open and arthroscopic repair

• Techniques

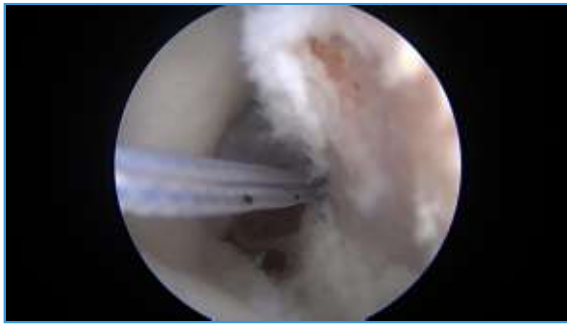- **Sling immobilization and physical therapy**
 - Technique
 - 4 week sling immobilization
 - shoulder strengthening following sling immobilization period
- **Open Anterior Repair**
 - advantages
 - visualization of neurovascular structures
 - less technically difficult
 - approach
 - deltopectoral approach
 - 3 subscapularis approaches
 - subscapularis tendon released leaving a 1cm cuff
 - subscapularis sparing technique described by Arciero and Mazzoca
 - L-shaped incision lower one third subscapularis tendon
 - subscapularis sparing technique by Bhatia
 - lower border subscapularis identified by anterior humeral circumflex
 - pectoralis major tendon retracted inferiorly
 - retract subscapularis superiorly
 - subscapularis is usually scarred inferiorly with a HAGL
 - technique
 - bone preparation
 - Medial humeral neck is rasped to remove scar tissue at 6 to 8 o'clock
 - instrumentation

- suture anchor placed in inferior humerus necks
- sutures pulled through anterior-inferior capsule
- complications specific to this treatment
 - axillary nerve entrapment
 - use caution, nerve is within 3mm of inferior capsule
- rehabilitation
 - anterior HAGL Protocol
 - 0 - 4 weeks
 - Sling
 - Passive forward flexion to 90 degrees, external rotation to 30 degrees with arm at the side
 - 4 - 10 weeks
 - Assisted active forward flexion to 140 degrees
 - External rotation to 40 degrees with arm at side
 - 10 - 12 weeks
 - External rotation permitted with 45 degrees of abduction
- **Open Posterior Repair**
 - approach
 - Judet approach
 - deltoid bluntly spread in line with fibers
 - interval between infraspinatus and teres minor utilized
 - technique
 - bone work
 - Roughen bone inferiorly on humeral neck to create bleeding surface
 - instrumentation
 - Place suture anchors in inferior humeral neck
 - rehabilitation
 - posterior HAGL Protocol
 - 0 - 6 weeks
 - Passive abduction to 45 degrees, forward flexion to 45 degrees, external rotation to 30 degrees
 - Internal rotation limited to arm against belly
 - 6 weeks - 12 weeks
 - No internal rotation with the arm abducted more than 45 degrees
 - complications
 - Axillary nerve entrapment
 - use caution, nerve is within 3mm of inferior capsule
- **Anterior Arthroscopic Repair**
 - approach
 - 3 portal approach
 - anterior superior portal under biceps
 - anterior inferior portal above or below subscapularis
 - posterior portal

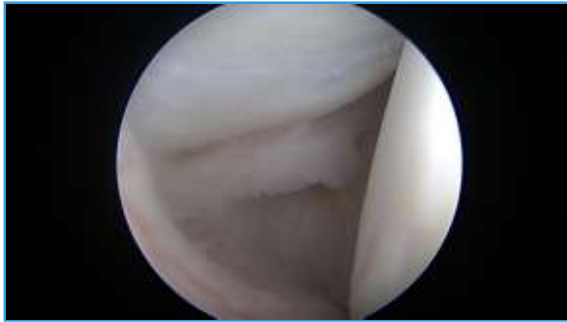

- accessory Portals
 - Anterior-inferior / 5 o'clock portal
 - 1 cm inferior to upper border subscapularis tendon
 - placed in neutral position to protect musculocutaneous nerve
 - 7 o'clock posterior-inferior portal - Davidson and Rivenburgh
 - 2 - 3 cm inferior to posterior viewing portal
 - Bhatia portal/ axillary pouch portal
 - 3 cm inferior to lower border of posterolateral acromial angle
 - 2 cm lateral to standard posterior portal
- technique
 - bone work

- humeral neck roughened with arthroscopic burr



- suture anchors placed at IGHL insertion on humeral neck
- soft tissue
 - suture passing device through 5 o'clock portal
 - horizontal mattress suture through capsular tissue to neck



- instrumentation
 - suture lasso, suture anchors with curved guide
 - wait until all sutures are passed to tie knots
- complications
 - axillary nerve damage
 - arthrofibrosis

○ **Posterior Arthroscopic Repair**

- approach
 - may Switch viewing portal from posterior to anterior using 30 degree scope
 - accessory inferior-lateral posterior portal
- technique
 - bone work
 - shaver and burr to posterior humeral neck
 - instrumentation
 - place 2 suture anchors into inferior humeral neck posteriorly
 - curved guide with all-suture anchor is helpful
 - soft tissue
 - use suture passer to pass sutures through posterior IGHL
 - repair IGHL to posterior humeral neck
 - tension sutures with arm externally rotated
 - repair IGHL 1st (before bankart) with combined injuries

• **Complications**

- Arthrofibrosis with Loss of External Rotation
 - Treatment
 - Physical Therapy for external rotation stretching
- Axillary Nerve Injury
 - Axillary nerve is 10 mm inferior to the glenoid and 2.5 mm inferior to capsule
- Chondrolysis
 - risk factors
 - reported with thermal capsulorrhaphy
 - overtightening anterior may be associated with accelerated posterior wear
- Pulmonary Embolism
 - Incidence
 - 0.6% with shoulder arthroscopy
- Recurrence of instability
 - Very Rare
 - Per systematic review: 0/25 operative, 9/10 nonoperative
 - Odds ratio 0.05 recurrence with operative vs nonoperative treatment (p=.006)

- Prognosis

- Good with adequate recognition and treatment

67- Shoulder Periprosthetic Fracture

• summary

- Shoulder Periprosthetic Fractures are intraoperative or postoperative complications associated with shoulder arthroplasty that can lead to loosening and migration of the prosthesis.
- Diagnosis can be made with plain radiographs of the shoulder and humerus. CT scan can help identify loosening of the prosthesis.
- Treatment involves ORIF or revision shoulder arthroplasty depending on location of the fracture and stability of the prosthesis.

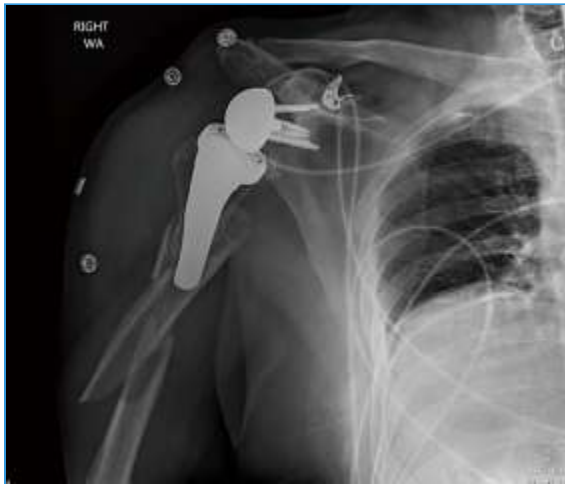• Epidemiology

- Incidence
 - 0.6-3% of patients with TSA
- Demographics
 - typically occurs in patients 50-85 years of age
- Timing of onset
 - most fractures often occur intraoperative at the time of the original implant
 - consists of 20% of all complications
- Anatomic location
 - adjacent to the prosthetic stem tip
 - greater tuberosity
 - most commonly occurs during revision total shoulder arthroplasty
- Risk factors
 - soft tissue contractures
 - osteoporosis
 - endosteal notching
 - aggressive reaming
 - incorrect entry reaming site
 - ideal entry reaming site is 9 mm lateral from anatomic center of rotation
 - use of press fit humeral stems
 - compared to cemented stems
 - revision arthroplasty cases
 - history of instability
 - female sex
 - post-traumatic arthritis
 - increased comorbidity index
 - osteonecrosis
 - corticosteroid-induced > alcohol and post-traumatic

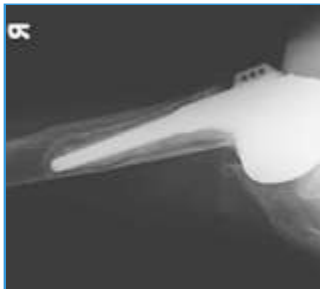• Etiology

- Pathophysiology
 - intraoperative fractures occur most often during revision total shoulder arthroplasty
 - greater exposure required during these procedures
 - increased scarring in the subacromial space and around the rotator cuff
 - increased soft-tissue retraction and greater torque placed on humerus
 - removing previous implant (up to 81% of intraoperative fractures)
 - metaphyseal filling implants -> increased risk of greater tuberosity fractures
 - bone loss from cement removal
 - bone loss from disengagement of the bone-implant interface
 - diaphyseal-engaging stems -> greater tuberosity fractures
 - stress shielding of the metaphysis
 - methods to prevent:
 - clearing soft-tissue from lateral portion of implant
 - use of implant specific removal instruments

- controlled corticotomy
- other mechanisms of intraoperative fractures:
 - reaming or broaching (up to 31% of intraoperative fracture)
 - implant trialing or insertion (up to 19% of cases)
 - during exposure (up to 15% of cases)
 - forceful retractor placement
- primary total shoulder arthroplasty has a lower risk for intraoperative fracture
 - factors associated with primary intraoperative fractures
 - endosteal notching from reaming
 - excessive humeral external rotation during exposure
 - cortical breaching during reaming or broaching
 - especially in osteopenic bone
- post-operative fractures can occur as a result of a fall or fatigue fracture through a stress riser
 - fall on outstretched hand
 - tip of prosthesis acts as a stress riser
 - most postoperative fractures as a result occur at or adjacent the tip of the prosthesis stem



- atraumatic due to prosthetic loosening
 - cortical weakening from implant "rattling" inside medullary canal



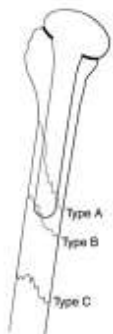

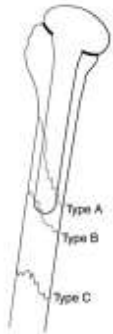

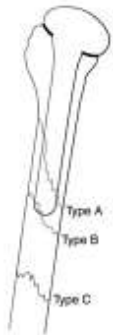

- high risk of nonunion
 - prosthesis disrupts endosteal blood supply impairing fracture revascularization and healing
 - prosthetic stem distracts the two fragments preventing end-to-end healing

○ Associated conditions

- nonunion
 - osteoporosis
 - RA
 - female sex
 - displacement >2 mm
 - presence of cement at fracture site

• Classification

- Wright and Cofield Classification

<ul style="list-style-type: none"> Type A 	<ul style="list-style-type: none"> Fracture centered near the tip of the stem and extends proximally 	<ul style="list-style-type: none">  
<ul style="list-style-type: none"> Type B 	<ul style="list-style-type: none"> Fracture centered near the tip of the stem and extends distally 	<ul style="list-style-type: none">  
<ul style="list-style-type: none"> Type C 	<ul style="list-style-type: none"> Fracture located distal to the tip of the stem. 	<ul style="list-style-type: none">  

- Presentation

- History

- mechanical fall
 - fall on out-stretched hand
- worsening arm pain
 - present with mechanical loosening of the prosthesis

- Symptoms

- common symptoms
 - acute pain in the upper arm
 - prodromal pain maybe present in patients with mechanically loose implants
 - gross deformity

- Physical exam

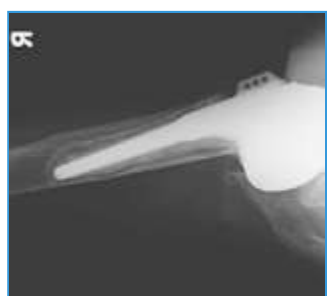- inspection
 - varus or valgus deformity
 - ecchymosis & swelling
 - shortening of the affected arm
 - diffuse tenderness of the upper arm
- motion

- patient may not be able to move affected elbow or shoulder
 - most often due to pain
- neurovascular
 - examine for radial nerve status
 - high incidence of radial nerve palsy with distal humerus fractures
 - most often neurapraxia and does not require operative management
 - document full neurological and vascular findings

• Imaging

○ Radiographs

- orthogonal radiographs of the affected humerus
 - AP, axillary lateral, Grashey, scapular Y views
- findings
 - fracture involving the prosthetic stem tip
 - usually in an oblique pattern
- criteria dictating treatment
 - appearance of stem stability
 - zones of lucency around stem



- suggests lack of bone ingrowth or osteolysis

○ CT

- indications
 - concern for loose prosthesis
 - fracture pattern on radiographs concerning for mechanical stability of humeral stem
 - prodromal pain consistent with mechanical loosening
 - comminution
- perform with metal suppression protocol
 - decreased artifact from prosthesis
- assessment:
 - determine fracture morphology
 - assess remaining bone stock
 - quality of the rotator cuff muscle
 - version of the glenoid if revision is determined necessary

• Treatments

○ Nonoperative treatment

- **immobilization**
 - indications
 - long oblique or spiral type A or B fractures with a stable prosthesis
 - type C fracture
 - outcomes:
 - union rates <50%

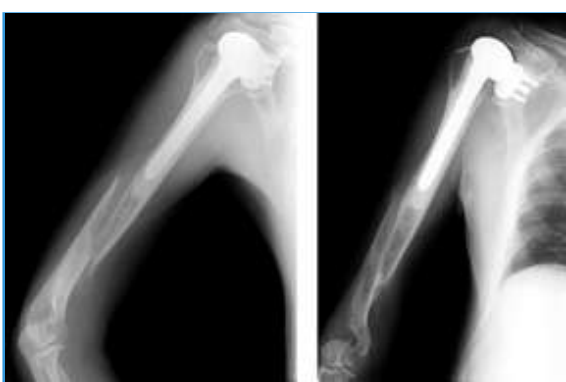
○ Operative treatment

- **conversion to prosthetic stem spanning fracture site by two cortical diameters**
 - indications
 - intraoperative type A fractures
- **conversion to proximally porous coated long stem prosthesis spanning fracture site by two to three cortical diameters**
 - indications
 - intraoperative type B fractures
 - intraoperative type C fractures
- **open reduction and internal fixation**
 - indications

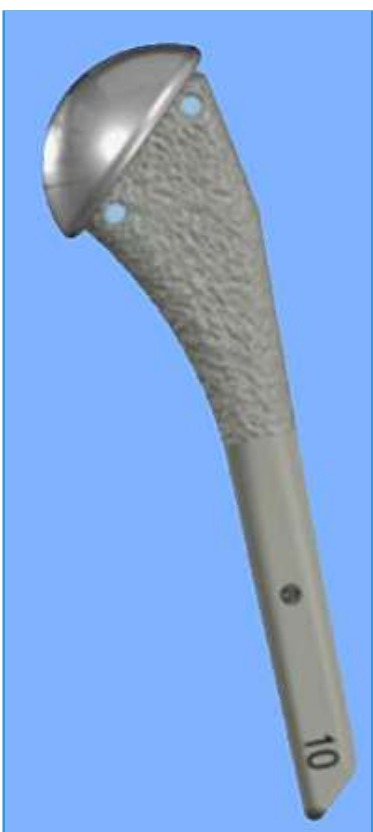- intraoperative fractures
 - type C unamenable to long stem prosthesis
- postoperative fractures
 - transverse type A and B fractures with stable prosthesis
 - type C that has failed nonsurgical management
 - patients unable to tolerate nonoperative management
- **revision arthroplasty with supplementary fixation**
 - indications
 - presence of a loose prosthesis with any fracture type
 - long stem prosthesis
 - poor bone stock
 - bypass fracture by two cortical diameters
 - short stem prosthesis
 - good bone stock
 - convert to a shorter stem prosthesis than original and apply supplementary fixation

• Techniques

○ Immobilization

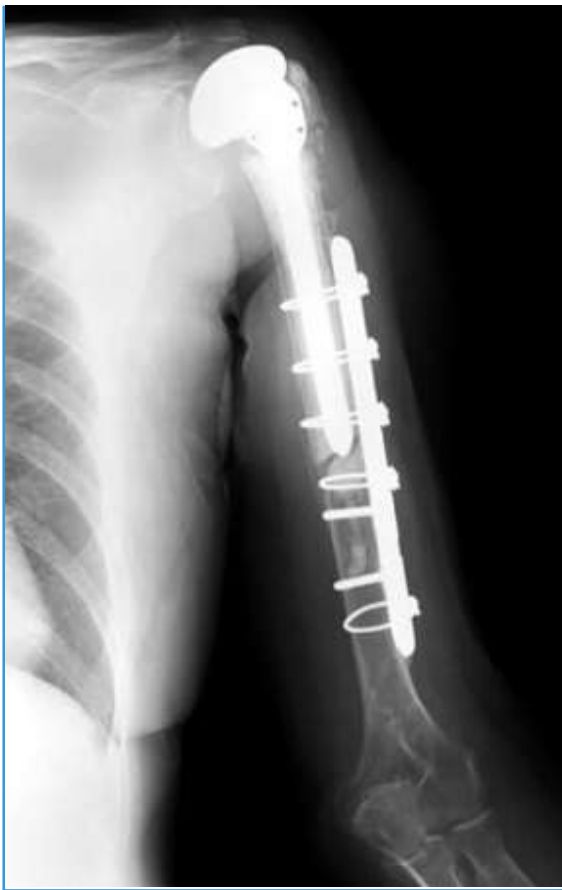

- coaptation splint followed by functional bracing
- hydrostatic pressure created by brace stabilizes fracture site
- higher risk of nonunion with type A and B fractures
- **Conversion to prosthetic stem spanning fracture site by two cortical diameters**
 - removal of original stem
 - placement of longer stem engages distal fragment and improves fracture alignment
 - +/- supplementary fixation depending on fracture stability
- **Conversion to proximally porous coated long stem prosthesis spanning fracture site by two to three cortical diameters**

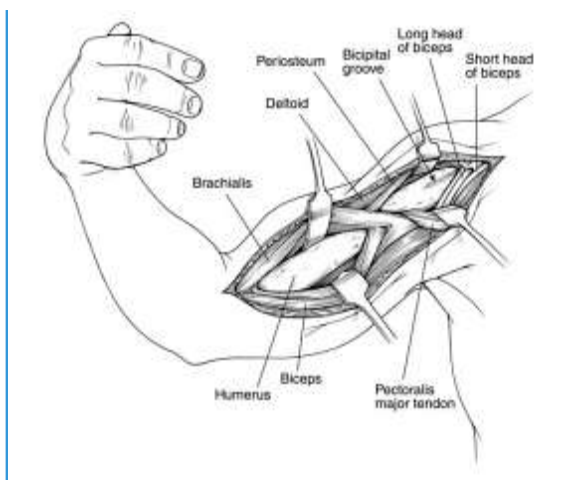


- proximal porous coating allows for metaphyseal stability
- distal fragment cemented to stem tip
- techniques:
 - pack cement into the distal canal to allow for distal stem fixation
 - avoid proximal cement extrusion into fracture site
 - use cortical strut grafting with cerclage cables in cases of bone deficiency
 - olecranon fossa may prevent successful treatment with this method

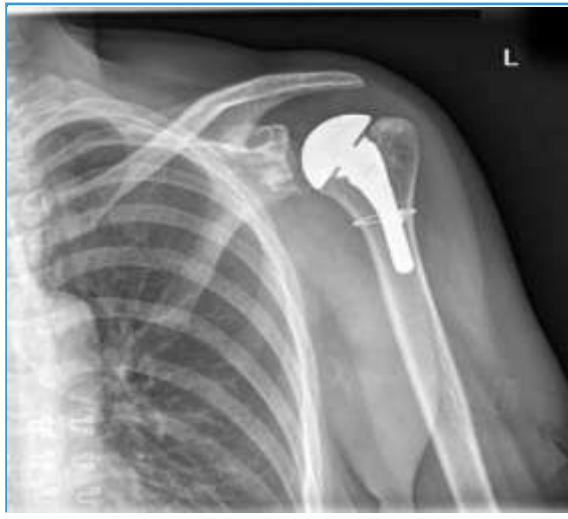- **Open reduction and internal fixation**



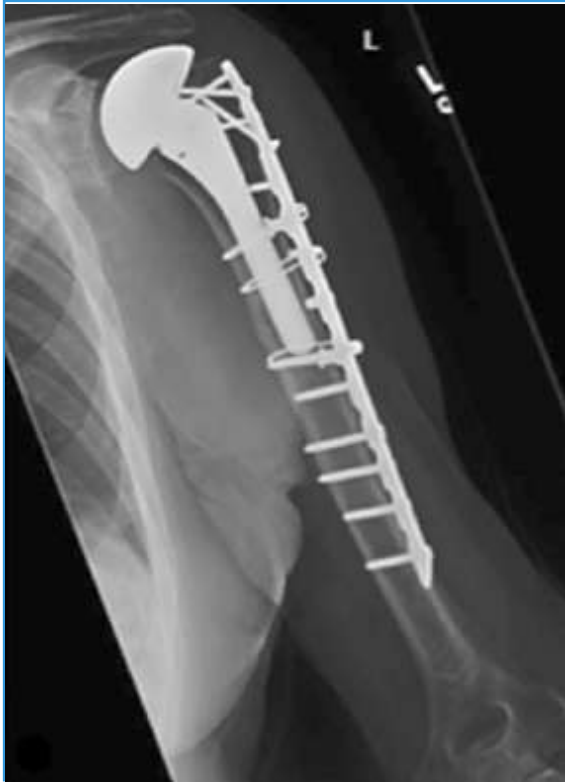- techniques:
 - approaches:
 - anterolateral approach to the humerus



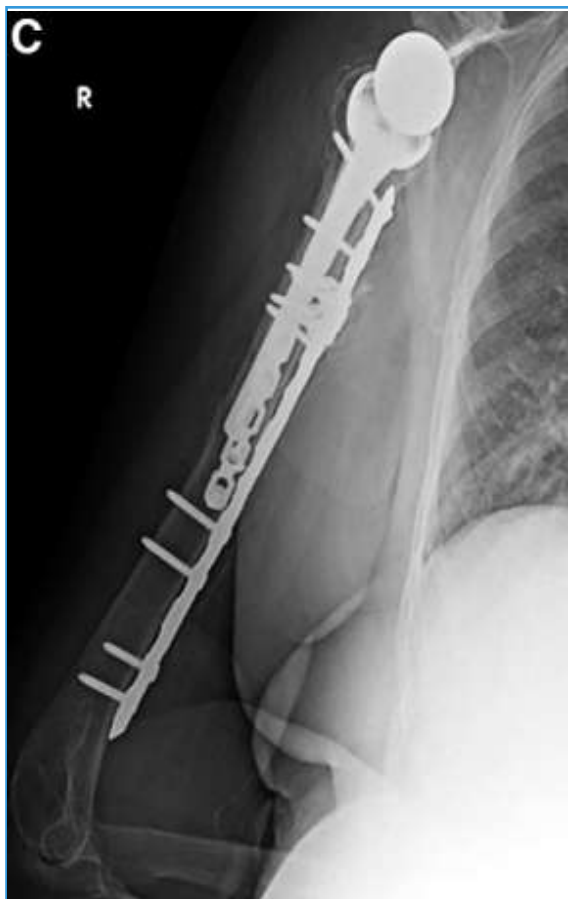
- can be extended from deltopectoral approach used for the index procedure
 - tip of coracoid process
 - curve along the deltopectoral groove
 - continue incision along lateral border of biceps brachii
- develop interval between biceps and brachialis muscle
- divide brachialis muscle longitudinally at midline and elevate subperiosteally to expose distal aspect humerus
 - medial fibers innervated by musculocutaneous nerve
 - lateral fibers innervated by radial nerve
- preserve as much soft tissue attachment to the humerus as possible
- place appropriate sized plate
 - usually 4.5 mm LC-DCP plate
 - screw fixation distal to stem
 - cerclage cables proximal to stem tip
- posterolateral approach
 - good for distal postoperative fracture with stable prosthesis
- greater tuberosity and calcar fractures
 - suture or cable fixation



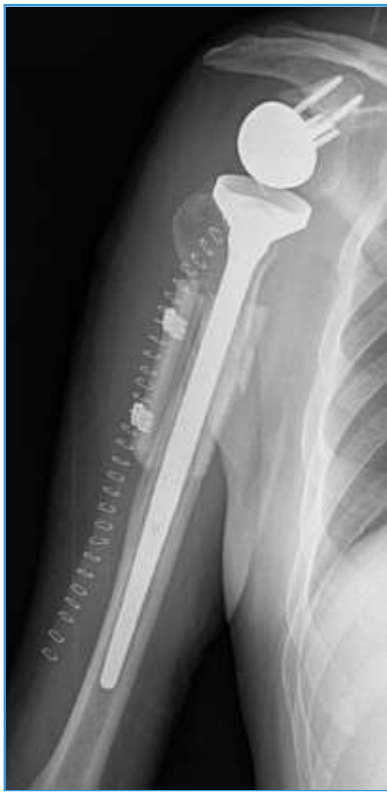- hybrid locking plates with cerclage cables have been used for postoperative fractures



- plate placed eccentrically on humerus to allow locking screws to miss humeral stem
 - allows bicortical fixation around the stem
- use of cerclage cables for added stability
- alternatively can use dual plate construct or 3.5 mm attachment plates for bicortical fixation



- can combine with allograft augmentation for fractures with deficient cortices
 - can use cortical strut allograft and fix with cerclage cables
 - 2 hemicylinders can be used to form a sarcophagus around prosthesis



- **Revision arthroplasty with supplementary fixation**

- type of revision prosthesis is dependent on the quality of bone stock
 - poor bone stock
 - conversion to long-stemmed prosthesis
 - bypasses fracture site by at least two to three cortical diameters
 - can be augmented with allograft to enhance bone stock
 - good bone stock
 - conversion to short-stemmed prosthesis
 - stem ends more proximal than original prosthesis
 - apply supplementary fixation to fracture site
 - shorter stem impants prevents stem tip from distacting the fracture site

- **Complications**

- Nonunion
- Delayed union
- Glenohumeral stiffness
- Radial nerve injury
 - can be secondary from the fracture
 - iatrogenic from fixation with cerclage cables
 - instrumentation proximal to the inferior edge of the latissimus dorsi insertion may reduce the risk of iatrogenic radial nerve injury

- **Prognosis**

- High union rates when appropriately treated
 - time to union 2-8 months
- Significant decrease in shoulder ROM

68- Revision Total Elbow Arthroplasty

• Summary

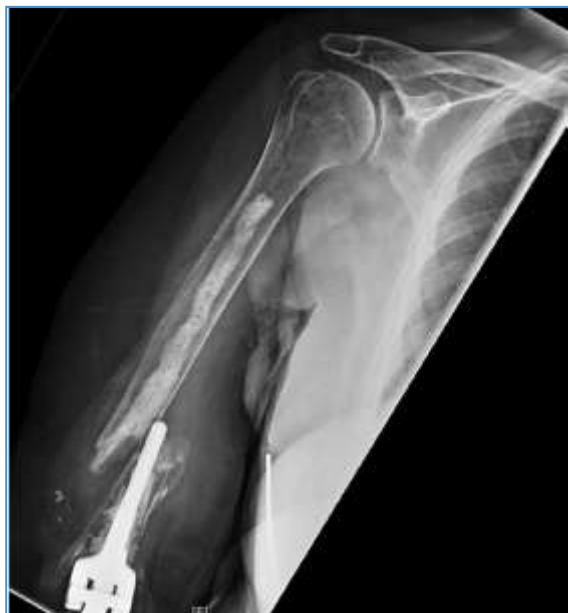- Revision Total Elbow Arthroplasty is most commonly performed due to aseptic loosening, periprosthetic infection, or periprosthetic fracture with loose implants.
- Diagnosis is made with radiographs in the setting of periprosthetic fracture or implant loosening. Inflammatory markers and elbow aspiration can be helpful in diagnosis of periprosthetic infection.
- The type of revision depends on etiology of failure, patient age and patient comorbidities.

• Epidemiology

- Incidence
 - overall lifetime revision rate of TEA is 13%
 - the current overall outcomes and survival rates of TEA shows overall 5, 10, 15 and 20 year rates of 92%, 81%, 71% and 61%
- Demographics
 - initially, the primary patients undergoing TEA were those with rheumatoid arthritis
 - with advent of anti-rheumatics, a major proportion of patients undergoing TEA are now post-traumatic
- Risk factors for overall TEA failure
 - smoking
 - significant medical co-morbidities
 - non-compliance with activity restrictions
 - non-constrained system (dislocation)
 - highly constrained system (loosening)

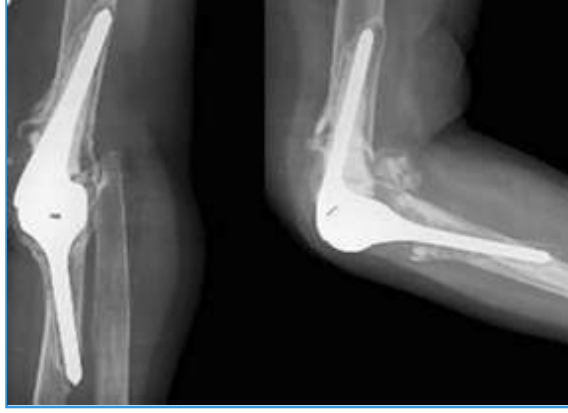• Etiology

- Pathophysiology
 - 5 modes of TEA failure requiring revision
 - infection (initially ~8% but since advent of DMARDs, rates have dropped to ~3%)
 - substantially higher than arthroplasty of other joints
 - most common pathogen is s.aureas (~40%) followed by s.epidermidus (30-35%)
 - worse outcomes with s.epidermidus
 - risk factors for TEA infection
 - higher prevalence in patients with rheumatoid arthritis on steroids
 - decreased thickness of soft tissue envelope
 - prior elbow infection
 - prior elbow surgery
 - psychiatric illness
 - periprosthetic fracture (5%)

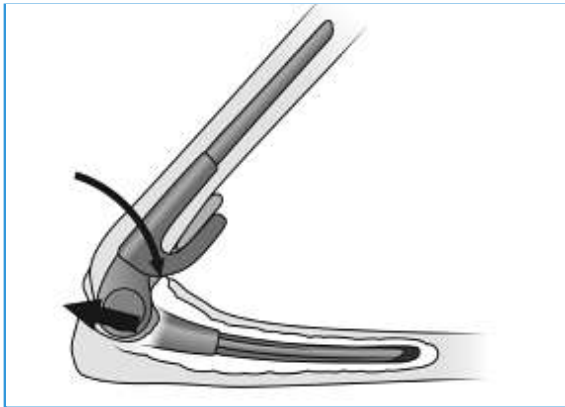


- intra-operative
 - can occur during bone preparation, reaming and implantation
- post-operative
 - non-compliance with activities

- ground-level falls
- aseptic loosening (15%)



- higher rates associated with cementation and highly constrained systems
- can result from anterior impingement of coronoid being driven into anterior humeral flange during maximal elbow flexion



- instability
 - commonly due to unconstrained TEA systems
- component failure (15%)
 - most commonly due to bushing wear



- most common in younger patients or those with significant pre-existing deformity

- Classification

- Mayo (O'Driscoll & Morrey) Classification of Periprosthetic fracture

	Characteristics	Treatment	
<ul style="list-style-type: none"> Type I 	<ul style="list-style-type: none"> Periarticular fracture involving the humeral condyle or olecranon. Caused by osteolysis around hinge components and distracting forces from muscle attachments 	<ul style="list-style-type: none"> Undisplaced - Immobilization /soft tissue repair is sufficient to achieve fibrous union (Rigid fixation not required). Displaced - ORIF with heavy nonabsorbable sutures or tension band wiring (if limited periprosthetic bone) 	
<ul style="list-style-type: none"> Type II 	<ul style="list-style-type: none"> Fracture along length of humeral or ulnar stem. Subtypes: <ul style="list-style-type: none"> II1: well-fixed implant II2 : loose implants, good bone stock II3 : loose implants, severe bone loss 	<ul style="list-style-type: none"> II1: ORIF with component retention +/- strut allograft II2: Revision arthroplasty using long-stem prosthesis ± strut allograft and impaction bone grafting. Locking plates/ cerclage wires may be added for added stability. II3: Require revision arthroplasty with extensive allograft supplementation. Often times require resection arthroplasty 	
<ul style="list-style-type: none"> Type III 	<ul style="list-style-type: none"> Distal to prosthesis. Treated like routine fractures Radiographs/CTs to ensure implants are not loose, cement mantle not cracked. 	<ul style="list-style-type: none"> If implants are well-fixed, immobilization for humerus and ORIF for ulna. If implants are loose, treat as Type II2 fractures. 	

- Presentation

- Symptoms

- squeaking
 - elbow crepitus or "squeaking" sound with motion
- pain
 - elbow pain
 - pain at night or rest is a red flag for infection
 - swelling
- stiffness
 - decrease motion after a period of normal motion
 - progressive loss of motion without identifiable cause is red flag for infection

- Physical exam

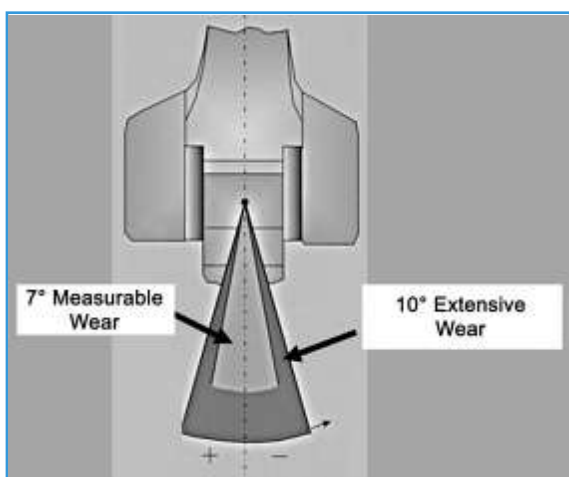
- inspection
 - erythema/sinus tract in the setting of infection
 - diffuse tenderness
 - elbow swelling
 - deformity
 - in cases of significant bushing wear
- motion
 - painful and limited range of motion
 - crepitus/squeaking during motion

- Imaging

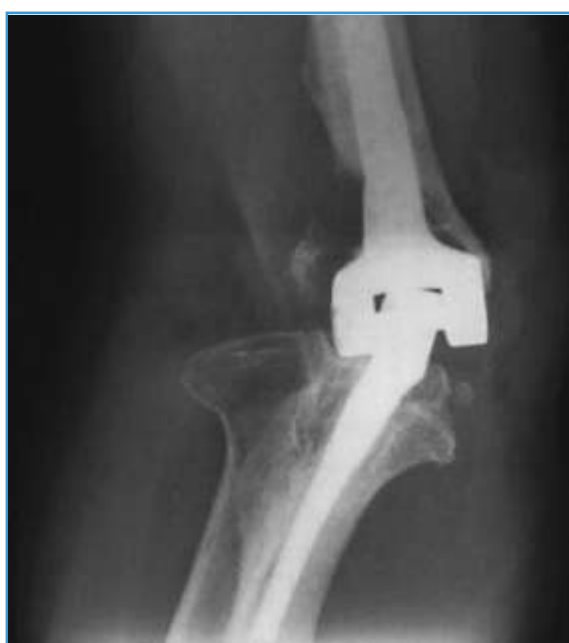- Radiographs

- recommended views
 - AP and lateral of humerus, elbow, and forearm

- findings
 - periprosthetic component loosening
 - early unexplained loosening concerning for infection
 - periprosthetic humeral or ulnar fractures
 - polyethylene bushing wear
 - angle of intersection between the ulnar implant in relation to the humeral implant is measured



- mild-moderate bushing wear is considered when the angle > 10 degrees



- CT
 - indications
 - assess for peri-prosthetic osteolysis or loosening
 - can be useful to determine if cement mantle is intact or broken in cases of peri-prosthetic fracture
- MRI
 - indications
 - to evaluate for abscess or soft tissue infection
 - views
 - obtain with metal subtraction
 - obtain with contrast

Studies

- Diagnosis
 - there are no definitive tests to reliably diagnose periprosthetic elbow infection
 - high clinical suspicion necessary for diagnosis of infection
- Serum Labs
 - ESR, CRP, WBC are usually elevated
 - IL-6 and alpha defensin have not been previously studied for utility in PJI of the elbow
- Elbow arthrocentesis
 - no documented acceptable synovial WBC count indicative of infection
 - positive culture generally indicative of chronic infection
 - very high PPV and very low NPV (a negative aspiration should NOT be used to rule out infection)
- Intraoperative analysis
 - intraoperative histologic analysis
 - most effective way of diagnosing TEA infection
 - specificity of 93% and NPV of 90%, sensitivity of only 51%
 - intraoperative cultures
 - cultures negative 10% of the time in cases of infectious TEA
 - negative cultures more common in chronic infections (~15%) compared to acute infections (3%)

- Treatment

- Nonoperative

- **immobilization, functional elbow brace**

- indications

- type I humeral condylar or olecranon fractures with stable prosthesis
- type III humeral fractures with stable implants
- patients who are not candidates for surgery (medical frailty, noncompliance, frequent falls)

- length

- length of immobilization depends on location of fracture (2-4 weeks)

- type

- transition to sarmiento (for Type III humerus fractures) or functional elbow brace (for Type 1 fractures)

- Operative

- **irrigation and debridement, bushing exchange, component retention**

- indications

- crepitus, squeaking +/- elbow pain with range of motion with stable implants and no evidence of infection (significant bushing wear)
- acute peri-prosthetic joint infection (presenting < 90 days from surgery)

- outcomes

- in appropriate candidates without signs of infection, 75% result in good results at 5 year followup following isolated bushing exchange
- in cases of acute infection, I&D and component retention is 63% effective at eradicating acute infections
 - only 31% effective in management of chronic infections

- **open reduction and internal fixation, component retention, +/- fracture excision, +/- strut allograft**

- indications

- type I peri-articular olecranon fractures
- type II1 fractures
- type III fractures of the ulna

- outcomes

- 80-90% patients have no complications following isolated ORIF or excision for selected fractures

- **single stage revision TEA, +/- ORIF and allograft**

- indications

- type II2 periprosthetic humeral shaft or ulna fractures
- aseptic loosening

- outcomes

- only 66% affective for errdicating chronic TEA infection

- **component explantation and 2-stage revision TEA**

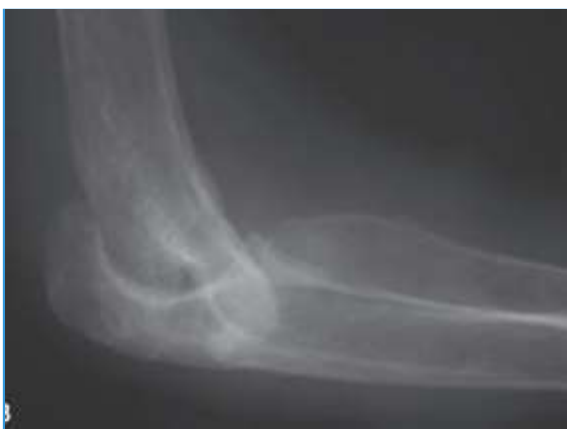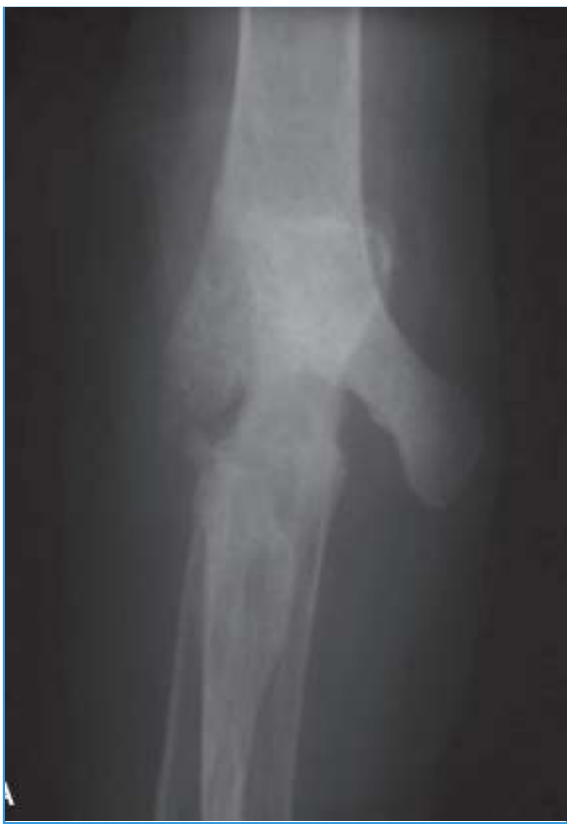- indications

- Mayo II2
- infected periprosthetic TEA

- outcomes

- success rate of eradicating chronic infection is 90% with 2-stage revision TEA (compared to 66% for single-stage)

- **resection arthroplasty**



- indications
 - salvage procedure for treatment resistant PJI in patients who are unable to go multiple surgical procedures, have severe bone loss, and severely compromised soft tissue envelope
 - Mayo II/III periprosthetic fractures not amendable for reconstruction
- outcomes
 - 71% effective in completely eradicating infection
 - leads to the lowest functional scores (based on Mayo Elbow Performance score)

• Techniques

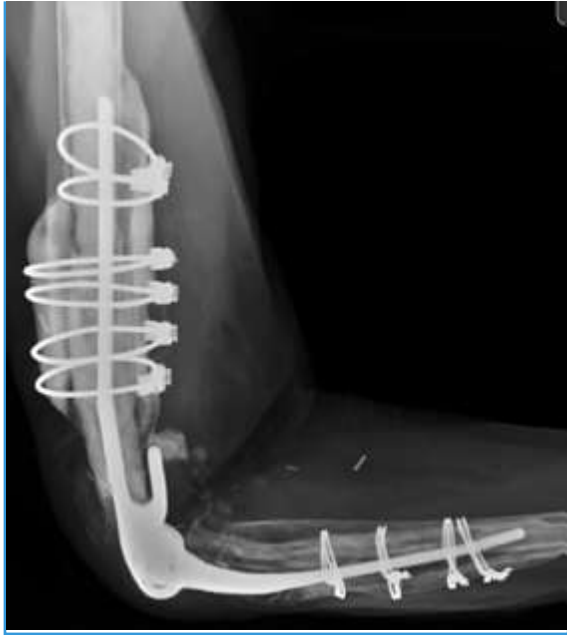○ Irrigation and debridement, bushing exchange, component retention

- approach
 - use prior surgical approach if feasible to allow adequate exposure to the elbow joint
- soft tissue work
 - most authors advocate for ulnar nerve exploration/decompression in presence of ulnar nerve symptoms
 - if nerve is not symptomatic, it can be identified proximally and protected throughout rest of case
 - a thorough debridement of any necrotic or infected soft tissue should be performed with care to preserve a soft tissue envelope for closure.
- instrumentation
 - humerus and ulnar components should be uncoupled
 - both humeral and ulnar components should be inspected for integrity, loosening and rotation
 - a polyethylene bushing exchange should then be performed

○ Open reduction and internal fixation, component retention, +/- fracture excision, +/- strut allograft,

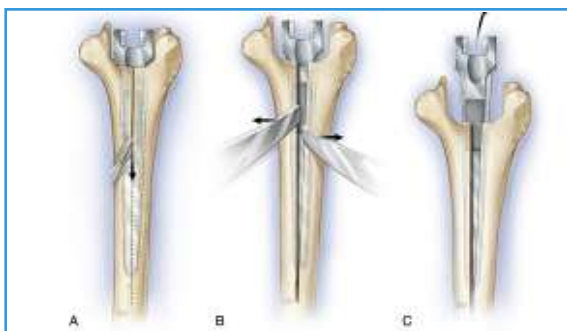
- approach
 - for humeral fractures
 - posterior paratricipital muscle sparing approach
 - for ulna fractures
 - posterior approach to elbow with ulna subcutaneous border extension.
- soft tissues
 - identify radial nerve
 - radial nerve crosses lateral intermuscular septum 14 cm proximal to the lateral epicondyle
 - ulnar nerve identified proximally
- instrumentation
 - type 1 peri-articular olecranon fractures
 - extensor mechanism disruption

- variation of tension band technique recommended
 - K-wires should be placed dorsal to implant to allow for engagement with the cement mantle followed by figure-of-8 technique
- extensor mechanism intact and well-fixed stem
 - a simple excision of the fragment be performed
- type II1 humerus fractures without component loosening
 - use allograft struts with cerclage cables
 - can use both anterior and posterior allograft struts if necessary



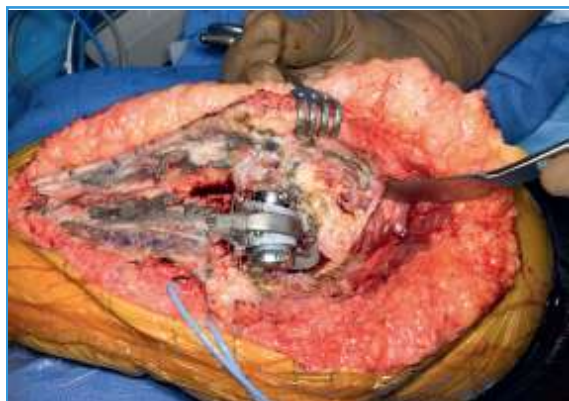- fixation along the humeral implant is achieved using unicortical screws and cerclage cables
- type III ulna fractures without component loosening
 - standard ORIF with plate fixation
- complications
 - hardware prominence causing soft tissue and nerve irritation
- **Single stage revision TEA, +/- ORIF and allograft**
 - approach
 - as above
 - bone work
 - removal of all loose implants and loose cement
 - instrumentation
 - canal must be prepared for an implant with a longer stem that will extend 2 cortical widths beyond a fracture (if present)
 - cementation preferred
 - important to cement revision stem before struts are placed because cement extravasation out of medullary canal may sit deep to allograft strut and prevent allograft incorporation or even cause nerve irritation.
 - bone strut allograft
 - for humeral-sided fractures
 - a longer posterior and shorter anterior strut are preferred (to prevent impingement with elbow flexion)
 - for ulnar-sided fractures
 - dorsal allograft strut placed laterally under anconeus or medially under FCU to prevent subcutaneous prominence
 - plate and screw fixation
 - implants
 - long-stem implants should be used in all cases
- **Component explantation and 2-stage revision TEA**
 - infection
 - approach
 - posterior triceps-sparing approach recommended
 - soft tissue
 - if ulnar nerve has been previously transposed and patient has ulnar nerve symptoms, consider revising transposition or perform submuscular transposition
 - component explantation
 - removal of humeral prosthesis
 - Using burr and flexible osteotomes to remove cement circumferentially around the humerus.
 - Loose components and those with precarious fixation may be removed with a slap-hammer extractor

- If humeral component cannot be safely removed, a posterior humeral cortical split with use of saw and osteotomes can be used



- removal of ulnar prosthesis

- In cases of well-fixed ulnar components and firmly retained cement, an extended olecranon osteotomy provides good exposure to the implant and cement



- should be repaired with cables followed reimplantation
- should attempt to remove all cement
- can use flexible reamers to further debride canal

- antibiotic spacer

- antibiotic spacers or beads are placed into both humeral and ulnar medullary canals
- discs of cement placed in locations around articulation
 - avoid cement placement in subcutaneous tissue

- static external fixator can stabilize joint while spacer in place

- intravenous antibiotics

- at least 6 weeks of intravenous culture specific antibiotics recommended prior to attempt at reimplantation

- reimplantation

- once inflammatory markers have normalized, can proceed with long-stem reimplantation
 - antibiotic cementation recommended

- periprosthetic fractures

- may be performed in 2 stages:

- stage I - address fracture union with iliac crest bone graft and plate fixation.

- stage II (after fracture union) - revise implants with longer stem and impaction graft

○ Resection arthroplasty

- approach

- use prior surgical approach, specially if posterior midline

- soft tissues

- care to keep thick subcutaneous soft tissue flaps to allow for skin closure

- delicate and careful exposure of the ulnar and radial nerves should be performed, which may be located in the most unpredictable locations

- bony work

- proceed with explantation as above with careful removal of all cement

- stabilization

- In the absence of sufficient bone stability, the ulna and humerus may be stabilized with heavy sutures or wires through bone

• Complications

○ Persistent deep infection

- incidence

- ~10% of patients following 2-stage revision, ~30% following single stage revision

- risk factors

- polymicrobial infections

- rheumatoid patients on steroids

- extensive bone loss

- treatment
 - resection arthroplasty
- Ulnar nerve palsy
 - risk factors
 - cement extravasation from medullary canal
 - not visualization nerve during any revision surgery
- Radial nerve palsy
 - risk factors
 - cement extravasation from medullary canal
 - impingement with long plates used for fracture fixation
- Symptomatic hardware
 - risk factors
 - ORIF of periprosthetic ulna fractures
 - treatment
 - removal of hardware after fracture union

- Prognosis

- Prognostic variable
 - depends on etiology of TEA failure, medical co-morbidities and remaining ulna and humeral bone stock

69- Neuropathic Charcot Joint Of The Elbow

• summary

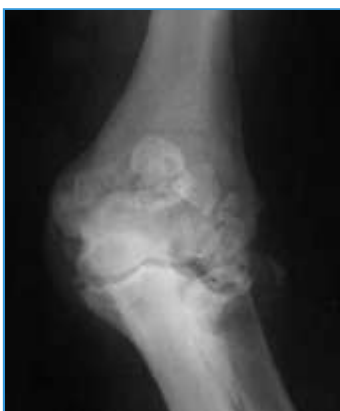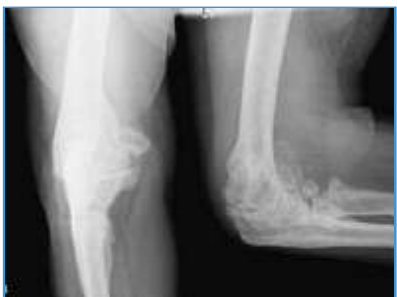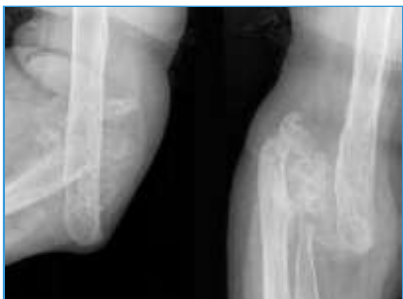- Neuropathic Charcot Joint of the Elbow is a chronic and progressive joint disease most commonly caused by syringomyelia leading to the destruction of the elbow joint and surrounding bony structures.
- Diagnosis is made with radiographs of the elbow and supplemented with cervical spine MRI to assess for a syrinx.
- Treatment should be individualized based on degree of functional limitation and underlying neurological condition. Neurosurgical decompression is indicated in the presence of a syrinx.

• Epidemiology

- Incidence
 - rare condition in the upper extremity (~ 40 cases reported in literature)
- Anatomic location
 - elbow (this topic)
 - shoulder
 - foot & ankle (see diabetic Charcot foot)

• Etiology

- Pathophysiology
 - syrinx formation
 - syrinx formation (fluid-filled cavity) in spinal cord causes damage to the decussating fibers of the lateral spinothalamic tract leading to loss of pain and temperature sensation
 - loss of pain/temperature leads to dissociative anesthesia in which proprioception and motor function are preserved but pain and temperature are not
 - as syrinx enlarges, damage to dorsal column and anterior horn of spinal cord lead to areflexia, loss of motor strength and muscle atrophy.
 - joint destruction



- neurotrauma
 - loss of peripheral sensation and proprioception leads to repetitive microtrauma to the joint
 - poor fine motor control generates unnatural pressure on certain joints leading to additional microtrauma
- neurovascular
 - neuropathic patients have dysregulated reflexes and desensitized joints that receive significantly greater blood flow
 - the resulting hyperemia leads to increased osteoclastic resorption of bone

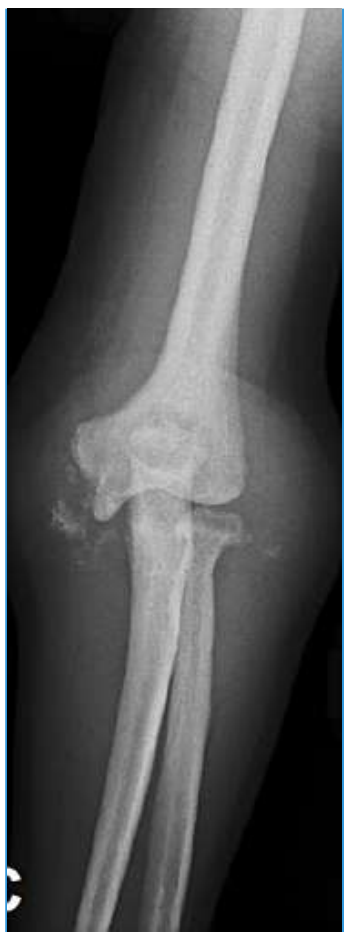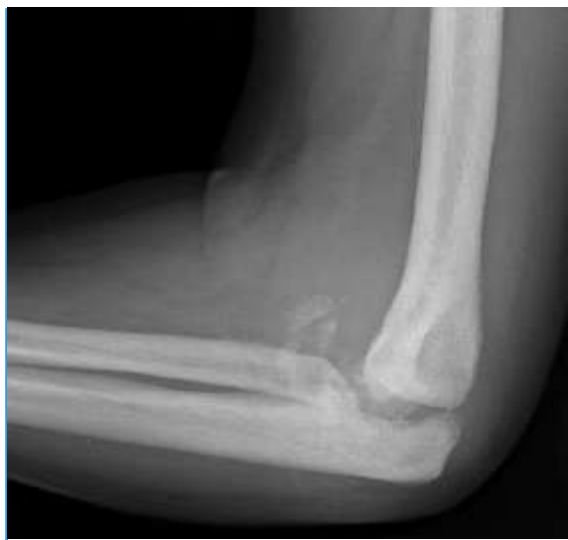- Genetics
 - molecular biology
 - RANK/RANKL/OPG triad pathway is thought to be involved
- Associated conditions
 - orthopedic conditions
 - ulnar neuropathy
 - medical conditions & comorbidities
 - syringomyelia
 - most common etiology of neuropathic arthropathy of the upper extremity
 - 25% of Charcot joints are a result of syringomyelia
 - monoarticular (shoulder > elbow)
 - Arnold-Chiari malformation
 - most common cause of syringomyelia
 - Hansen's disease (leprosy)
 - second most common cause of upper extremity neuropathic arthropathy
 - neurosyphilis (tabes dorsalis)
 - usually affects the knee
 - can be polyarticular
 - diabetes
 - most common cause of foot and ankle neuropathic joints

• Presentation

- Symptoms
 - swollen elbow
 - 50% have pain, 50% are painless
 - loss of function
- Physical exam
 - inspection
 - swollen, warm, erythematous joint
 - mimics infection
 - atrophy due to ulnar nerve entrapment
 - interosseous atrophy
 - hypothenar atrophy
 - clawing
 - motion
 - loss of active motion is most common finding
 - elbow flexion, extension, pronation and supination all affected
 - elbow joint may be mechanically unstable
 - loss of passive motion indicates mechanical block
 - neurovascular
 - a neurologic evaluation is essential
 - ulnar nerve entrapment at the elbow very common
 - paresthesias in ulnar nerve distribution
 - interosseous weakness

• Imaging

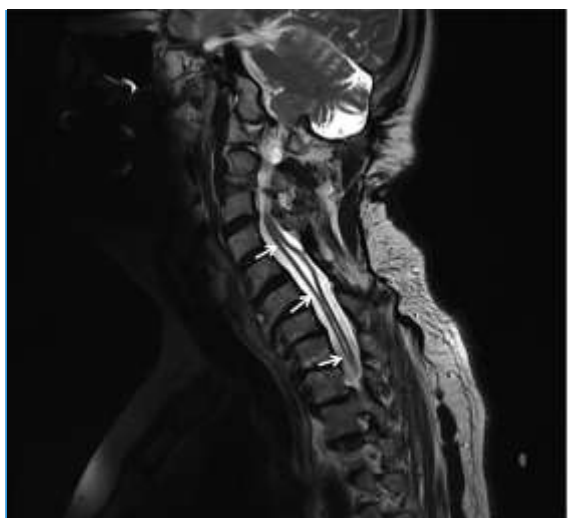- Radiographs
 - recommended views
 - standard views of affected joint
 - AP and lateral of the elbow
 - findings
 - early changes
 - degenerative changes may mimic osteoarthritis
 - late changes



- obliteration of joint space
- fragmentation of both articular surfaces of a joint leading to subluxation or dislocation
- scattered "chunks" of bone in fibrous tissue
- joint distention by fluid
- surrounding soft tissue edema
- heterotopic ossification
- fracture

○ MRI

- indications
 - MRI of cervical spine to rule out syrinx when neuropathic elbow arthropathy is present



○ Bone scan

- technetium bone scan
 - findings
 - may be positive (hot) for neuropathic joints and osteomyelitis
- indium WBC scan
 - findings
 - will be negative (cold) for neuropathic joints and positive (hot) for osteomyelitis
 - useful to differentiate from osteomyelitis

• Studies

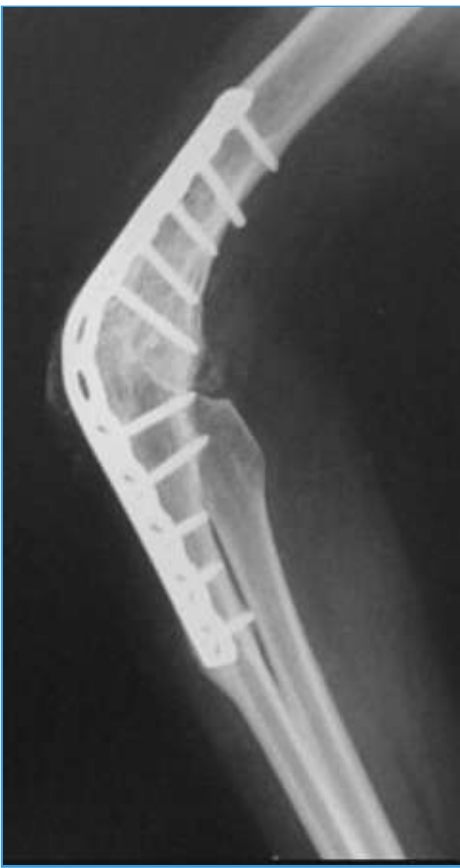- Labs
 - ESR and WBC can be elevated making it difficult to differentiate from osteomyelitis
- EMG/NCS
 - helpful for confirming ulnar neuropathy associated with diagnosis
- Histology
 - synovial hypertrophy
 - detritic synovitis (cartilage and bone distributed in synovium)

• Differential

- Osteomyelitis/septic joint
 - difficult to distinguish from osteomyelitis based on radiographs and physical exam
 - common findings in both conditions
 - swelling, warmth
 - elevated WBC and ESR
 - technetium bone scan is "hot"
 - unique to Charcot joint disease
 - indium leukocyte scan will be "cold" (negative)
 - will be "hot" (positive) for osteomyelitis

• Treatment

- Nonoperative
 - **rest, NSAIDs, functional bracing, restriction of activity and treatment of underlying disease**
 - indications
 - first line treatment for neuropathic elbow joint
 - outcomes
 - 50% of patients reported improvement after non-operative management
 - **intra-articular corticosteroid injection**
 - indications
 - severe elbow pain
- Operative
 - **neurosurgical decompression**
 - indications
 - presence of cervical syrinx
 - outcomes
 - decompression of syrinx has shown to slow disease progression, maximize joint function and improve bone quality
 - studies have shown some elbow joint space restoration following syrinx decompression
 - **peripheral nerve neurolysis**
 - indications
 - ulnar nerve palsies
 - PIN palsies
 - outcomes
 - limited cases series have shown good recovery of nerve function but high recurrent rates
 - **elbow arthrodesis**



- indications
 - elbow pain and instability having failed conservative management
- outcomes
 - limited case series have shown improvement of pain but with functional limitations
- **total joint replacement**
 - indications
 - Charcot joint is considered a contraindication to elbow total joint replacement
 - due to poor bone stock, prosthetic loosening, instability, and soft-tissue compromise
 - outcomes
 - limited case reports exist on elbow arthroplasties for charcot elbow with mixed results

• Techniques

- **Rest, NSAIDs, functional bracing, restriction of activity and treatment of underlying disease**
 - technique
 - functional bracing
 - allows flexion-extension, but neutralizes varus-valgus stresses
- Intra-articular corticosteroid injection
 - technique
 - ulnohumeral joint injection is considered most effective
- Neurosurgical decompression
 - technique
 - neurosurgical management has been reported to consist of 1 or more of the following
 - posterior fossa decompression
 - craniotomy
 - syringoperitoneal shunt
 - laminectomy
- Peripheral nerve neurolysis
 - technique
 - cubital tunnel release must be performed with careful soft tissue dissection due to severely altered anatomy noted in patients with charcot elbow
- Elbow arthrodesis
 - technique
 - optimal position
 - optimal position for most activities is 110 degrees flexion whereas 45-60 degrees flexion is optimal for work-related activities.
 - contoured plate fixation most commonly used to achieve arthrodesis

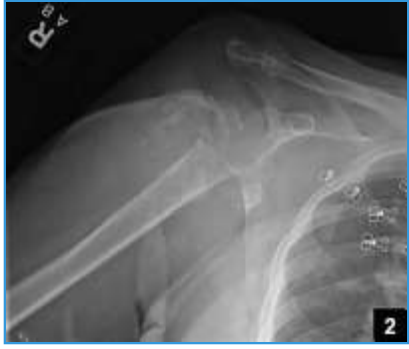• Complications

- Ulnar nerve entrapment
 - most common complication of charcot elbow
- Infection

- risk factors
 - high risk with surgical intervention without management of underlying condition
- Upper extremity DVT
 - risk factors
 - any surgical intervention

70- Neuropathic Charcot Joint Of Shoulder

Images



• summary

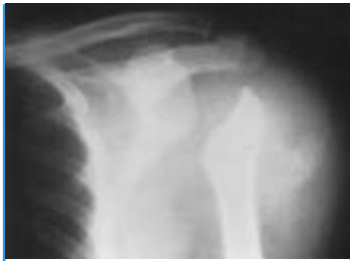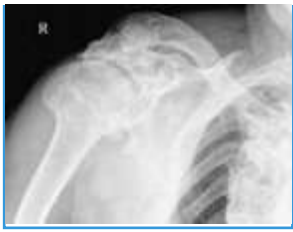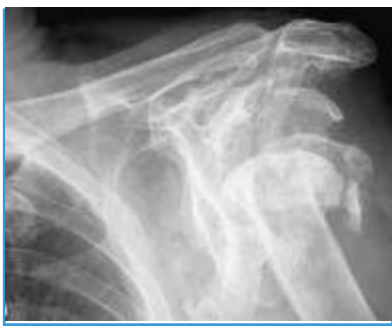- Neuropathic (charcot) shoulder is a chronic and progressive joint disease most commonly caused by syringomyelia leading to the destruction of the shoulder joint and surrounding structures.
- Diagnosis is made with radiographs of the shoulder and supplemented with cervical spine MRI to assess for a syrinx.
- Treatment should be individualized based on degree of functional limitation and underlying neurological condition. Neurosurgical decompression is indicated in the presence of a syrinx.

• Epidemiology

- Incidence
 - very rare
 - around 70 total cases reported in literature
 - 25% of individuals with syrinxes develop neuropathic arthropathy, with 80% of cases occurring in upper extremity
- Demographics
 - mean age at diagnosis is ~50
 - 2:1 male:female ratio
- Anatomic location
 - shoulder (this topic)
 - elbow
 - foot & ankle

• Etiology

- Pathophysiology
 - syrinx formation
 - syrinx formation (fluid-filled cavity) in spinal cord causes damage to the decussating fibers of the lateral spinothalamic tract leading to loss of pain and temperature sensation
 - loss of pain/temperature leads to dissociative anesthesia in which proprioception and motor function are preserved but pain and temperature are not
 - as syrinx enlarges, damage to dorsal column and anterior horn of spinal cord lead to areflexia, loss of motor strength and muscle atrophy.
 - joint destruction
 - neurotrauma
 - loss of peripheral sensation and proprioception leads to repetitive microtrauma to the joint
 - poor fine motor control generates unnatural pressure on certain joints leading to additional microtrauma
 - neurovascular
 - neuropathic patients have dysregulated reflexes and desensitized joints that receive significantly greater blood flow
 - the resulting hyperemia leads to increased osteoclastic resorption of bone
- Genetics
 - molecular biology
 - RANK/RANKL/OPG triad pathway is thought to be involved
- Associated conditions
 - shoulder



- syringomyelia
 - most common etiology of neuropathic arthropathy of the upper extremity
 - 25% of Charcot joints are a result of syringomyelia
 - monoarticular (shoulder > elbow)
 - cervical syringomyelia is the cause of 75% cases of charcot shoulder
- Hansen's disease (leprosy)
 - second most common cause of upper extremity neuropathic arthropathy
- neurosyphilis (tabes dorsalis)
 - usually affects the knee
 - can be polyarticular
- diabetes
 - most common cause of foot and ankle neuropathic joints
- Arnold-Chiari malformation
 - most common cause of syringomyelia
- multiple sclerosis
- end-stage renal disease
- adhesive arachnoiditis and TB arachnoiditis
- meningomyelocele
- chronic alcoholism

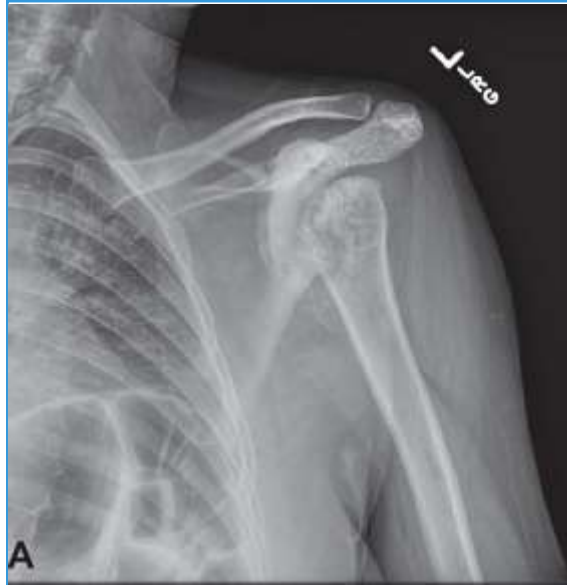• Presentation

- History
 - 30% of patients report trauma to the shoulder as the inciting event
- Symptoms
 - swollen shoulder
 - 50% are painless
 - loss of function
 - joint instability
- Physical exam
 - inspection
 - swollen, warm, erythematous joint
 - can mimic an infection
 - motion
 - loss of motion is most common finding (90%)
 - crepitus
 - joint laxity with mechanical instability
 - neurovascular
 - decreased upper extremity muscle strength
 - sensory and temperature changes along patient's back and arms in cape-like distribution
 - asymmetric reflexes
 - areflexia common in late-stage disease

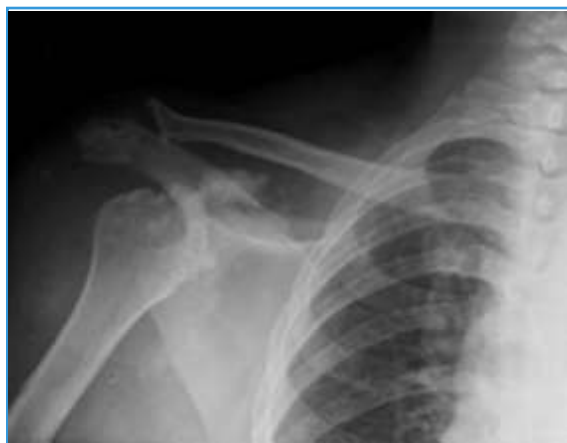- Imaging

- Radiographs

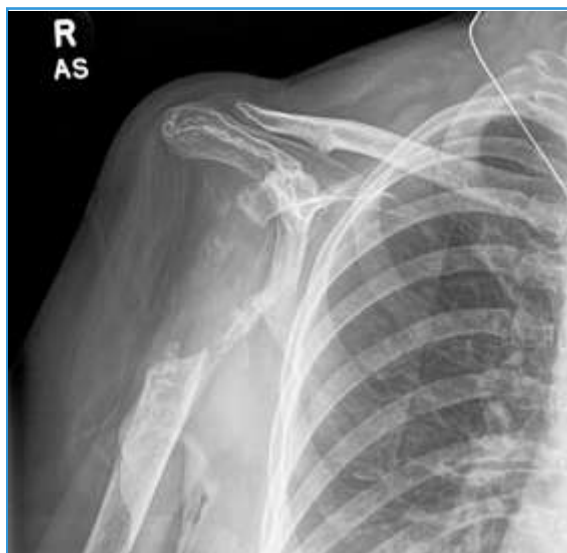- recommended views
 - standard views of affected joint
 - AP and scapular Y of the shoulder
- findings
 - gold-standard in diagnosis of Charcot shoulder
 - early changes
 - degenerative changes may mimic osteoarthritis
 - late changes
 - superomedial flattening of the humeral head



- periarticular soft-tissue calcifications



- glenoid sclerosis
- extensive bone resorption



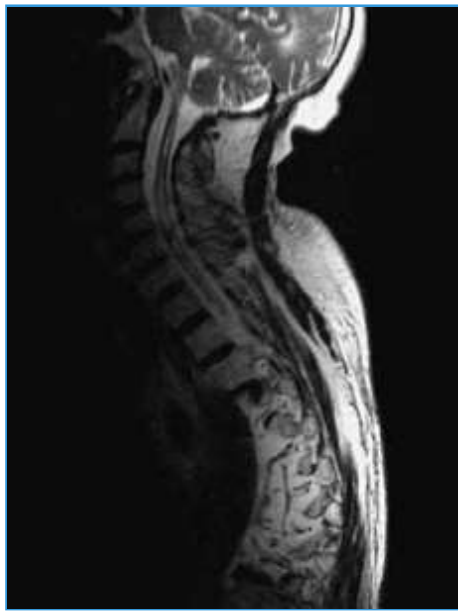- joint destruction
- eventual joint subluxation and dislocation

- CT scan

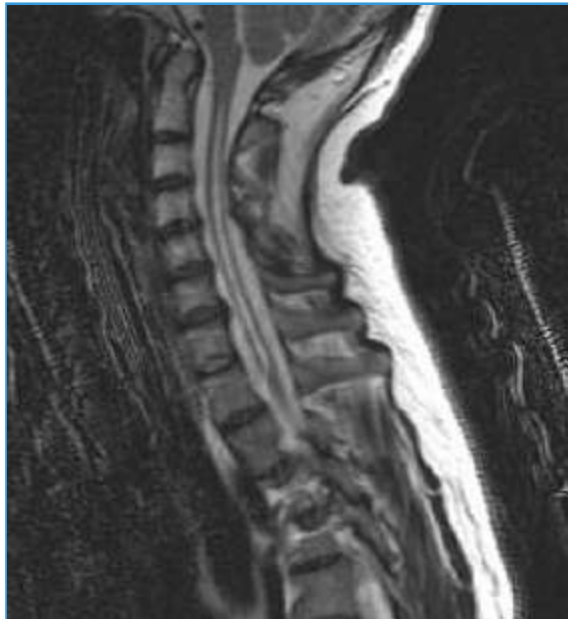- indications
 - if significant concern osteomyelitis/chronic infection
- findings
 - helpful in evaluating for intraosseous gas, cortical destruction, and sequestra

- MRI

- indications
 - MRI of cervical spine to rule out syrinx when neuropathic shoulder arthropathy is present



- findings
 - syrinx has signal intensity equal to or higher than CSF on T1-weighted images



- Bone scan
 - technetium bone scan
 - findings
 - may be positive (hot) for neuropathic joints and osteomyelitis
 - indium WBC scan
 - findings
 - will be negative (cold) for neuropathic joints and positive (hot) for osteomyelitis
 - useful to differentiate from osteomyelitis

• Studies

- Labs
 - ESR and WBC can be elevated making it difficult to differentiate from osteomyelitis
- Histology
 - synovial hypertrophy
 - detritic synovitis (cartilage and bone distributed in synovium)

• Differential

- Osteomyelitis/septic joint
 - difficult to distinguish from osteomyelitis based on radiographs and physical exam
 - common findings in both conditions
 - swelling, warmth
 - elevated WBC and ESR
 - technetium bone scan is "hot"
 - unique to Charcot joint disease
 - indium leukocyte scan will be "cold" (negative)
 - will be "hot" (positive) for osteomyelitis
- Synovial chondromatosis
- Soft tissue sarcoma
- Tumeral calcinosis
- Winchester syndrome
- Gorham's disease
- Milwaukee shoulder syndrome

• Treatment

○ Nonoperative

▪ **rest, NSAIDs, protected immobilization with a sling, restriction of activity and treatment of underlying disease**

▪ indications

- first line treatment for neuropathic shoulder joint

▪ outcomes

- 50% of patients reported improvement after non-operative management

▪ **intra-articular corticosteroid injection**

▪ indications

- severe shoulder pain

▪ outcomes

- some case reports have shown temporary 80% reduction in pain following glenohumeral CSI

○ Operative

▪ **neurosurgical decompression**

▪ indications

- presence of cervical syrinx

▪ outcomes

- decompression of syrinx has shown to slow disease progression, maximize joint function and improve bone quality

- studies have shown regrowth of glenoid fossa following syrinx decompression

▪ **shoulder arthrodesis**

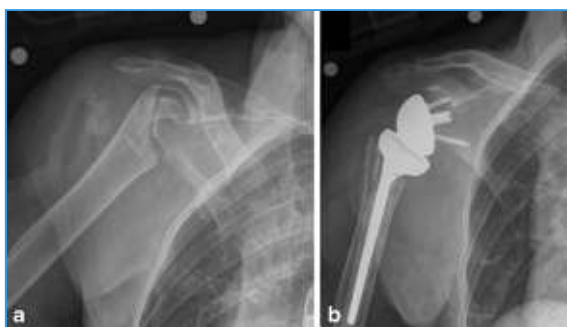▪ indications

- severe charcot shoulder pain having failed conservative management

▪ outcomes

- previously was only operative management offered for charcot shoulder

▪ **shoulder arthroplasty**



▪ indications

- neuropathy arthropathy is listed as STRICT contraindication for majority of FDA-approved shoulder arthroplasties due to concerns of prosthetic loosening

- arthroplasty for this condition should be physician-directed application or off-label use

- newer literature states that arthroplasty is a viable option for patients with charcot shoulder who have failed conservative management and have had underlying condition treated/managed

▪ outcomes

- 70% patients reported improved function with off-label hemiarthroplasty or reverse TSA combined with physical therapy at 5 year followup

• Techniques

○ **Rest, NSAIDs, protected immobilization with a sling, restriction of activity and treatment of underlying disease**

▪ technique

- immobilization slows the progression of ligamentous and soft-tissue laxity

- gentle physical therapy, passive stretching, range-of-motion exercises allow for reduction of pain and swelling

○ **Intra-articular corticosteroid injection**

▪ technique

- glenohumeral injection is considered most effective

○ **Neurosurgical decompression**

▪ technique

- neurosurgical management has been reported to consist of 1 or more of the following

- posterior fossa decompression

- craniotomy

- syringoperitoneal shunt
- laminectomy

- **Shoulder arthrodesis**

- approach
 - S-shaped skin incision beginning over scapular spine, traversing anteriorly over acromion, and extending down the anterolateral aspect of arm
- technique
 - fusion position
 - goal is to allow patients to reach their mouths for feeding
 - think "30°-30°-30°"
 - 20°-30° of abduction
 - 20°-30° of forward flexion
 - 20°-30° of internal rotation

- **Shoulder arthroplasty**

- technique
 - hemiarthroplasty, anatomic TSA, reverse TSA and shoulder resurfacing have all been previously performed off-label for treatment of charcot shoulder with encouraging results.
- complications
 - progressive glenoid erosion in hemiarthroplasty cases
 - acromial stress fractures in rTSA

- **Complications**

- Infection
 - risk factors
 - high risk with surgical intervention without management of underlying condition
- Upper extremity DVT
 - risk factors
 - any surgical intervention
- Acromial stress fracture
 - risk factors
 - reverse TSA for treatment of charcot shoulder

