

Index

[1- Trapezius](#)

[2- Serratus](#)

[3- Levator Scapulae](#)

[4- Rhomboid Minor And Major](#)

[5- Scalene](#)

[6- Pectoralis Minor](#)

[7- Pectoralis Major](#)

[8- Teres Major](#)

[9- Latissimus Dorsi](#)

[10- Coracobrachialis](#)

[11- Deltoid](#)

[12- Supraspinatus](#)

[13- Infraspinatus](#)

[14- Teres Minor](#)

[15- Subscapularis](#)

[16- Biceps Brachii](#)

[17- Brachialis](#)

[18- Brachioradialis](#)

[19- Triceps Brachii](#)

[20- Pronator Teres](#)

[21- Flexor Carpi Radialis](#)

[22- Palmaris Longus](#)

[23- Flexor Digitorum Superficialis](#)

24- Flexor Carpi Ulnaris

25- Flexor Digitorum Profundus

26- Flexor Pollicis Longus

27- Pronator Quadratus

28- Anconeus

29- Extensor Carpi Radialis Longus

30- Extensor Carpi Radialis Brevis

31- Extensor Digitorum Communis

32- Extensor Digiti Minimi

33- Extensor Carpi Ulnaris

34- Supinator

35- Abductor Pollicis Longus

36- Extensor Pollicis Brevis

37- Extensor Pollicis Longus

38- Extensor Indicis Proprius

39- Opponens Pollicis

40- Abductor Pollicis Brevis

41- Flexor Pollicis Brevis

42- Adductor Pollicis

43- Palmaris Brevis

44- Abductor Digiti Minimi

45- Flexor Digiti Minimi Brevis

46- Opponens Digiti Minimi

47- Dorsal Interossei

48- Palmar Interossei

49- Lumbrical Muscles

50- Brachial Plexus

51- Psoas

52- Iliacus

53- Sartorius

54- Pectineus

55- Rectus Femoris

56- Vastus Lateralis

57- Vastus Intermedius

58- Vastus Medialis

59- Gluteus Maximus

60- Gluteus Medius

61- Gluteus Minimus

62- Tensor Fascia Lata

63- Adductor Longus

64- Adductor Brevis

65- Adductor Magnus

66- Gracilis

67- Semitendinosus

68- Semimembranosus

69- Biceps Femoris Long Head

70- Biceps Femoris Short Head

71- Piriformis

72- Obturator Externus

73- Obturator Internus

74- Superior Gemellus

75- Inferior Gemellus

76- Quadratus Femoris

77- Tibialis Anterior

78- Extensor Digitorum Longus

79- Extensor Hallucis Longus L5

80- Peroneus Tertius

81- Peroneus Longus

82- Peroneus Brevis

83- Gastrocnemius

84- Soleus

85- Plantaris

86- Popliteus

87- Tibialis Posterior

88- Flexor Digitorum Longus

89- Flexor Hallucis Longus

90- Abductor Hallucis

91- Flexor Digitorum Brevis

92- Abductor Digiti Minimi

93- Quadratus Plantae

94- Lumbricals

95- Flexor Hallucis Brevis

96- Adductor Hallucis

97- Flexor Digiti Minimi Brevis

98- Plantar Interossei

99- Dorsal Interossei Lpn

100- Musculocutaneous Nerve

101- Radial Nerve

102- Posterior Interosseous Nerve

103- Superficial Radial Nerve

104- Median Nerve

105- Anterior Interosseous Nerve

106- Ulnar Nerve

107- Lateral Antebrachial Cut Nerve

108- Lumbosacral Plexus

109- Femoral Nerve

110- Obturator Nerve

111- Superior Gluteal Nerve

112- Inferior Gluteal Nerve

113- Sciatic Nerve

114- Tibial Nerve

115- Deep Peroneal Nerve

116- Quadrangular Space Triangular Space Triangular Interval

117- Posterior Approach To Knee

118- Compartments Of Leg

119- Extensor Digitorum And Hallucis Brevis

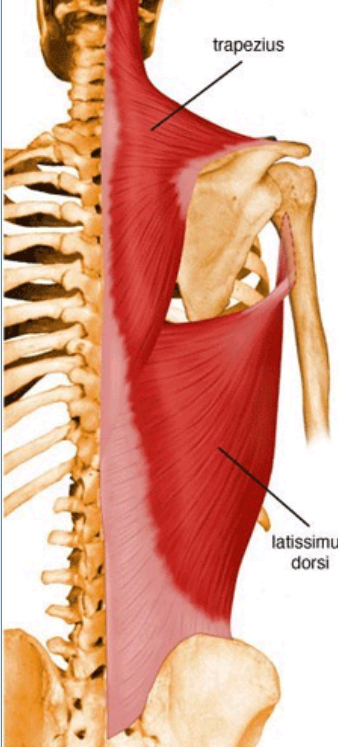
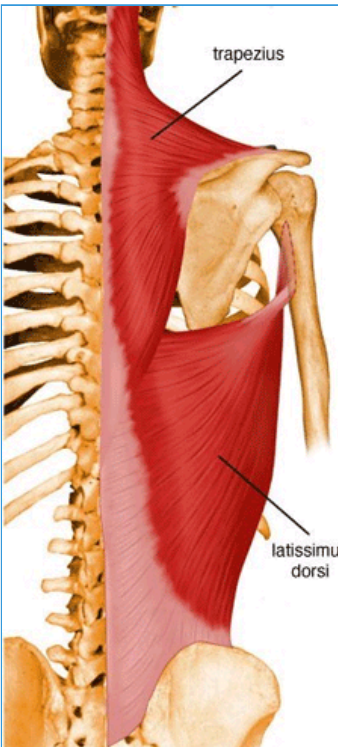
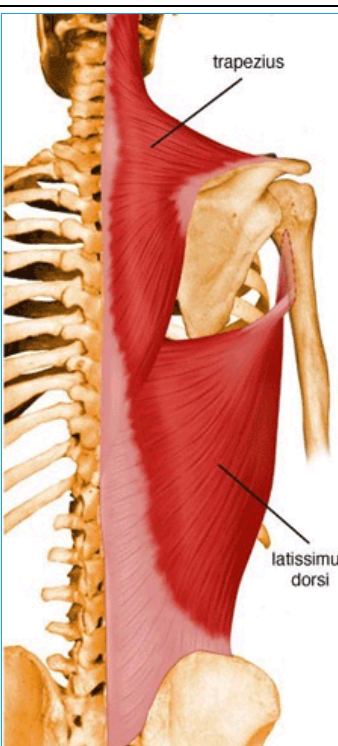

120- Long Thoracic Nerve

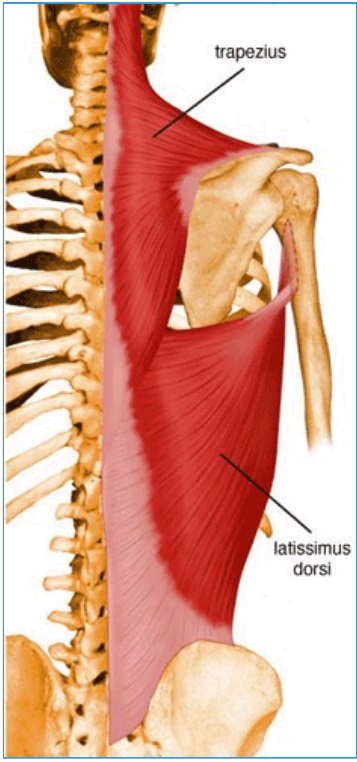
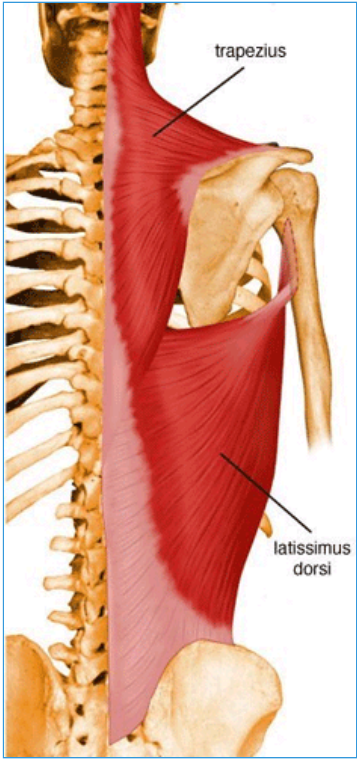
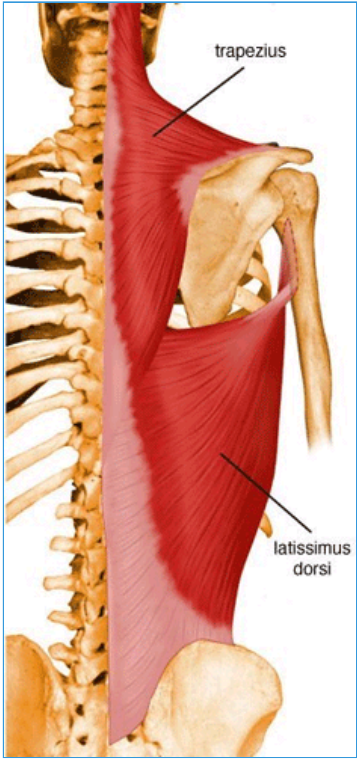

121- Axillary Nerve

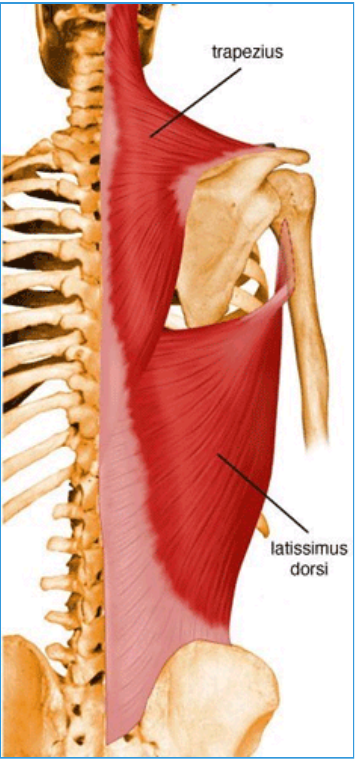
122- Superficial Peroneal Nerve

1- Trapezius

- Summary

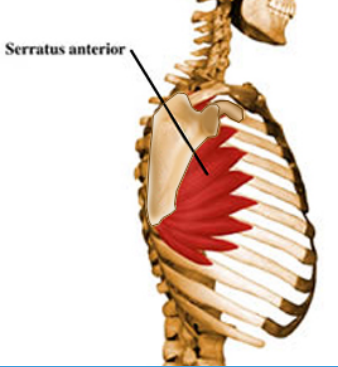
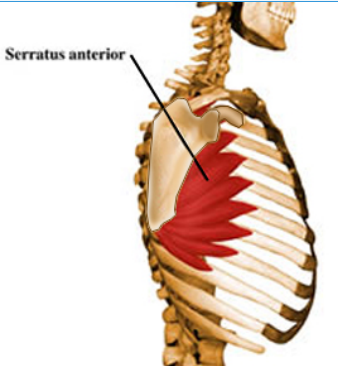
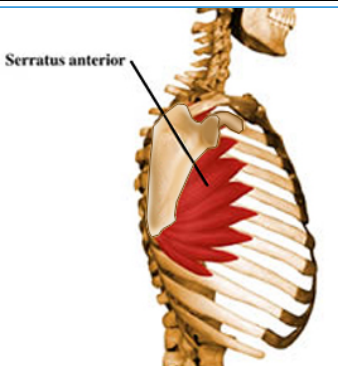
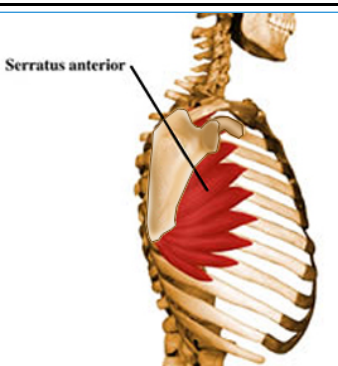
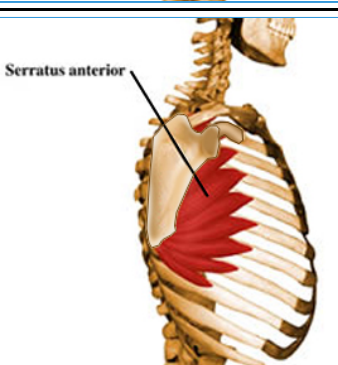
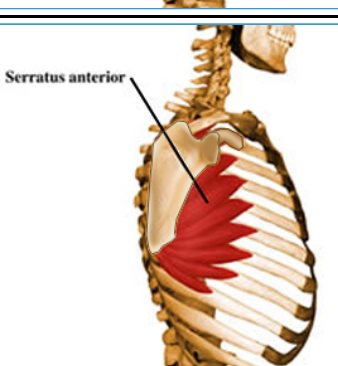
<ul style="list-style-type: none"> <ul style="list-style-type: none"> ■ Trapezius 		<ul style="list-style-type: none"> <ul style="list-style-type: none"> ■ 
<ul style="list-style-type: none"> <ul style="list-style-type: none"> ■ Origin 	<ul style="list-style-type: none"> <ul style="list-style-type: none"> ■ Medial third of superior nuchal line; external occipital protuberance, nuchal ligament, and spinous processes of C7 - T12 vertebrae 	<ul style="list-style-type: none"> <ul style="list-style-type: none"> ■ 
<ul style="list-style-type: none"> <ul style="list-style-type: none"> ■ Insertion 	<ul style="list-style-type: none"> <ul style="list-style-type: none"> ■ Lateral third of clavicle, acromion, and spine of scapula 	<ul style="list-style-type: none"> <ul style="list-style-type: none"> ■ 
<ul style="list-style-type: none"> <ul style="list-style-type: none"> ■ Action 	<ul style="list-style-type: none"> <ul style="list-style-type: none"> ■ Elevates retracts, and rotates scapula ; superior fibers elevate, middle fibers retract, and inferior fibers depress scapula; superior and inferior fibers act together in superior rotation of scapula 	<ul style="list-style-type: none"> <ul style="list-style-type: none"> ■ 
<ul style="list-style-type: none"> <ul style="list-style-type: none"> ■ Innervation 		<ul style="list-style-type: none"> <ul style="list-style-type: none"> ■

	<ul style="list-style-type: none"> Spinal root of the accessory nerve (CN XI) (motor) and cervical nerves (C3 and C4) (pain and proprioception) (XI, C3, C4) 	
<ul style="list-style-type: none"> Arterial Supply 	<ul style="list-style-type: none"> Transverse cervical artery 	<ul style="list-style-type: none"> 
<ul style="list-style-type: none"> Relevant Approaches 	<ul style="list-style-type: none"> Posterolateral (Costotransversectomy) Approach to Thoracic Spine 	<ul style="list-style-type: none"> 
<ul style="list-style-type: none"> Relevant Conditions 	<ul style="list-style-type: none"> Lateral Scapular Winging 	<ul style="list-style-type: none"> 



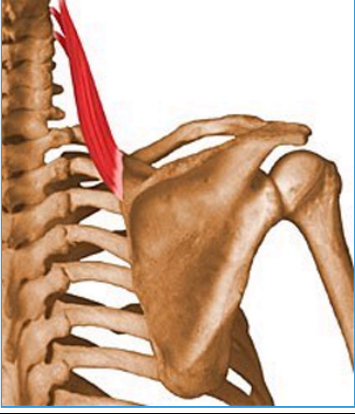
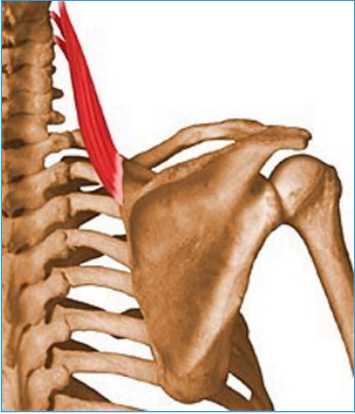
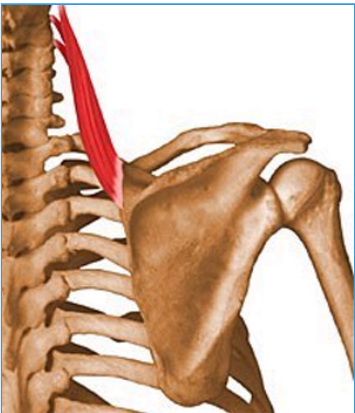
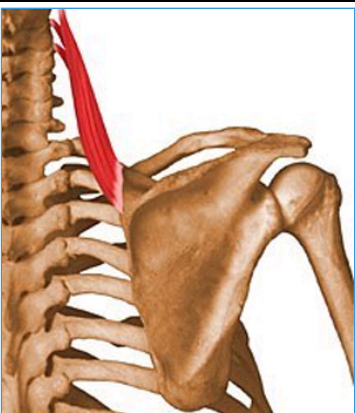
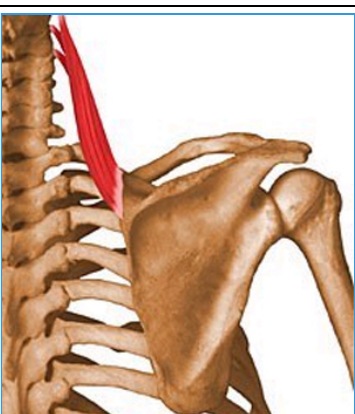
2- Serratus

- Summary

<ul style="list-style-type: none"> <ul style="list-style-type: none"> ■ Serratus 		
<ul style="list-style-type: none"> <ul style="list-style-type: none"> ■ Origin 	<ul style="list-style-type: none"> <ul style="list-style-type: none"> <ul style="list-style-type: none"> ■ Superolateral surfaces of upper 8 or 9 ribs at the side of chest 	<ul style="list-style-type: none"> <ul style="list-style-type: none"> <ul style="list-style-type: none"> ■ 
<ul style="list-style-type: none"> <ul style="list-style-type: none"> ■ Insertion 	<ul style="list-style-type: none"> <ul style="list-style-type: none"> <ul style="list-style-type: none"> ■ Vertebral border of scapula 	<ul style="list-style-type: none"> <ul style="list-style-type: none"> <ul style="list-style-type: none"> ■ 
<ul style="list-style-type: none"> <ul style="list-style-type: none"> ■ Action 	<ul style="list-style-type: none"> <ul style="list-style-type: none"> <ul style="list-style-type: none"> ■ Draws scapula forward and upward; abducts scapula and rotates it; stabilizes vertebral border of scapula 	<ul style="list-style-type: none"> <ul style="list-style-type: none"> <ul style="list-style-type: none"> ■ 
<ul style="list-style-type: none"> <ul style="list-style-type: none"> ■ Innervation 	<ul style="list-style-type: none"> <ul style="list-style-type: none"> <ul style="list-style-type: none"> ■ Long thoracic nerve (C5, C6, C7) 	<ul style="list-style-type: none"> <ul style="list-style-type: none"> <ul style="list-style-type: none"> ■ 
<ul style="list-style-type: none"> <ul style="list-style-type: none"> ■ Arterial Supply 	<ul style="list-style-type: none"> <ul style="list-style-type: none"> <ul style="list-style-type: none"> ■ Circumflex scapular artery 	<ul style="list-style-type: none"> <ul style="list-style-type: none"> <ul style="list-style-type: none"> ■ 
<ul style="list-style-type: none"> <ul style="list-style-type: none"> ■ Clinical Conditions 	<ul style="list-style-type: none"> <ul style="list-style-type: none"> <ul style="list-style-type: none"> ■ Medial scapular Winging 	<ul style="list-style-type: none"> <ul style="list-style-type: none"> <ul style="list-style-type: none"> ■ 

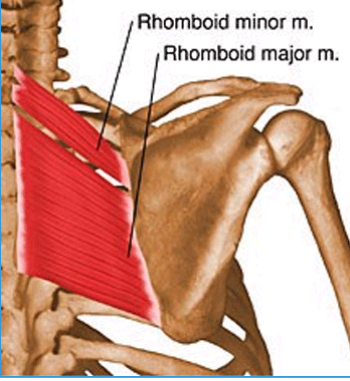
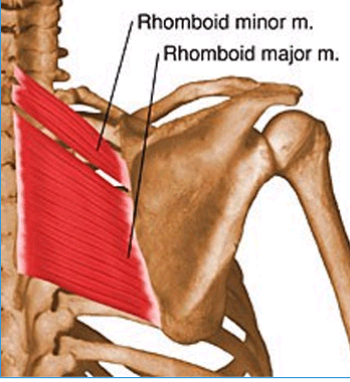
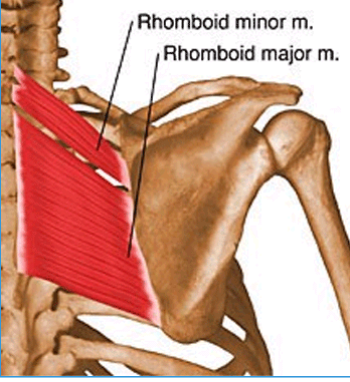
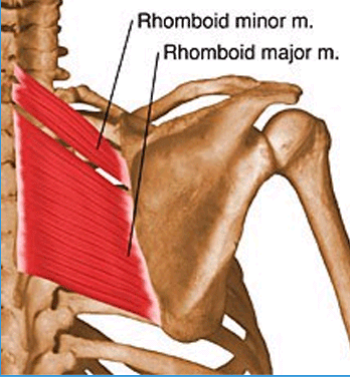
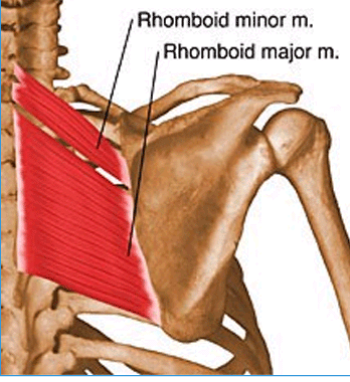
3- Levator Scapulae

- Summary

<ul style="list-style-type: none"> Levator Scapulae 		
<ul style="list-style-type: none"> Origin 	<ul style="list-style-type: none"> Posterior tubercles of transverse processes of C1 - C4 vertebrae 	
<ul style="list-style-type: none"> Insertion 	<ul style="list-style-type: none"> Superior part of medial border of scapula 	
<ul style="list-style-type: none"> Action 	<ul style="list-style-type: none"> Elevates scapula and tilts its glenoid cavity inferiorly by rotating scapula 	
<ul style="list-style-type: none"> Innervation 	<ul style="list-style-type: none"> Dorsal scapular nerve (C5) 	
<ul style="list-style-type: none"> Arterial Supply 	<ul style="list-style-type: none"> Dorsal scapular artery 	

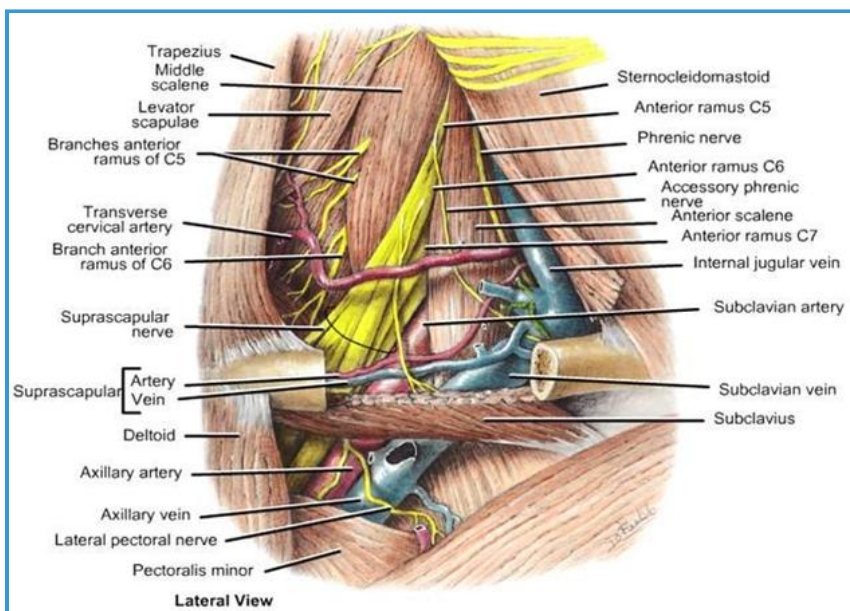
4- Rhomboid Minor And Major

- Summary

<ul style="list-style-type: none"> <ul style="list-style-type: none"> ■ Rhomboid Minor and Major 		
<ul style="list-style-type: none"> <ul style="list-style-type: none"> ■ Origin 	<ul style="list-style-type: none"> <ul style="list-style-type: none"> <ul style="list-style-type: none"> ■ Minor: nuchal ligament and spinous processes of C7 and T1 vertebrae; ■ Major: spinous processes of T2 - T5 vertebrae 	<ul style="list-style-type: none"> <ul style="list-style-type: none"> <ul style="list-style-type: none"> ■ 
<ul style="list-style-type: none"> <ul style="list-style-type: none"> ■ Insertion 	<ul style="list-style-type: none"> <ul style="list-style-type: none"> ■ Medial border of scapula from level of spine to inferior angle 	<ul style="list-style-type: none"> <ul style="list-style-type: none"> <ul style="list-style-type: none"> ■ 
<ul style="list-style-type: none"> <ul style="list-style-type: none"> ■ Action 	<ul style="list-style-type: none"> <ul style="list-style-type: none"> ■ Retract scapula and rotate it to depress glenoid cavity; fix scapula to thoracic wall. 	<ul style="list-style-type: none"> <ul style="list-style-type: none"> <ul style="list-style-type: none"> ■ 
<ul style="list-style-type: none"> <ul style="list-style-type: none"> ■ Innervation 	<ul style="list-style-type: none"> <ul style="list-style-type: none"> ■ Dorsal scapular nerve (C4 and C5) 	<ul style="list-style-type: none"> <ul style="list-style-type: none"> <ul style="list-style-type: none"> ■ 
<ul style="list-style-type: none"> <ul style="list-style-type: none"> ■ Arterial Supply 	<ul style="list-style-type: none"> <ul style="list-style-type: none"> ■ Dorsal scapular artery 	<ul style="list-style-type: none"> <ul style="list-style-type: none"> <ul style="list-style-type: none"> ■ 

5- Scalene

Images

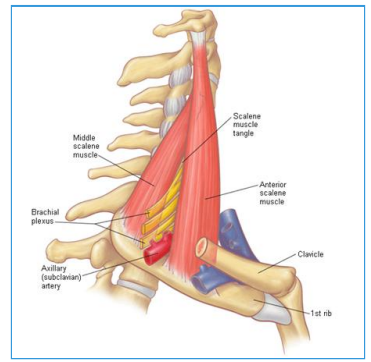


Summary

<ul style="list-style-type: none"> Scalene 		
<ul style="list-style-type: none"> Origin 	<ul style="list-style-type: none"> Transverse process of C2 to C7 	
<ul style="list-style-type: none"> Insertion 	<ul style="list-style-type: none"> Anterior and medial scalene insert on first rib. Posterior scalene inserts on second rib. 	
<ul style="list-style-type: none"> Action 	<ul style="list-style-type: none"> Anterior and medial scalene elevate first rib and flexes neck to same side. Posterior scalene elevates second rib and flexes neck to same side. 	
<ul style="list-style-type: none"> Innervation 	<ul style="list-style-type: none"> Anterior branches of the cervical spinal nerves (C3-C8) 	

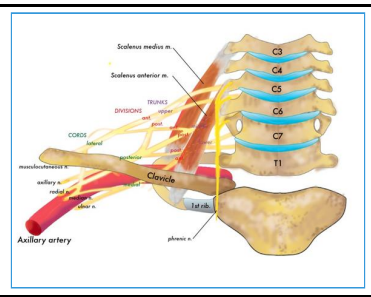
--

--



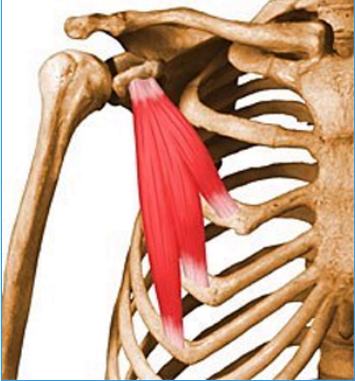


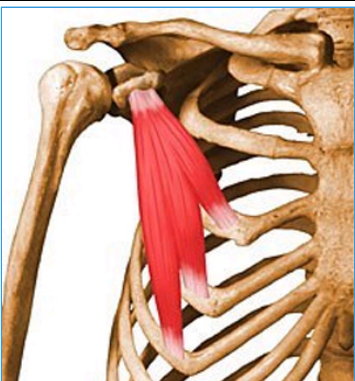

<ul style="list-style-type: none">■ Arterial Supply
--

<ul style="list-style-type: none">■ Ascending cervical artery (branch of the thyrocervical trunk)



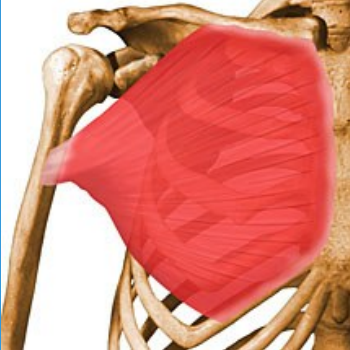
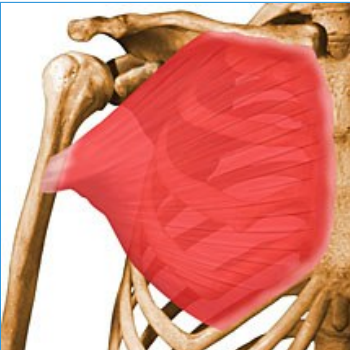
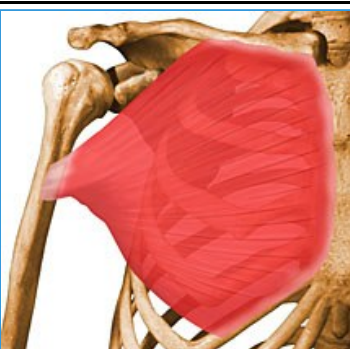
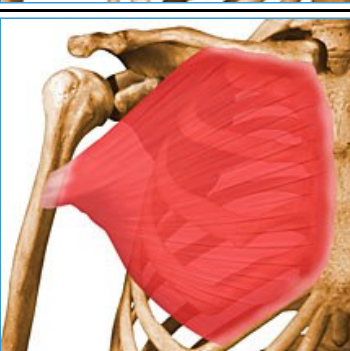
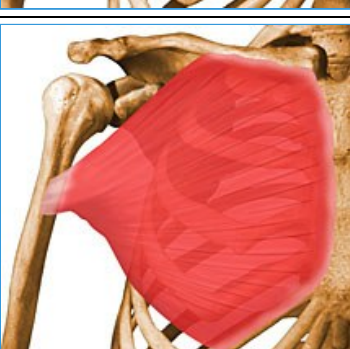
6- Pectoralis Minor

- Summary

<ul style="list-style-type: none">○ ■ Pectoralis Minor		
<ul style="list-style-type: none">■ Origin	<ul style="list-style-type: none">■ 3rd to 5th ribs near their costal cartilages	<ul style="list-style-type: none">■ 
<ul style="list-style-type: none">■ Insertion	<ul style="list-style-type: none">■ Medial border and superior surface of coracoid process of scapula	<ul style="list-style-type: none">■ 
<ul style="list-style-type: none">■ Action	<ul style="list-style-type: none">■ Stabilizes scapula by drawing it inferiorly and anteriorly against thoracic wall	<ul style="list-style-type: none">■ 
<ul style="list-style-type: none">■ Innervation	<ul style="list-style-type: none">■ Medial pectoral nerves (C8 and T1)	<ul style="list-style-type: none">■ 
<ul style="list-style-type: none">■ Arterial Supply	<ul style="list-style-type: none">■ Pectoral branch of the thoracoacromial trunk	<ul style="list-style-type: none">■ 

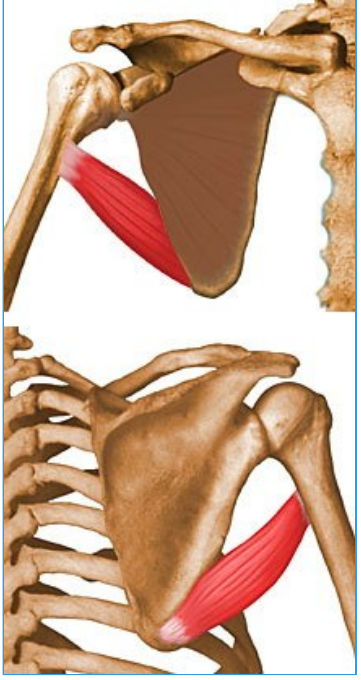
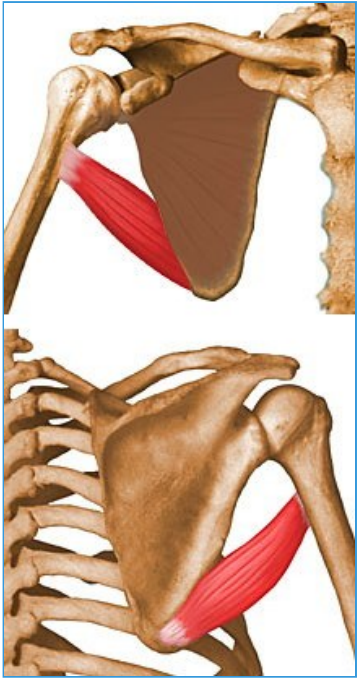
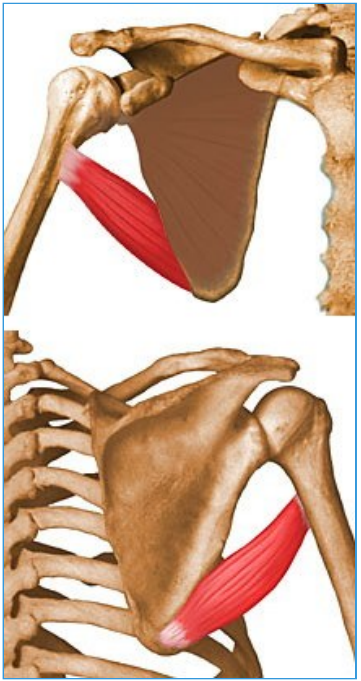

7- Pectoralis Major

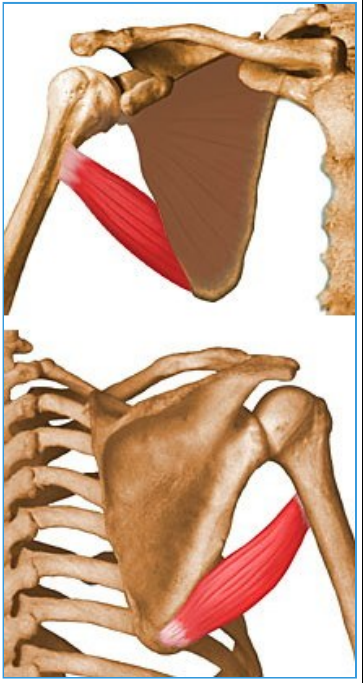
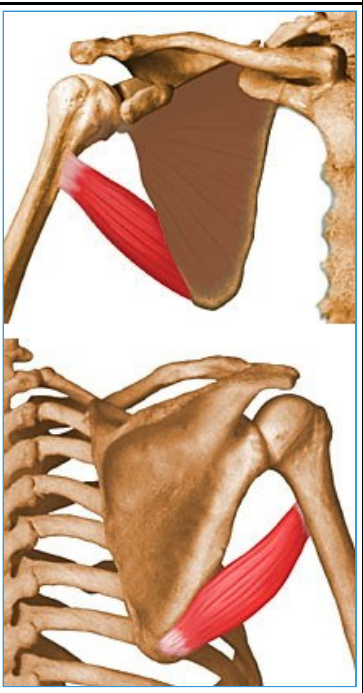
- Summary

<ul style="list-style-type: none">○ ■ Pectoralis Major		
■ Origin	<ul style="list-style-type: none">■ Clavicular head<ul style="list-style-type: none">■ anterior surface of medial half of clavicle■ Sternocostal head<ul style="list-style-type: none">■ anterior surface of sternum, superior six costal cartilages, and aponeurosis of external oblique muscle	<ul style="list-style-type: none">■ 
■ Insertion	<ul style="list-style-type: none">■ Lateral lip of intertubercular groove of humerus	<ul style="list-style-type: none">■ 
■ Action	<ul style="list-style-type: none">■ Adducts and medially rotates humerus■ Draws scapula anteriorly and inferiorly■ Acting alone: clavicular head flexes humerus and sternocostal head extends it	<ul style="list-style-type: none">■ 
■ Innervation	<ul style="list-style-type: none">■ Lateral and medial pectoral nerves (C5-T1)	<ul style="list-style-type: none">■ 
■ Arterial Supply	<ul style="list-style-type: none">■ Pectoral branch of the thoracoacromial trunk	<ul style="list-style-type: none">■ 

8- Teres Major

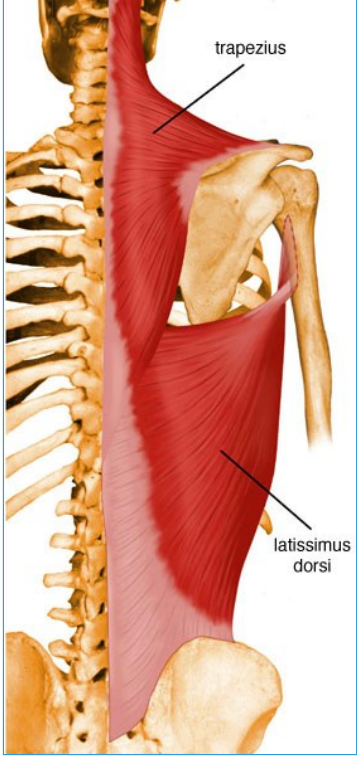
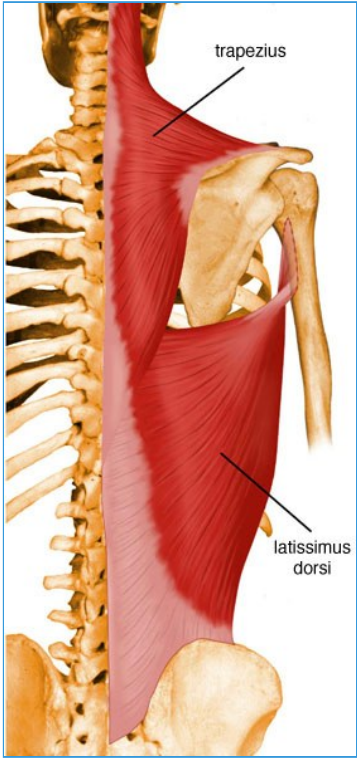
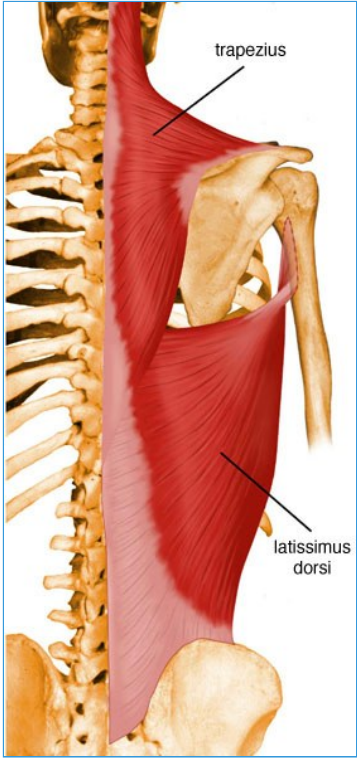

- ANATOMY

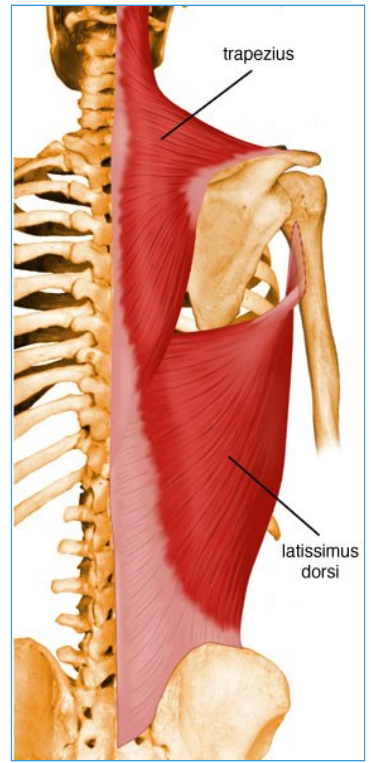
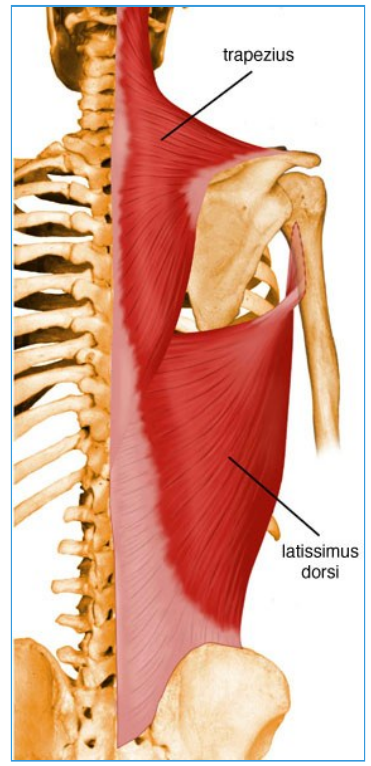
<ul style="list-style-type: none">o ■ Teres Major		
<ul style="list-style-type: none">■ Origin	<ul style="list-style-type: none">■ Dorsal surface of inferior angle of scapula	<ul style="list-style-type: none">■ 
<ul style="list-style-type: none">■ Insertion	<ul style="list-style-type: none">■ Medial lip of intertubercular groove of humerus	<ul style="list-style-type: none">■ 
<ul style="list-style-type: none">■ Action	<ul style="list-style-type: none">■ Adducts and medially rotates arm	<ul style="list-style-type: none">■ 
<ul style="list-style-type: none">■ Innervation	<ul style="list-style-type: none">■ Lower subscapular nerve (C6, C7)	<ul style="list-style-type: none">■ 

		
<ul style="list-style-type: none">■ Arterial supply	<ul style="list-style-type: none">■ Subscapular and circumflex scapular arteries	<ul style="list-style-type: none">■ 

9- Latissimus Dorsi

- ANATOMY

<ul style="list-style-type: none"> <ul style="list-style-type: none"> Latissimus Dorsi 	<ul style="list-style-type: none"> <ul style="list-style-type: none"> <ul style="list-style-type: none"> Origin 	<ul style="list-style-type: none"> <ul style="list-style-type: none"> <ul style="list-style-type: none"> <ul style="list-style-type: none"> 
<ul style="list-style-type: none"> <ul style="list-style-type: none"> <ul style="list-style-type: none"> Insertion 	<ul style="list-style-type: none"> <ul style="list-style-type: none"> <ul style="list-style-type: none"> <ul style="list-style-type: none"> Floor of intertubercular groove of humerus 	<ul style="list-style-type: none"> <ul style="list-style-type: none"> <ul style="list-style-type: none"> <ul style="list-style-type: none"> 
<ul style="list-style-type: none"> <ul style="list-style-type: none"> <ul style="list-style-type: none"> Action 	<ul style="list-style-type: none"> <ul style="list-style-type: none"> <ul style="list-style-type: none"> <ul style="list-style-type: none"> Extends, adducts, and medially rotates humerus; raises body toward arms during climbing 	<ul style="list-style-type: none"> <ul style="list-style-type: none"> <ul style="list-style-type: none"> <ul style="list-style-type: none"> 
<ul style="list-style-type: none"> <ul style="list-style-type: none"> <ul style="list-style-type: none"> Innervation 	<ul style="list-style-type: none"> <ul style="list-style-type: none"> <ul style="list-style-type: none"> <ul style="list-style-type: none"> Thoracodorsal nerve (C6, C7, C8) 	<ul style="list-style-type: none"> <ul style="list-style-type: none"> <ul style="list-style-type: none"> <ul style="list-style-type: none"> 

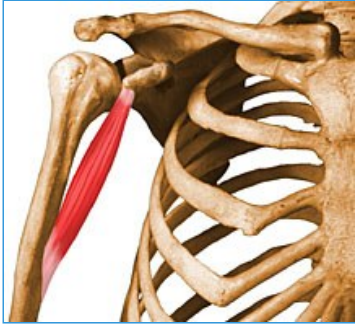






- **Arterial supply**

- Thoracodorsal artery

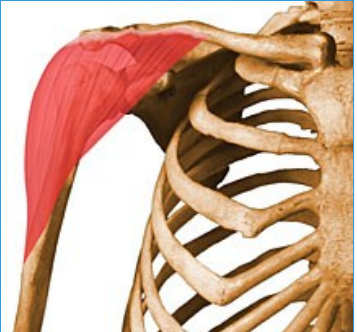
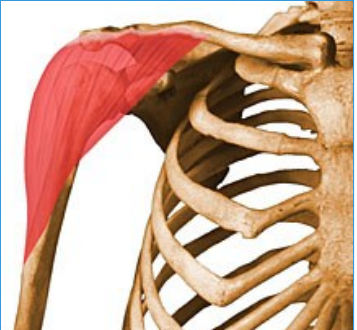



10- Coracobrachialis

- Summary

○ ■ Coracobrachialis		
■ Origin	■ Tip of coracoid process of scapula	■ 
■ Insertion	■ Middle third of medial surface of humerus	■ 
■ Action	■ Helps to flex and adduct arm	■ 
■ Innervation	■ Musculocutaneous nerve (C5, C6, C7)	■ 
■ Arterial supply	■ Muscular branches of brachial artery	■ 



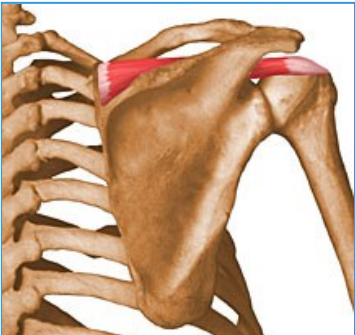
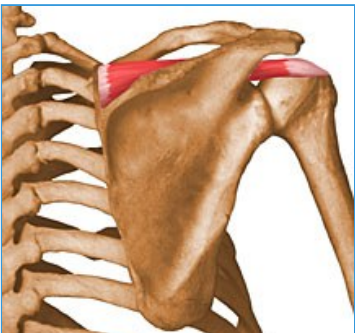
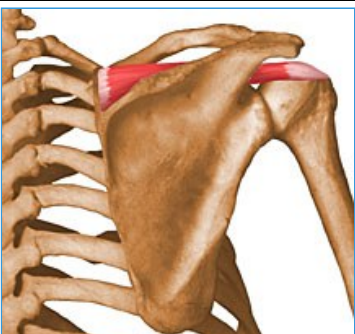
11- Deltoid

- Summary

<ul style="list-style-type: none"> <ul style="list-style-type: none"> ■ Deltoid 		
<ul style="list-style-type: none"> <ul style="list-style-type: none"> ■ Origin 	<ul style="list-style-type: none"> <ul style="list-style-type: none"> ■ Lateral third of clavicle, acromion, and spine of scapula 	<ul style="list-style-type: none"> <ul style="list-style-type: none"> ■ 
<ul style="list-style-type: none"> <ul style="list-style-type: none"> ■ Insertion 	<ul style="list-style-type: none"> <ul style="list-style-type: none"> ■ Deltoid tuberosity of humerus 	<ul style="list-style-type: none"> <ul style="list-style-type: none"> ■ 
<ul style="list-style-type: none"> <ul style="list-style-type: none"> ■ Action 	<ul style="list-style-type: none"> <ul style="list-style-type: none"> ■ Anterior part: flexes and medially rotates arm; ■ Middle part: abducts arm; ■ Posterior part: extends and laterally rotates arm 	<ul style="list-style-type: none"> <ul style="list-style-type: none"> ■ 
<ul style="list-style-type: none"> <ul style="list-style-type: none"> ■ Innervation 	<ul style="list-style-type: none"> <ul style="list-style-type: none"> ■ Axillary nerve (C5, C6) 	<ul style="list-style-type: none"> <ul style="list-style-type: none"> ■ 
<ul style="list-style-type: none"> <ul style="list-style-type: none"> ■ Arterial Supply 	<ul style="list-style-type: none"> <ul style="list-style-type: none"> ■ Deltoid branch of thoracoacromial artery 	<ul style="list-style-type: none"> <ul style="list-style-type: none"> ■ 




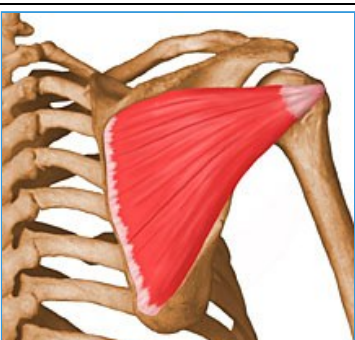
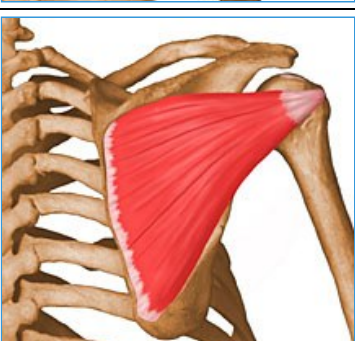
12- Supraspinatus

- Summary

<ul style="list-style-type: none"> Supraspinatus 		
<ul style="list-style-type: none"> Origin 	<ul style="list-style-type: none"> Supraspinous fossa of scapula 	<ul style="list-style-type: none"> 
<ul style="list-style-type: none"> Insertion 	<ul style="list-style-type: none"> Superior facet on greater tuberosity of humerus 	<ul style="list-style-type: none"> 
<ul style="list-style-type: none"> Action 	<ul style="list-style-type: none"> Initiates and assists deltoid in abduction of arm and acts with other rotator cuff muscles 	<ul style="list-style-type: none"> 
<ul style="list-style-type: none"> Innervation 	<ul style="list-style-type: none"> Suprascapular nerve (C4, C5, C6) 	<ul style="list-style-type: none"> 
<ul style="list-style-type: none"> Arterial Supply 	<ul style="list-style-type: none"> Suprascapular artery 	<ul style="list-style-type: none"> 


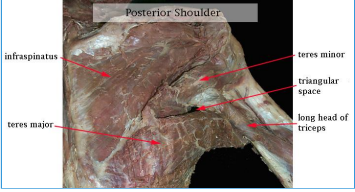

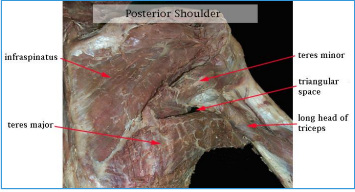

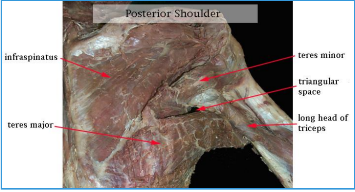
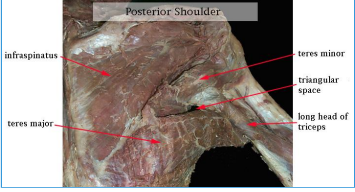
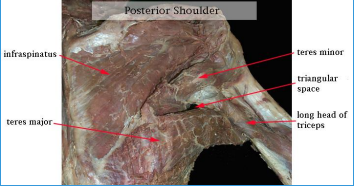
13- Infraspinatus

- Summary

■ Infraspinatus		
■ Origin	■ infraspinous fossa of scapula	■ 
■ Insertion	■ Middle facet on greater tuberosity of humerus	■ 
■ Action	■ Laterally rotate arm; helps to hold humeral head in glenoid cavity of scapula	■ 
■ Innervation	■ Suprascapular nerve (C5, C6)	■ 
■ Arterial supply	■ Suprascapular and circumflex scapular arteries	■ 






14- Teres Minor

- Summary

<ul style="list-style-type: none"> <ul style="list-style-type: none"> ■ Teres Minor 		
<ul style="list-style-type: none"> <ul style="list-style-type: none"> ■ Origin 	<ul style="list-style-type: none"> <ul style="list-style-type: none"> ■ Superior part of lateral border of scapula 	<ul style="list-style-type: none">  
<ul style="list-style-type: none"> <ul style="list-style-type: none"> ■ Insertion 	<ul style="list-style-type: none"> <ul style="list-style-type: none"> ■ Inferior facet on greater tuberosity of humerus 	<ul style="list-style-type: none">  
<ul style="list-style-type: none"> <ul style="list-style-type: none"> ■ Action 	<ul style="list-style-type: none"> <ul style="list-style-type: none"> ■ Laterally rotate arm; helps to hold humeral head in glenoid cavity of scapula 	<ul style="list-style-type: none">  
<ul style="list-style-type: none"> <ul style="list-style-type: none"> ■ Innervation 	<ul style="list-style-type: none"> <ul style="list-style-type: none"> ■ Axillary nerve (C5, C6) 	<ul style="list-style-type: none"> 
<ul style="list-style-type: none"> <ul style="list-style-type: none"> ■ Arterial Supply 	<ul style="list-style-type: none"> <ul style="list-style-type: none"> ■ Subscapular and circumflex scapular arteries 	<ul style="list-style-type: none"> 





15- Subscapularis

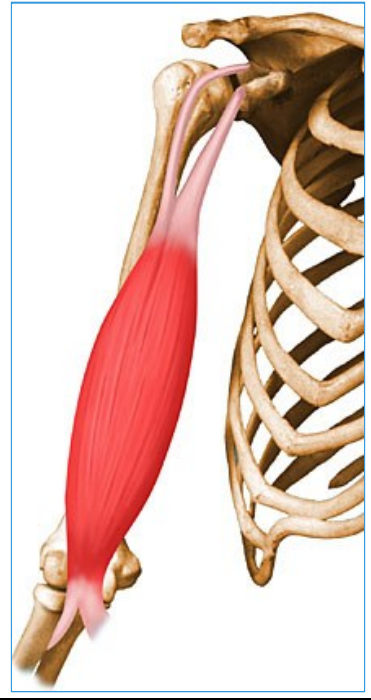
- Summary

<ul style="list-style-type: none"> <ul style="list-style-type: none"> Subscapularis 		
<ul style="list-style-type: none"> <ul style="list-style-type: none"> Origin 	<ul style="list-style-type: none"> <ul style="list-style-type: none"> Subscapular fossa of scapula 	<ul style="list-style-type: none"> <ul style="list-style-type: none"> 
<ul style="list-style-type: none"> <ul style="list-style-type: none"> Insertion 	<ul style="list-style-type: none"> <ul style="list-style-type: none"> Lesser tuberosity of humerus 	<ul style="list-style-type: none"> <ul style="list-style-type: none"> 
<ul style="list-style-type: none"> <ul style="list-style-type: none"> Action 	<ul style="list-style-type: none"> <ul style="list-style-type: none"> Medially rotates arm and adducts it; helps to hold humeral head in glenoid cavity of scapula 	<ul style="list-style-type: none"> <ul style="list-style-type: none"> 
<ul style="list-style-type: none"> <ul style="list-style-type: none"> Innervation 	<ul style="list-style-type: none"> <ul style="list-style-type: none"> Upper and lower subscapular nerves (C5, C6, C7) 	<ul style="list-style-type: none"> <ul style="list-style-type: none"> 
<ul style="list-style-type: none"> <ul style="list-style-type: none"> Arterial Supply 	<ul style="list-style-type: none"> <ul style="list-style-type: none"> Subscapular artery 	<ul style="list-style-type: none"> <ul style="list-style-type: none"> 

16- Biceps Brachii

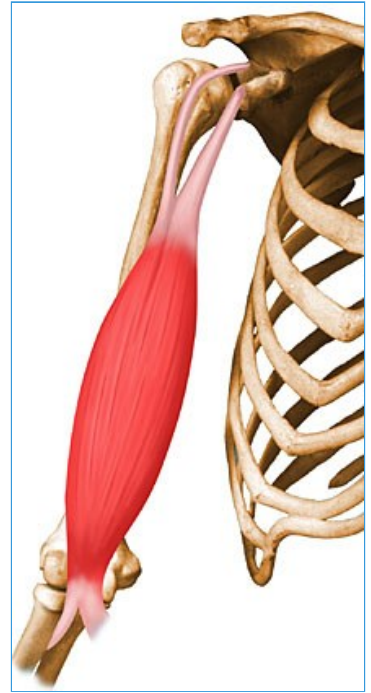
- Summary

<ul style="list-style-type: none"> <ul style="list-style-type: none"> ■ Biceps Brachii 		
<ul style="list-style-type: none"> <ul style="list-style-type: none"> ■ Origin 	<ul style="list-style-type: none"> <ul style="list-style-type: none"> <ul style="list-style-type: none"> ■ Short head: tip of coracoid process of scapula; ■ Long head: supraglenoid tubercle of scapula 	<ul style="list-style-type: none"> <ul style="list-style-type: none"> <ul style="list-style-type: none"> ■ 
<ul style="list-style-type: none"> <ul style="list-style-type: none"> ■ Insertion 	<ul style="list-style-type: none"> <ul style="list-style-type: none"> <ul style="list-style-type: none"> ■ Tuberosity of radius and fascia of forearm via a bicipital aponeurosis 	<ul style="list-style-type: none"> <ul style="list-style-type: none"> <ul style="list-style-type: none"> ■ 
<ul style="list-style-type: none"> <ul style="list-style-type: none"> ■ Action 	<ul style="list-style-type: none"> <ul style="list-style-type: none"> <ul style="list-style-type: none"> ■ Supinates and flexes forearm 	<ul style="list-style-type: none"> <ul style="list-style-type: none"> <ul style="list-style-type: none"> ■ 
<ul style="list-style-type: none"> <ul style="list-style-type: none"> ■ Innervation 	<ul style="list-style-type: none"> <ul style="list-style-type: none"> <ul style="list-style-type: none"> ■ Musculocutaneous nerve (C5,C6) 	<ul style="list-style-type: none"> <ul style="list-style-type: none"> <ul style="list-style-type: none"> ■ 







- **Arterial Supply**



- Muscular branches of brachial artery



17- Brachialis

- Summary

<ul style="list-style-type: none"> Brachialis 		
<ul style="list-style-type: none"> Origin 	<ul style="list-style-type: none"> Distal half of anterior surface of humerus 	<ul style="list-style-type: none"> 
<ul style="list-style-type: none"> Insertion 	<ul style="list-style-type: none"> Coronoid process and tuberosity of ulna 	<ul style="list-style-type: none"> 
<ul style="list-style-type: none"> Action 	<ul style="list-style-type: none"> Major flexor of forearm -- flexes forearm in all positions 	<ul style="list-style-type: none"> 
<ul style="list-style-type: none"> Innervation 	<ul style="list-style-type: none"> Medial half: Musculocutaneous nerve (C5,C6) Lateral half: Radial nerve (C5,C6,C7) 	<ul style="list-style-type: none"> 

		
<ul style="list-style-type: none">■ Arterial Supply	<ul style="list-style-type: none">■ Muscular branches of brachial artery, recurrent radial artery	<ul style="list-style-type: none">■ 

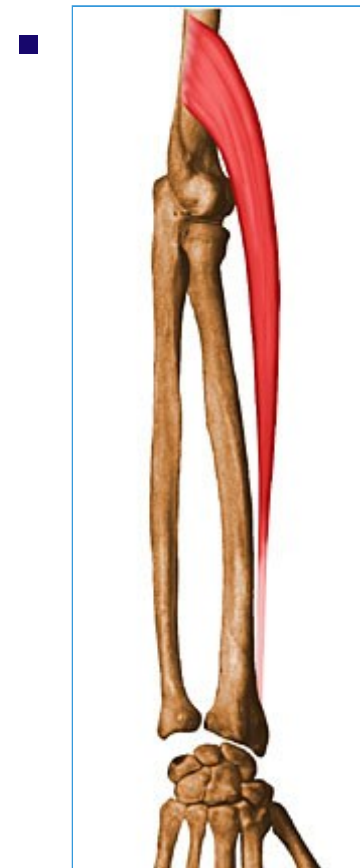
18- Brachioradialis

- Summary

- ■ Brachioradialis

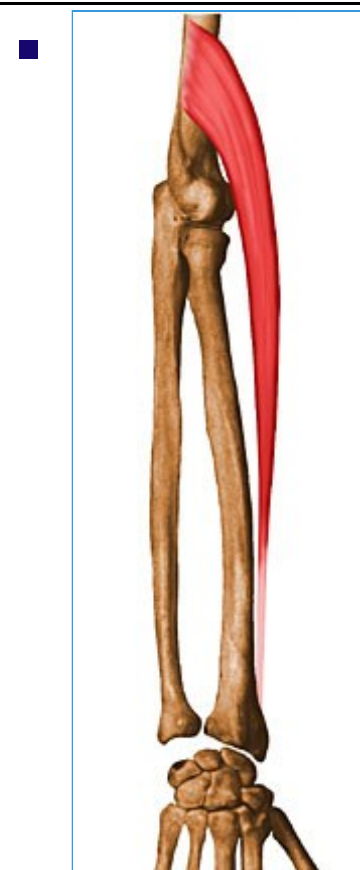
- **Origin**

- Proximal 2/3 of lateral supracondylar ridge of humerus



- **Insertion**




- Base of radial styloid



- **Action**






- Flexes forearm

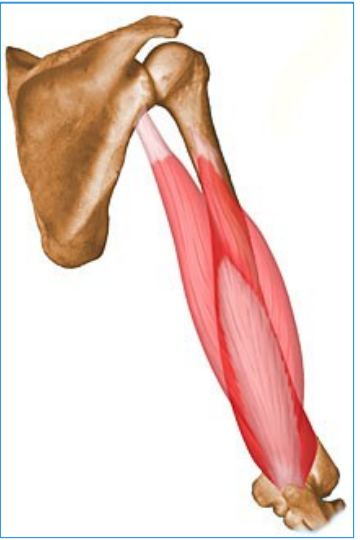

		
<ul style="list-style-type: none">■ Innervation	<ul style="list-style-type: none">■ Radial nerve (C5,C6, C7)	<ul style="list-style-type: none">■ 
<ul style="list-style-type: none">■ Arterial Supply	<ul style="list-style-type: none">■ Radial recurrent artery	<ul style="list-style-type: none">■ 

19- Triceps Brachii





- Summary

<ul style="list-style-type: none"> <ul style="list-style-type: none"> Triceps Brachii 		
<ul style="list-style-type: none"> <ul style="list-style-type: none"> Origin 	<ul style="list-style-type: none"> <ul style="list-style-type: none"> <ul style="list-style-type: none"> Long head: infraglenoid tubercle of scapula; Lateral head: posterior surface of humerus, superior to radial groove; Medial head: posterior surface of humerus, inferior to radial groove 	<ul style="list-style-type: none"> 
<ul style="list-style-type: none"> <ul style="list-style-type: none"> Insertion 	<ul style="list-style-type: none"> <ul style="list-style-type: none"> <ul style="list-style-type: none"> Proximal end of olecranon process of ulna and fascia of forearm 	<ul style="list-style-type: none"> 
<ul style="list-style-type: none"> <ul style="list-style-type: none"> Action 	<ul style="list-style-type: none"> <ul style="list-style-type: none"> <ul style="list-style-type: none"> Chief extensor of forearm; long head steadies head of abducted humerus 	<ul style="list-style-type: none"> 
<ul style="list-style-type: none"> <ul style="list-style-type: none"> Innervation 	<ul style="list-style-type: none"> <ul style="list-style-type: none"> <ul style="list-style-type: none"> Radial nerve (C6, C7, C8) 	<ul style="list-style-type: none"> 
<ul style="list-style-type: none"> <ul style="list-style-type: none"> Arterial supply 	<ul style="list-style-type: none"> <ul style="list-style-type: none"> <ul style="list-style-type: none"> Branches of deep brachial artery 	<ul style="list-style-type: none"> 



20- Pronator Teres

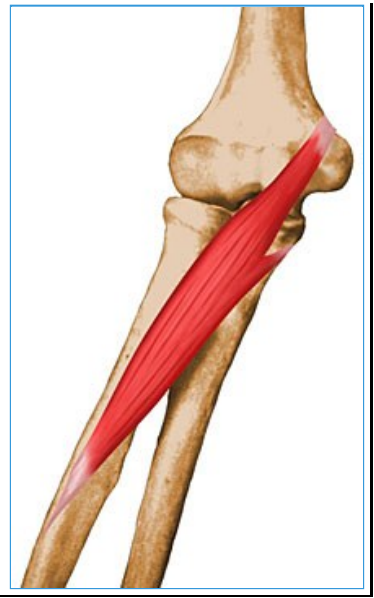- Summary

<ul style="list-style-type: none">○ Pronator Teres		
<ul style="list-style-type: none">■ Origin	<ul style="list-style-type: none">■ Medial epicondyle of humerus and coronoid process of ulna	<ul style="list-style-type: none">■ 
<ul style="list-style-type: none">■ Insertion	<ul style="list-style-type: none">■ Middle of lateral surface of radius	<ul style="list-style-type: none">■ 
<ul style="list-style-type: none">■ Action	<ul style="list-style-type: none">■ Pronates and flexes forearm (at elbow)	<ul style="list-style-type: none">■ 
<ul style="list-style-type: none">■ Innervation■	<ul style="list-style-type: none">■ Median nerve (C6, C7)	<ul style="list-style-type: none">■ 

- **Arterial Supply**

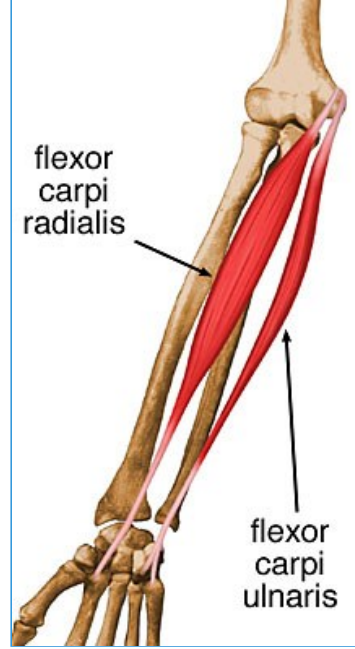
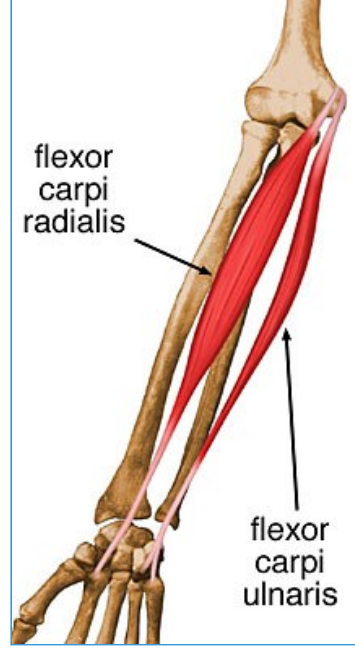
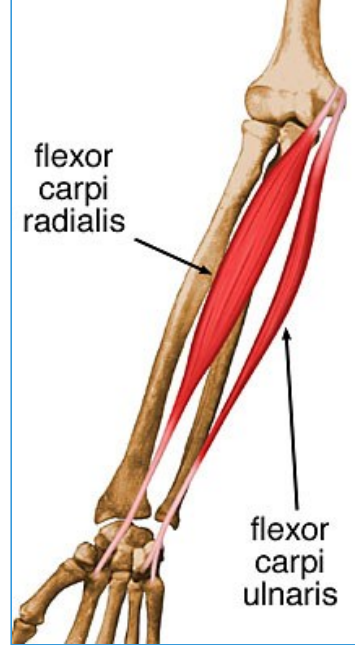
- Ulnar artery, anterior recurrent ulnar artery

-

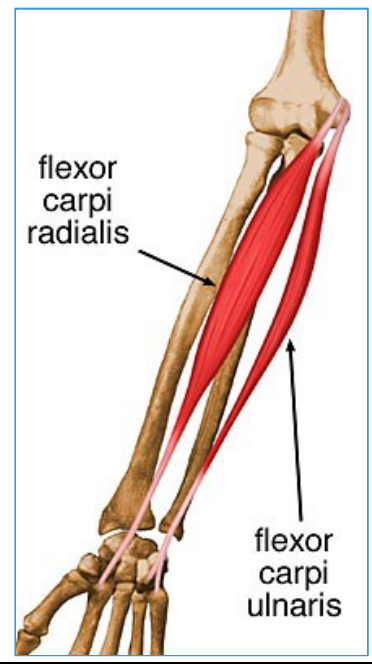


21- Flexor Carpi Radialis

- Summary

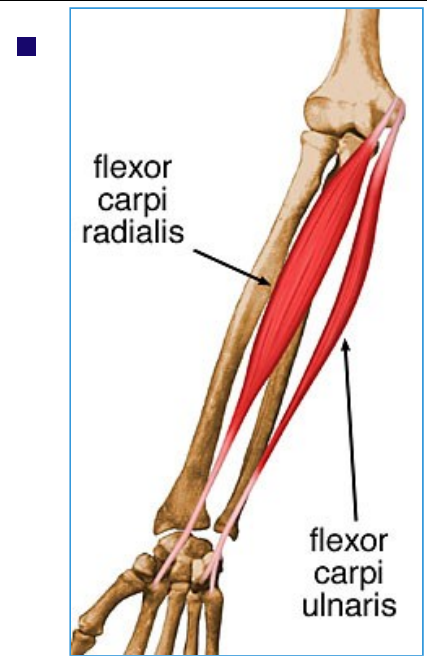
<ul style="list-style-type: none"> Flexor Carpi Radialis 		
<ul style="list-style-type: none"> Origin 	<ul style="list-style-type: none"> Medial epicondyle of humerus 	<ul style="list-style-type: none"> 
<ul style="list-style-type: none"> Insertion 	<ul style="list-style-type: none"> Base of 2nd metacarpal 	<ul style="list-style-type: none"> 
<ul style="list-style-type: none"> Action 	<ul style="list-style-type: none"> Flexes and abducts hand (at wrist) 	<ul style="list-style-type: none"> 
<ul style="list-style-type: none"> Innervation 	<ul style="list-style-type: none"> Median nerve (C6, C7) 	<ul style="list-style-type: none">

--



<ul style="list-style-type: none">■ Arterial Supply
--




<ul style="list-style-type: none">■ Ulnar artery
--





22- Palmaris Longus

- Summary




- ■ **Palmaris Longus**



<ul style="list-style-type: none">■ Origin	<ul style="list-style-type: none">■ Medial epicondyle of humerus	<ul style="list-style-type: none">■ 
<ul style="list-style-type: none">■ Insertion	<ul style="list-style-type: none">■ Distal half of flexor retinaculum and palmar aponeurosis	<ul style="list-style-type: none">■ 
<ul style="list-style-type: none">■ Action	<ul style="list-style-type: none">■ Flexes hand (at wrist) and tightens palmar aponeurosis	<ul style="list-style-type: none">■ 

<ul style="list-style-type: none">■ Innervation	<ul style="list-style-type: none">■ Median nerve (C7, C8)	<ul style="list-style-type: none">■ 
<ul style="list-style-type: none">■ Arterial Supply	<ul style="list-style-type: none">■ Ulnar artery	<ul style="list-style-type: none">■ 

23- Flexor Digitorum Superficialis

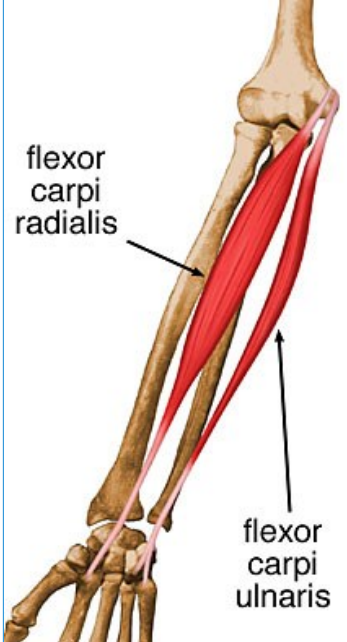
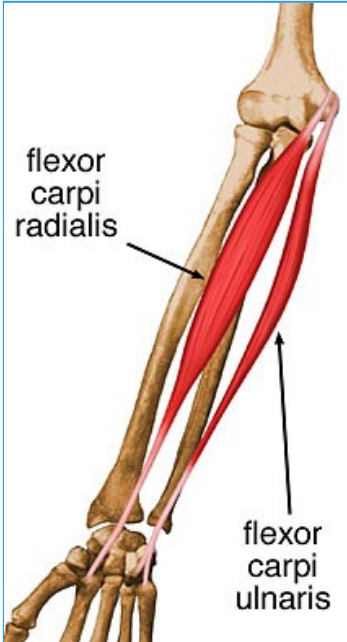
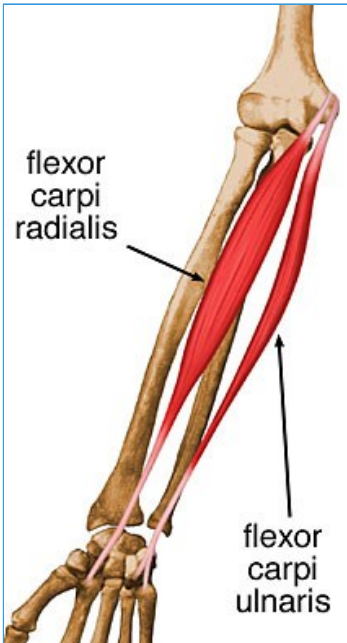
- Summary

<ul style="list-style-type: none">○ ■ Flexor Digitorum Superficialis <ul style="list-style-type: none">■ Origin	<ul style="list-style-type: none">■ Humeroulnar head: medial epicondyle of humerus, ulnar collateral ligament, and coronoid process of ulna.■ Radial head: superior half of anterior border of radius	<ul style="list-style-type: none">■ 
<ul style="list-style-type: none">■ Insertion	<ul style="list-style-type: none">■ Bodies of middle phalanges of fingers	<ul style="list-style-type: none">■ 
<ul style="list-style-type: none">■ Action	<ul style="list-style-type: none">■ Flexes middle phalanges at PIP joints of digits 2-5. Also flexes proximal phalanges at MCP joint.	<ul style="list-style-type: none">■ 

<ul style="list-style-type: none">■ Innervation	<ul style="list-style-type: none">■ Median nerve (C7, C8, T1)	<ul style="list-style-type: none">■ 
<ul style="list-style-type: none">■ Arterial supply	<ul style="list-style-type: none">■ Ulnar artery	<ul style="list-style-type: none">■ 

24- Flexor Carpi Ulnaris

- Summary

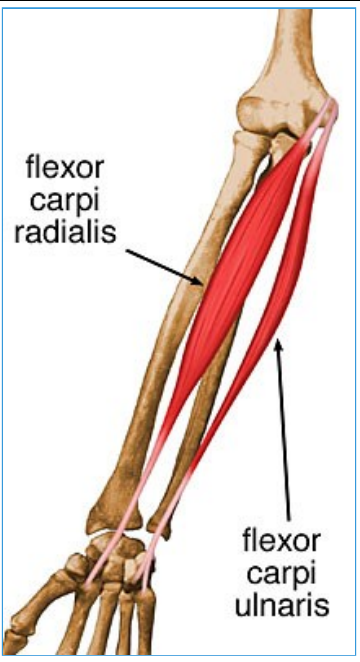
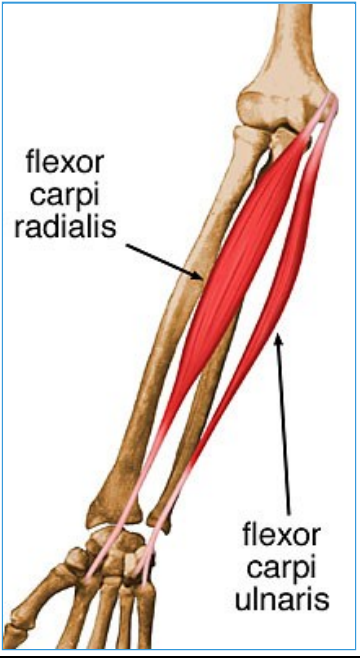
<ul style="list-style-type: none"> Flexor Carpi Ulnaris 		
<ul style="list-style-type: none"> Origin 	<ul style="list-style-type: none"> Humeral head: medial epicondyle of humerus; Ulnar head: olecranon and posterior border of ulna 	
<ul style="list-style-type: none"> Insertion 	<ul style="list-style-type: none"> Pisiform bone, hook of hamate bone, and 5th metacarpal bone 	
<ul style="list-style-type: none"> Action 	<ul style="list-style-type: none"> Flexes and adducts hand (at wrist) 	
<ul style="list-style-type: none"> Innervation 	<ul style="list-style-type: none"> Ulnar nerve (C7, C8) 	

--

<ul style="list-style-type: none">■ Arterial supply
--

--





<ul style="list-style-type: none">■ Ulnar artery
--



25- Flexor Digitorum Profundus

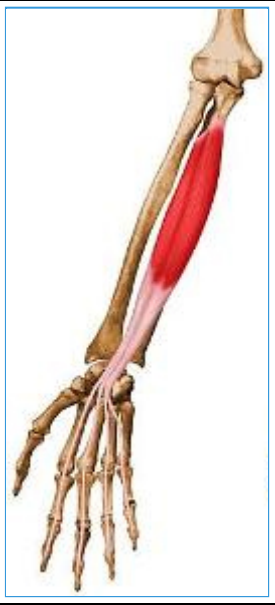- Summary

- Flexor Digitorum Profundus

<ul style="list-style-type: none"> Origin 	<ul style="list-style-type: none"> Proximal 3/4 of medial and anterior surfaces of ulna and interosseous membrane 	<ul style="list-style-type: none"> 
<ul style="list-style-type: none"> Insertion 	<ul style="list-style-type: none"> Base of the distal phalanx of digits 2 - 5 	<ul style="list-style-type: none"> 
<ul style="list-style-type: none"> Action 	<ul style="list-style-type: none"> Flexes distal phalanges at distal interphalangeal joints of medial four digits; assists with flexion of hand 	<ul style="list-style-type: none"> 
<ul style="list-style-type: none"> Innervation 	<ul style="list-style-type: none"> Medial part (slips to SF and RF): ulnar nerve (C8, T1); Lateral part (slips to MF and IF): anterior interosseous nerve (C8, T1) 	<ul style="list-style-type: none"> 




- **Arterial supply**

- Ulnar and anterior interosseous arteries



26- Flexor Pollicis Longus

- Summary

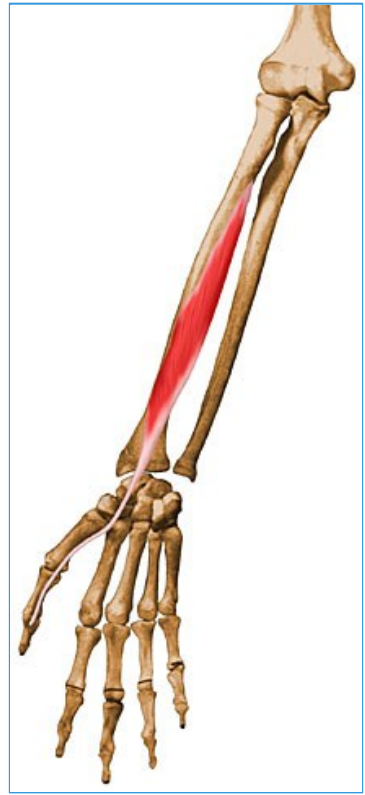<ul style="list-style-type: none">○ Flexor Pollicis Longus <ul style="list-style-type: none">■ Origin	<ul style="list-style-type: none">■ Anterior surface of radius and adjacent interosseous membrane	<ul style="list-style-type: none">■ 
<ul style="list-style-type: none">■ Insertion	<ul style="list-style-type: none">■ Base of distal phalanx of thumb	<ul style="list-style-type: none">■ 
<ul style="list-style-type: none">■ Action■	<ul style="list-style-type: none">■ Flexes phalanges of 1st digit (thumb)	<ul style="list-style-type: none">■ 

- **Innervation**

-

- Anterior interosseous nerve (C8, T1)

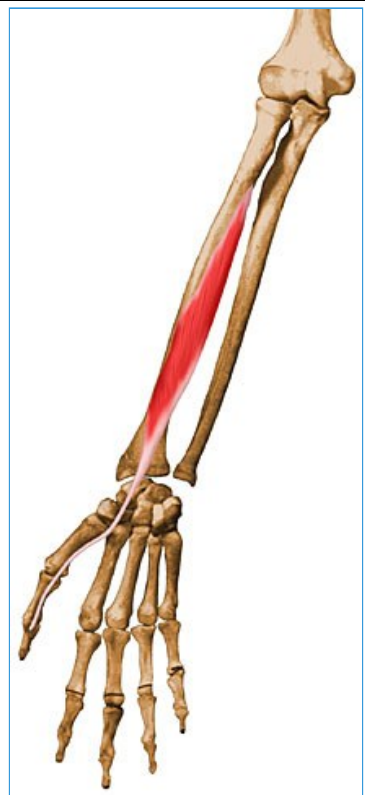-



- **Arterial Supply**

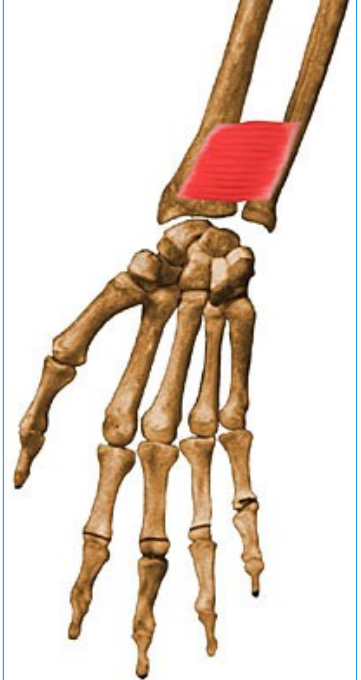


- Anterior interosseous artery

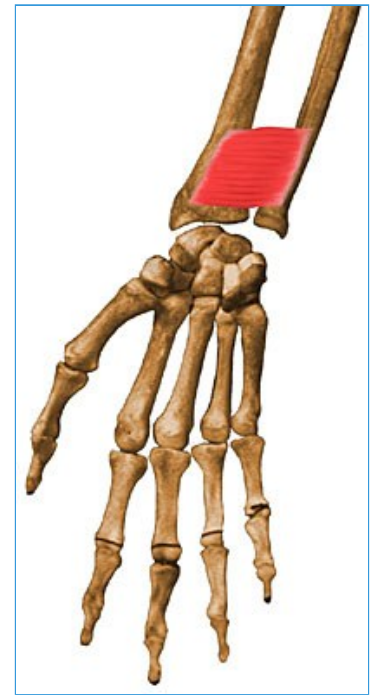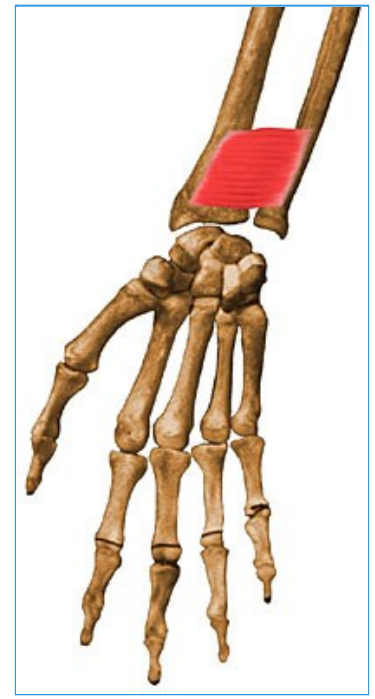-



27- Pronator Quadratus

- Summary

<ul style="list-style-type: none"> <ul style="list-style-type: none"> ■ Pronator quadratus 		
<ul style="list-style-type: none"> <ul style="list-style-type: none"> ■ Origin 	<ul style="list-style-type: none"> <ul style="list-style-type: none"> ■ Distal 1/4 of anterior surface of ulna 	<ul style="list-style-type: none"> <ul style="list-style-type: none"> ■ 
<ul style="list-style-type: none"> <ul style="list-style-type: none"> ■ Insertion ■ 	<ul style="list-style-type: none"> <ul style="list-style-type: none"> ■ Distal 1/4 of anterior surface of radius 	<ul style="list-style-type: none"> <ul style="list-style-type: none"> ■ 
<ul style="list-style-type: none"> <ul style="list-style-type: none"> ■ Action ■ 	<ul style="list-style-type: none"> <ul style="list-style-type: none"> ■ Pronates forearm; deep fibers bind radius and ulna together 	<ul style="list-style-type: none"> <ul style="list-style-type: none"> ■ 
<ul style="list-style-type: none"> <ul style="list-style-type: none"> ■ Innervation ■ 	<ul style="list-style-type: none"> <ul style="list-style-type: none"> ■ Anterior interosseous nerve (C8, T1) 	<ul style="list-style-type: none"> <ul style="list-style-type: none"> ■







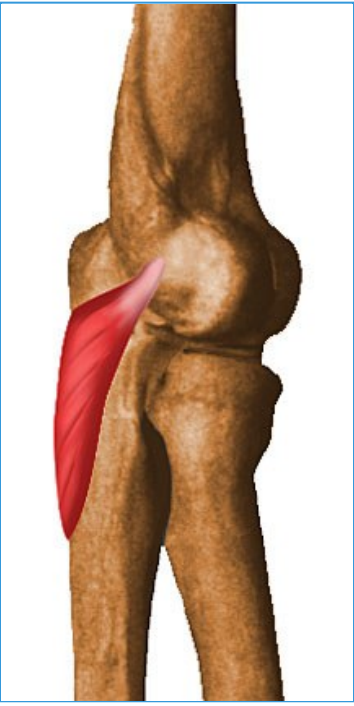

■ **Arterial supply**

■ Anterior interosseous artery

28- Anconeus

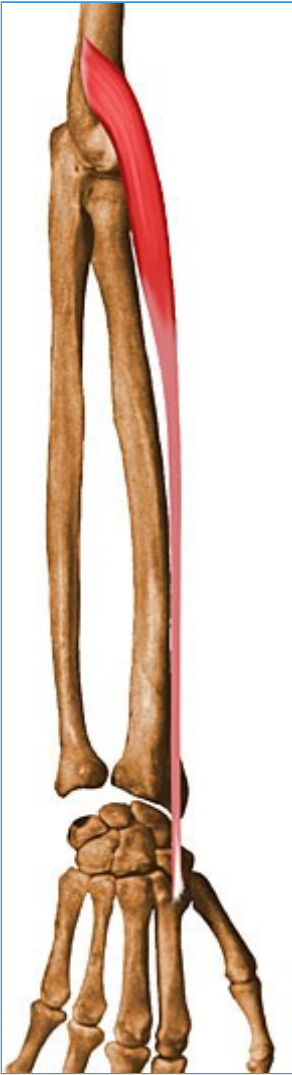

- Summary

<ul style="list-style-type: none"> <ul style="list-style-type: none"> ■ Anconeus 		
<ul style="list-style-type: none"> <ul style="list-style-type: none"> ■ Origin 	<ul style="list-style-type: none"> <ul style="list-style-type: none"> ■ Lateral epicondyle of humerus 	<ul style="list-style-type: none"> <ul style="list-style-type: none"> ■ 
<ul style="list-style-type: none"> <ul style="list-style-type: none"> ■ Insertion 	<ul style="list-style-type: none"> <ul style="list-style-type: none"> ■ Lateral surface of olecranon and superior part of posterior surface of ulna 	<ul style="list-style-type: none"> <ul style="list-style-type: none"> ■ 
<ul style="list-style-type: none"> <ul style="list-style-type: none"> ■ Action 	<ul style="list-style-type: none"> <ul style="list-style-type: none"> ■ Assists triceps in extending forearm (terminal 15° of extension and supination); stabilizes elbow joint; abducts ulna during pronation 	<ul style="list-style-type: none"> <ul style="list-style-type: none"> ■ 
<ul style="list-style-type: none"> <ul style="list-style-type: none"> ■ Innervation 	<ul style="list-style-type: none"> <ul style="list-style-type: none"> ■ Radial nerve (C7, C8, T1) 	<ul style="list-style-type: none"> <ul style="list-style-type: none"> ■ 

		
<ul style="list-style-type: none">■ Arterial supply	<ul style="list-style-type: none">■ Medial collateral artery; recurrent posterior interosseous artery, posterior branch of radial collateral artery	<ul style="list-style-type: none">■ 

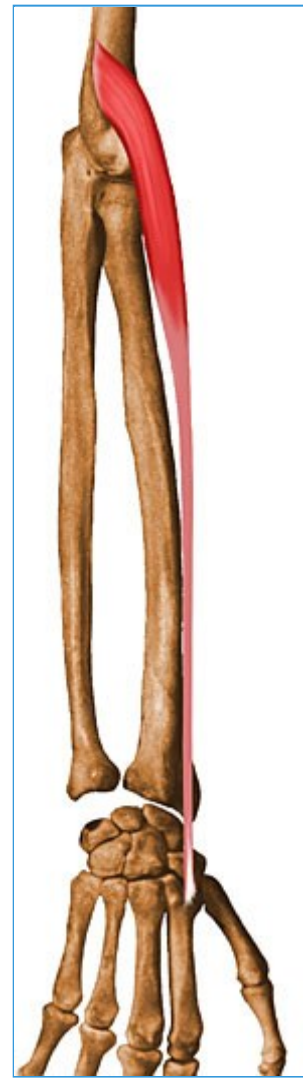29- Extensor Carpi Radialis Longus

- Summary

<ul style="list-style-type: none"> Extensor Carpi Radialis Longus 		
<ul style="list-style-type: none"> Origin 	<ul style="list-style-type: none"> Lateral supracondylar ridge of humerus 	
<ul style="list-style-type: none"> Insertion 	<ul style="list-style-type: none"> Base of 2nd metacarpal 	

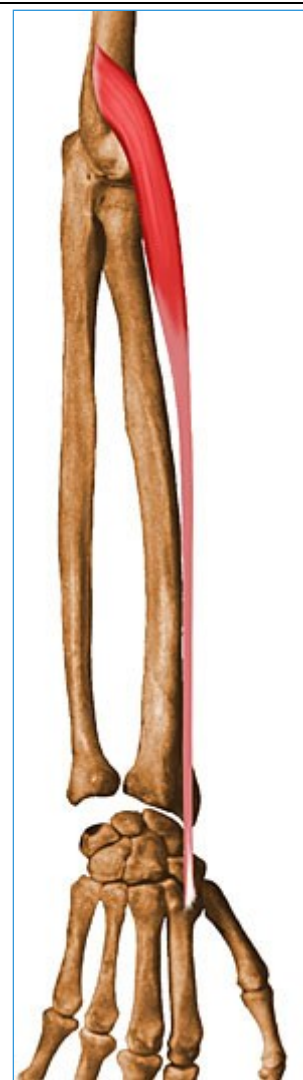■ **Action**

■ Wrist extension and wrist abduction (radial deviation)



■ **Innervation**

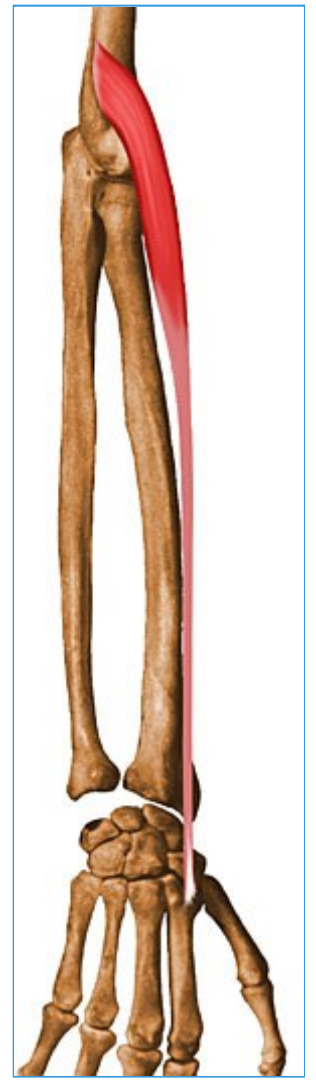■ Radial nerve (C6 ,C7)



■ **Arterial Supply**

■ Radial artery

■



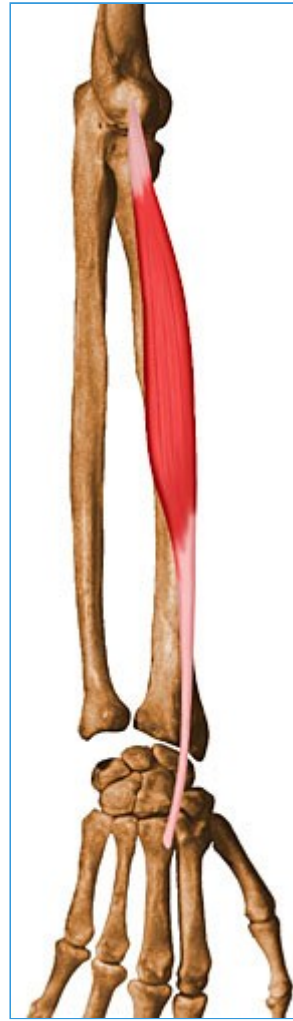30- Extensor Carpi Radialis Brevis

- Summary

- ■ Extensor Carpi Radialis Brevis

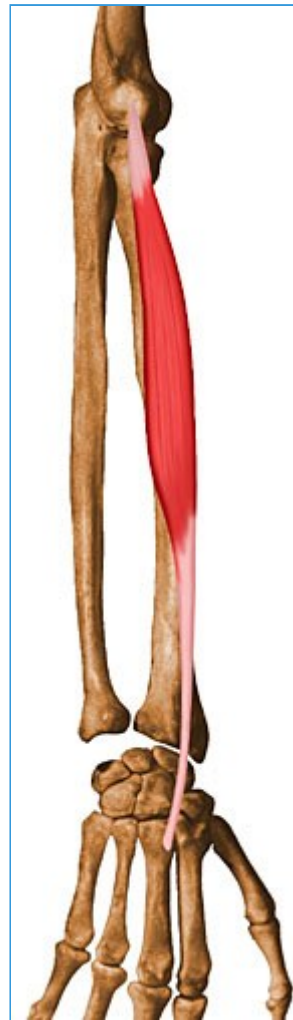- **Origin**

- Lateral epicondyle of humerus



- **Insertion**

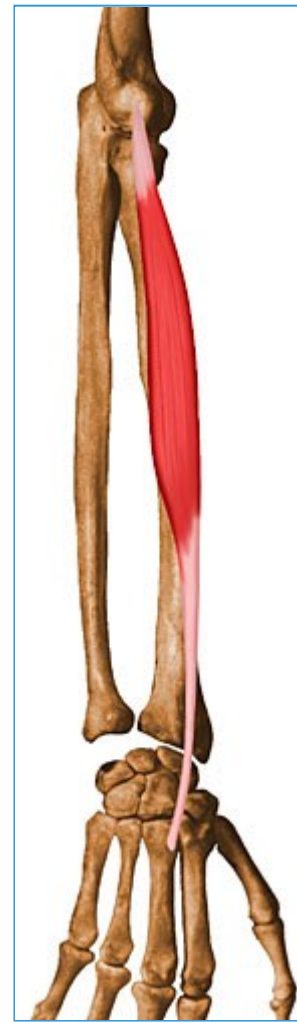- Base of 3rd metacarpal



- **Action**

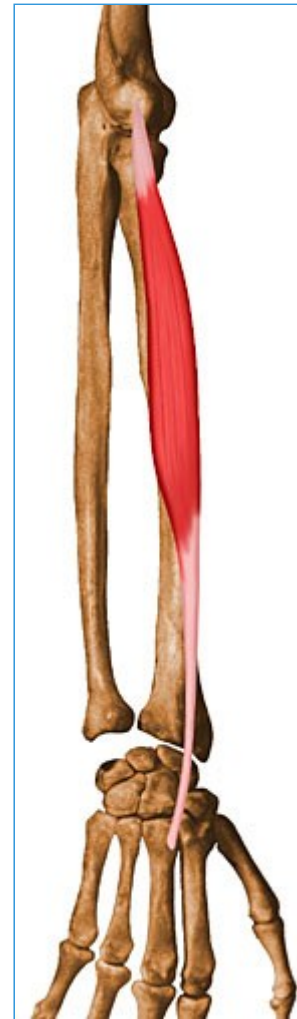- Extend and abduct hand at wrist joint

-



■ **Innervation**

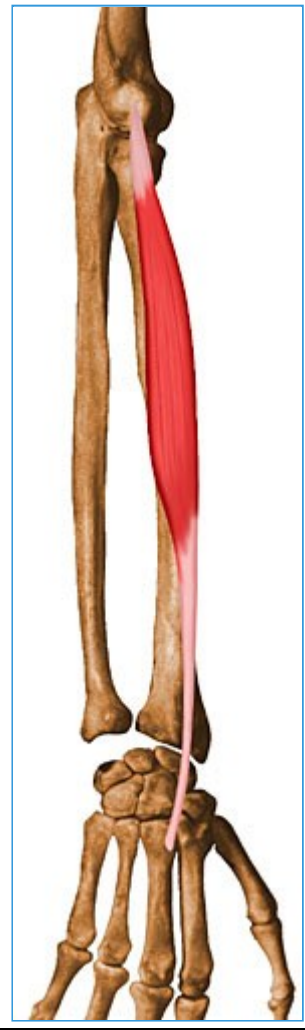- Deep branch of radial nerve (C7, C8)



■ **Arterial Supply**

- Radial artery






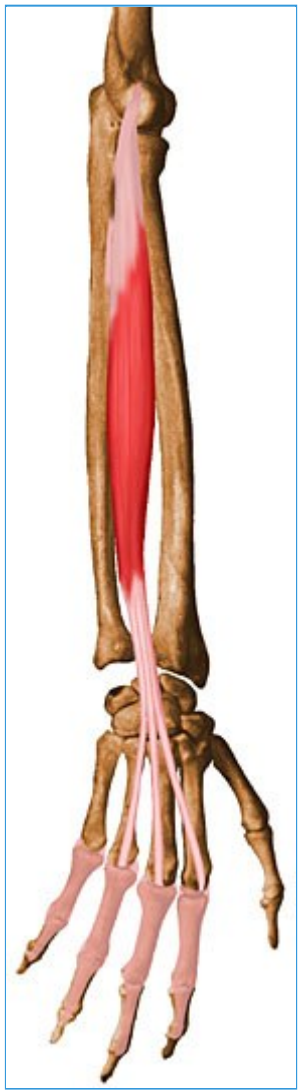

31- Extensor Digitorum Communis

- Summary

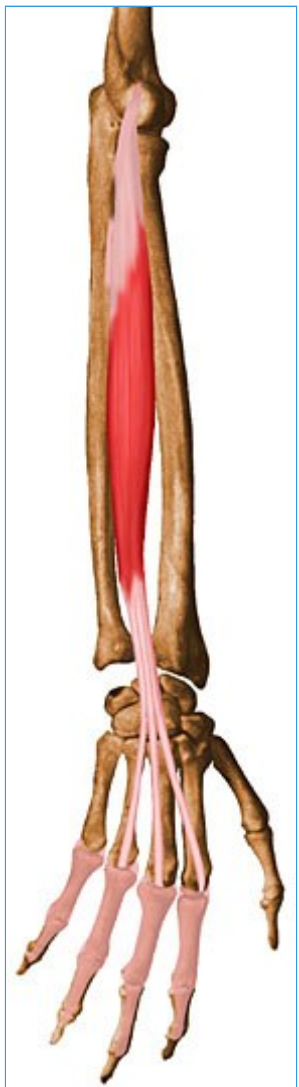- Extensor Digitorum Communis

<ul style="list-style-type: none"> Origin 	<ul style="list-style-type: none"> Lateral epicondyle of humerus 	<ul style="list-style-type: none"> 
<ul style="list-style-type: none"> Insertion 	<ul style="list-style-type: none"> Extensor expansions of medial four digits 	<ul style="list-style-type: none"> 
<ul style="list-style-type: none"> Action 	<ul style="list-style-type: none"> Extends medial four digits at metacarpophalangeal joints; Extends hand at wrist joint 	<ul style="list-style-type: none"> 



■ **Innervation**

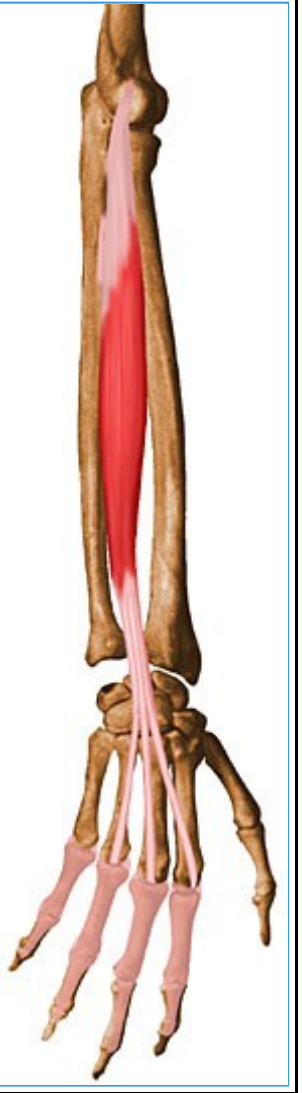
- Posterior interosseous nerve (C7, C8)



■ **Arterial Supply**

- Interosseous recurrent and posterior interosseous arteries





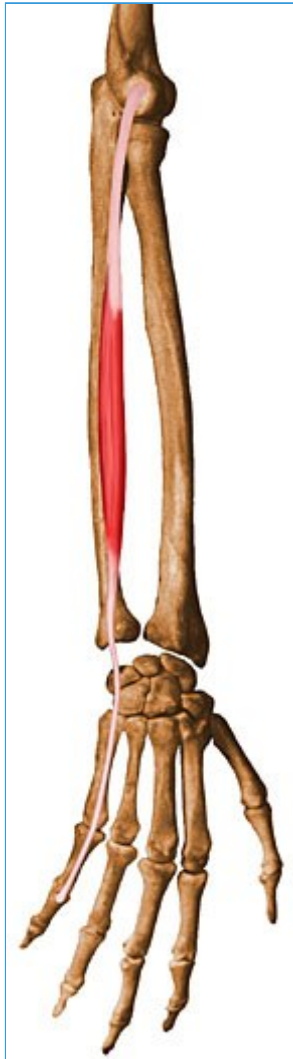32- Extensor Digiti Minimi

- Summary

- ■ Extensor Digiti Minimi

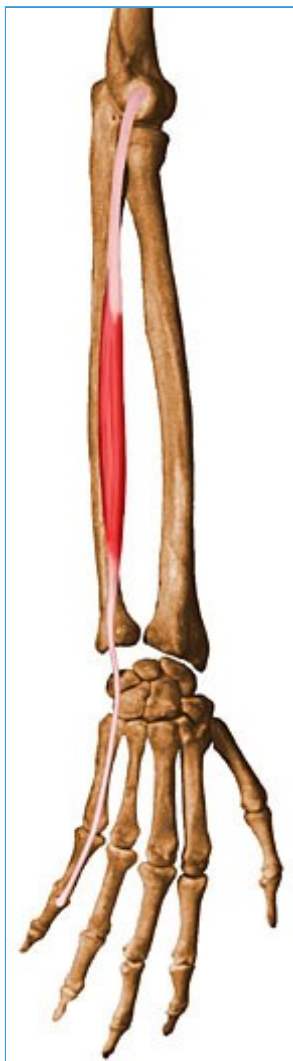- **Origin**

- Lateral epicondyle of humerus



- **Insertion**

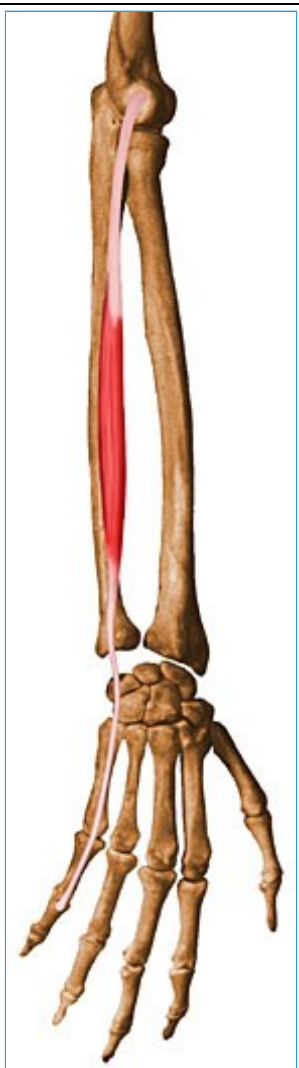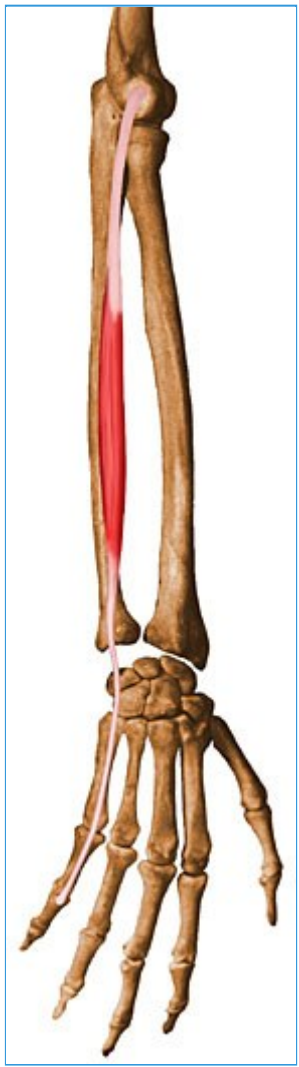- Extensor expansion of 5th digit



- **Action**

- Extends 5th digit at metacarpophalangeal and interphalangeal joints

-



- **Innervation**

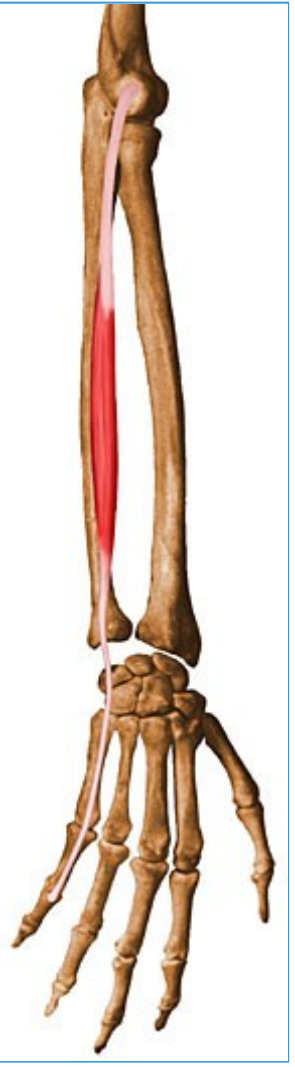-

- Posterior interosseous nerve (C7, C8)

- **Arterial Supply**

- Interosseous recurrent artery

-



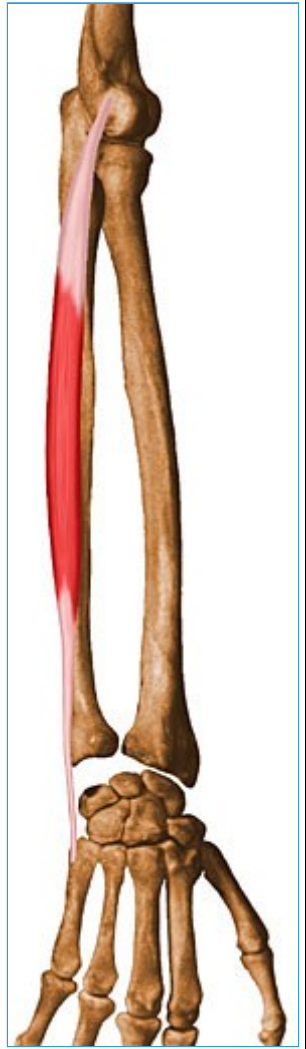33- Extensor Carpi Ulnaris

- Summary

- o **Extensor Carpi Ulnaris**

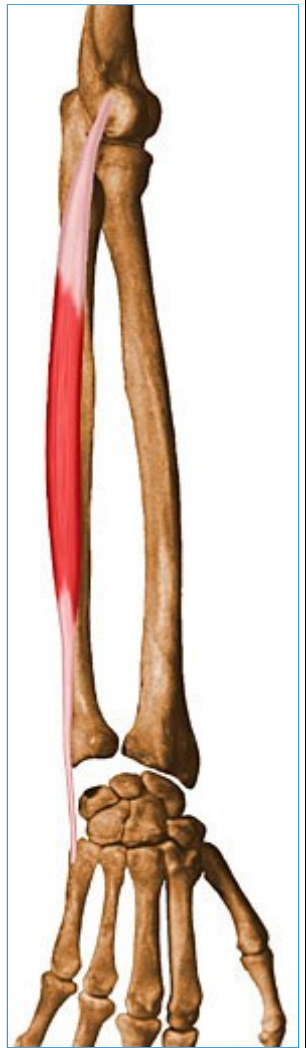- **Origin**

- Lateral epicondyle of humerus and posterior border of ulna



- **Insertion**

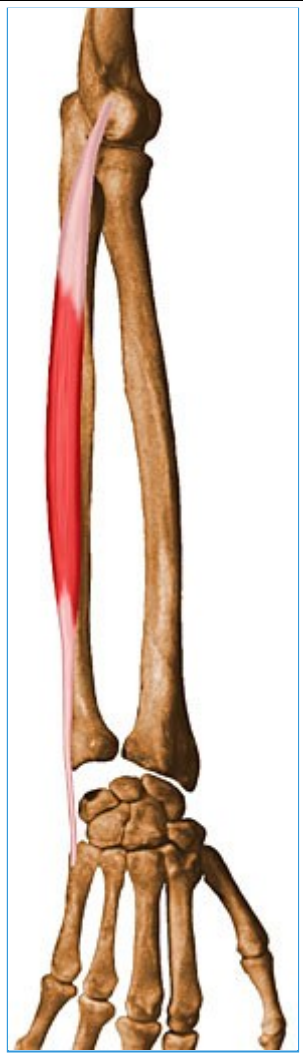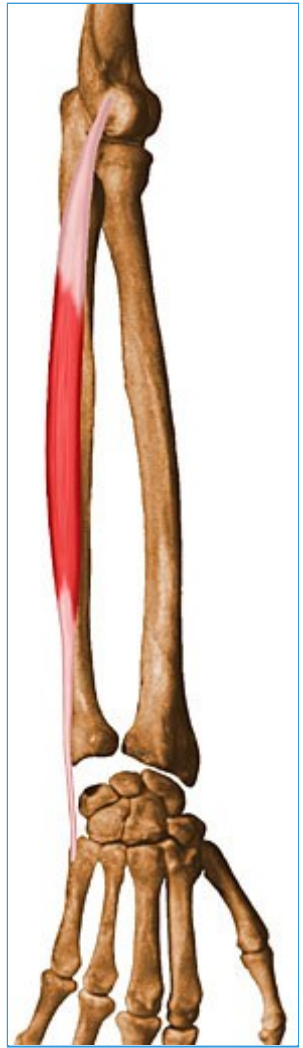- Base of 5th metacarpal



- **Action**

- Wrist extension and wrist adduction

- 



- **Innervation**

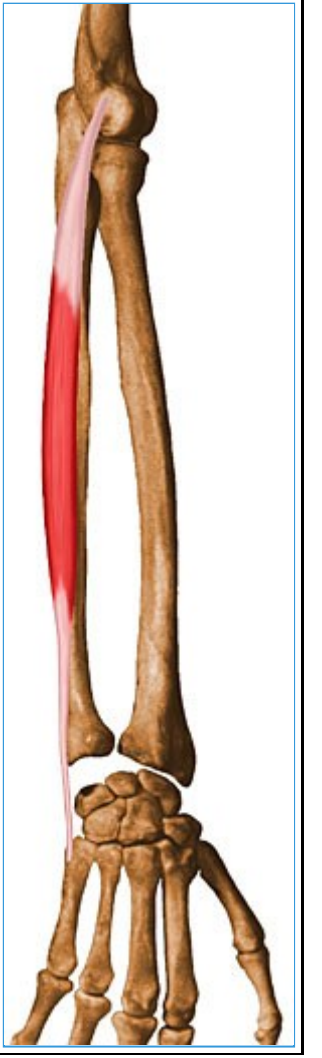-

- Posterior interosseous nerve (C7, C8)

- **Arterial Supply**





- Ulnar artery



-



34- Supinator



- Summary

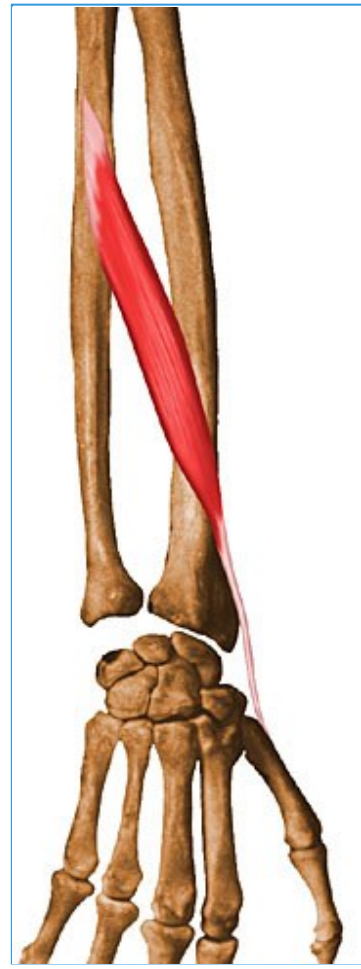<ul style="list-style-type: none"> Supinator 		
<ul style="list-style-type: none"> Origin 	<ul style="list-style-type: none"> Lateral epicondyle of humerus, radial collateral and annular ligaments, supinator fossa and crest of ulna 	
<ul style="list-style-type: none"> Insertion 	<ul style="list-style-type: none"> Lateral, posterior and anterior surfaces of proximal 1/3 of radius 	
<ul style="list-style-type: none"> Action 	<ul style="list-style-type: none"> Supinates forearm (i.e., rotates radius to turn palm anteriorly) 	
<ul style="list-style-type: none"> Innervation 	<ul style="list-style-type: none"> Deep branch of radial nerve (C5, C6) 	

		
<ul style="list-style-type: none">■ Arterial supply	<ul style="list-style-type: none">■ Recurrent interosseous artery	<ul style="list-style-type: none">■ 

35- Abductor Pollicis Longus

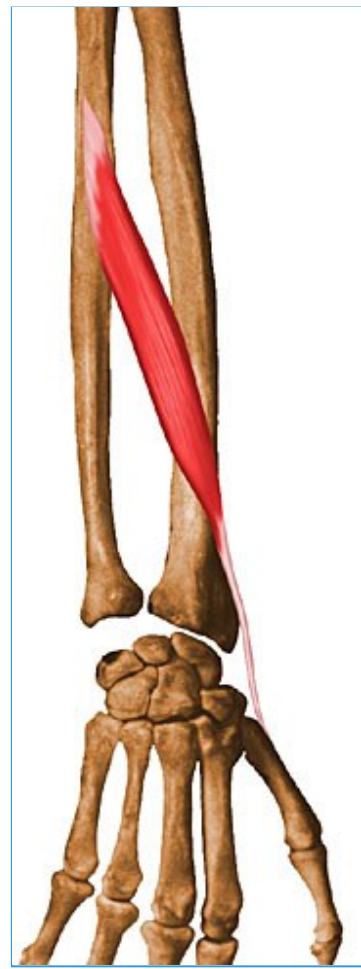- Summary

<ul style="list-style-type: none">○ ■ Abductor Pollicis Longus <ul style="list-style-type: none">■ Origin■	<ul style="list-style-type: none">■ Posterior surfaces of ulna, radius and interosseous membrane	<ul style="list-style-type: none">■ 
<ul style="list-style-type: none">■ Insertion	<ul style="list-style-type: none">■ Base of 1st metacarpal	<ul style="list-style-type: none">■ 
<ul style="list-style-type: none">■ Action	<ul style="list-style-type: none">■ Abducts thumb and extends it at carpometacarpal joint	<ul style="list-style-type: none">■



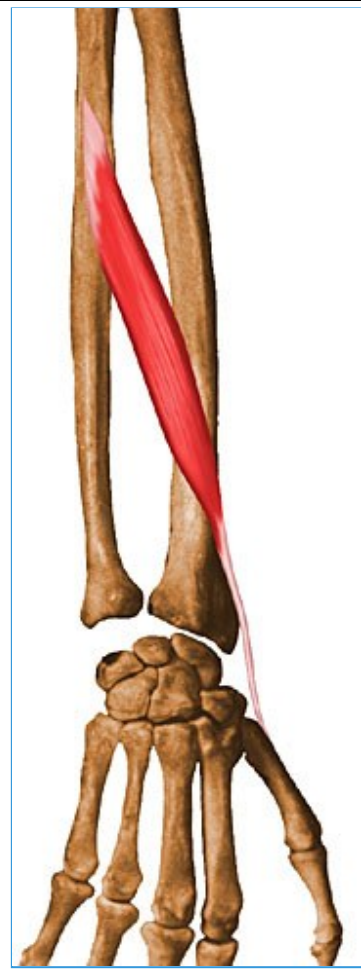■ **Innervation**

- Posterior interosseous nerve (C7, C8)



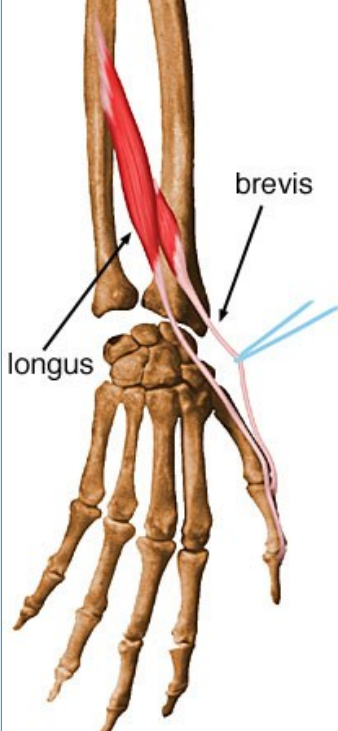
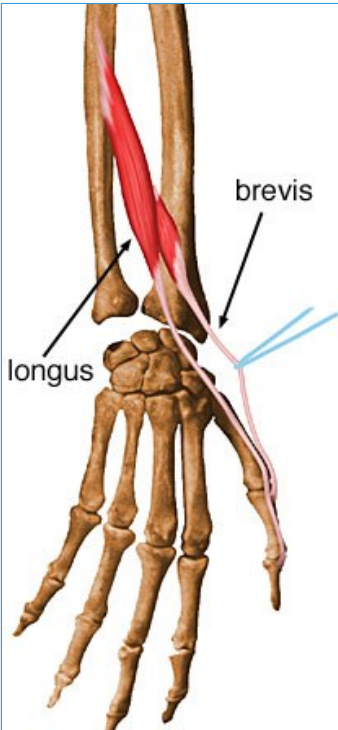
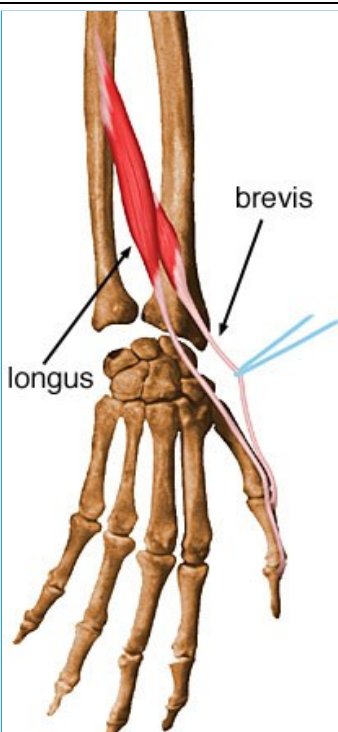

■ **Arterial Supply**

- Posterior interosseous artery



36- Extensor Pollicis Brevis

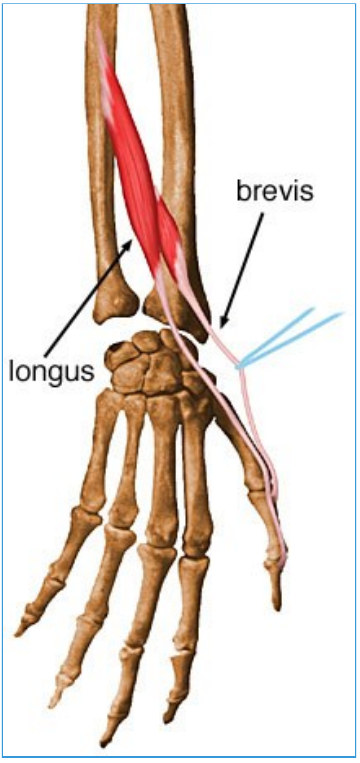
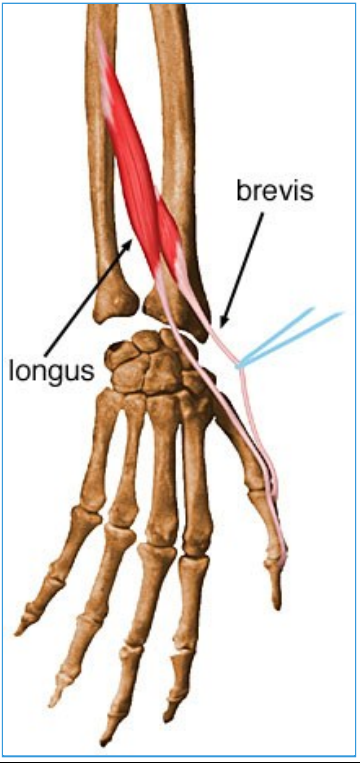
- Summary

<ul style="list-style-type: none"> Extensor Pollicis Brevis Origin 	<ul style="list-style-type: none"> Posterior surfaces of radius and interosseous membrane 	
<ul style="list-style-type: none"> Insertion 	<ul style="list-style-type: none"> Base of proximal phalanx of thumb 	
<ul style="list-style-type: none"> Action 	<ul style="list-style-type: none"> Extends proximal phalanx of thumb at metacarpophalangeal joint 	
<ul style="list-style-type: none"> Innervation 	<ul style="list-style-type: none"> Posterior interosseous nerve (C7, C8) 	

-

- **Arterial Supply**

- Posterior interosseous artery



37- Extensor Pollicis Longus

- Summary

<ul style="list-style-type: none"> Extensor Pollicis Longus 		
<ul style="list-style-type: none"> Origin 	<ul style="list-style-type: none"> Posterior surface of middle 1/3 of ulna and interosseous membrane 	
<ul style="list-style-type: none"> Insertion 	<ul style="list-style-type: none"> Base of distal phalanx of thumb 	
<ul style="list-style-type: none"> Action 	<ul style="list-style-type: none"> Extends distal phalanx of thumb at metacarpophalangeal and interphalangeal joints 	
<ul style="list-style-type: none"> Innervation 	<ul style="list-style-type: none"> Posterior interosseous nerve (C7, C8) 	

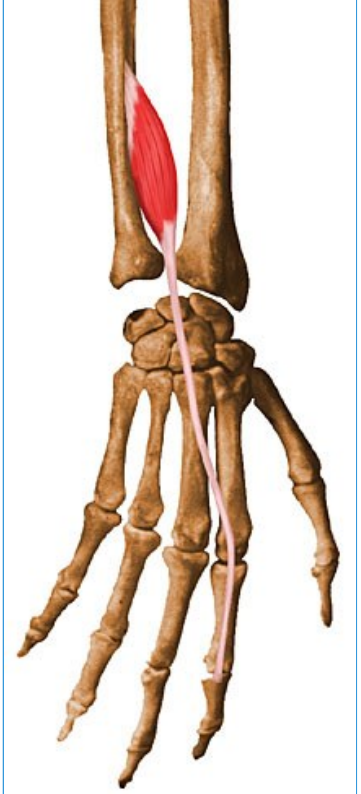
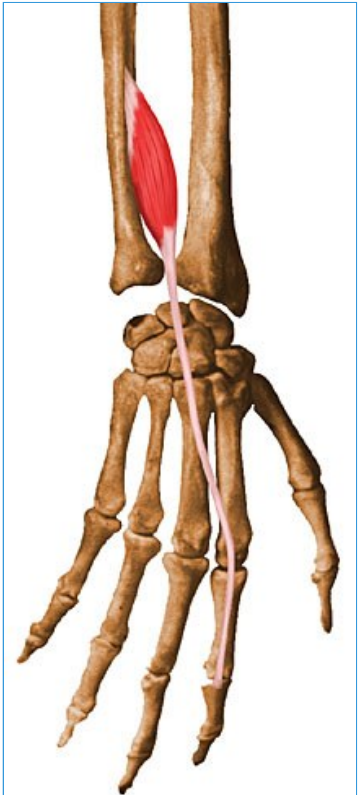
<ul style="list-style-type: none">■		
<ul style="list-style-type: none">■ Arterial supply	<ul style="list-style-type: none">■ Posterior interosseous artery	

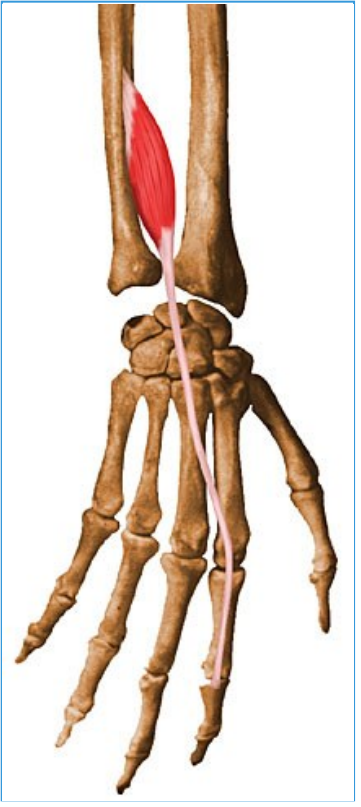
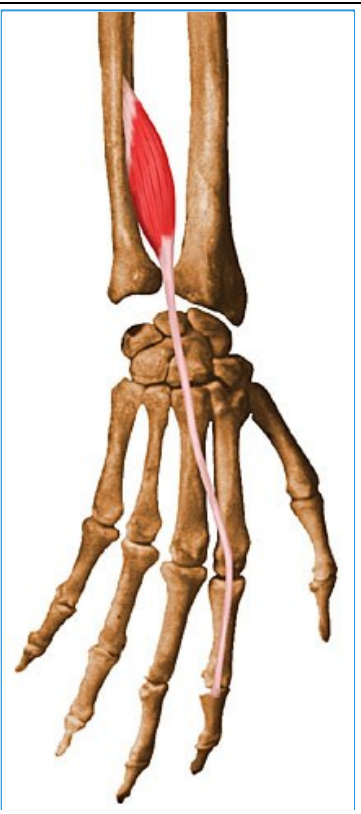
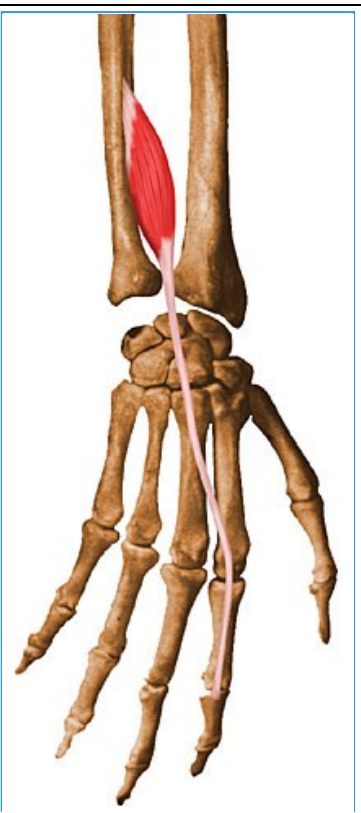
-

38- Extensor Indicis Proprius

- Summary

- ■ **Extensor Indicis Proprius**

<ul style="list-style-type: none">■ Origin	<ul style="list-style-type: none">■ Posterior surface of ulna and interosseous membrane	<ul style="list-style-type: none">■ 
<ul style="list-style-type: none">■ Insertion	<ul style="list-style-type: none">■ Extensor expansion of 2nd digit	<ul style="list-style-type: none">■ 
<ul style="list-style-type: none">■ Action■	<ul style="list-style-type: none">■ Extends 2nd digit and helps to extend the hand	<ul style="list-style-type: none">■

		
<ul style="list-style-type: none"> ■ Innervation ■ 	<ul style="list-style-type: none"> ■ Posterior interosseous nerve (C7, C8) 	<ul style="list-style-type: none"> ■ 
<ul style="list-style-type: none"> ■ Arterial supply 	<ul style="list-style-type: none"> ■ Posterior interosseous artery 	<ul style="list-style-type: none"> ■ 

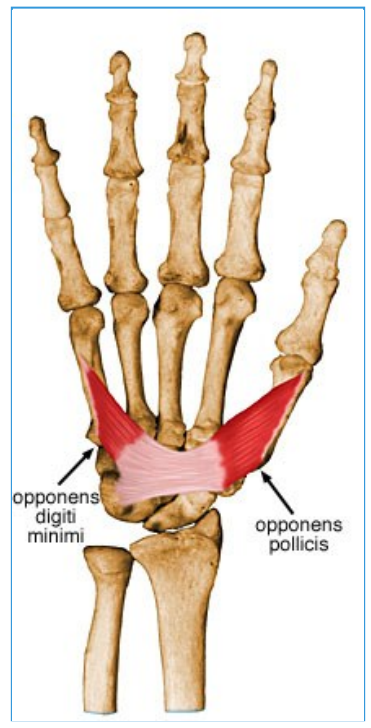
39- Opponens Pollicis

- Summary

<ul style="list-style-type: none"> Opponens Pollicis 		
<ul style="list-style-type: none"> Origin 	<ul style="list-style-type: none"> Flexor retinaculum and tubercles of scaphoid and trapezium 	
<ul style="list-style-type: none"> Insertion 	<ul style="list-style-type: none"> Lateral side of 1st metacarpal 	
<ul style="list-style-type: none"> Action 	<ul style="list-style-type: none"> Draws 1st metacarpal into adduction to oppose thumb toward center of palm and rotates it medially 	
<ul style="list-style-type: none"> Innervation 	<ul style="list-style-type: none"> Recurrent branch of median nerve (C8, T1) 	

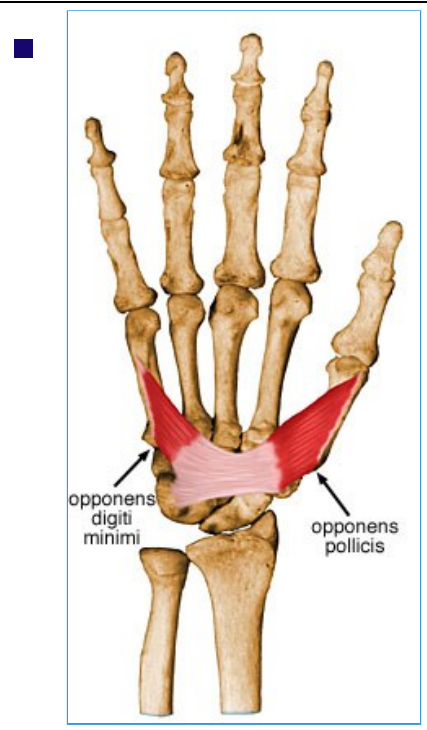
--

--



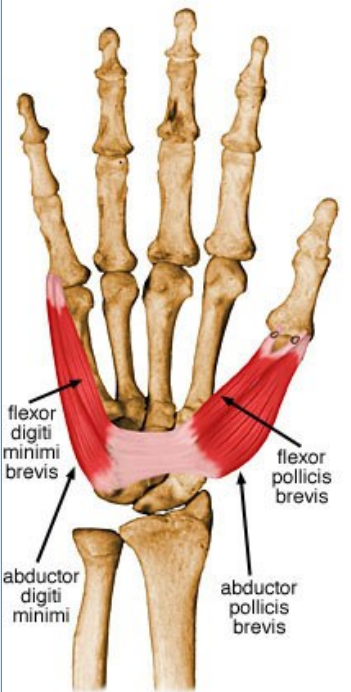
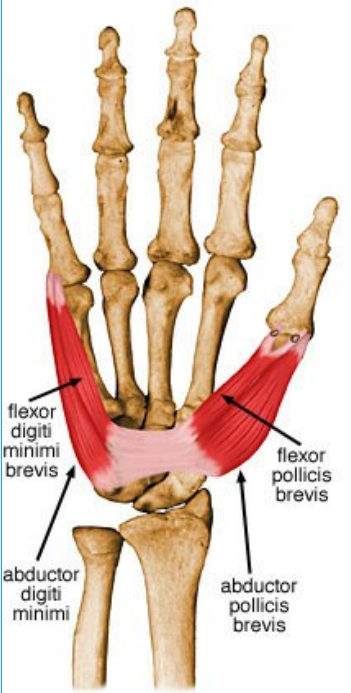
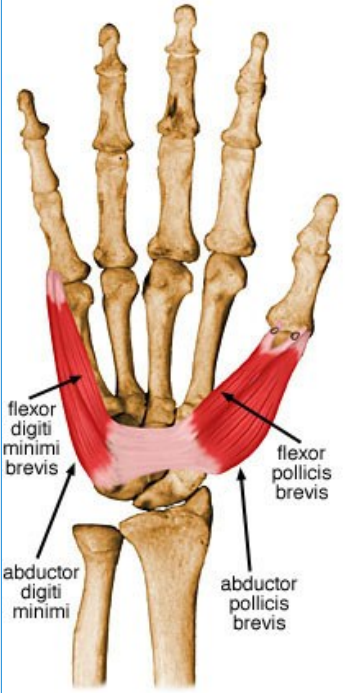
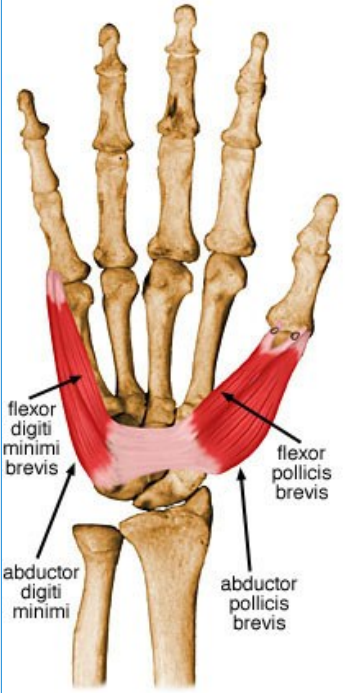
<ul style="list-style-type: none">■ Arterial supply
--

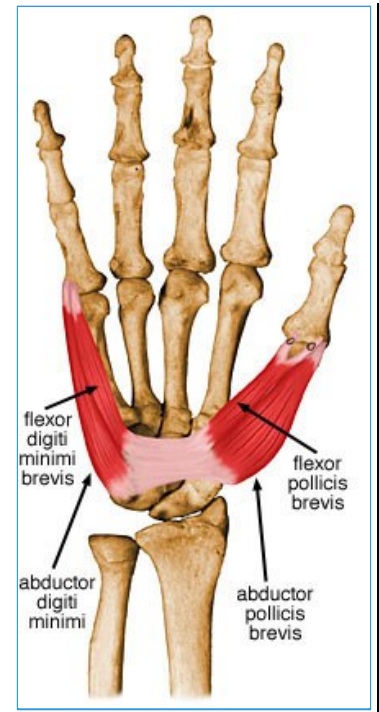
<ul style="list-style-type: none">■ Superficial palmar branch of the radial artery
--



40- Abductor Pollicis Brevis

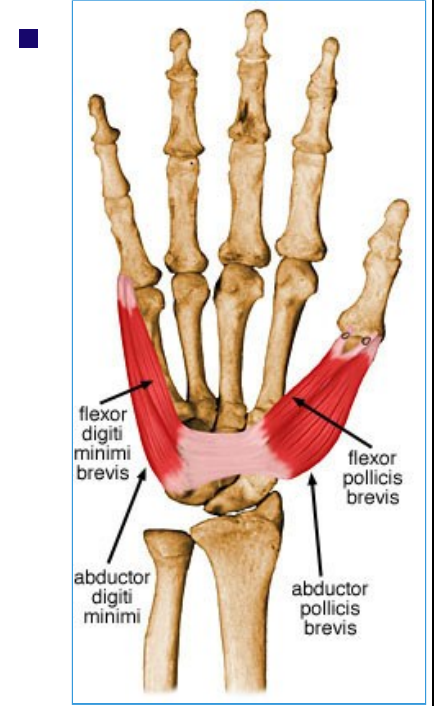
- Summary

<ul style="list-style-type: none"> Abductor Pollicis Brevis 	<ul style="list-style-type: none"> Origin Flexor retinaculum and tubercles of scaphoid and trapezium 	
<ul style="list-style-type: none"> Insertion 	<ul style="list-style-type: none"> Lateral side of base of proximal phalanx of thumb 	
<ul style="list-style-type: none"> Action 	<ul style="list-style-type: none"> Abducts thumb and helps oppose it 	
<ul style="list-style-type: none"> Innervation 	<ul style="list-style-type: none"> Recurrent branch of median nerve (C8 and T1) 	



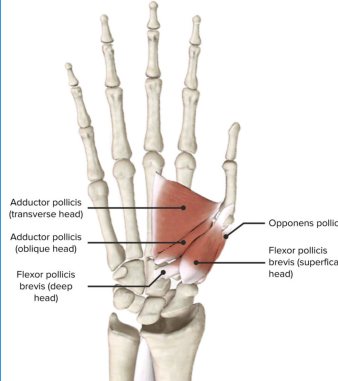
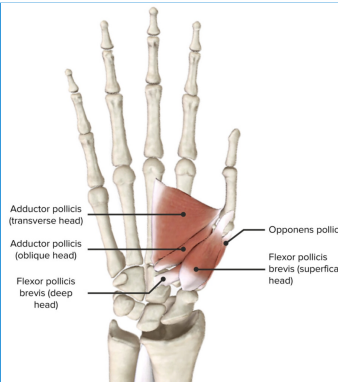
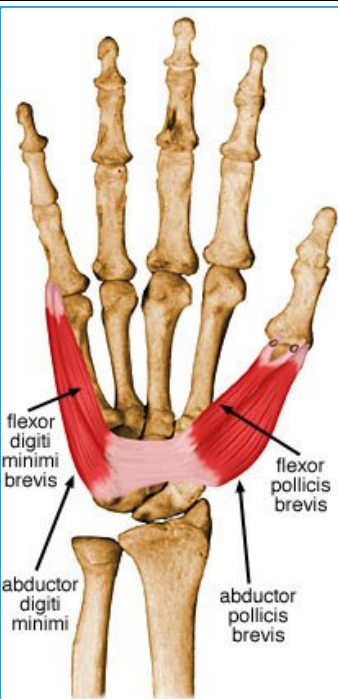
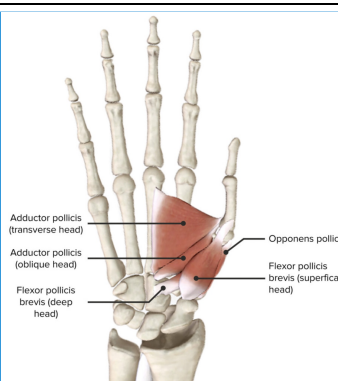
■ **Arterial Supply**

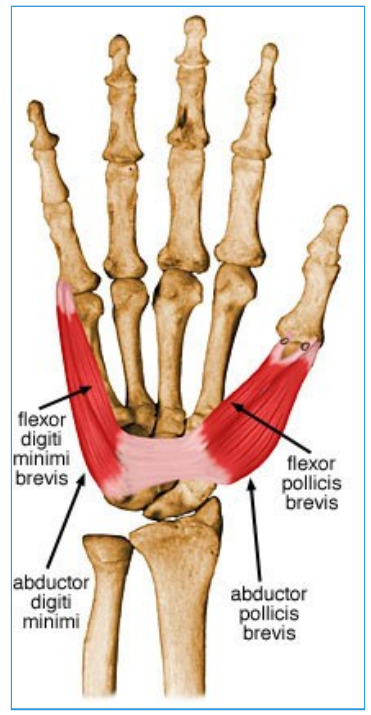
■ Superficial palmar branch of the radial artery



41- Flexor Pollicis Brevis





• Summary

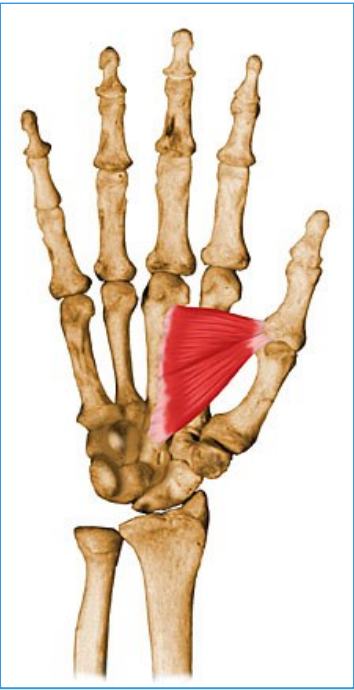
Flexor Pollicis Brevis		
<ul style="list-style-type: none">Origin	<ul style="list-style-type: none">Superficial head: Flexor retinaculum and tubercles of scaphoid and trapeziumDeep head: Trapezoid and Capitate (more medial than superficial head)	
<ul style="list-style-type: none">Insertion	<ul style="list-style-type: none">Lateral side of base of proximal phalanx of thumb	
<ul style="list-style-type: none">Action	<ul style="list-style-type: none">Flexes thumb	
<ul style="list-style-type: none">Innervation	<ul style="list-style-type: none">Superficial head: recurrent branch of the median nerve (C8, T1)Deep head: deep branch of ulnar nerve.	
<ul style="list-style-type: none">Arterial Supply	<ul style="list-style-type: none">Superficial palmar branch of the radial artery	



42- Adductor Pollicis

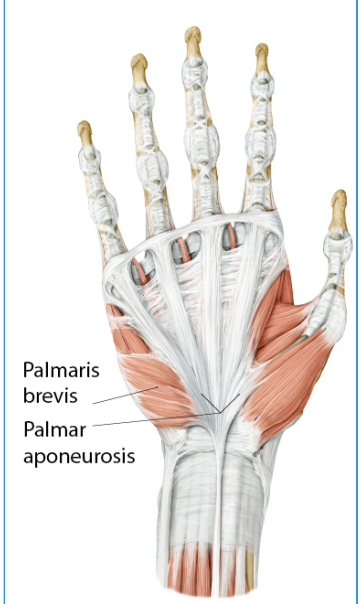
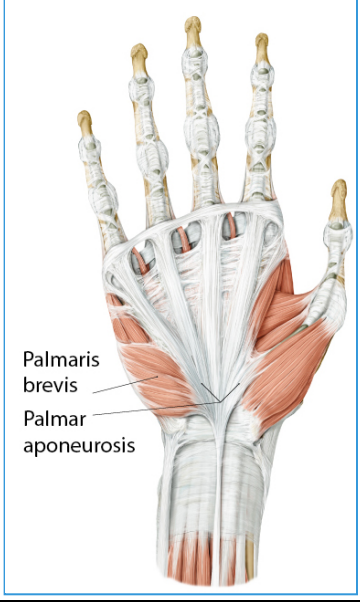
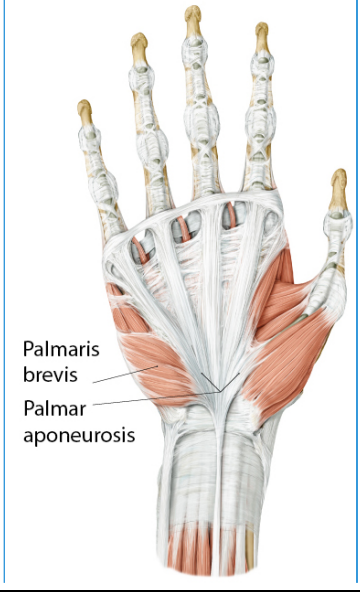
- Summary

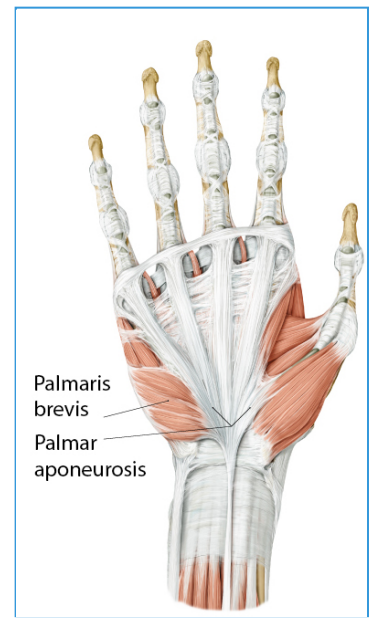

<ul style="list-style-type: none"> <ul style="list-style-type: none"> ■ Adductor Pollicis 	<ul style="list-style-type: none"> <ul style="list-style-type: none"> ■ Origin <ul style="list-style-type: none"> ■ Oblique head: bases of 2nd and 3rd metacarpals, capitate, and adjacent carpals; ■ Transverse head: anterior surface of the body of 3rd metacarpal 	<ul style="list-style-type: none"> <ul style="list-style-type: none"> ■ 
<ul style="list-style-type: none"> <ul style="list-style-type: none"> ■ Insertion 	<ul style="list-style-type: none"> <ul style="list-style-type: none"> ■ Medial side of base of proximal phalanx of thumb 	<ul style="list-style-type: none"> <ul style="list-style-type: none"> ■ 
<ul style="list-style-type: none"> <ul style="list-style-type: none"> ■ Action 	<ul style="list-style-type: none"> <ul style="list-style-type: none"> ■ Draws 1st metacarpal laterally to oppose thumb toward center of palm and rotates it medially 	<ul style="list-style-type: none"> <ul style="list-style-type: none"> ■ 
<ul style="list-style-type: none"> <ul style="list-style-type: none"> ■ Innervation 	<ul style="list-style-type: none"> <ul style="list-style-type: none"> ■ Deep branch of ulnar nerve (C8, T1) 	<ul style="list-style-type: none"> <ul style="list-style-type: none"> ■ 

		
<ul style="list-style-type: none">■ Arterial supply	<ul style="list-style-type: none">■ Deep palmar arterial arch	<ul style="list-style-type: none">■ 

43- Palmaris Brevis

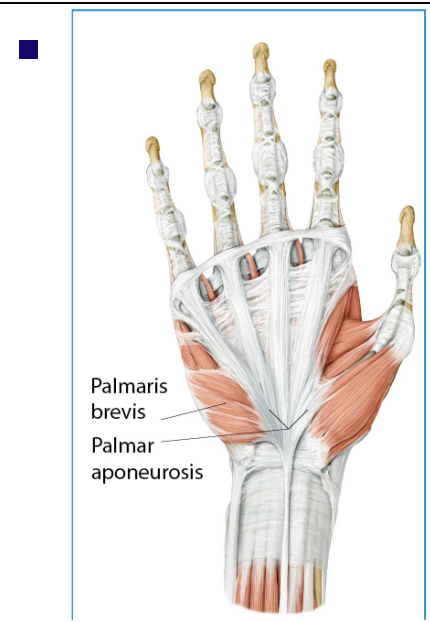
- Summary

■ Palmaris Brevis		
■ Origin	■ Transverse carpal ligament, palmar aponeurosis	■ 
■ Insertion	■ Ulnar palm	■ 
■ Action	■ Wrinkles the skin of medial palm	■ 
■ Innervation	■ Ulnar nerve (C8, T1)	■






■ **Arterial supply**

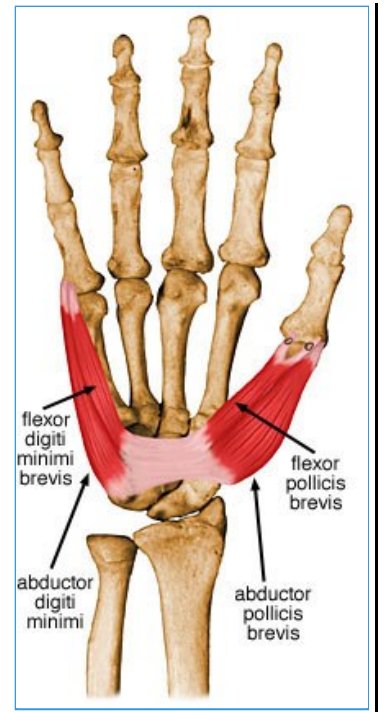
■ Ulnar artery



44- Abductor Digiti Minimi

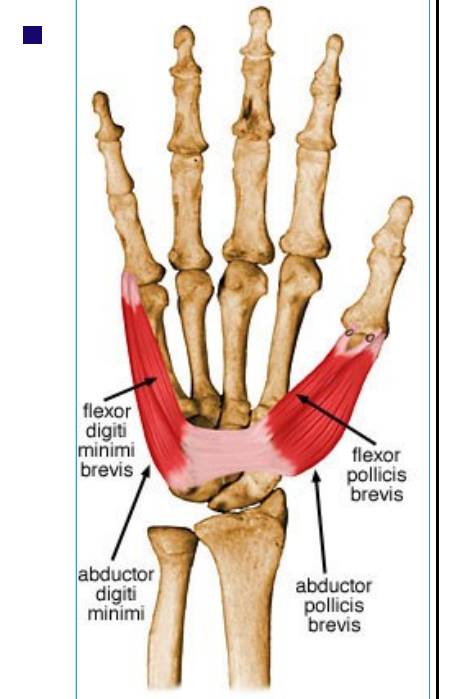
- Summary

<ul style="list-style-type: none"> Abductor Digiti Minimi 	<ul style="list-style-type: none"> Pisiform 	
<ul style="list-style-type: none"> Insertion 	<ul style="list-style-type: none"> Medial side of base of proximal phalanx of little finger 	
<ul style="list-style-type: none"> Action 	<ul style="list-style-type: none"> Abducts small finger 	
<ul style="list-style-type: none"> Innervation 	<ul style="list-style-type: none"> Deep branch of ulnar nerve (C8 and T1) 	<ul style="list-style-type: none">






■ **Arterial supply**

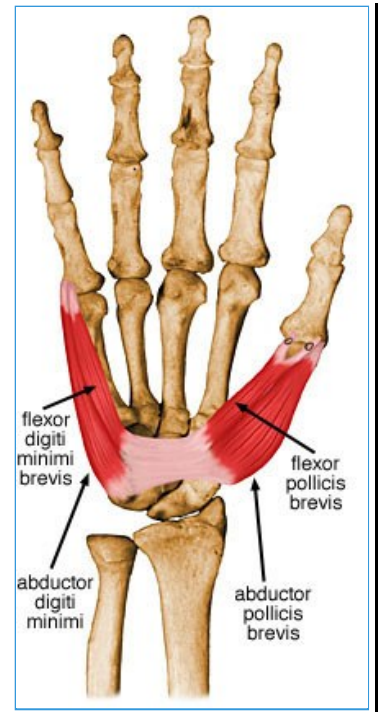
■ Ulnar artery



45- Flexor Digiti Minimi Brevis

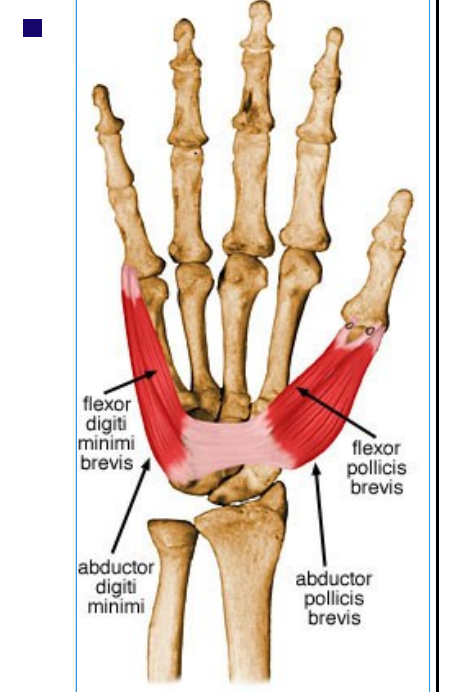
- Summary

<ul style="list-style-type: none"> Flexor digiti minimi brevis 		
<ul style="list-style-type: none"> Origin 	<ul style="list-style-type: none"> Hook of hamate and flexor retinaculum 	
<ul style="list-style-type: none"> Insertion 	<ul style="list-style-type: none"> Medial side of base of proximal phalanx of little finger 	
<ul style="list-style-type: none"> Action 	<ul style="list-style-type: none"> Flexes proximal phalanx of small finger 	
<ul style="list-style-type: none"> Innervation 	<ul style="list-style-type: none"> Deep branch of ulnar nerve (C8, T1) 	<ul style="list-style-type: none">







■ **Arterial supply**

■ Ulnar artery



46- Opponens Digiti Minimi

- Summary

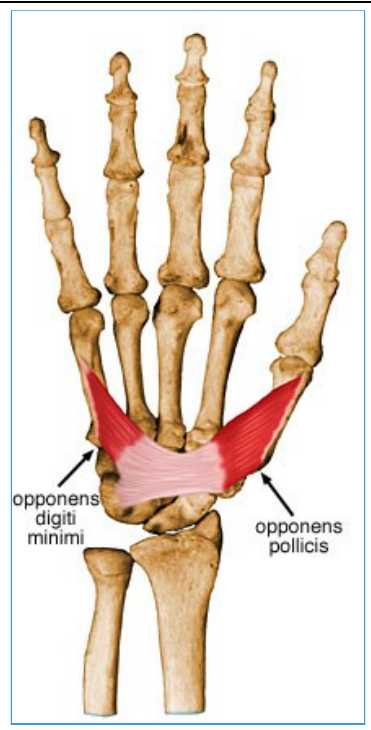
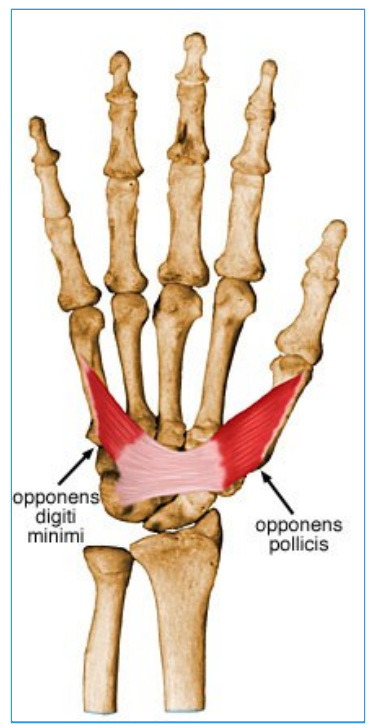
<ul style="list-style-type: none"> Opponens digiti minimi 		
<ul style="list-style-type: none"> Origin 	<ul style="list-style-type: none"> Hook of hamate and flexor retinaculum 	
<ul style="list-style-type: none"> Insertion 	<ul style="list-style-type: none"> Medial border of 5th metacarpal 	
<ul style="list-style-type: none"> Action 	<ul style="list-style-type: none"> Draws 5th metacarpal anteriorly and rotates it, bringing little finger (5th digit) into opposition with thumb 	
<ul style="list-style-type: none"> Innervation 	<ul style="list-style-type: none"> Deep branch of ulnar nerve (C8, T1) 	

--

--

<ul style="list-style-type: none">■ Arterial supply
--

<ul style="list-style-type: none">■ Ulnar artery
--



47- Dorsal Interossei

- Summary

<ul style="list-style-type: none"> <ul style="list-style-type: none"> Dorsal interossei (4 muscles) 		
<ul style="list-style-type: none"> <ul style="list-style-type: none"> <ul style="list-style-type: none"> Origin 	<ul style="list-style-type: none"> <ul style="list-style-type: none"> <ul style="list-style-type: none"> Adjacent sides of two metacarpals (4 bipennate muscles) 	
<ul style="list-style-type: none"> <ul style="list-style-type: none"> <ul style="list-style-type: none"> Insertion 	<ul style="list-style-type: none"> <ul style="list-style-type: none"> <ul style="list-style-type: none"> Extensor expansions and bases of proximal phalanges of digits 2 - 4 	
<ul style="list-style-type: none"> <ul style="list-style-type: none"> <ul style="list-style-type: none"> Action 	<ul style="list-style-type: none"> <ul style="list-style-type: none"> <ul style="list-style-type: none"> Abduct digits from axial line and act with lumbricals to flex metacarpophalangeal joints and extend interphalangeal joints 	
<ul style="list-style-type: none"> <ul style="list-style-type: none"> <ul style="list-style-type: none"> Innervation 	<ul style="list-style-type: none"> <ul style="list-style-type: none"> <ul style="list-style-type: none"> Deep branch of ulnar nerve (C8, T1) 	
<ul style="list-style-type: none"> <ul style="list-style-type: none"> <ul style="list-style-type: none"> Arterial Supply 	<ul style="list-style-type: none"> <ul style="list-style-type: none"> <ul style="list-style-type: none"> Dorsal and palmar metacarpal arteries 	

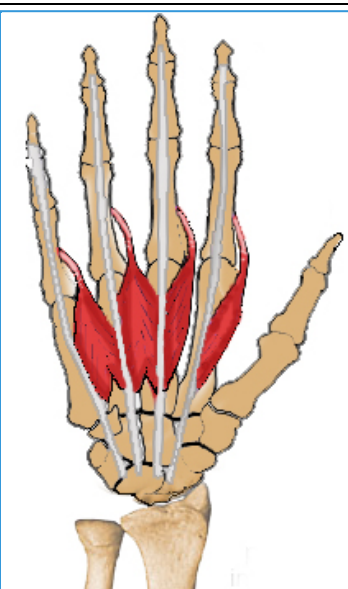
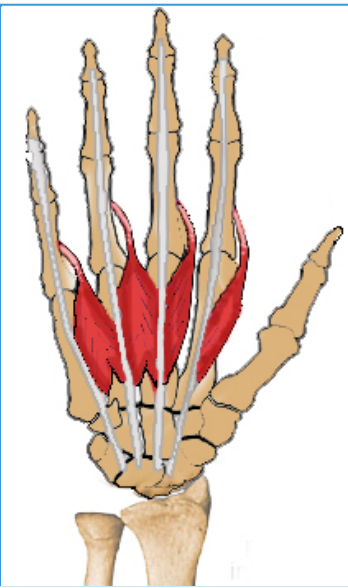
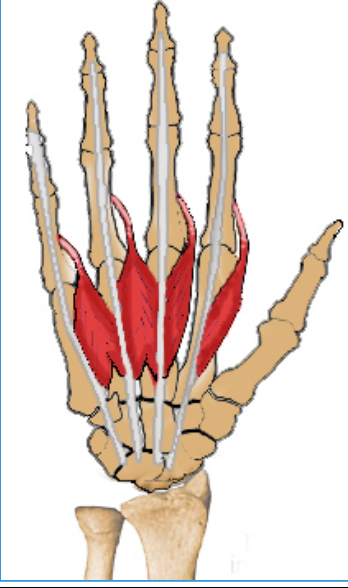
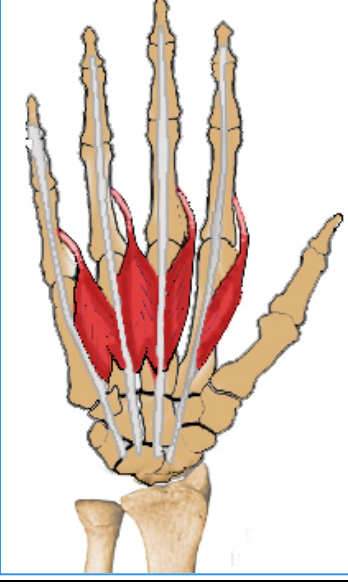
48- Palmar Interossei

- Summary

<ul style="list-style-type: none"> Palmar interossei (3 muscles) 		
<ul style="list-style-type: none"> Origin 	<ul style="list-style-type: none"> Palmar surfaces of 2nd, 4th and 5th metacarpals (3 unipennate muscles) 	
<ul style="list-style-type: none"> Insertion 	<ul style="list-style-type: none"> Extensor expansions of digits and bases of proximal phalanges of digits 2, 4 and 5 	
<ul style="list-style-type: none"> Action 	<ul style="list-style-type: none"> Adduct digits toward axial line and assist lumbricals in flexing metacarpophalangeal joints and extending interphalangeal joints 	
<ul style="list-style-type: none"> Innervation 	<ul style="list-style-type: none"> Deep branch of ulnar nerve (C8, T1) 	
<ul style="list-style-type: none"> Arterial supply 	<ul style="list-style-type: none"> Palmar metacarpal arteries 	

49- Lumbrical Muscles

- Summary

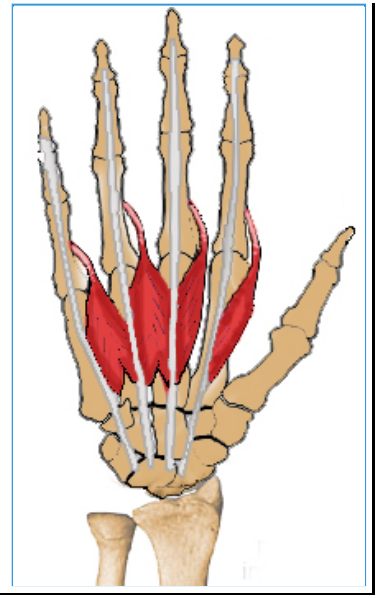
<ul style="list-style-type: none"> <ul style="list-style-type: none"> ■ Lumbricals (4 muscles) 		
<ul style="list-style-type: none"> <ul style="list-style-type: none"> ■ Origin ■ 	<ul style="list-style-type: none"> <ul style="list-style-type: none"> ■ FDP tendon 	<ul style="list-style-type: none"> <ul style="list-style-type: none"> ■ 
<ul style="list-style-type: none"> <ul style="list-style-type: none"> ■ Insertion 	<ul style="list-style-type: none"> <ul style="list-style-type: none"> ■ Radial lateral band of the extensor expansion (tendon) 	<ul style="list-style-type: none"> <ul style="list-style-type: none"> ■ 
<ul style="list-style-type: none"> <ul style="list-style-type: none"> ■ Action 	<ul style="list-style-type: none"> <ul style="list-style-type: none"> ■ Extends PIP and DIP joint. 	<ul style="list-style-type: none"> <ul style="list-style-type: none"> ■ 
<ul style="list-style-type: none"> <ul style="list-style-type: none"> ■ Innervation 	<ul style="list-style-type: none"> <ul style="list-style-type: none"> ■ 1st & 2nd lumbricals: median nerve . ■ 3rd & 4th lumbricals: ulnar nerve 	<ul style="list-style-type: none"> <ul style="list-style-type: none"> ■ 

- **Arterial supply**

- Palmar metacarpal arteries

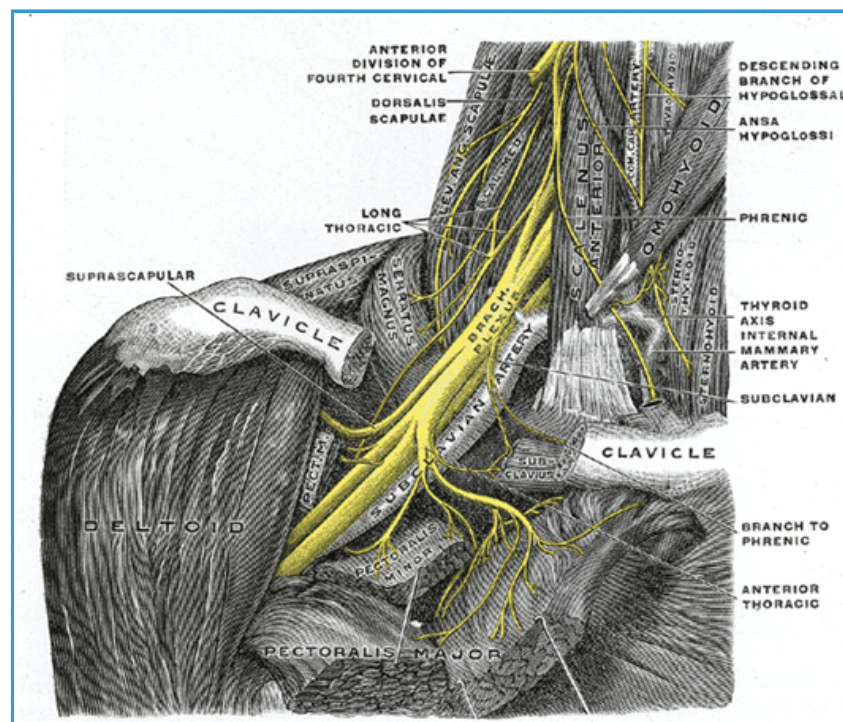
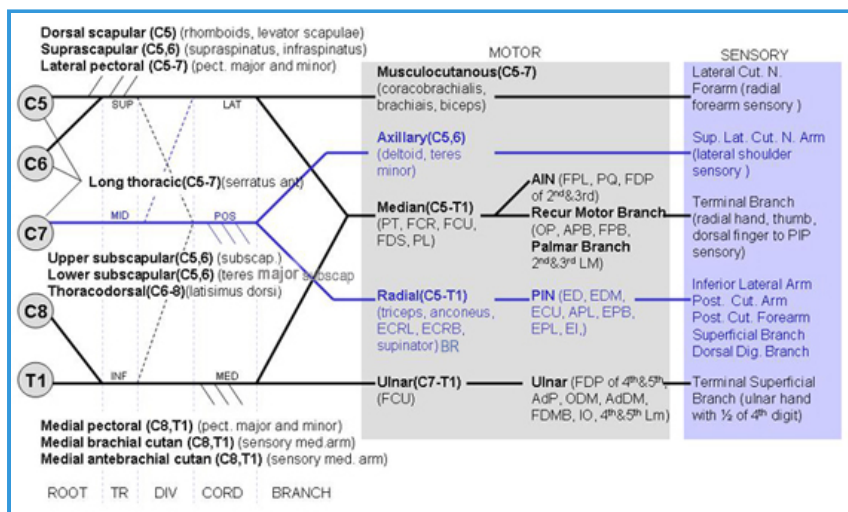
-

-



50- Brachial Plexus

Images



• Introduction

- Standard: C5, C6, C7, C8, T1 - 77% of patients
- Prefixed: Prefixed (contributions from C3, C4) - 22%
- Postfixed (roots caudal to T1) - 1%



• Anatomy




- Remember: Robert Turner Drinks Cold Beer
- Roots (5) : ventral rami of C5-T1, superior and posterior to subclavian
 - dorsal scapular nerve (C5): through levator scapula to supply levator scapula, rhomboid major & minor
 - long thoracic nerve (C5, 6, 7): posterior to plexus onto thoracic wall to supply serratus anterior
- Trunks (3): emerge from triangle formed by anterior scalene, middle scalene, first rib
 - superior (C5,6 roots)
 - suprascapular nerve (C5, 6): through suprascapular notch to suprascapular, infraspinatus, AC and glenohumeral joints
 - nerve to subclavius (C5, 6)
 - middle (C7)
 - inferior (C8, T1)
- Divisions (6): 3 anterior, 3 posterior (each trunk gives 1 anterior and 1 posterior division)

- Cords (3):
 - Posterior Cord: formed from 3 posterior division
 - upper subscapular nerve (C5, 6): subscapularis
 - lower subscapular nerve (C5,6): subscapularis, teres major
 - thoracodorsal nerve (C6, 7, 8): latissimus dorsi
 - Lateral Cord: ant divisions of superior & middle trunks (C5, 6, 7)
 - lateral pectoral nerve (C5, 6, 7): pectoralis major, communication with medial pectoral nerve
 - Medial Cord: anterior division of inferior trunk (C8, T1) Branches (6) - 2 terminal branches from each cord
 - medial pectoral nerve (C8, T1): pierces pec minor; supplies pec minor and major
 - medial brachial cutaneous nerve (T1)
 - medial antebrachial cutaneous nerve (C8, T1)
 - Posterior cord:
 - axillary nerve (C5, 6): through quadrilateral space to teres minor, deltoid, major nerve supply to glenohumeral joint, superior lateral brachial cutaneous nerve
 - radial nerve (C5 - T1): runs with long head of triceps (triangular interval) into radial groove on posterior humerus; supplies elbow & forearm extensors, supinator; posterior brachial cutaneous, inferior lateral brachial cutaneous, posterior antebrachial cutaneous, superficial radial (post. radial hand)
 - Lateral cord:
 - lateral cord of median nerve (C5 - C7): joins medial cord anterior to axillary artery then travels with artery: wrist flexors (except FCU, ulnar \hat{A} $\frac{1}{2}$ FDP), pronators, radial two lumbricals, OP, APB, superficial head FPB); sensory distribution in hand
 - musculocutaneous (C5, 6, 7): most superficial branch, pierces coracobrachialis (1.5-9 cm from origin) to supply biceps, coracobrachialis, brachialis, ends as lateral antebrachial cutaneous nerve
 - Medial cord:
 - medial cord of median nerve (C8, T1): see above
 - ulnar nerve (C8, T1): FCU, \hat{A} $\frac{1}{2}$ FDP, adductor pollicis, deep head FPB, hypothenar, intrinsics (except radial 2 lumbricals), sensory to hand

51- Psoas

- Summary



<ul style="list-style-type: none">○ ■ Psoas <ul style="list-style-type: none">■ Origin■	<ul style="list-style-type: none">■ Anterior surfaces and lower borders of transverse processes of L1 - L5 and bodies and discs of T12 - L5	<ul style="list-style-type: none">■ 
<ul style="list-style-type: none">■ Insertion	<ul style="list-style-type: none">■ Lesser trochanter	<ul style="list-style-type: none">■ 
<ul style="list-style-type: none">■ Action■	<ul style="list-style-type: none">■ Flex the torso and thigh with respect to each other	<ul style="list-style-type: none">■


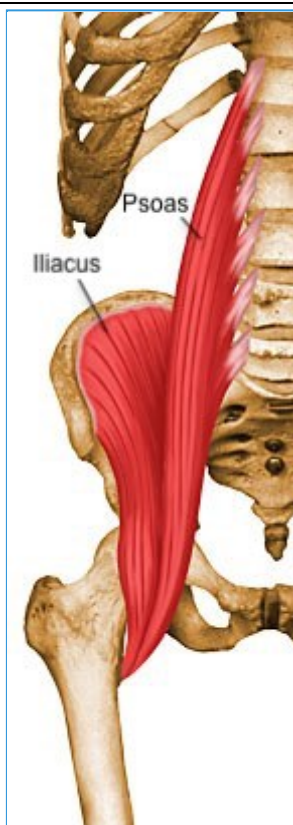

		
<ul style="list-style-type: none"> ■ Innervation ■ 	<ul style="list-style-type: none"> ■ Direct fibers of L1 - L3 of lumbar plexus (L1, L2, L3) 	<ul style="list-style-type: none"> ■ 
<ul style="list-style-type: none"> ■ Arterial Supply ■ 	<ul style="list-style-type: none"> ■ Lumbar branch of iliopsoas branch of internal iliac artery 	<ul style="list-style-type: none"> ■ 

52- Iliacus

- Summary

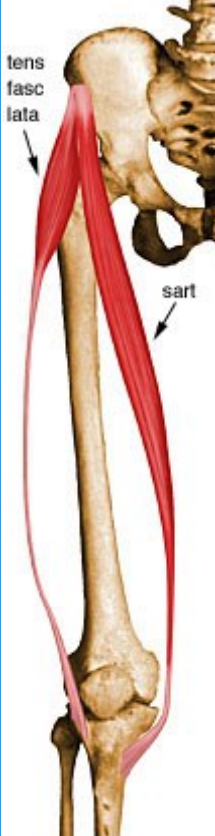
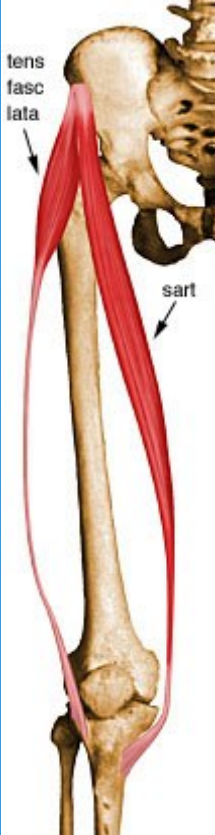
- ■ Iliacus

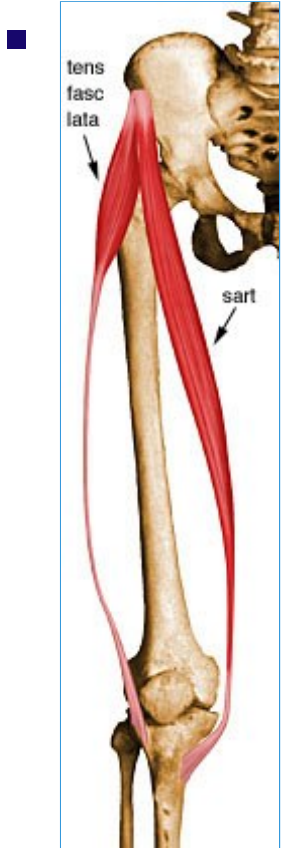
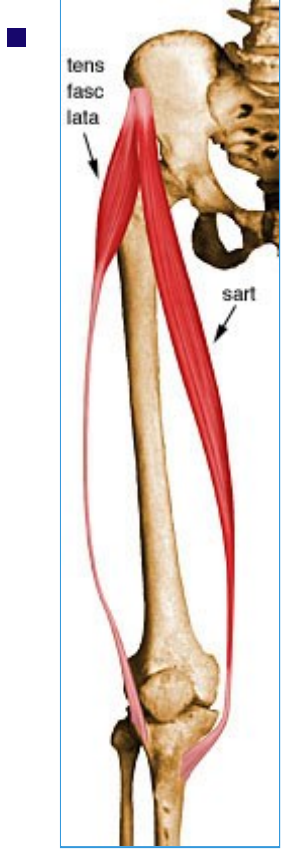
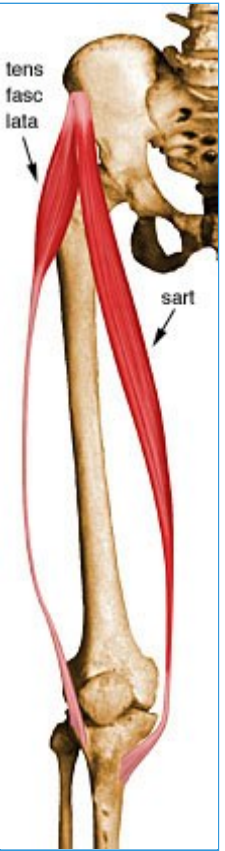<ul style="list-style-type: none">■ Origin	<ul style="list-style-type: none">■ Upper 2/3 of iliac fossa, internal lip of iliac crest, lateral aspect of sacrum, ventral sacroiliac ligament, and lower portion of iliolumbar ligament	<ul style="list-style-type: none">■ 
<ul style="list-style-type: none">■ Insertion	<ul style="list-style-type: none">■ Lesser trochanter	<ul style="list-style-type: none">■ 
<ul style="list-style-type: none">■ Action	<ul style="list-style-type: none">■ Flex the torso and thigh with respect to each other	<ul style="list-style-type: none">■

		
<ul style="list-style-type: none"> ■ Innervation 	<ul style="list-style-type: none"> ■ Muscular branch of femoral nerve (L1, L2, L3) 	<ul style="list-style-type: none"> ■ 
<ul style="list-style-type: none"> ■ Arterial Supply 	<ul style="list-style-type: none"> ■ Lumbar branch of iliopsoas branch of internal iliac artery 	<ul style="list-style-type: none"> ■ 

53- Sartorius

- Summary

<ul style="list-style-type: none"> Sartorius 		
<ul style="list-style-type: none"> Origin 	<ul style="list-style-type: none"> Anterior superior iliac spine 	
<ul style="list-style-type: none"> Insertion 	<ul style="list-style-type: none"> Superior aspect of the medial surface of the tibial shaft near the tibial tuberosity (joins gracilis and semitendinosus at the pes anserinus) 	
<ul style="list-style-type: none"> Action 	<ul style="list-style-type: none"> Flexes and laterally rotates the hip joint and flexes the knee 	



■ **Innervation**

- Femoral nerve (L2, L3, L4)

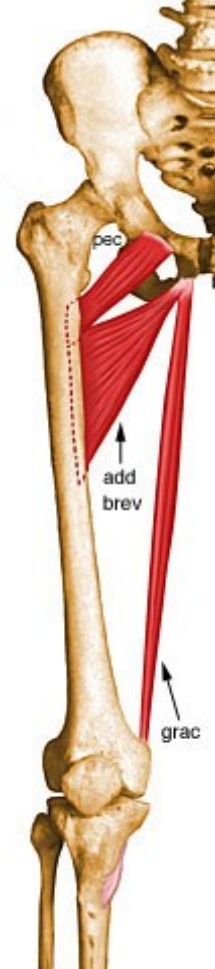
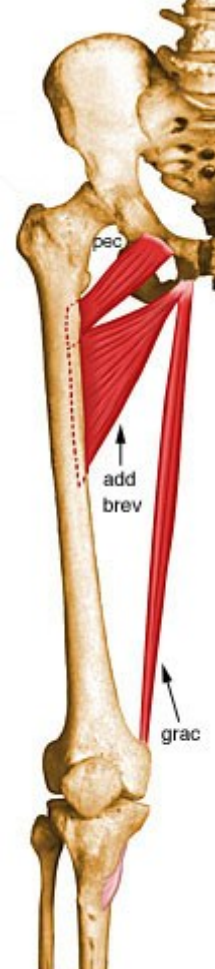
■ **Arterial Supply**

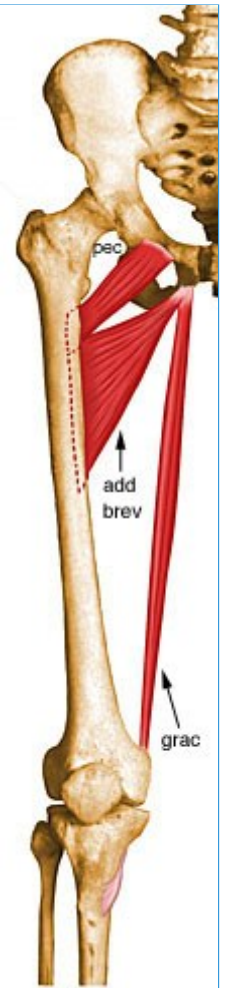
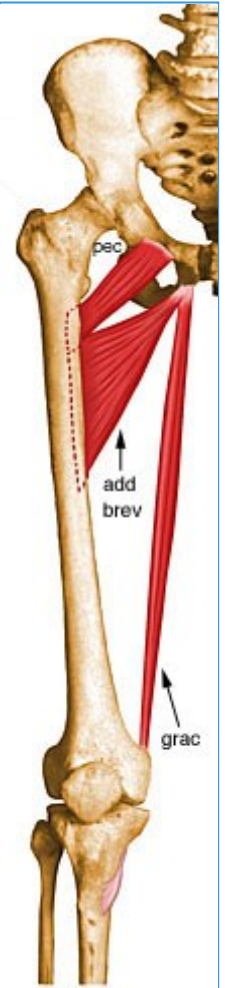
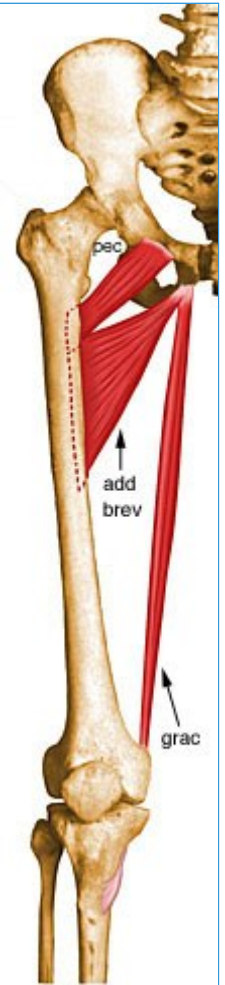
■

- Muscular branches of the femoral artery

54- Pectineus

- Summary

<ul style="list-style-type: none">○ ■ Pectineus		
<ul style="list-style-type: none">■ Origin	<ul style="list-style-type: none">■ Pecten pubis and pectineal surface of the pubis	 <ul style="list-style-type: none">■
<ul style="list-style-type: none">■ Insertion	<ul style="list-style-type: none">■ Pectineal line of femur	 <ul style="list-style-type: none">■
<ul style="list-style-type: none">■ Action	<ul style="list-style-type: none">■ Adducts the thigh and flexes the hip joint	<ul style="list-style-type: none">■



- **Innervation**

-

- Femoral nerve (L2, L3, L4)

-

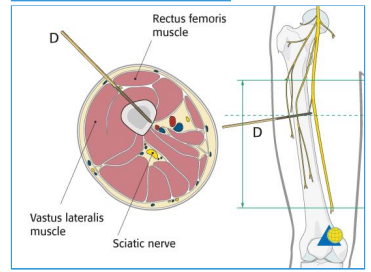
- **Arterial Supply**

- Medial circumflex femoral branch of femoral artery and obturator artery

55- Rectus Femoris

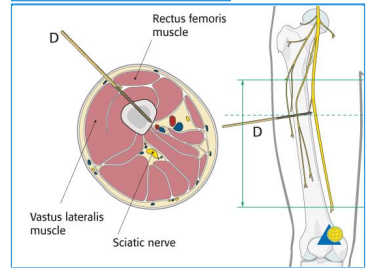
- Summary

<ul style="list-style-type: none"> Rectus femoris 	<ul style="list-style-type: none"> Origin Straight head from anterior inferior iliac spine; reflected head from groove just above acetabulum 	<ul style="list-style-type: none">
<ul style="list-style-type: none"> Insertion 	<ul style="list-style-type: none"> Base of patella to form the more central portion of the quadriceps femoris tendon 	<ul style="list-style-type: none">
<ul style="list-style-type: none"> Action 	<ul style="list-style-type: none"> Extends the knee, accessory flexor of hip 	<ul style="list-style-type: none">



■ **Innervation**

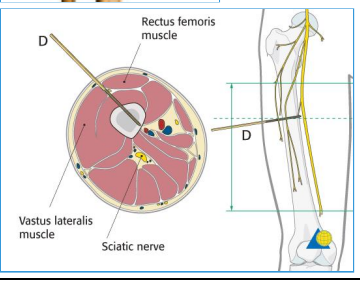
- Muscular branches of femoral nerve (L2, L3, L4)



■ **Arterial Supply**

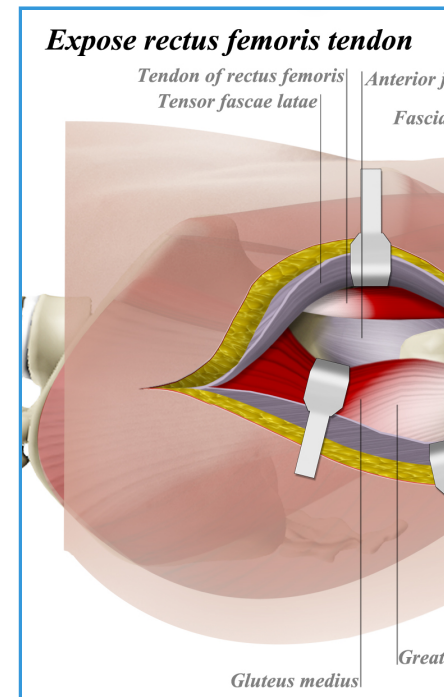
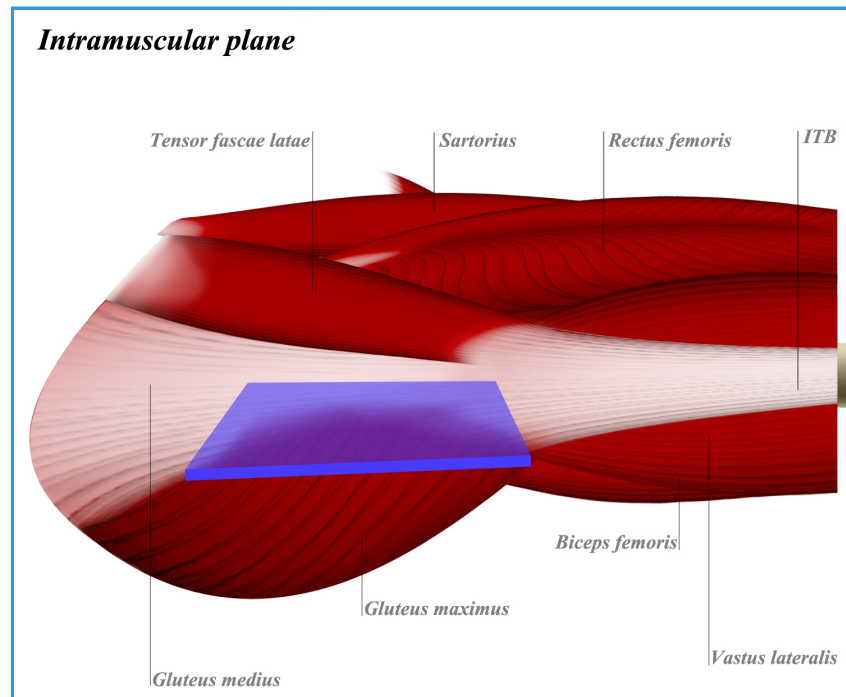
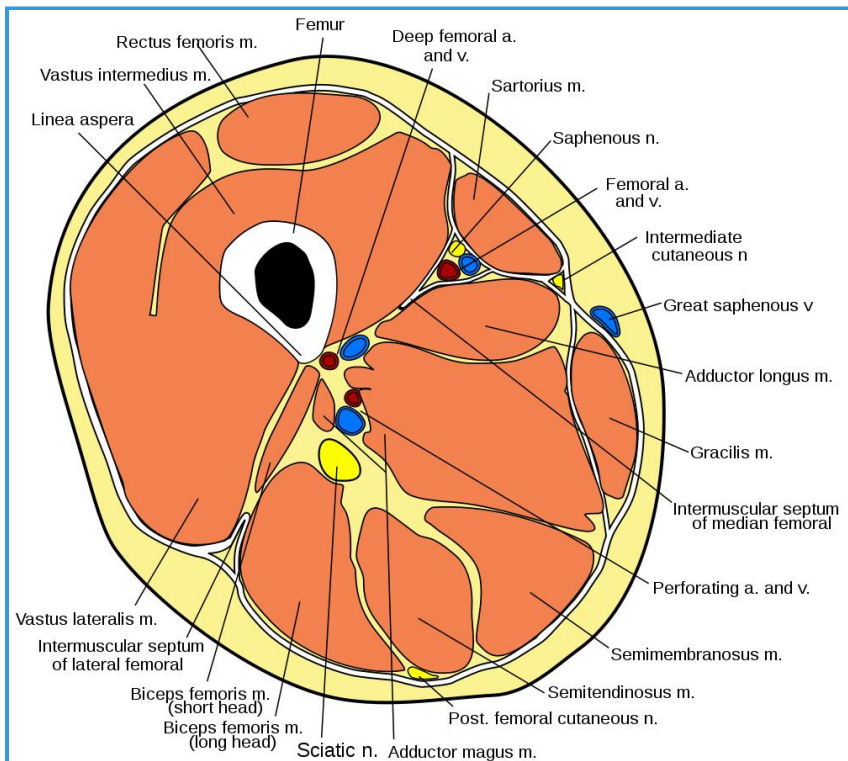
- Lateral circumflex femoral artery



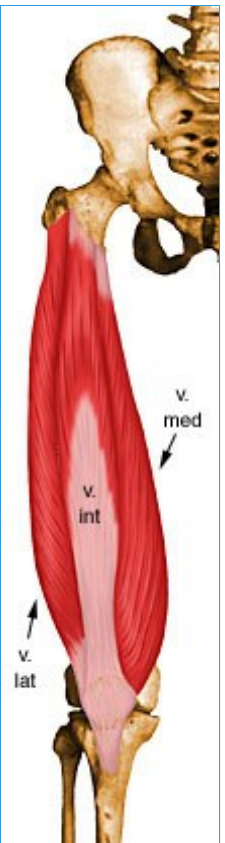


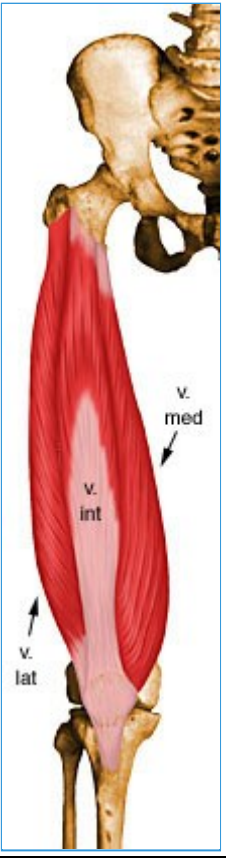
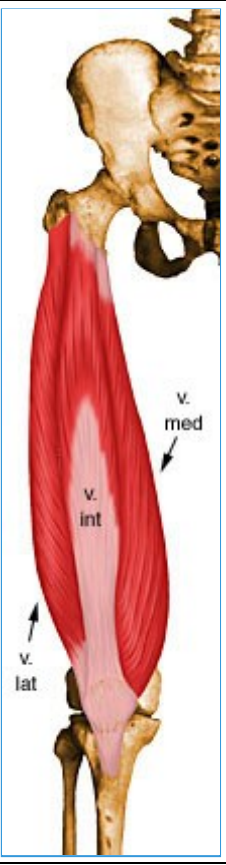
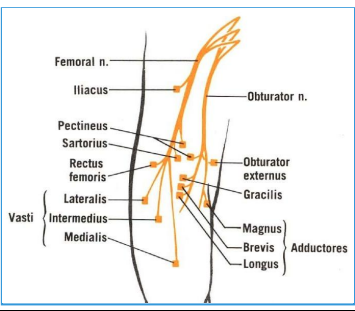
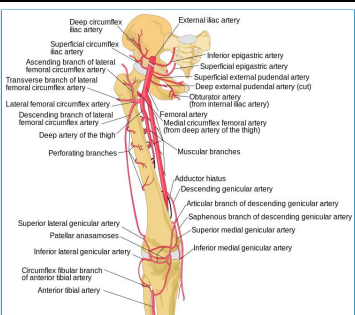
56- Vastus Lateralis

Images



SUMMARY

<ul style="list-style-type: none"> ■ Vastus lateralis 		
<ul style="list-style-type: none"> ■ Origin 	<ul style="list-style-type: none"> ■ Superior portion of intertrochanteric line, anterior and inferior borders of greater trochanter, superior portion of lateral lip of linea aspera, and lateral portion of gluteal tuberosity of femur 	
<ul style="list-style-type: none"> ■ Insertion 	<ul style="list-style-type: none"> ■ Lateral base and border of patella; also forms the lateral patellar retinaculum and lateral side of quadriceps femoris tendon 	<ul style="list-style-type: none"> ■

		
<ul style="list-style-type: none"> ■ Action ■ 	<ul style="list-style-type: none"> ■ Extends the knee 	
<ul style="list-style-type: none"> ■ Innervation ■ 	<ul style="list-style-type: none"> ■ Muscular branches of femoral nerve (L2, L3, L4) 	
<ul style="list-style-type: none"> ■ Arterial Supply 	<ul style="list-style-type: none"> ■ Lateral circumflex femoral artery 	

- **Innervation**

- Vastus lateralis is supplied by the muscular branches of the femoral nerve
- Primary nerves of the anterior thigh
 - obturator nerve
 - femoral nerve
 - origin
 - L2-4 of lumbar plexus

- motor
 - extensors of the knee
 - rectus femoris
 - vastus lateralis
 - vastus medialis
 - vastus intermedius
- sensory
 - none
- course
 - descends in the abdomen through the psoas
 - runs behind inguinal ligament and into the thigh where it splits into an anterior and posterior division
 - passes through femoral triangle lateral to femoral vessels
 - terminal cutaneous branch is the saphenous nerve

• Blood Supply

- Vastus lateralis is primarily supplied by lateral circumflex artery, a branch of femoral artery
- Femoral artery
 - branches in thigh
 - profunda femoris
 - medial femoral circumflex
 - lateral femoral circumflex
 - lateral to rectus femoris
 - branches
 - ascending branch - runs towards ASIS between sartorius and TFL
 - requires ligation during anterior approach to hip
 - transverse branch - joins branch of medial femoral circumflex
 - descending branch - runs between vastus intermedius and lateralis muscles
 - encountered in anterolateral approach to femur

• Cross Sectional Anatomy

- Vastus lateralis lies in the anterior compartment of the thigh
 - anterior compartment consists of
 - rectus femoris (femoral n.)
 - vastus lateralis (femoral n.)

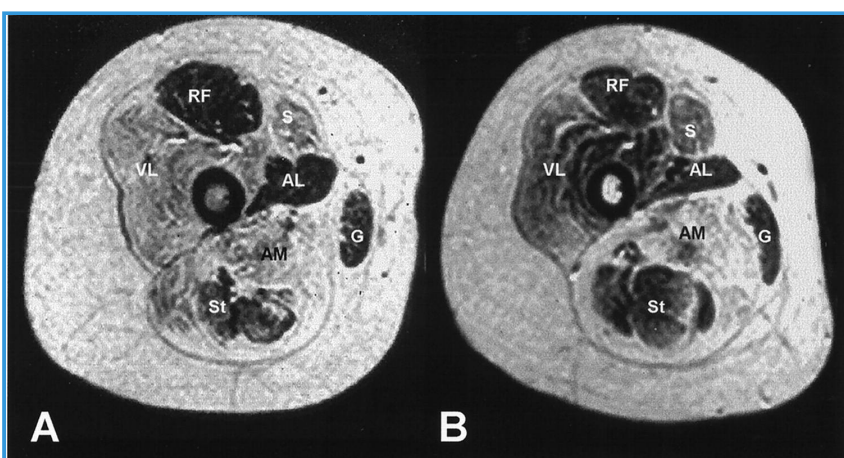
- vastus medialis (femoral n.)
- vastus lateralis (femoral n.)
- vastus lateralis is bordered by
 - at the level of the greater trochanter
 - lateral
 - subcutaneous tissue
 - medial
 - femur
 - vastus intermedius
 - vastus intermedius (anterior/medial)
 - anteromedial
 - rectus femoris
 - posteromedial
 - intermuscular septum
 - sciatic nerve
 - biceps femoris

- Relevant Surgical Approaches

- Hip Anterolateral Approach (Watson-Jones)
- Hip Direct Lateral Approach (Hardinge, Transgluteal)
- Hip Posterior Approach (Moore or Southern)
- Femur Lateral Approach
- Femur Posterolateral Approach

- Related Anatomy

- Quadriceps contusion

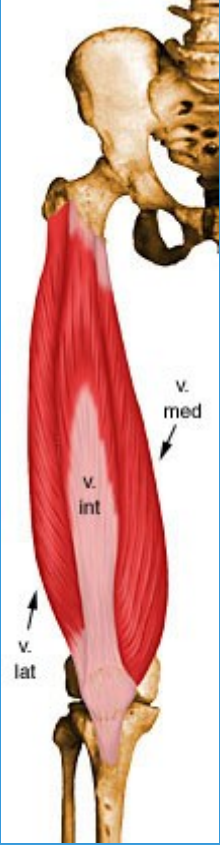
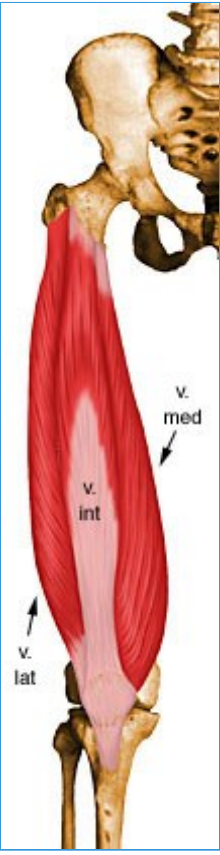


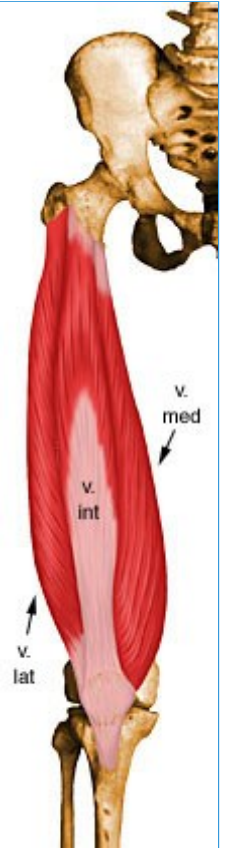
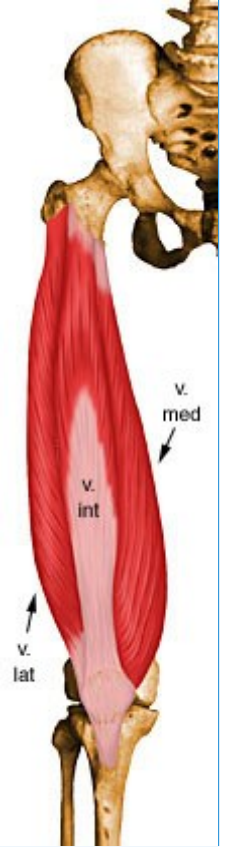
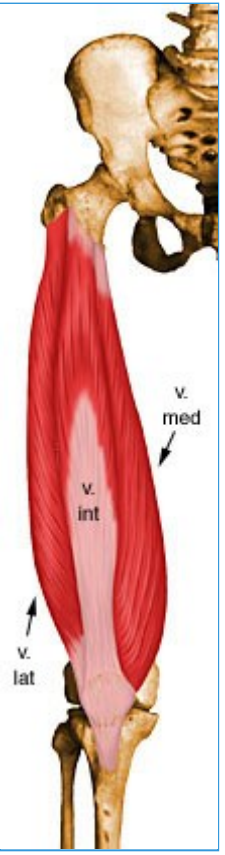
- Clinical Conditions

- Quadriceps contusion

57- Vastus Intermedius

- Summary

<ul style="list-style-type: none">○ ■ Vastus intermedius <ul style="list-style-type: none">■ Origin■	<ul style="list-style-type: none">■ Superior 2/3 of anterior and lateral surfaces of femur; also from lateral intermuscular septum of thigh	<ul style="list-style-type: none">■ 
<ul style="list-style-type: none">■ Insertion■	<ul style="list-style-type: none">■ Lateral border of patella; also forms the deep portion of the quadriceps tendon	<ul style="list-style-type: none">■ 
<ul style="list-style-type: none">■ Action	<ul style="list-style-type: none">■ Extends the knee	<ul style="list-style-type: none">■



■ **Innervation**

■

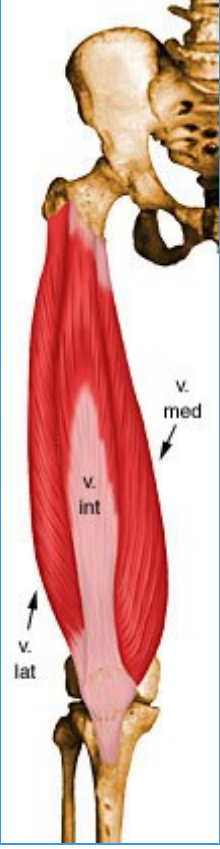
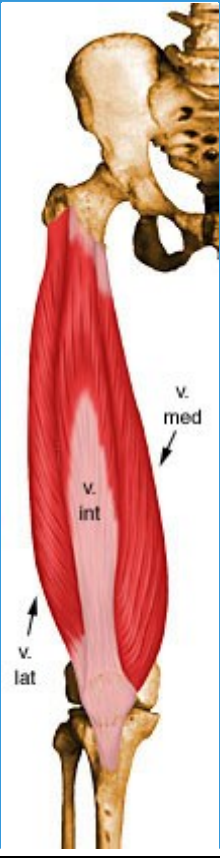

■ Muscular branches of femoral nerve (L2, L3, L4)

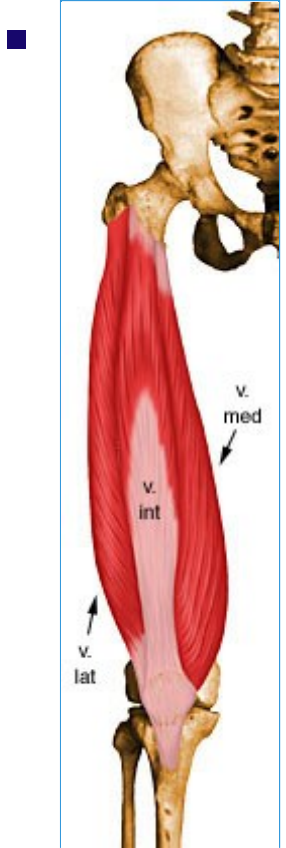
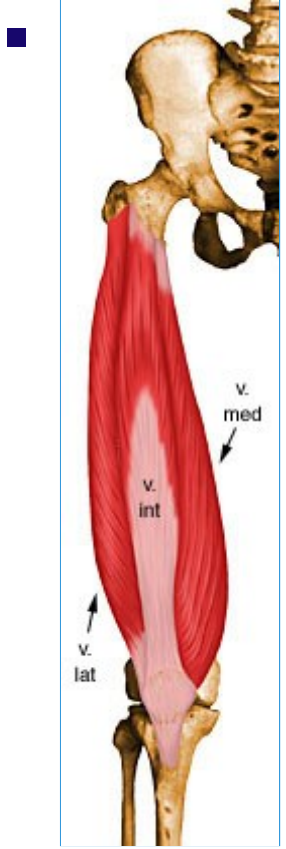
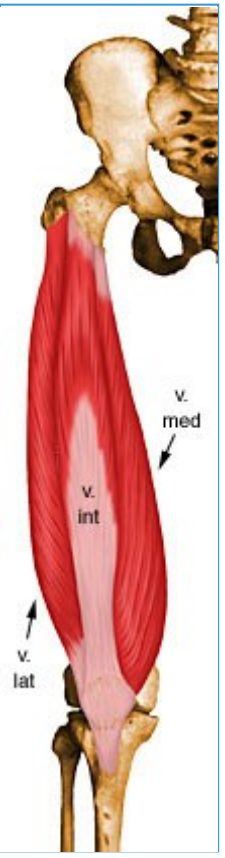
■ **Arterial supply**

■ Lateral circumflex femoral artery

58- Vastus Medialis

- Summary

<ul style="list-style-type: none">○ ■ Vastus medialis <ul style="list-style-type: none">■ Origin	<ul style="list-style-type: none">■ Inferior portion of intertrochanteric line, spiral line, medial lip of linea aspera, superior part of medial supracondylar ridge of femur, and medial intermuscular septum	<ul style="list-style-type: none">■ 
<ul style="list-style-type: none">■ Insertion	<ul style="list-style-type: none">■ Medial base and border of patella; also forms the medial patellar retinaculum and medial side of quadriceps femoris tendon	<ul style="list-style-type: none">■ 
<ul style="list-style-type: none">■ Action	<ul style="list-style-type: none">■ Extends the knee	<ul style="list-style-type: none">■ 



■ **Innervation**

■ Muscular branches of femoral nerve (L2, L3, L4)






■ **Arterial Supply**

■ Femoral artery, profunda femoris artery, and superior medial genicular branch of popliteal artery

■

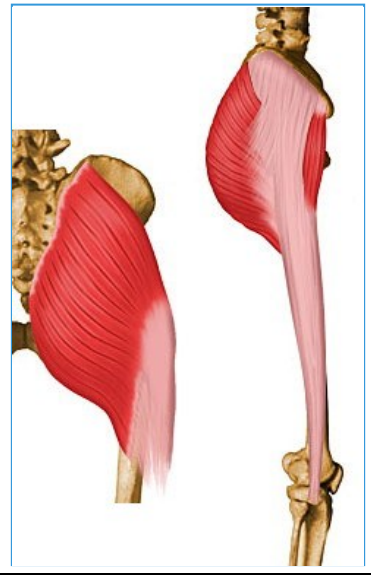
59- Gluteus Maximus

- Summary

<ul style="list-style-type: none"> <ul style="list-style-type: none"> ■ Gluteus maximus 		
<ul style="list-style-type: none"> <ul style="list-style-type: none"> ■ Origin 	<ul style="list-style-type: none"> <ul style="list-style-type: none"> <ul style="list-style-type: none"> ■ Posterior aspect of dorsal ilium posterior to posterior gluteal line, posterior superior iliac crest, posterior inferior aspect of sacrum and coccyx, and sacrotuberous ligament 	<ul style="list-style-type: none"> <ul style="list-style-type: none"> <ul style="list-style-type: none"> ■ 
<ul style="list-style-type: none"> <ul style="list-style-type: none"> ■ Insertion 	<ul style="list-style-type: none"> <ul style="list-style-type: none"> <ul style="list-style-type: none"> ■ Primarily in fascia lata at the iliotibial band; also into the gluteal tuberosity on posterior femoral surface 	<ul style="list-style-type: none"> <ul style="list-style-type: none"> <ul style="list-style-type: none"> ■ 
<ul style="list-style-type: none"> <ul style="list-style-type: none"> ■ Action 	<ul style="list-style-type: none"> <ul style="list-style-type: none"> <ul style="list-style-type: none"> ■ Major extensor of hip joint, assists in laterally rotating the thigh; upper and middle third section of the muscle are abductors 	<ul style="list-style-type: none"> <ul style="list-style-type: none"> <ul style="list-style-type: none"> ■ 
<ul style="list-style-type: none"> <ul style="list-style-type: none"> ■ Innervation 	<ul style="list-style-type: none"> <ul style="list-style-type: none"> <ul style="list-style-type: none"> ■ Inferior gluteal nerve (L5, S1, S2) 	<ul style="list-style-type: none"> <ul style="list-style-type: none"> <ul style="list-style-type: none"> ■ 
		<ul style="list-style-type: none"> <ul style="list-style-type: none"> <ul style="list-style-type: none"> ■ 






- **Arterial supply**

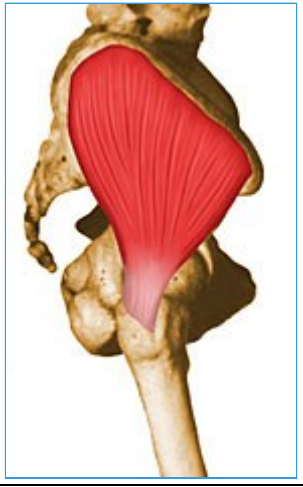
- Inferior and superior gluteal arteries and the first perforating branch of the profunda femoris artery



60- Gluteus Medius






- Summary

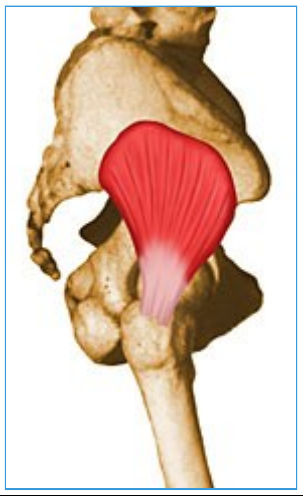
<ul style="list-style-type: none"> <ul style="list-style-type: none"> Gluteus medius 		
<ul style="list-style-type: none"> Origin 	<ul style="list-style-type: none"> Dorsal ilium inferior to iliac crest 	<ul style="list-style-type: none"> 
<ul style="list-style-type: none"> Insertion 	<ul style="list-style-type: none"> Lateral and superior surfaces of greater trochanter 	<ul style="list-style-type: none"> 
<ul style="list-style-type: none"> Action 	<ul style="list-style-type: none"> Major abductor of thigh; anterior fibers help to rotate hip medially; posterior fibers help to rotate hip laterally 	<ul style="list-style-type: none"> 
<ul style="list-style-type: none"> Innervation 	<ul style="list-style-type: none"> Superior gluteal nerve (L4, L5, S1) 	<ul style="list-style-type: none"> 
<ul style="list-style-type: none"> Arterial Supply 	<ul style="list-style-type: none"> Superior gluteal artery 	<ul style="list-style-type: none"> 



61- Gluteus Minimus

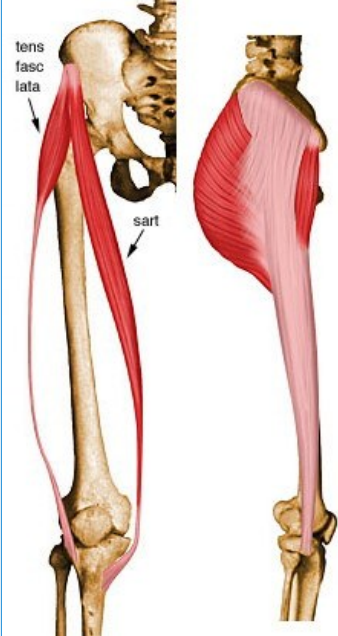
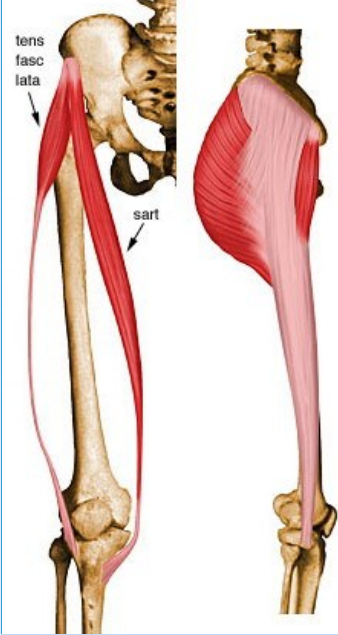
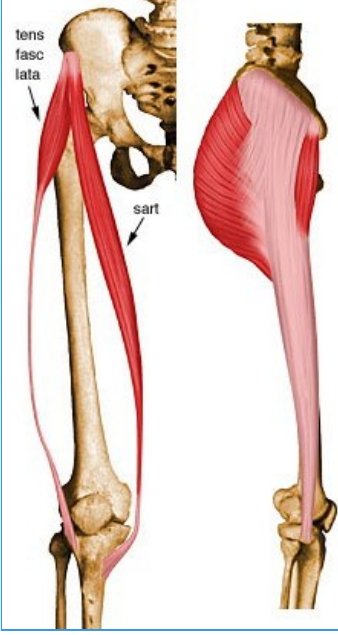
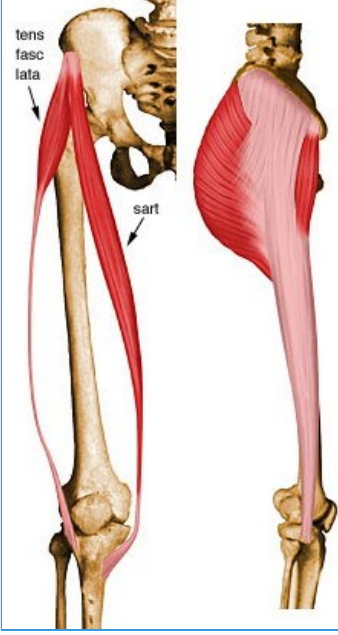
- Summary


<ul style="list-style-type: none"> <ul style="list-style-type: none"> ■ Gluteus minimus 		
<ul style="list-style-type: none"> <ul style="list-style-type: none"> ■ Origin 	<ul style="list-style-type: none"> <ul style="list-style-type: none"> ■ Dorsal ilium between inferior and anterior gluteal lines; also from edge of greater sciatic notch 	<ul style="list-style-type: none"> <ul style="list-style-type: none"> ■ 
<ul style="list-style-type: none"> <ul style="list-style-type: none"> ■ Insertion 	<ul style="list-style-type: none"> <ul style="list-style-type: none"> ■ Anterior surface of greater trochanter 	<ul style="list-style-type: none"> <ul style="list-style-type: none"> ■ 
<ul style="list-style-type: none"> <ul style="list-style-type: none"> ■ Action 	<ul style="list-style-type: none"> <ul style="list-style-type: none"> ■ Abducts and internally rotates the hip joint 	<ul style="list-style-type: none"> <ul style="list-style-type: none"> ■ 
<ul style="list-style-type: none"> <ul style="list-style-type: none"> ■ Innervation 	<ul style="list-style-type: none"> <ul style="list-style-type: none"> ■ Superior gluteal nerve (L4, L5, S1) 	<ul style="list-style-type: none"> <ul style="list-style-type: none"> ■ 
<ul style="list-style-type: none"> <ul style="list-style-type: none"> ■ Arterial supply 	<ul style="list-style-type: none"> <ul style="list-style-type: none"> ■ Superior gluteal artery 	<ul style="list-style-type: none"> <ul style="list-style-type: none"> ■ 




62- Tensor Fascia Lata

- Summary

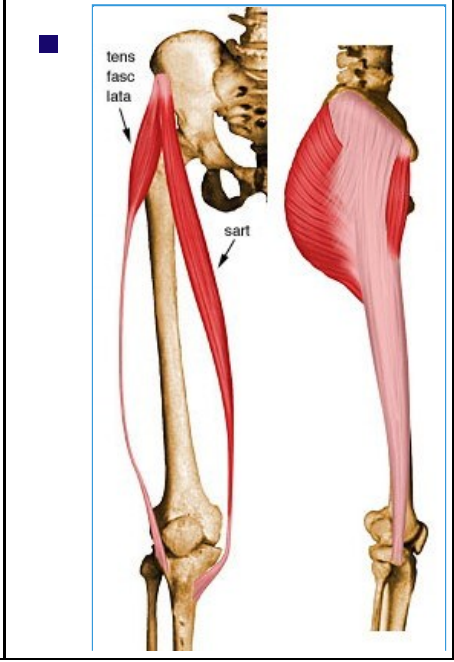
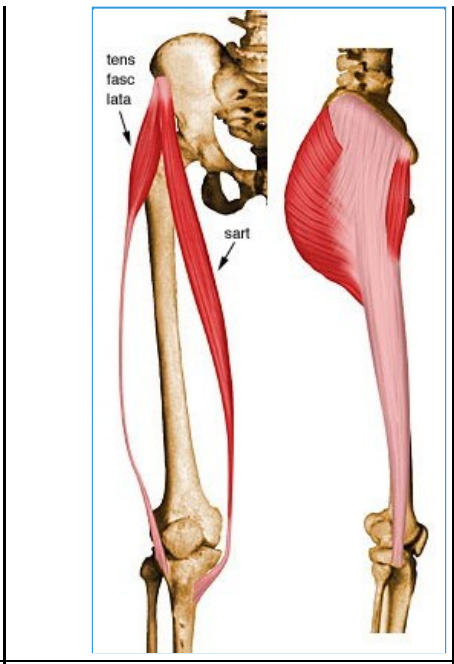
<ul style="list-style-type: none"> Tensor fascia lata 	<ul style="list-style-type: none"> Origin 	
<ul style="list-style-type: none"> Insertion 	<ul style="list-style-type: none"> Iliotibial band (Gerdy's tubercle) 	
<ul style="list-style-type: none"> Action 	<ul style="list-style-type: none"> Helps stabilize and steady the hip and knee joints by putting tension on the iliotibial band of fascia 	
<ul style="list-style-type: none"> Innervation 	<ul style="list-style-type: none"> Superior gluteal nerve (L4, L5, S1) 	



- **Arterial Supply**
-



- Superior gluteal and lateral circumflex femoral artery



63- Adductor Longus

- Summary

- ■ Adductor longus

- **Origin**
-

- Anterior surface of body of pubis, just lateral to pubic symphysis



- **Insertion**
-


- Middle third of linea aspera, between the more medial adductor magnus and brevis insertions and the more lateral origin of the vastus medialis



- **Action**
-

- Adducts and flexes the thigh, and helps to laterally rotate the hip joint

-



- **Innervation**

- Anterior division of obturator nerve (L2, L3, L4)

- **Arterial supply**

- Obturator artery and medial circumflex femoral artery

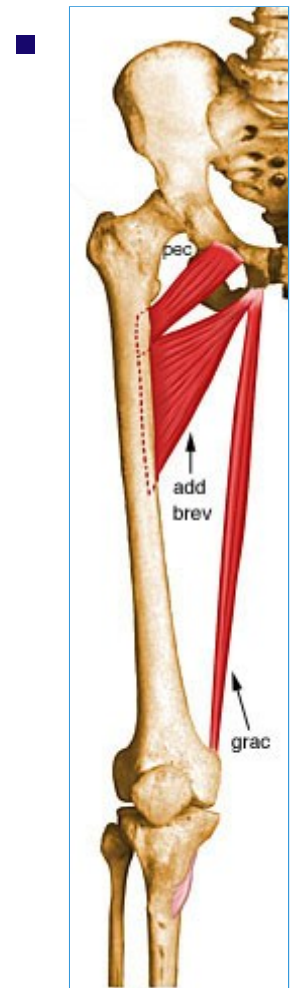
64- Adductor Brevis

- Summary

- ■ Adductor brevis

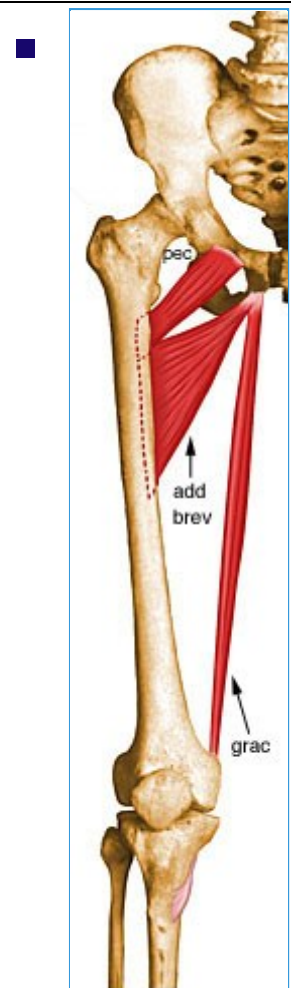
- **Origin**

- Anterior surface of inferior pubic ramus, inferior to origin of adductor longus



- **Insertion**

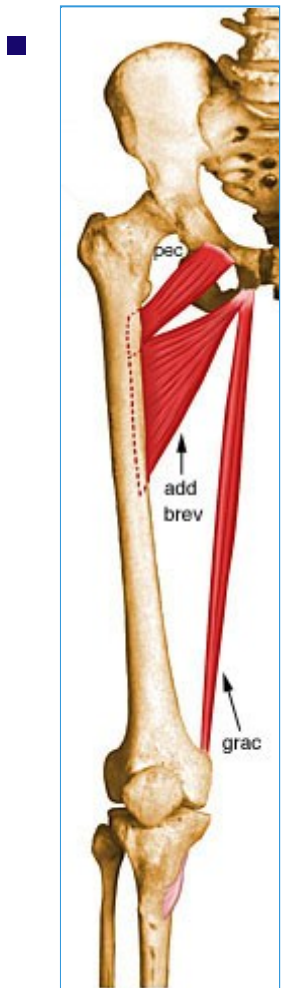
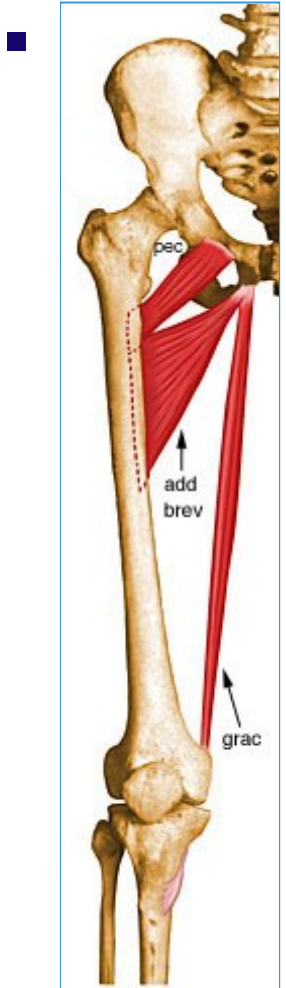
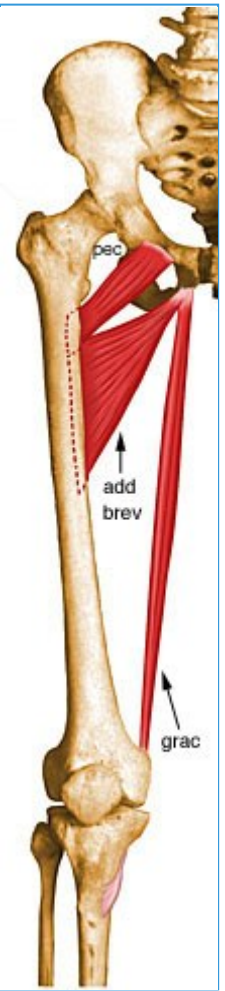
- Pectineal line and superior part of medial lip of linea aspera



- **Action**

- Adducts and flexes the thigh, and helps to laterally rotate the thigh





■ **Innervation**

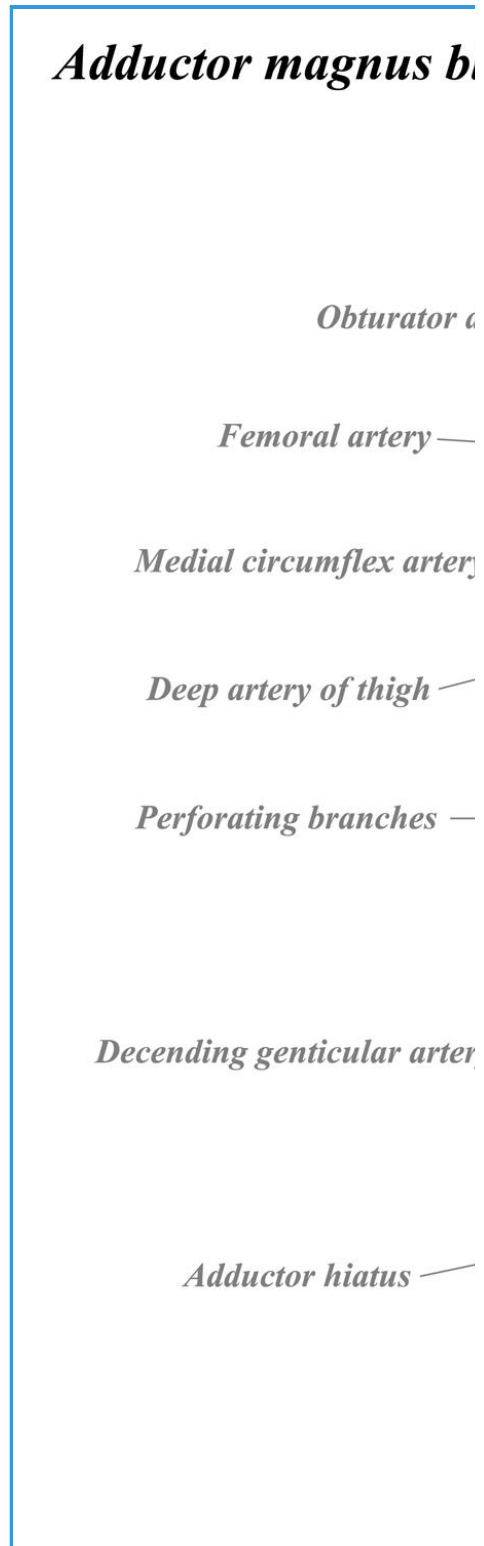
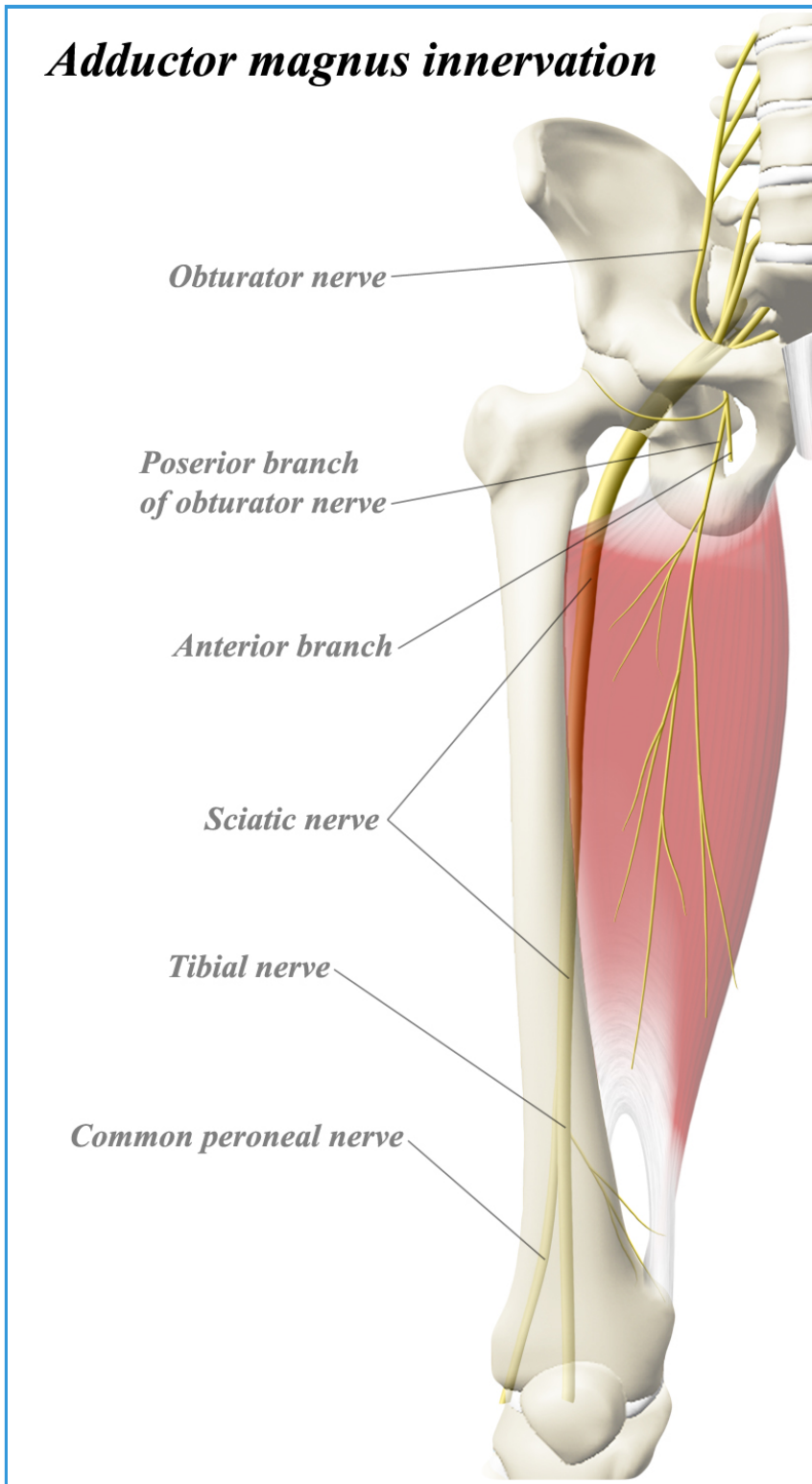
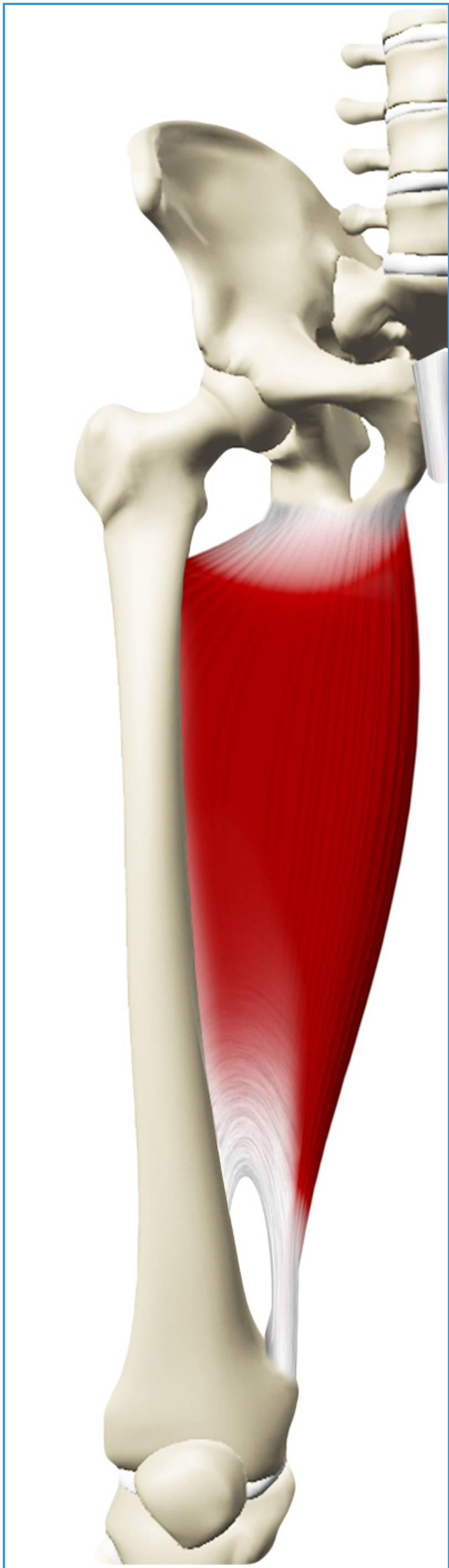
- Obturator nerve (L2, L3, L4)

■ **Arterial supply**

- Obturator artery and medial circumflex femoral artery

65- Adductor Magnus

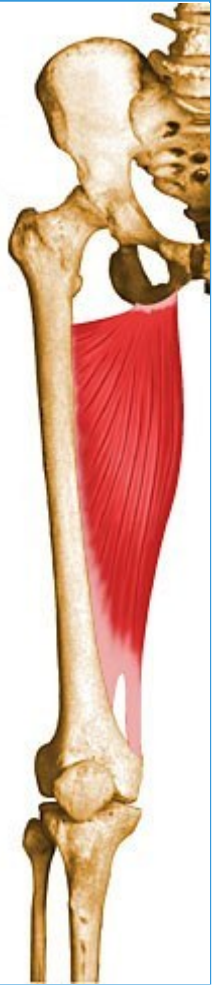Images



■ Adductor magnus

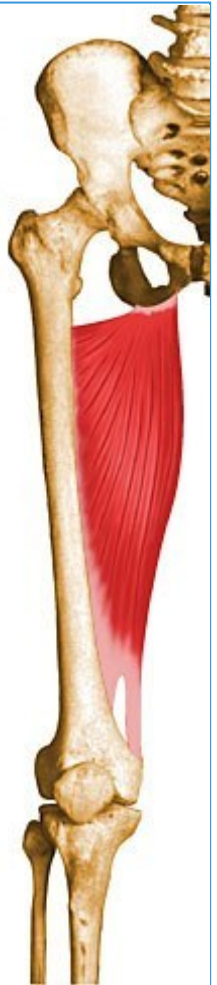■ **Origin**

- Inferior pubic ramus, ischial ramus, and inferolateral area of ischial tuberosity



■ **Insertion**

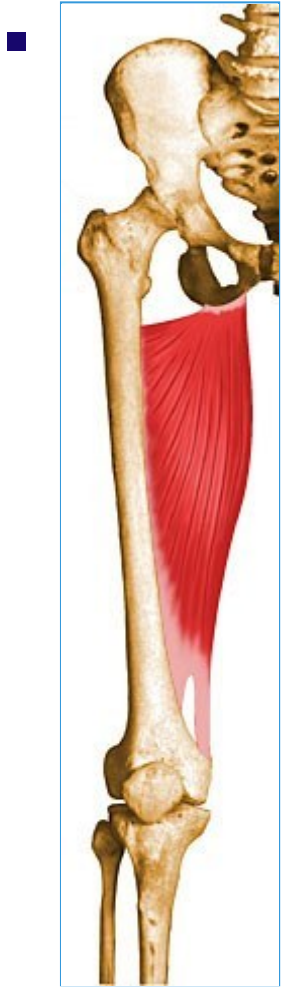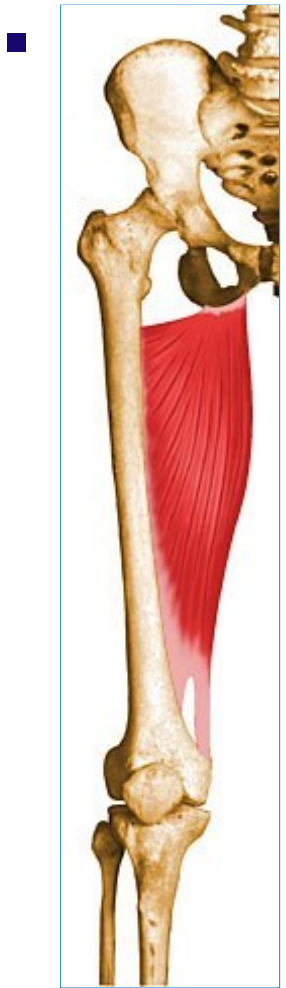- 2 separate insertions:
- 1) Gluteal tuberosity of femur, medial lip of linea aspera, medial supracondylar ridge, 2) Adductor tubercle



■ **Action**

- Powerful thigh adductor; superior horizontal fibers also help flex the thigh, while vertical fibers help extend the thigh





■ **Innervation**

- Posterior division of obturator nerve innervates most of the adductor magnus; Hamstring portion innervated by tibial nerve (L2, L3, L4)

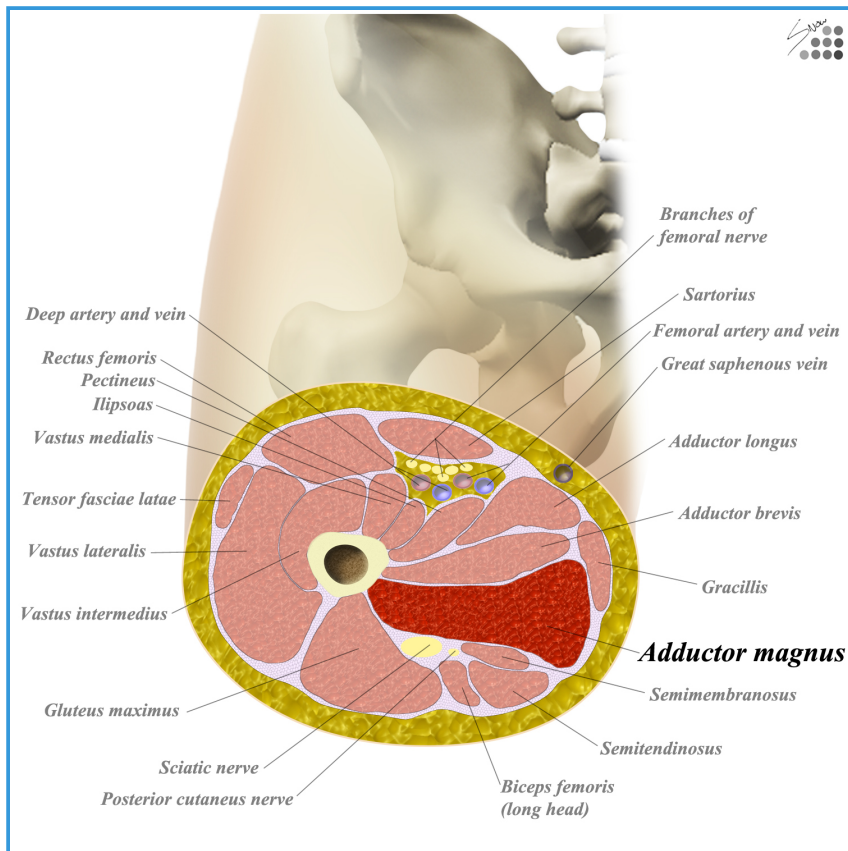
■ **Arterial supply**

- Medial circumflex femoral artery, inferior gluteal artery, 1st - 4th perforating arteries, obturator artery, and some superior muscular branches of popliteal artery

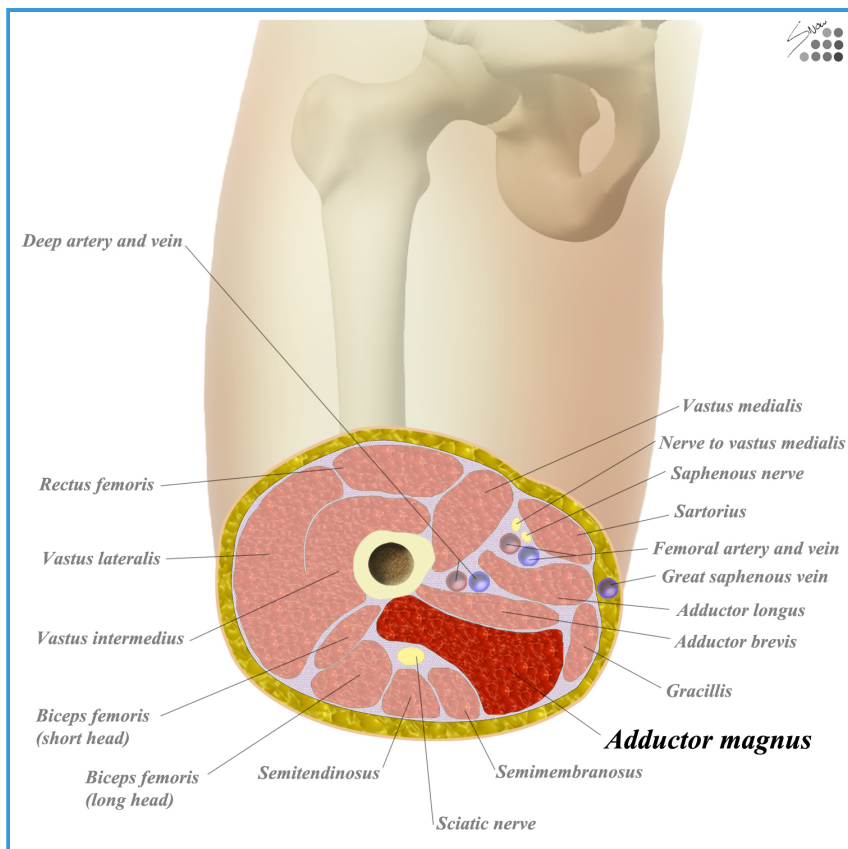
• Innervation

- Adductor magnus is innervated by the
 - obturator nerve (L2-L4) - adductor part
 - tibial nerve (L4-S3) - hamstring part
- Primary nerves of the anterior thigh
 - obturator nerve
 - origin
 - L2-4 of lumbar plexus
 - motor
 - medial compartment of thigh
 - adductor longus
 - adductor brevis
 - adductor magnus
 - gracilis
 - sensory
 - cutaneous branch innervates skin of medial thigh
 - course
 - descends through psoas and emerges at medial border
 - runs posterior to common iliac artery to the obturator foramen
 - enters thigh through obturator canal
 - splits into anterior and posterior divisions
 - anterior division - descends between adductor longus and brevis
 - pierces fascia lata to become the cutaneous branch of obturator nerve
 - posterior division - descends through obturator externus muscle
 - passes anterior to adductor magnus and gives off branches to supply it
 - tibial nerve
- Adductor magnus is supplied by the
 - obturator artery
 - femoral artery
 - medial femoral circumflex
 - direct and perforating branches of the deep femoral artery
- Obturator artery
 - arises from internal iliac artery in pelvis
 - bifurcates in medial thigh into two branches
 - anterior branch - pectineus, obturator externus, adductor muscles and gracilis

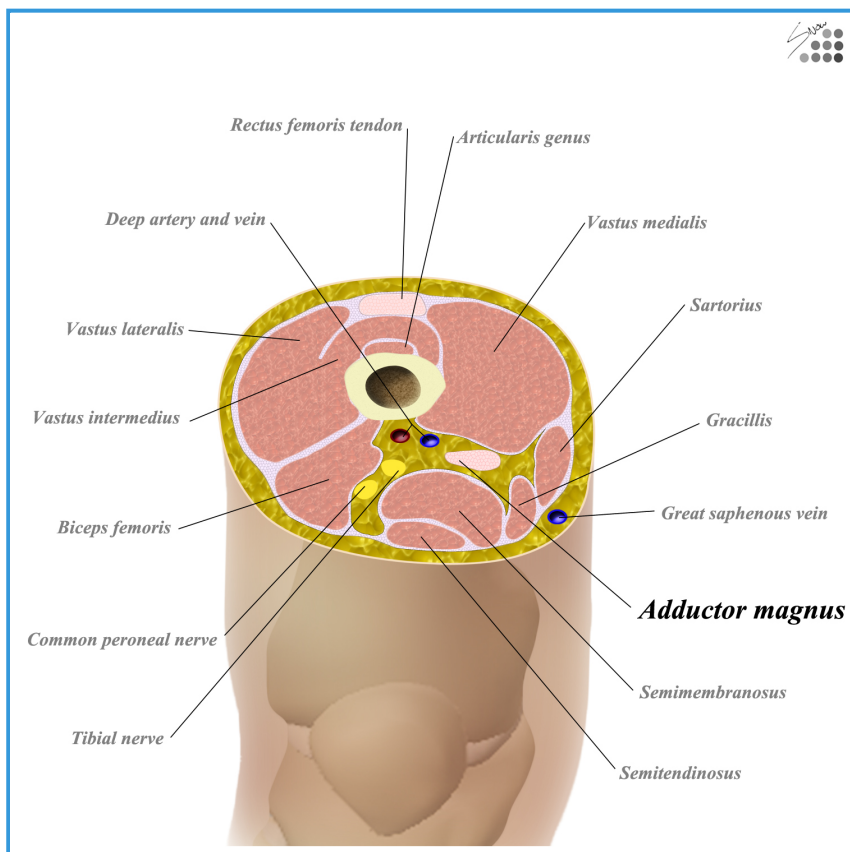
- posterior branch - deep gluteal muscles
- Femoral artery
 - branches in thigh
 - profunda femoris
 - direct and perforating branches
 - medial femoral circumflex
 - lateral femoral circumflex
- Cross section
 - high thigh



- mid thigh



- low thigh



- Adductor magnus lies in the medial compartment of the thigh.
- medial thigh compartment consists of
 - adductor brevis (obturator n.)
 - adductor longus (obturator n.)
 - adductor magnus (obturator n.)
 - gracilis (obturator n.)
- adductor magnus is bordered by
 - anterior
 - pectineus
 - adductor longus
 - adductor brevis
 - sartorius (anterior/medial)
 - medial
 - gracilis
 - sartorius (anterior/medial)
 - superior
 - obturator externus
 - quadratus femoris
 - posterior surface
 - semitendinosus
 - semimembranosus
 - biceps femoris
 - gluteus maximus

• Relevant Surgical Approaches

- Hip Medial Approach

- Clinical Images

- Obturator nerve block

- used for management of post-op pain from lower limb surgery or for chronic hip pain

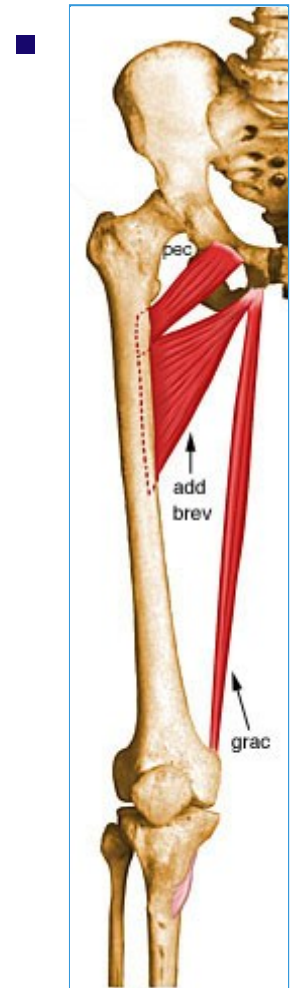
66- Gracilis

- Summary

- ■ Gracilis

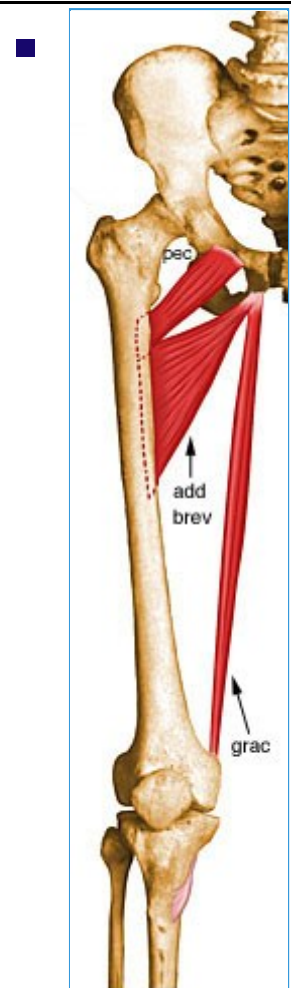
- **Origin**

- Inferior margin of pubic symphysis, inferior ramus of pubis, and adjacent ramus of ischium



- **Insertion**

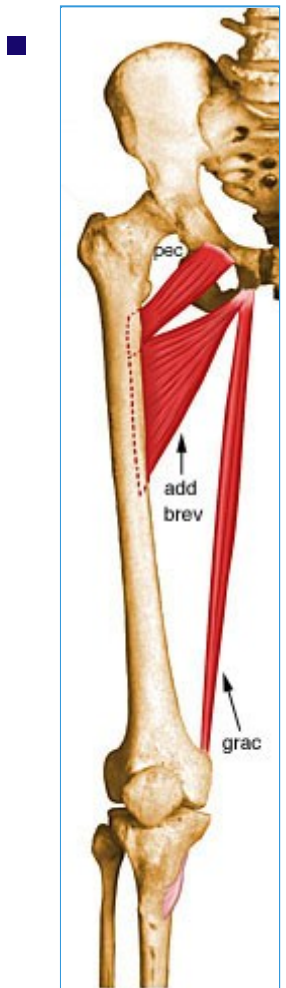
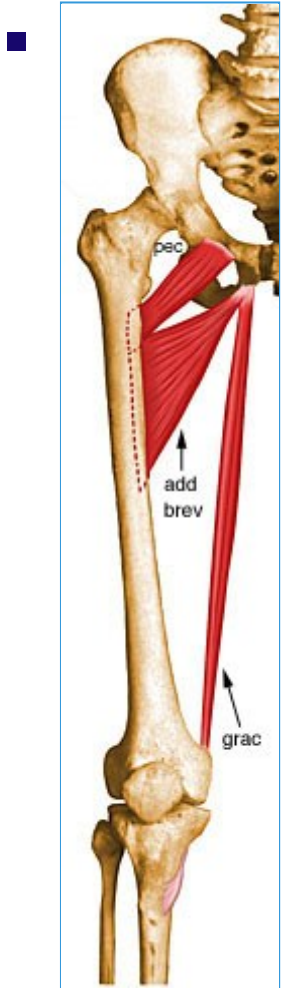
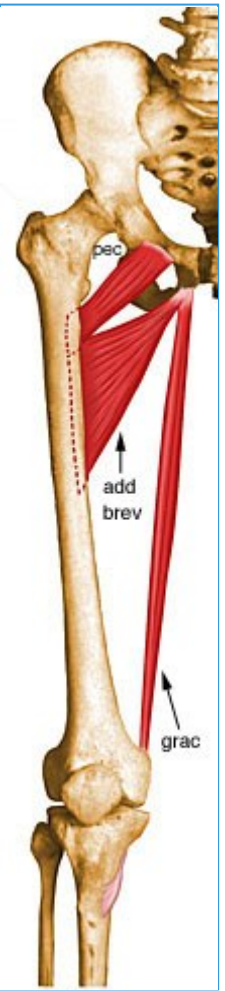
- Medial surface of tibial shaft, just posterior to sartorius



- **Action**

- Flexes the knee, adducts the thigh, and helps to medially rotate the tibia on the femur





■ **Innervation**



- Anterior division of obturator nerve (L2, L3)

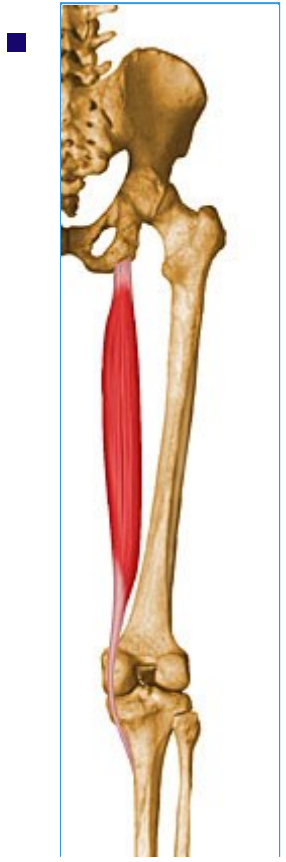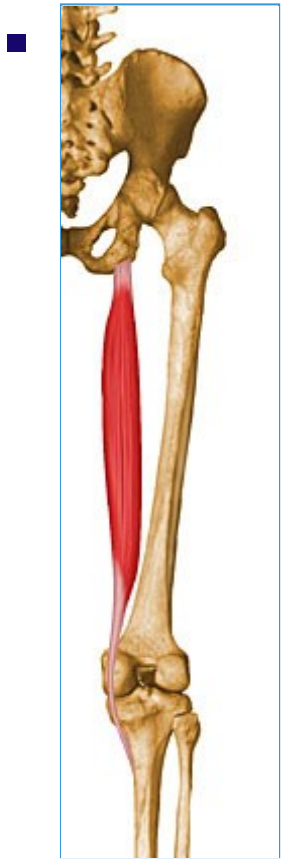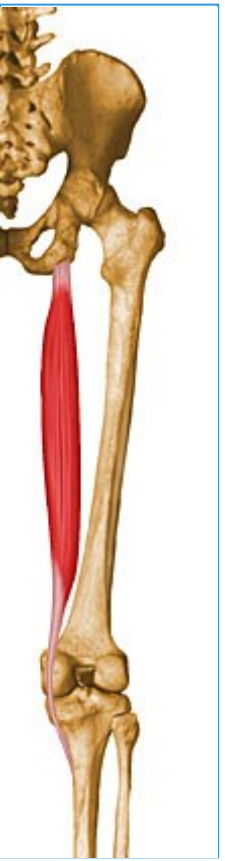■ **Arterial supply**

- Obturator artery, medial circumflex femoral artery, and muscular branches of profunda femoris artery

67- Semitendinosus

- Summary

<ul style="list-style-type: none"> <ul style="list-style-type: none"> ■ Semitendinosus 		
<ul style="list-style-type: none"> <ul style="list-style-type: none"> ■ Origin ■ 	<ul style="list-style-type: none"> <ul style="list-style-type: none"> ■ Posterior portion of the ischial tuberosity 	<ul style="list-style-type: none"> <ul style="list-style-type: none"> ■ 
<ul style="list-style-type: none"> <ul style="list-style-type: none"> ■ Insertion ■ 	<ul style="list-style-type: none"> <ul style="list-style-type: none"> ■ Superior aspect of medial portion of tibial shaft (pes anserine) 	<ul style="list-style-type: none"> <ul style="list-style-type: none"> ■ 
<ul style="list-style-type: none"> <ul style="list-style-type: none"> ■ Action ■ 	<ul style="list-style-type: none"> <ul style="list-style-type: none"> ■ Extends the thigh and flexes the knee, and also rotates the tibia medially, especially when the knee is flexed 	<ul style="list-style-type: none"> <ul style="list-style-type: none"> ■



- **Innervation**

- Tibial nerve (L5, S1, S2)

- **Arterial Supply**

- Perforating branches of profunda femoris artery, inferior gluteal artery, and the superior muscular branches of popliteal artery

-

68- Semimembranosus

- Summary

- ■ Semimembranosus

- **Origin**

- Superior lateral quadrant of the ischial tuberosity



- **Insertion**

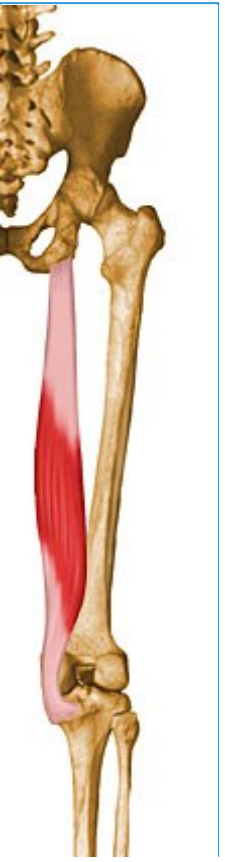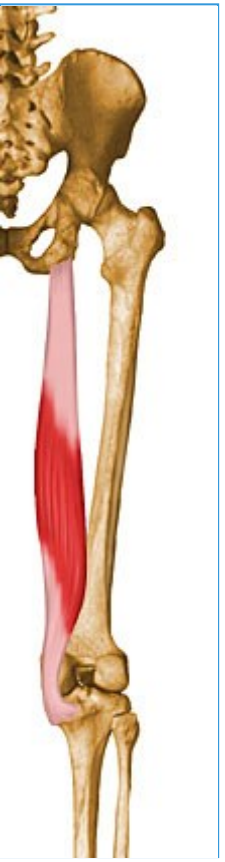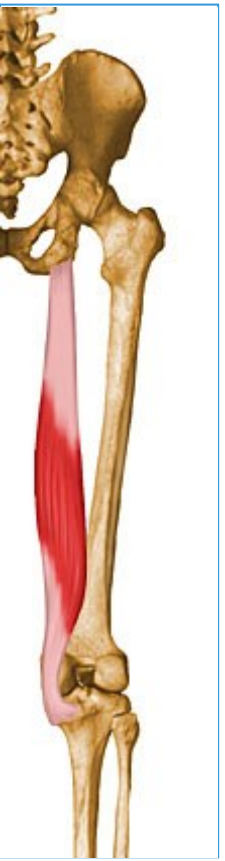- Posterior surface of the medial tibial condyle



- **Action**

- Extends the thigh, flexes the knee, and also rotates the tibia medially, especially when the knee is flexed





■ **Innervation**

- Tibial nerve (L5, S1, S2)




■ **Arterial Supply**

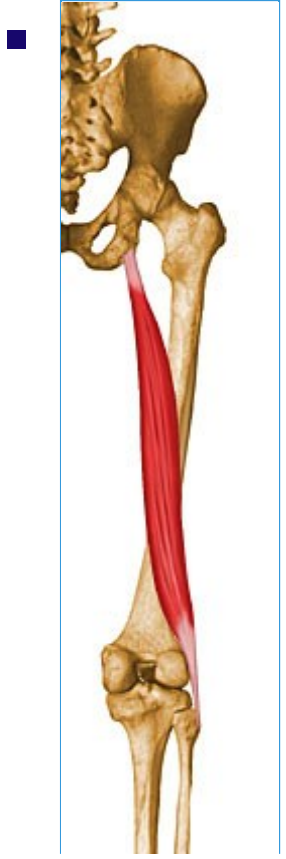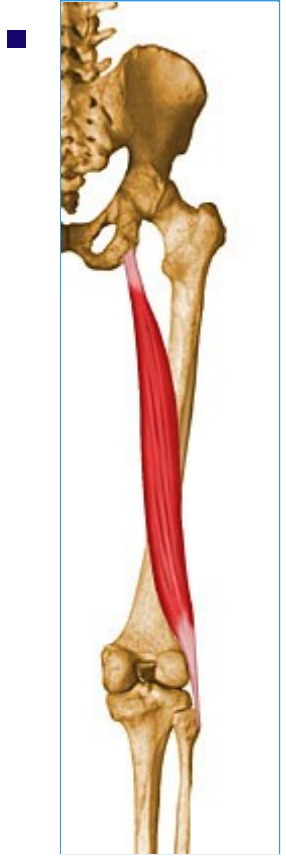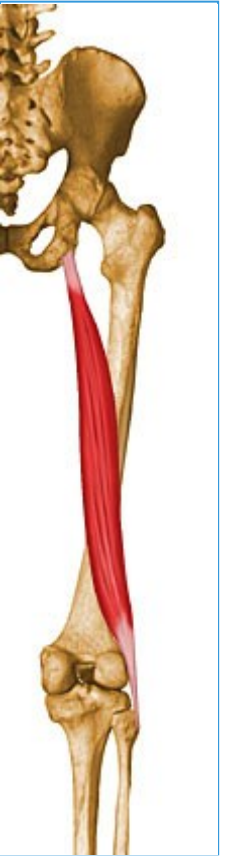- Perforating branches of profunda femoris artery, inferior gluteal artery, and the superior muscular branches of popliteal artery

69- Biceps Femoris Long Head

- Summary

- ■ Biceps femoris long head

<ul style="list-style-type: none">■ Origin	<ul style="list-style-type: none">■ Superior medial quadrant of the posterior portion of the ischial tuberosity	<ul style="list-style-type: none">■ 
<ul style="list-style-type: none">■ Insertion	<ul style="list-style-type: none">■ Primarily on fibular head; also on lateral collateral ligament and lateral tibial condyle	<ul style="list-style-type: none">■ 
<ul style="list-style-type: none">■ Action	<ul style="list-style-type: none">■ Flexes the knee, and also rotates the tibia laterally; long head also extends the hip joint	<ul style="list-style-type: none">■ 



■ **Innervation**

- Tibial nerve (L5, S1, S2)




■ **Arterial supply**

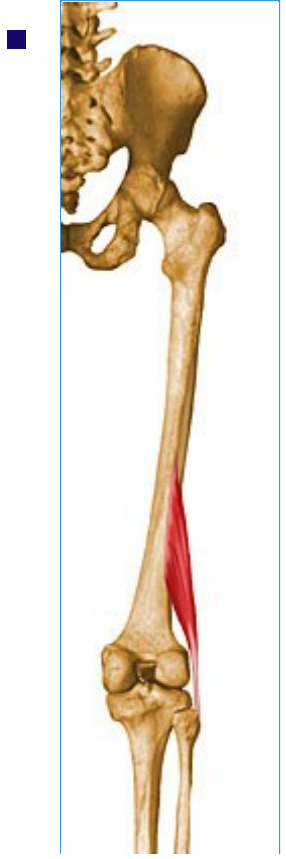
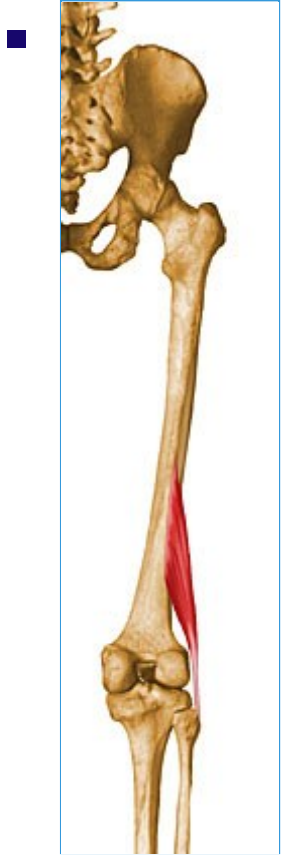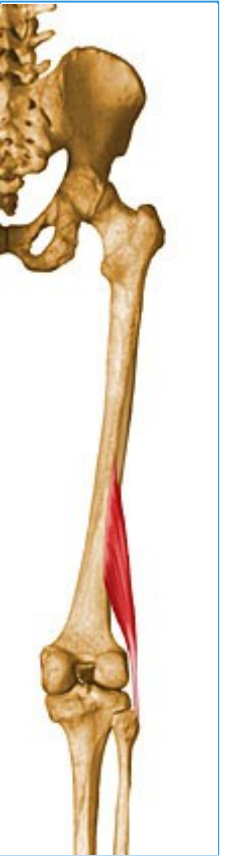- Perforating branches of profunda femoris artery, inferior gluteal artery, and the superior muscular branches of popliteal artery

70- Biceps Femoris Short Head

- Summary

- Biceps femoris short head

<ul style="list-style-type: none"> <ul style="list-style-type: none"> Origin 	<ul style="list-style-type: none"> <ul style="list-style-type: none"> <ul style="list-style-type: none"> Lateral lip of linea aspera, lateral supracondylar ridge of femur, and lateral intermuscular septum of thigh 	<ul style="list-style-type: none"> <ul style="list-style-type: none"> 
<ul style="list-style-type: none"> <ul style="list-style-type: none"> Insertion 	<ul style="list-style-type: none"> <ul style="list-style-type: none"> <ul style="list-style-type: none"> Primarily on fibular head; also on lateral collateral ligament and lateral tibial condyle 	<ul style="list-style-type: none"> <ul style="list-style-type: none"> 
<ul style="list-style-type: none"> <ul style="list-style-type: none"> Action 	<ul style="list-style-type: none"> <ul style="list-style-type: none"> <ul style="list-style-type: none"> Flexes the knee, and also rotates the tibia laterally; long head also extends the hip joint 	<ul style="list-style-type: none"> <ul style="list-style-type: none"> 



■ **Innervation**

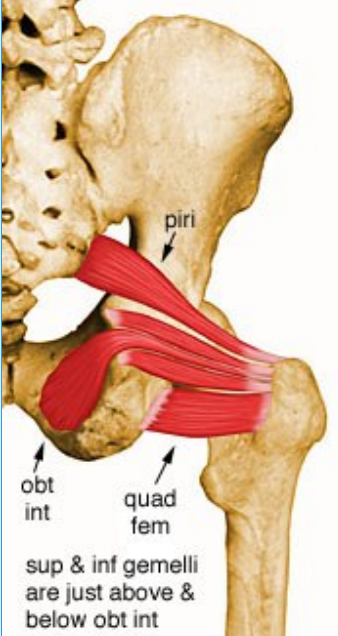
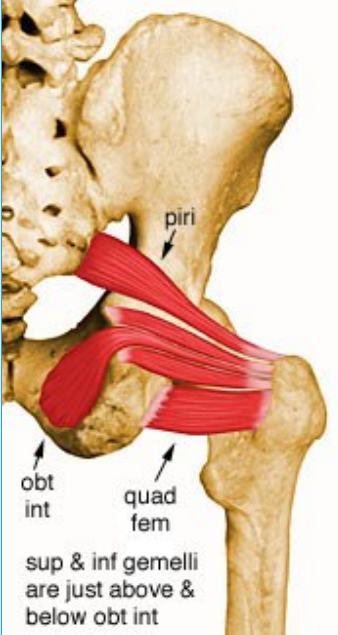
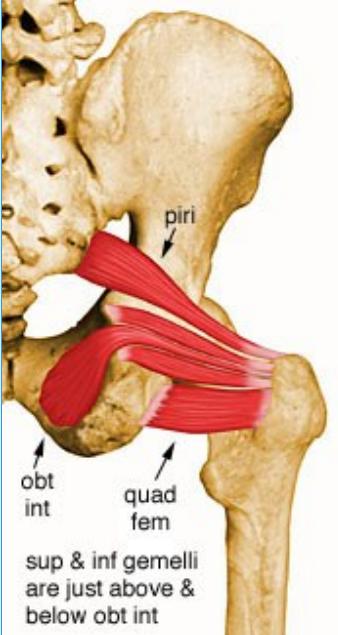
- Common peroneal nerve (L5, S1, S2)

■ **Arterial supply**

- Perforating branches of profunda femoris artery, inferior gluteal artery, and the superior muscular branches of popliteal artery

71- Piriformis

- Summary

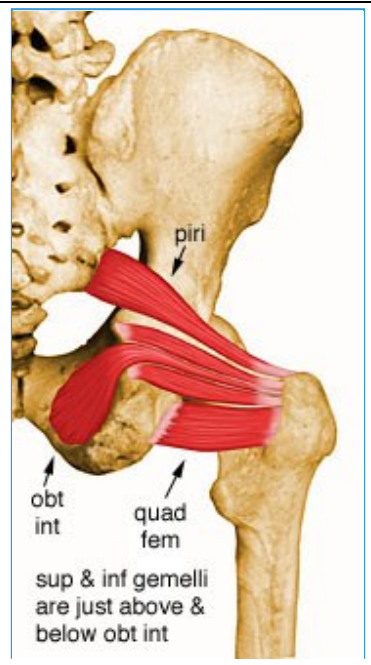
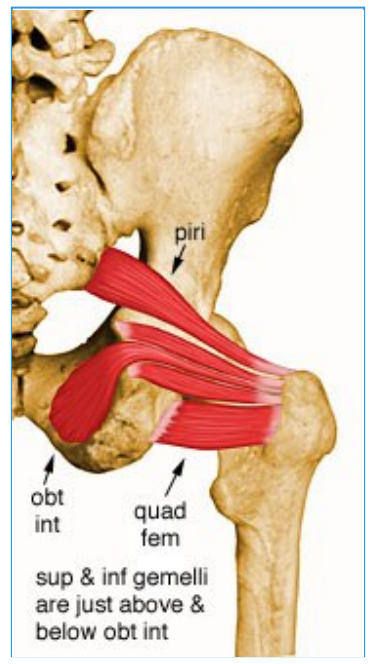
<ul style="list-style-type: none"> <ul style="list-style-type: none"> ■ Piriformis 		
<ul style="list-style-type: none"> <ul style="list-style-type: none"> ■ Origin 	<ul style="list-style-type: none"> <ul style="list-style-type: none"> ■ Anterior surface of sacrum and gluteal surface of ilium at the margin of the greater sciatic notch 	<ul style="list-style-type: none"> 
<ul style="list-style-type: none"> <ul style="list-style-type: none"> ■ Insertion 	<ul style="list-style-type: none"> <ul style="list-style-type: none"> ■ Superior border of greater trochanter 	<ul style="list-style-type: none"> 
<ul style="list-style-type: none"> <ul style="list-style-type: none"> ■ Action ■ 	<ul style="list-style-type: none"> <ul style="list-style-type: none"> ■ External rotator of the hip joint; also helps abduct the hip if it is flexed 	<ul style="list-style-type: none"> 
<ul style="list-style-type: none"> <ul style="list-style-type: none"> ■ Innervation 	<ul style="list-style-type: none"> <ul style="list-style-type: none"> ■ Piriformis nerve (L5, S1, S2) 	<ul style="list-style-type: none"> <ul style="list-style-type: none"> ■

--

<ul style="list-style-type: none">■ Arterial supply
--






--

<ul style="list-style-type: none">■ Superior and inferior gluteal and internal pudendal arteries
--



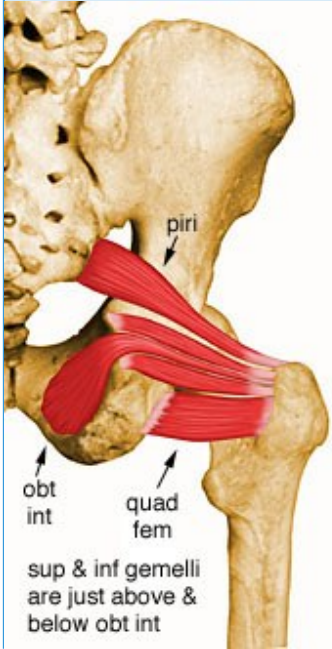
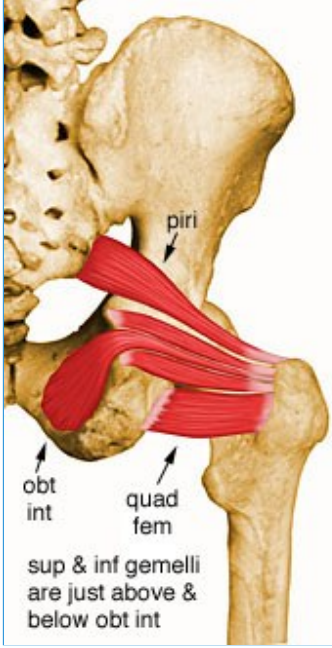
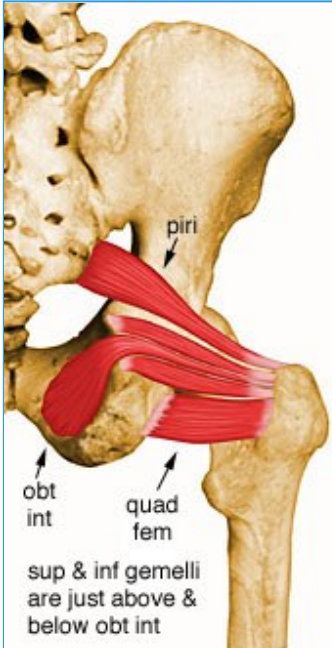
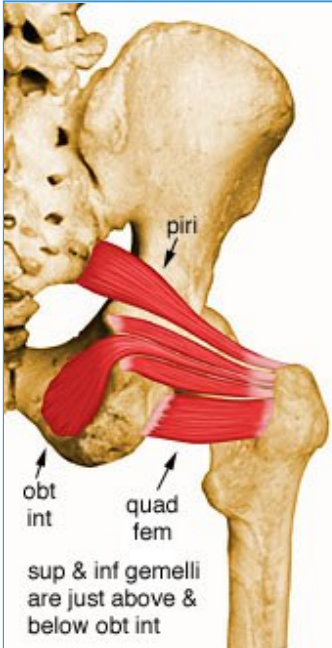
72- Obturator Externus

- Summary

<ul style="list-style-type: none"> <ul style="list-style-type: none"> ■ Obturator externus 		
<ul style="list-style-type: none"> <ul style="list-style-type: none"> ■ Origin 	<ul style="list-style-type: none"> <ul style="list-style-type: none"> ■ Anterior surface of obturator membrane and anterior bony margins of obturator foramen 	<ul style="list-style-type: none"> <ul style="list-style-type: none"> ■ 
<ul style="list-style-type: none"> <ul style="list-style-type: none"> ■ Insertion 	<ul style="list-style-type: none"> <ul style="list-style-type: none"> ■ Trochanteric fossa on the medial surface of the greater trochanter 	<ul style="list-style-type: none"> <ul style="list-style-type: none"> ■ 
<ul style="list-style-type: none"> <ul style="list-style-type: none"> ■ Action 	<ul style="list-style-type: none"> <ul style="list-style-type: none"> ■ Rotates the thigh laterally; also helps adduct thigh 	<ul style="list-style-type: none"> <ul style="list-style-type: none"> ■ 
<ul style="list-style-type: none"> <ul style="list-style-type: none"> ■ Innervation 	<ul style="list-style-type: none"> <ul style="list-style-type: none"> ■ Posterior division of obturator nerve (L3, L4) 	<ul style="list-style-type: none"> <ul style="list-style-type: none"> ■ 
<ul style="list-style-type: none"> <ul style="list-style-type: none"> ■ Arterial supply 	<ul style="list-style-type: none"> <ul style="list-style-type: none"> ■ Obturator and medial circumflex femoral arteries 	<ul style="list-style-type: none"> <ul style="list-style-type: none"> ■ 

73- Obturator Internus

- Summary

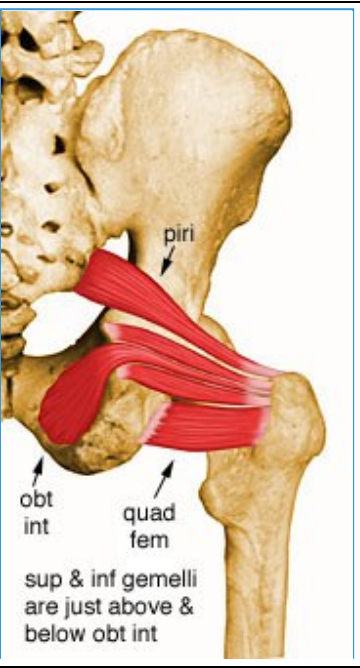
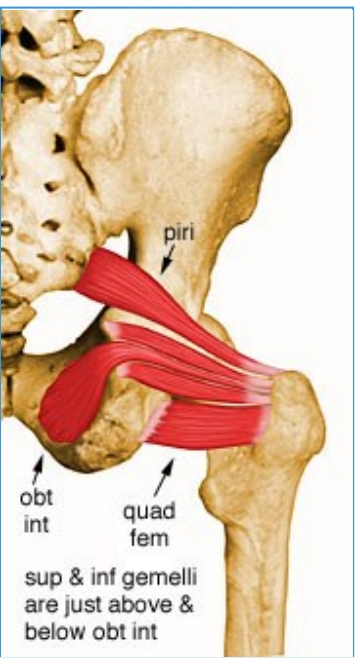
<ul style="list-style-type: none"> ■ Obturator internus 		<ul style="list-style-type: none"> ■ 
<ul style="list-style-type: none"> ■ Origin ■ 	<ul style="list-style-type: none"> ■ Internal surface of obturator membrane and posterior bony margins of obturator foramen 	<ul style="list-style-type: none"> ■ 
<ul style="list-style-type: none"> ■ Insertion ■ 	<ul style="list-style-type: none"> ■ Medial surface of greater trochanter of femur, in common with superior and inferior gemelli 	<ul style="list-style-type: none"> ■ 
<ul style="list-style-type: none"> ■ Action ■ 	<ul style="list-style-type: none"> ■ Rotates the thigh laterally; also helps abduct the thigh when it is flexed 	<ul style="list-style-type: none"> ■ 
<ul style="list-style-type: none"> ■ Innervation ■ 	<ul style="list-style-type: none"> ■ Nerve to the obturator internus (L5, S1) 	<ul style="list-style-type: none"> ■

--

<ul style="list-style-type: none">■ Arterial Supply
--

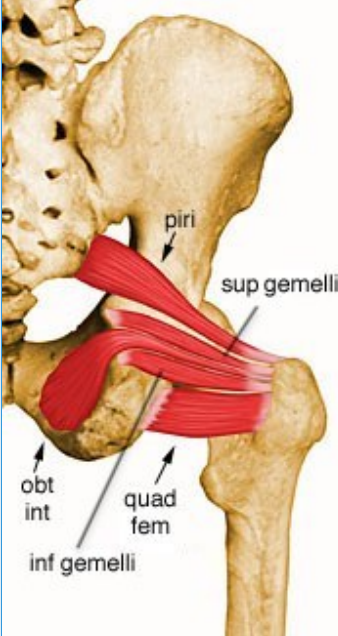
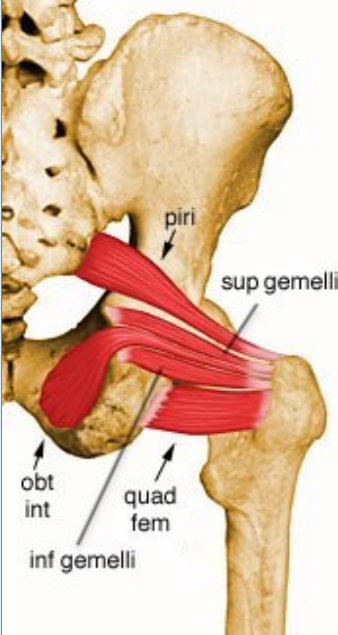
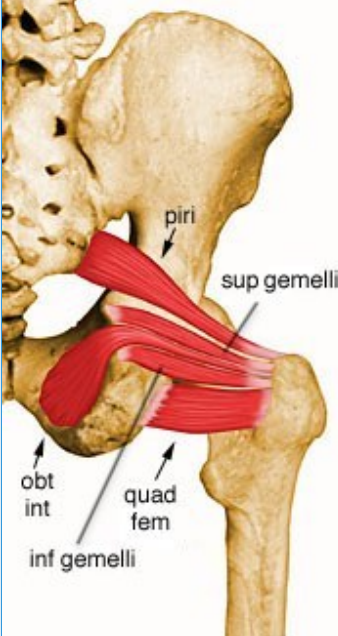
--

<ul style="list-style-type: none">■ Internal pudendal and superior and inferior gluteal arteries
--



74- Superior Gemellus

- Summary

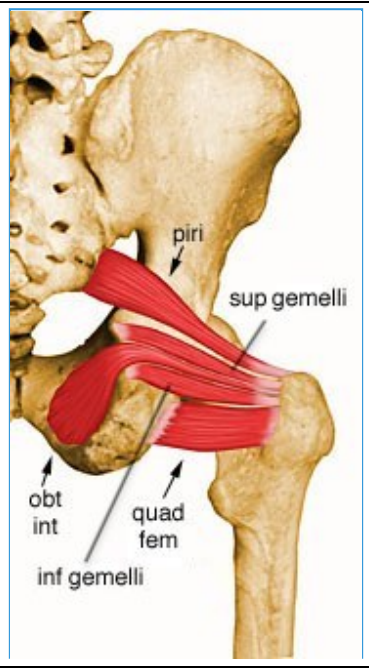
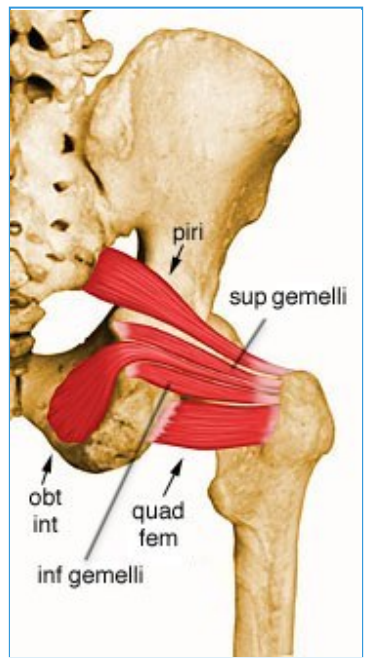
<ul style="list-style-type: none"> Superior gemellus 		
<ul style="list-style-type: none"> Origin 	<ul style="list-style-type: none"> Ischial spine 	
<ul style="list-style-type: none"> Insertion 	<ul style="list-style-type: none"> Medial surface of greater trochanter of femur, in common with obturator internus 	
<ul style="list-style-type: none"> Action 	<ul style="list-style-type: none"> Rotates the thigh laterally; also helps abduct the flexed thigh 	
<ul style="list-style-type: none"> Innervation 	<ul style="list-style-type: none"> Nerve to the obturator internus (L5, S1) 	

--

<ul style="list-style-type: none">■ Arterial supply
--

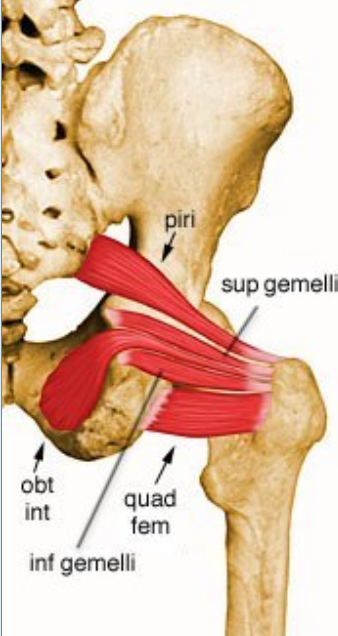
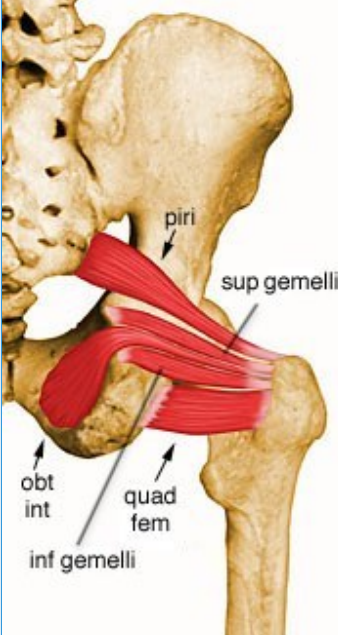
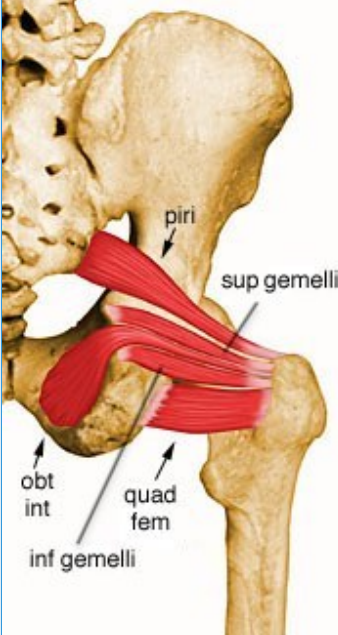
--

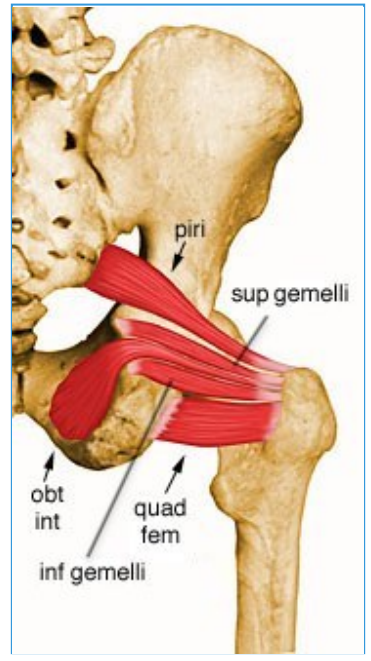
<ul style="list-style-type: none">■ Inferior gluteal artery



75- Inferior Gemellus

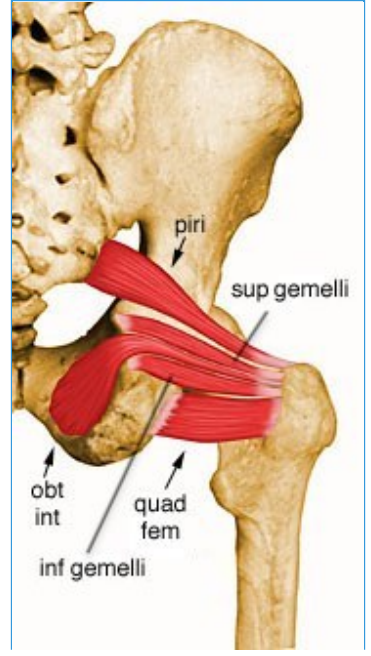
- Summary

<ul style="list-style-type: none"> <ul style="list-style-type: none"> ■ Inferior Gemellus 		
<ul style="list-style-type: none"> <ul style="list-style-type: none"> ■ Origin 	<ul style="list-style-type: none"> <ul style="list-style-type: none"> ■ Posterior portions of ischial tuberosity and lateral obturator ring 	<ul style="list-style-type: none"> 
<ul style="list-style-type: none"> <ul style="list-style-type: none"> ■ Insertion 	<ul style="list-style-type: none"> <ul style="list-style-type: none"> ■ Medial surface of greater trochanter of femur, in common with obturator internus 	<ul style="list-style-type: none"> 
<ul style="list-style-type: none"> <ul style="list-style-type: none"> ■ Action 	<ul style="list-style-type: none"> <ul style="list-style-type: none"> ■ Rotates the thigh laterally; also helps abduct the flexed thigh 	<ul style="list-style-type: none"> 
<ul style="list-style-type: none"> <ul style="list-style-type: none"> ■ Innervation 	<ul style="list-style-type: none"> <ul style="list-style-type: none"> ■ Nerve to the quadratus femoris (L5, S1) 	<ul style="list-style-type: none"> <ul style="list-style-type: none"> ■



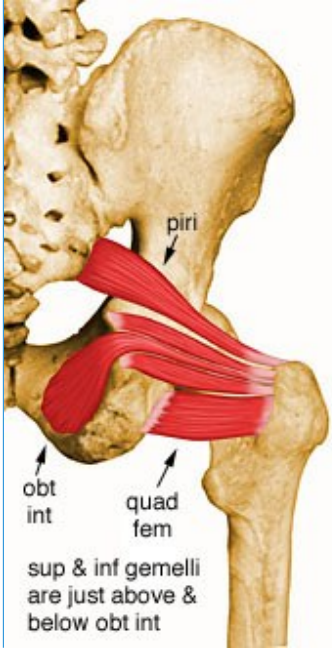
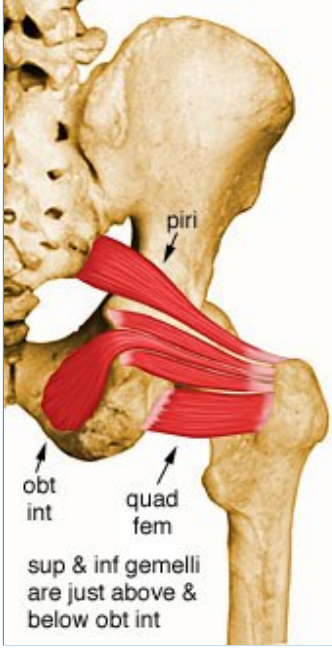
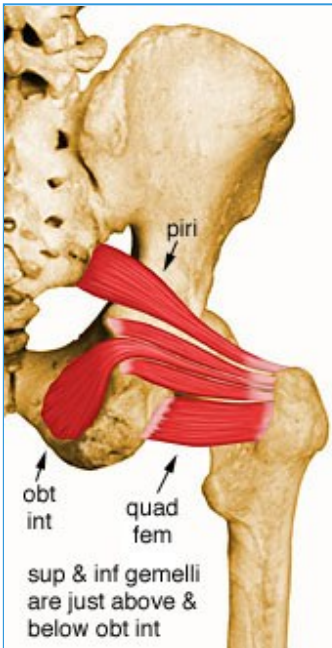
- **Arterial supply**

- Inferior gluteal artery



76- Quadratus Femoris

- Summary

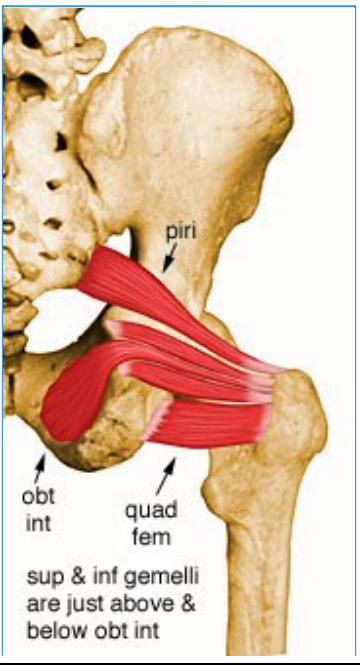
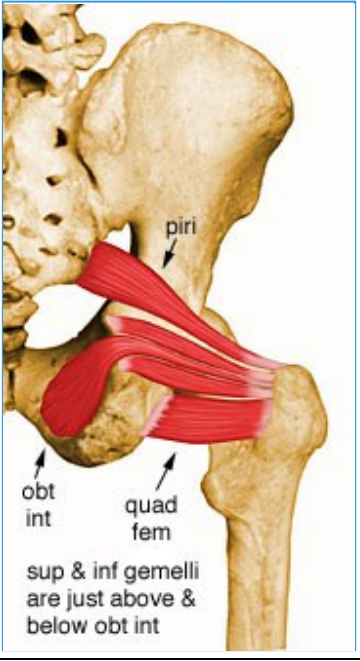
<ul style="list-style-type: none"> ■ Quadratus femoris 	<ul style="list-style-type: none"> ■ Origin ■ Lateral margin of obturator ring above ischial tuberosity ■ 	<ul style="list-style-type: none"> ■ 
<ul style="list-style-type: none"> ■ Insertion ■ 	<ul style="list-style-type: none"> ■ Quadrate tubercle and adjacent bone of intertrochanteric crest of proximal posterior femur ■ 	<ul style="list-style-type: none"> ■ 
<ul style="list-style-type: none"> ■ Action ■ 	<ul style="list-style-type: none"> ■ Rotates the hip laterally; also helps adduct the hip ■ 	<ul style="list-style-type: none"> ■ 
<ul style="list-style-type: none"> ■ Innervation ■ 	<ul style="list-style-type: none"> ■ Nerve to the quadratus femoris (L5, S1) ■ 	<ul style="list-style-type: none"> ■

--

<ul style="list-style-type: none">■ Arterial supply
--

--

<ul style="list-style-type: none">■ Medial circumflex femoral artery, inferior gluteal artery, 1st - 4th perforating arteries, obturator artery, and some superior muscular branches of popliteal artery
--



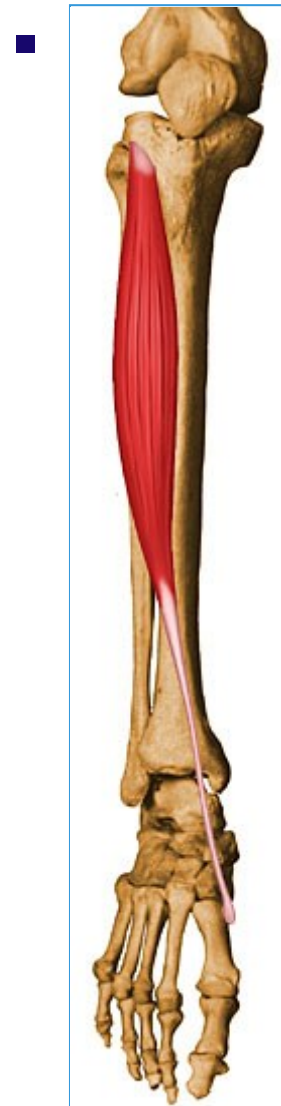77- Tibialis Anterior

- Summary

- ■ Tibialis anterior

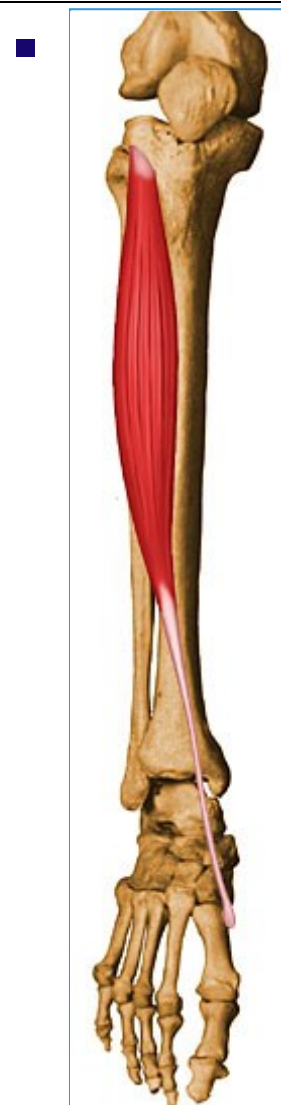- **Origin**




- Lateral condyle of tibia, proximal 1/2 - 2/3 or lateral surface of tibial shaft, interosseous membrane, and the deep surface of the fascia cruris

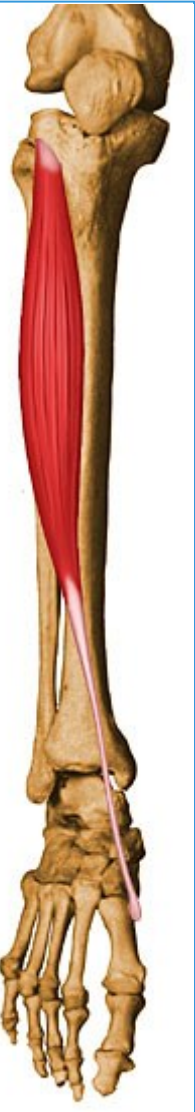

- **Insertion**

- Medial and plantar surfaces of 1st cuneiform and base of first metatarsal



<ul style="list-style-type: none"> ■ Action 	<ul style="list-style-type: none"> ■ 1. Dorsiflexes ankle and inverts the hindfoot ■ 2. Dorsiflexes foot in preparation for heel strike (late swing phase) ■ 3. Eccentrically contracts after heel strike 	<ul style="list-style-type: none"> ■ 
<ul style="list-style-type: none"> ■ Innervation 	<ul style="list-style-type: none"> ■ Deep peroneal nerve (L4, L5) 	<ul style="list-style-type: none"> ■ 
<ul style="list-style-type: none"> ■ Arterial Supply 	<ul style="list-style-type: none"> ■ Anterior tibial artery 	<ul style="list-style-type: none"> ■ 



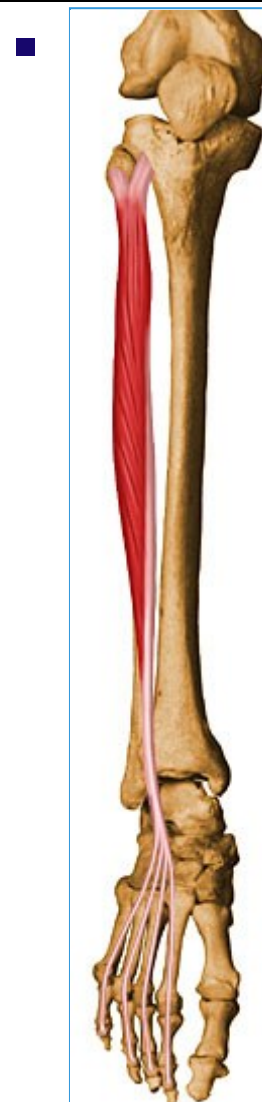78- Extensor Digitorum Longus

- Summary

- ■ Extensor digitorum longus

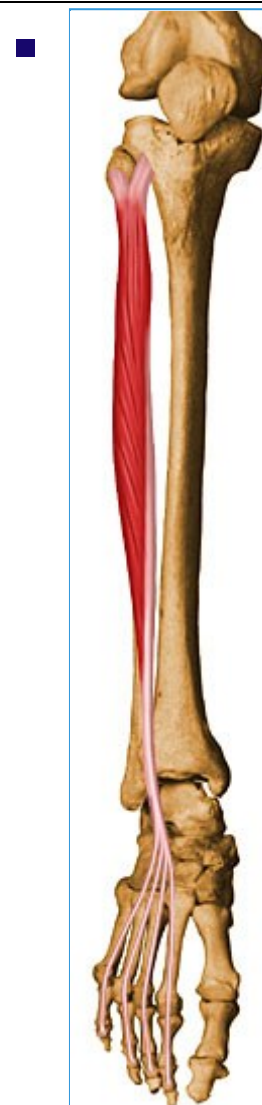- **Origin**




- Lateral tibial condyle, proximal 3/4 of anterior fibula, upper part of interosseous membrane, fascia cruris, and anterior intermuscular septum

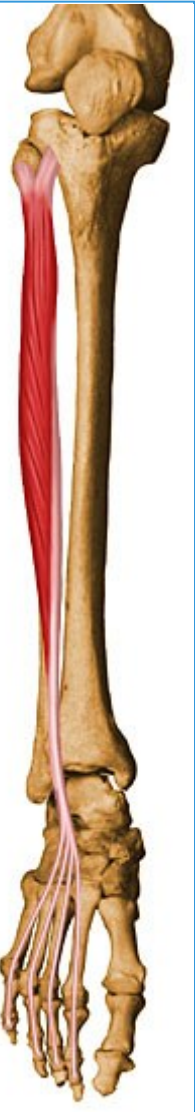

- **Insertion**

- Splits into 4 tendon slips after inferior extensor retinaculum, each of which insert on dorsum of middle and distal phalanges as part of extensor expansion complex



<ul style="list-style-type: none">■ Action	<ul style="list-style-type: none">■ Extend toes 2 - 5 and dorsiflexes ankle	<ul style="list-style-type: none">■ 
<ul style="list-style-type: none">■ Innervation	<ul style="list-style-type: none">■ Deep peroneal nerve (L4, L5, S1)	<ul style="list-style-type: none">■ 
<ul style="list-style-type: none">■ Arterial supply	<ul style="list-style-type: none">■ Anterior tibial artery	<ul style="list-style-type: none">■ 



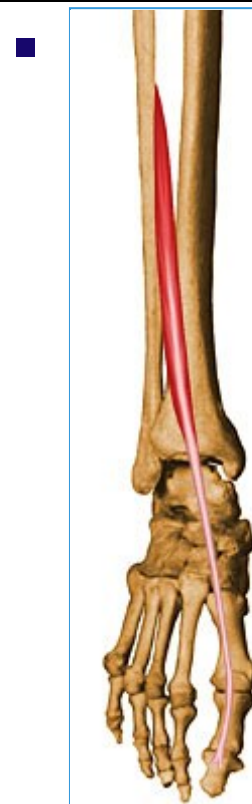79- Extensor Hallucis Longus L5

- Summary

- ■ Extensor hallucis longus

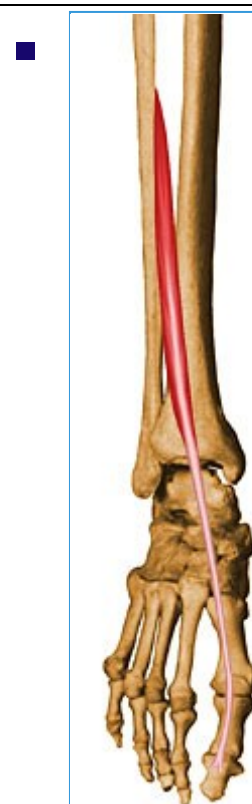- **Origin**

- Anterior surface of the fibula and the adjacent interosseous membrane



- **Insertion**

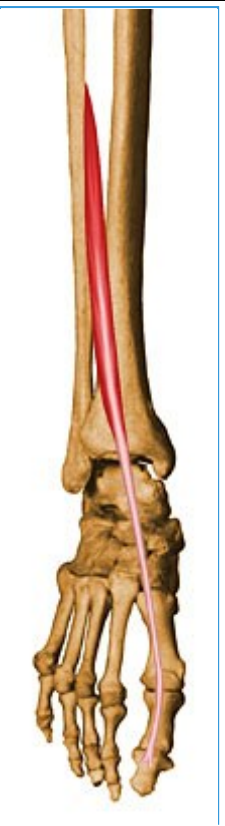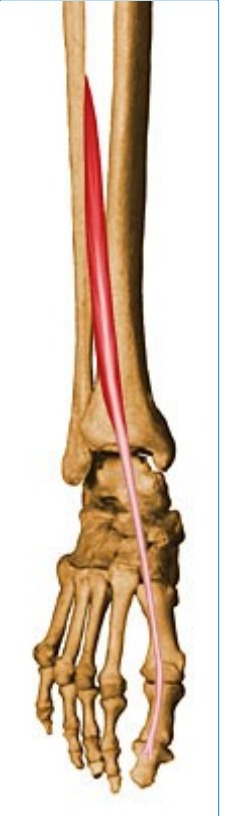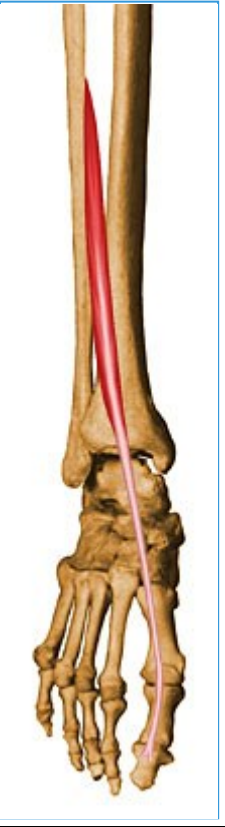- Base and dorsal center of distal phalanx of great toe



- **Action**

- Extends great toe and dorsiflexes ankle





- **Innervation**

- Deep peroneal nerve (L4, L5, S1)




- **Arterial supply**

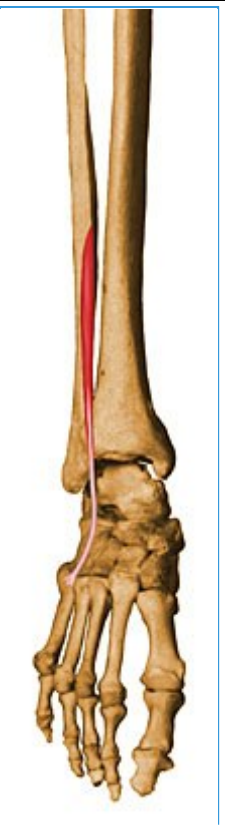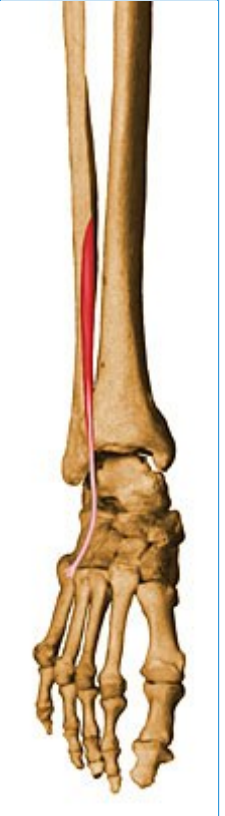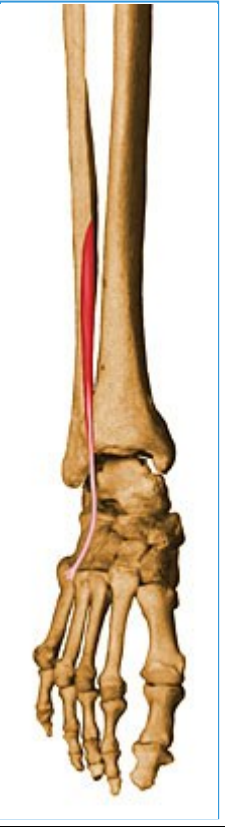- Anterior tibial artery

80- Peroneus Tertius

- Summary

- ■ Peroneus tertius

<ul style="list-style-type: none">■ Origin	<ul style="list-style-type: none">■ Arises with the extensor digitorum longus from the medial fibular shaft surface and the anterior intermuscular septum (between the extensor digitorum longus and the tibialis anterior)	<ul style="list-style-type: none">■ 
<ul style="list-style-type: none">■ Insertion	<ul style="list-style-type: none">■ Dorsal surface of the base of the fifth metatarsal	<ul style="list-style-type: none">■ 
<ul style="list-style-type: none">■ Action	<ul style="list-style-type: none">■ Works with the extensor digitorum longus to dorsiflex, evert and abduct the foot	<ul style="list-style-type: none">■ 



- **Innervation**

- Deep peroneal nerve (L5, S1)


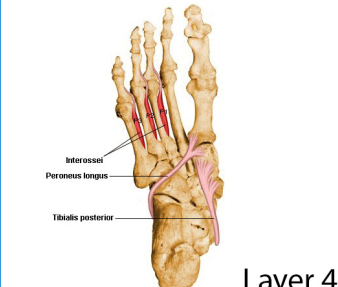

- **Arterial supply**



- Anterior tibial artery

81- Peroneus Longus

- Summary




- Peroneus longus



<ul style="list-style-type: none"> Origin 	<ul style="list-style-type: none"> Head of the fibula, upper 1/2 - 2/3 of lateral fibular shaft surface; also anterior and posterior intermuscular septa of leg 	<ul style="list-style-type: none"> 
<ul style="list-style-type: none"> Insertion 	<ul style="list-style-type: none"> Plantar aspect of medial cuneiform and lateral side of 1st metatarsal base 	<ul style="list-style-type: none"> 
<ul style="list-style-type: none"> Action 	<ul style="list-style-type: none"> Everts foot and plantar flexes ankle; also helps to support the transverse arch of the foot 	<ul style="list-style-type: none"> 
<ul style="list-style-type: none"> Innervation 	<ul style="list-style-type: none"> Superficial peroneal nerve (L5, S1, S2) 	<ul style="list-style-type: none">

		
<ul style="list-style-type: none">■ Arterial Supply	<ul style="list-style-type: none">■ Anterior tibial and peroneal arteries	<ul style="list-style-type: none">■ 

82- Peroneus Brevis

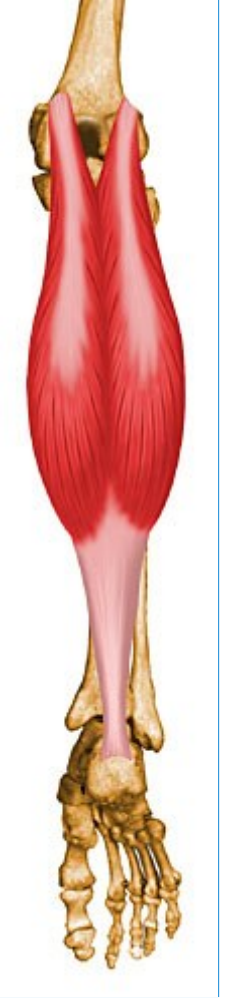
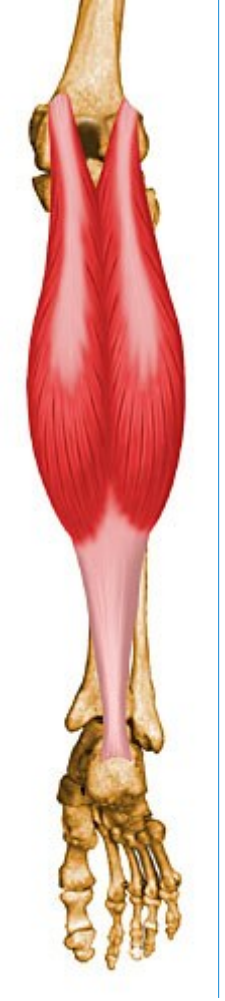
- Summary

<ul style="list-style-type: none"> <ul style="list-style-type: none"> Peroneus brevis 		
<ul style="list-style-type: none"> <ul style="list-style-type: none"> Origin 	<ul style="list-style-type: none"> <ul style="list-style-type: none"> Inferior 2/3 of lateral fibular surface; also anterior and posterior intermuscular septa of leg 	<ul style="list-style-type: none"> 
<ul style="list-style-type: none"> <ul style="list-style-type: none"> Insertion 	<ul style="list-style-type: none"> <ul style="list-style-type: none"> Lateral surface of styloid process of 5th metatarsal base 	<ul style="list-style-type: none"> 
<ul style="list-style-type: none"> <ul style="list-style-type: none"> Action 	<ul style="list-style-type: none"> <ul style="list-style-type: none"> Everts foot and plantar flexes ankle 	<ul style="list-style-type: none"> 

<ul style="list-style-type: none">■ Innervation■	<ul style="list-style-type: none">■ Superficial peroneal nerve (L5, S1, S2)	<ul style="list-style-type: none">■ 
<ul style="list-style-type: none">■ Arterial supply■	<ul style="list-style-type: none">■ Muscular branches of peroneal artery	<ul style="list-style-type: none">■ 

83- Gastrocnemius

- Summary

<ul style="list-style-type: none">○ ■ Gastrocnemius		
<ul style="list-style-type: none">■ Origin	<ul style="list-style-type: none">■ Medial head: from posterior nonarticular surface of medial femoral condyle;■ Lateral head: from lateral surface of femoral lateral condyle	<ul style="list-style-type: none">■ 
<ul style="list-style-type: none">■ Insertion	<ul style="list-style-type: none">■ The two heads unite into a broad aponeurosis which eventually unites with the deep tendon of the soleus to form the Achilles tendon, inserting on the middle 1/3 of the posterior calcaneal surface	<ul style="list-style-type: none">■ 
<ul style="list-style-type: none">■ Action	<ul style="list-style-type: none">■ Powerful plantar flexor of ankle	<ul style="list-style-type: none">■



■ **Innervation**

- Tibial nerve (S1, S2)



■ **Arterial supply**

- Each head supplied by a sural branch of the popliteal artery

84- Soleus


- Summary

- ■ Soleus

<ul style="list-style-type: none">■ Origin	<ul style="list-style-type: none">■ Posterior aspect of fibular head, upper 1/4 of posterior surface of fibula, middle 1/3 of medial border of tibial shaft, and from posterior surface of a tendinous arch spanning the two sites of bone origin	<ul style="list-style-type: none">■ 
<ul style="list-style-type: none">■ Insertion	<ul style="list-style-type: none">■ Eventually unites with the gastrocnemius aponeurosis to form the Achilles tendon, inserting on the middle 1/3 of the posterior calcaneal surface	<ul style="list-style-type: none">■ 
<ul style="list-style-type: none">■ Action	<ul style="list-style-type: none">■ Powerful plantar flexor of ankle	<ul style="list-style-type: none">■



■



■



■ **Innervation**

- Tibial nerve (S1, S2)



■ **Arterial supply**

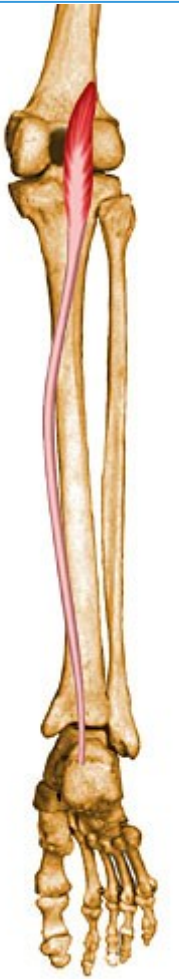
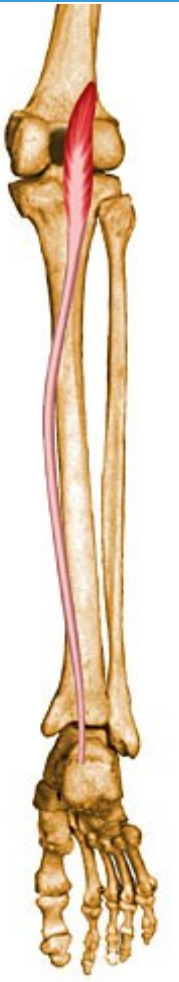
■

- Posterior tibial, peroneal, and sural arteries

85- Plantaris

- Summary

<ul style="list-style-type: none"> Plantaris 		
<ul style="list-style-type: none"> Origin 	<ul style="list-style-type: none"> Inferior aspect of lateral supracondylar line of distal femur 	
<ul style="list-style-type: none"> Insertion 	<ul style="list-style-type: none"> Middle 1/3 of the posterior calcaneal surface, just medial to Achilles tendon 	<ul style="list-style-type: none"> 
<ul style="list-style-type: none"> Action 	<ul style="list-style-type: none"> Plantar flexor of ankle; also flexes knee 	<ul style="list-style-type: none"> 
<ul style="list-style-type: none"> Innervation 	<ul style="list-style-type: none"> Tibial nerve (L5, S1, S2) 	<ul style="list-style-type: none">








- **Arterial Supply**

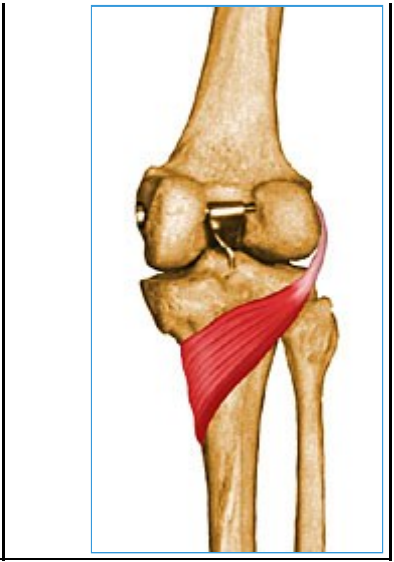
- Sural arteries

86- Popliteus

- Summary

<ul style="list-style-type: none"> Popliteus 		
<ul style="list-style-type: none"> Origin 	<ul style="list-style-type: none"> Anterior part of the popliteal groove on lateral surface of lateral femoral condyle 	
<ul style="list-style-type: none"> Insertion 	<ul style="list-style-type: none"> Posterior surface of tibia in a fan-like fashion, just superior to the popliteal line 	
<ul style="list-style-type: none"> Action 	<ul style="list-style-type: none"> Internally rotates tibia relative to femur and unlocks knee during knee flexion initiation 	
<ul style="list-style-type: none"> Innervation 	<ul style="list-style-type: none"> Tibial nerve (L4, L5, S1) 	
<ul style="list-style-type: none"> Arterial Supply 	<ul style="list-style-type: none"> Medial inferior genicular branch of popliteal artery and muscular branch of posterior tibial artery 	

■



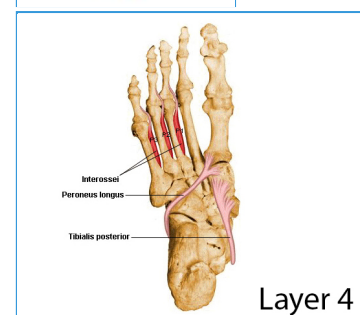
87- Tibialis Posterior

• Summary

○ ■ Tibialis posterior

■ Origin

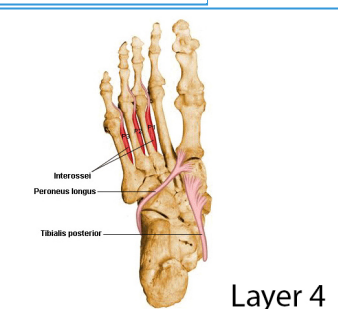
- Posterior aspect of interosseous membrane, superior 2/3 of medial posterior surface of fibula, superior aspect of posterior surface of tibia, and from intermuscular septum between muscles of posterior compartment and deep transverse septum



Layer 4

■ Insertion

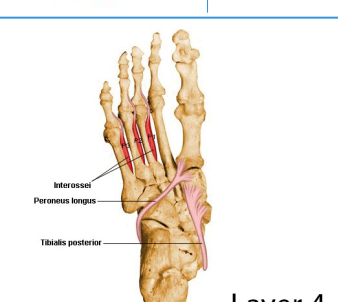
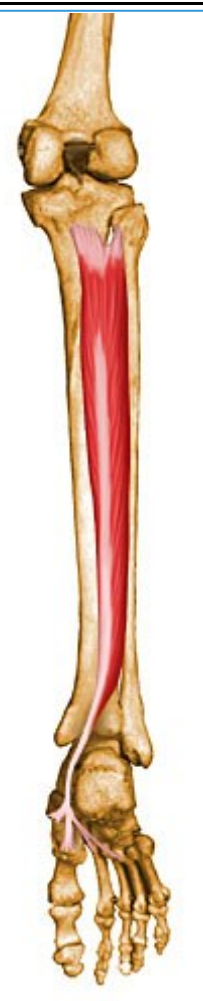- Splits into two slips after passing inferior to plantar calcaneonavicular ligament;
- Superficial slip: inserts on the tuberosity of the navicular bone and sometimes medial cuneiform;
- Deeper slip: divides again into slips inserting on plantar surfaces of metatarsals 2 - 4 and second cuneiform



Layer 4

■ **Action**

- Principal invertor of foot; also adducts foot, plantar flexes ankle, and helps to supinate the foot

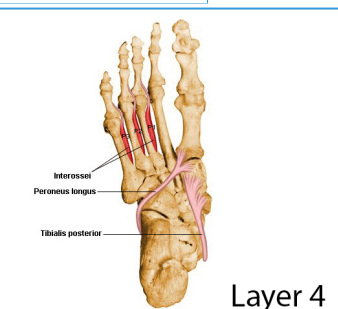


Layer 4

■ **Innervation**

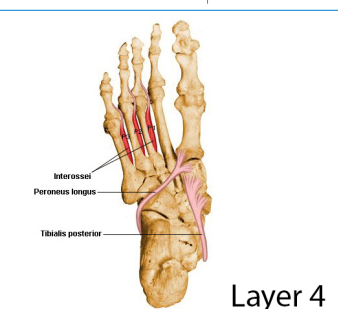
- Tibial nerve (L4, L5)

■



- **Arterial supply**


- Muscular branches of sural, peroneal and posterior tibial arteries



88- Flexor Digitorum Longus

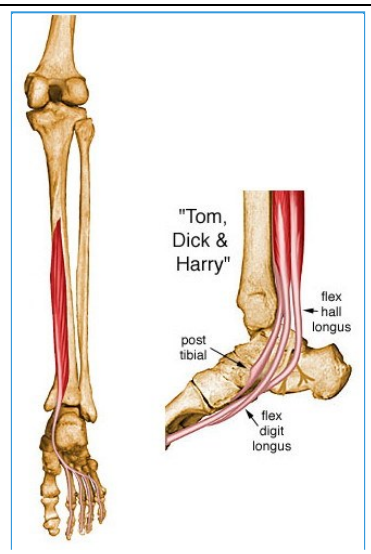
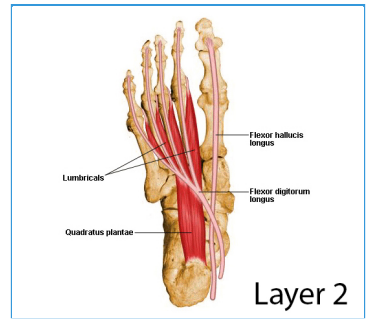
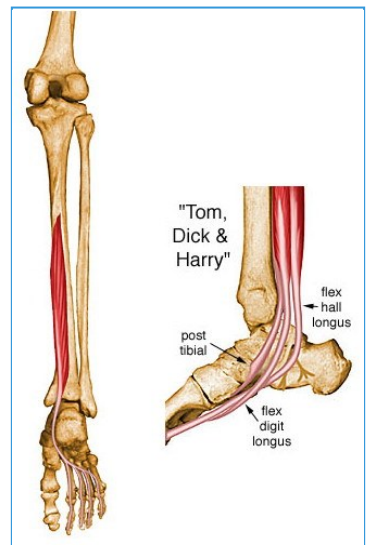
- Summary

<ul style="list-style-type: none"> Flexor digitorum longus 		
<ul style="list-style-type: none"> Origin 	<ul style="list-style-type: none"> Posterior surface of tibia distal to popliteal line 	<ul style="list-style-type: none">
<ul style="list-style-type: none"> Insertion 	<ul style="list-style-type: none"> Splits into four slips after passing through medial intermuscular septum of plantar surface of foot; these slips then insert on plantar surface of bases of 2nd - 5th distal phalanges 	<ul style="list-style-type: none">
<ul style="list-style-type: none"> Action 	<ul style="list-style-type: none"> Flexes toes 2 - 5; also helps in plantar flexion of ankle 	<ul style="list-style-type: none">
<ul style="list-style-type: none"> Innervation 	<ul style="list-style-type: none"> Tibial nerve (S2, S3) 	<ul style="list-style-type: none">



- **Arterial supply**
-

- Muscular branch of posterior tibial artery



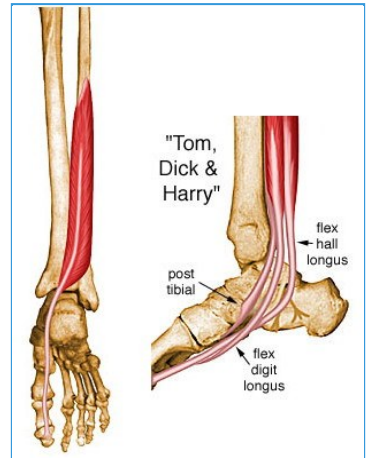
89- Flexor Hallucis Longus

- Summary

- Flexor Hallucis Longus

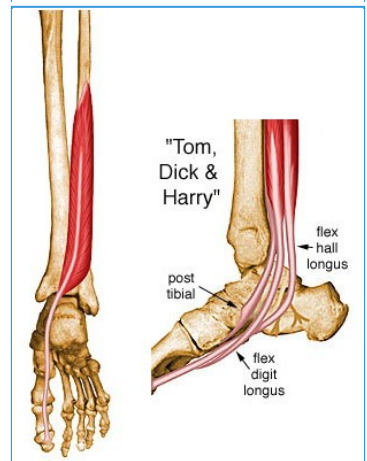
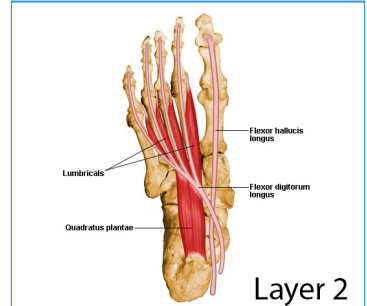
- Origin**

- Inferior 2/3 of posterior surface of fibula, lower part of interosseous membrane



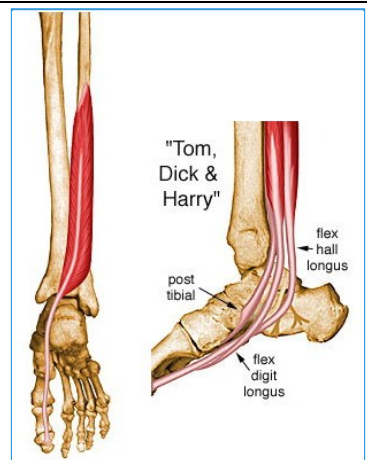
- Insertion**

- Plantar surface of base of distal phalanx of great toe



- Action**


- Flexes great toe, helps to supinate ankle, and is a very weak plantar flexor of ankle



- Innervation**

- Tibial nerve (S2, S3)

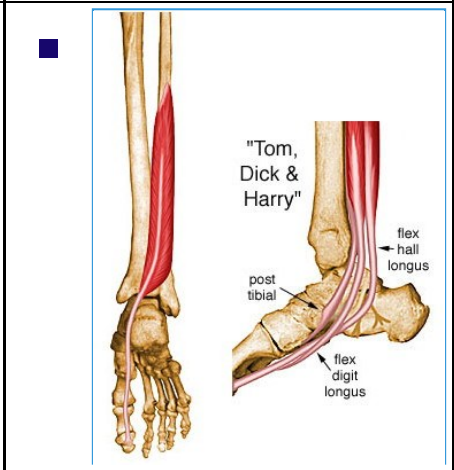
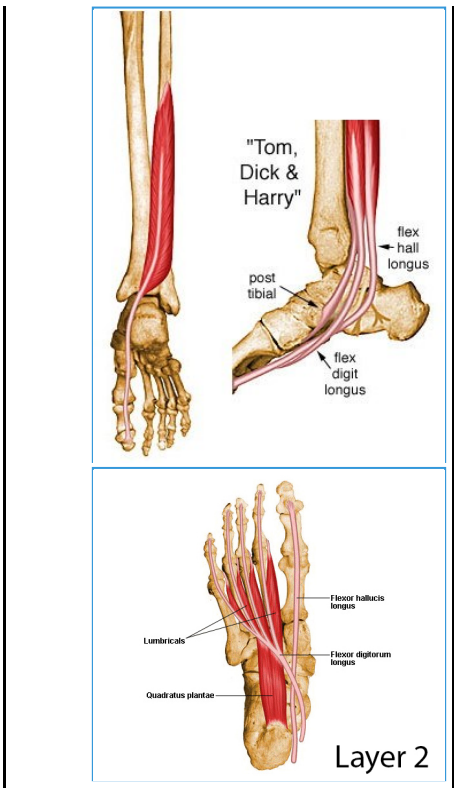




- **Arterial Supply**
-

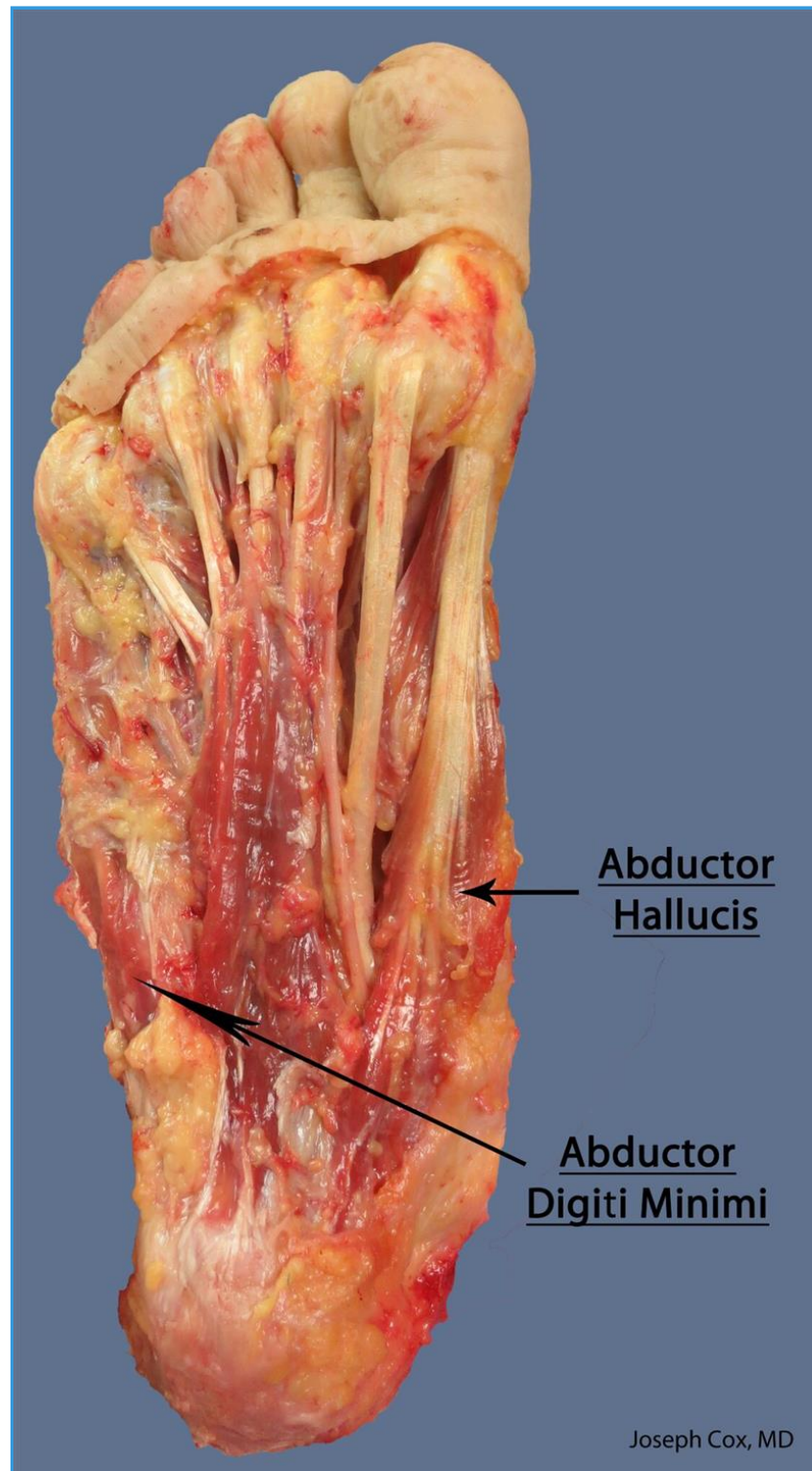
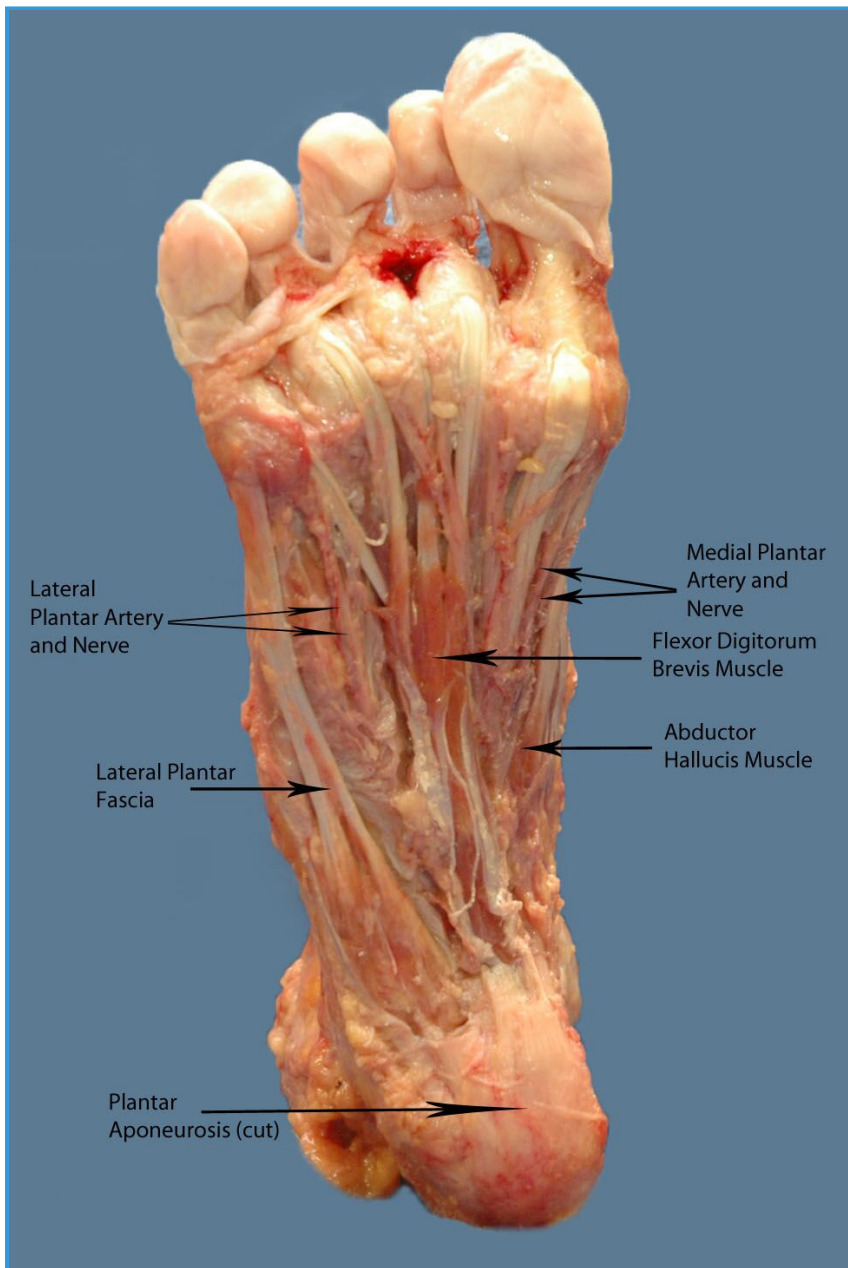


- Muscular branch of peroneal and posterior tibial artery

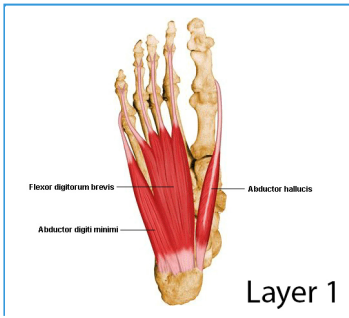
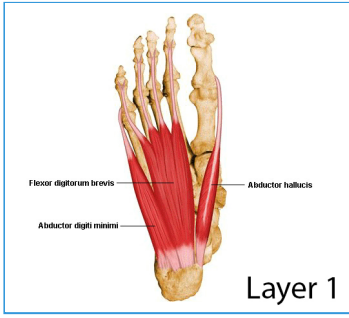


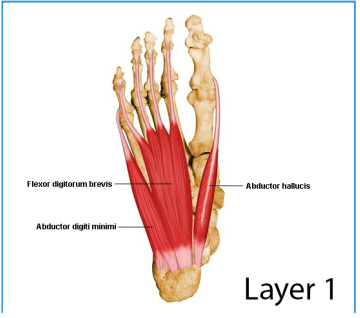
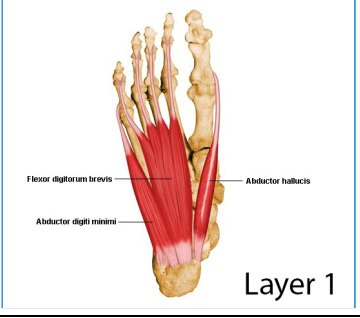
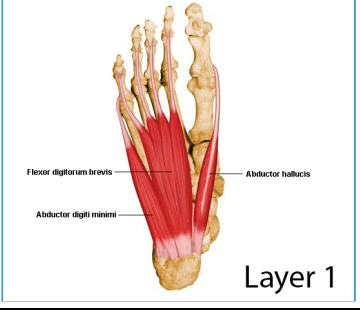
90- Abductor Hallucis

Images



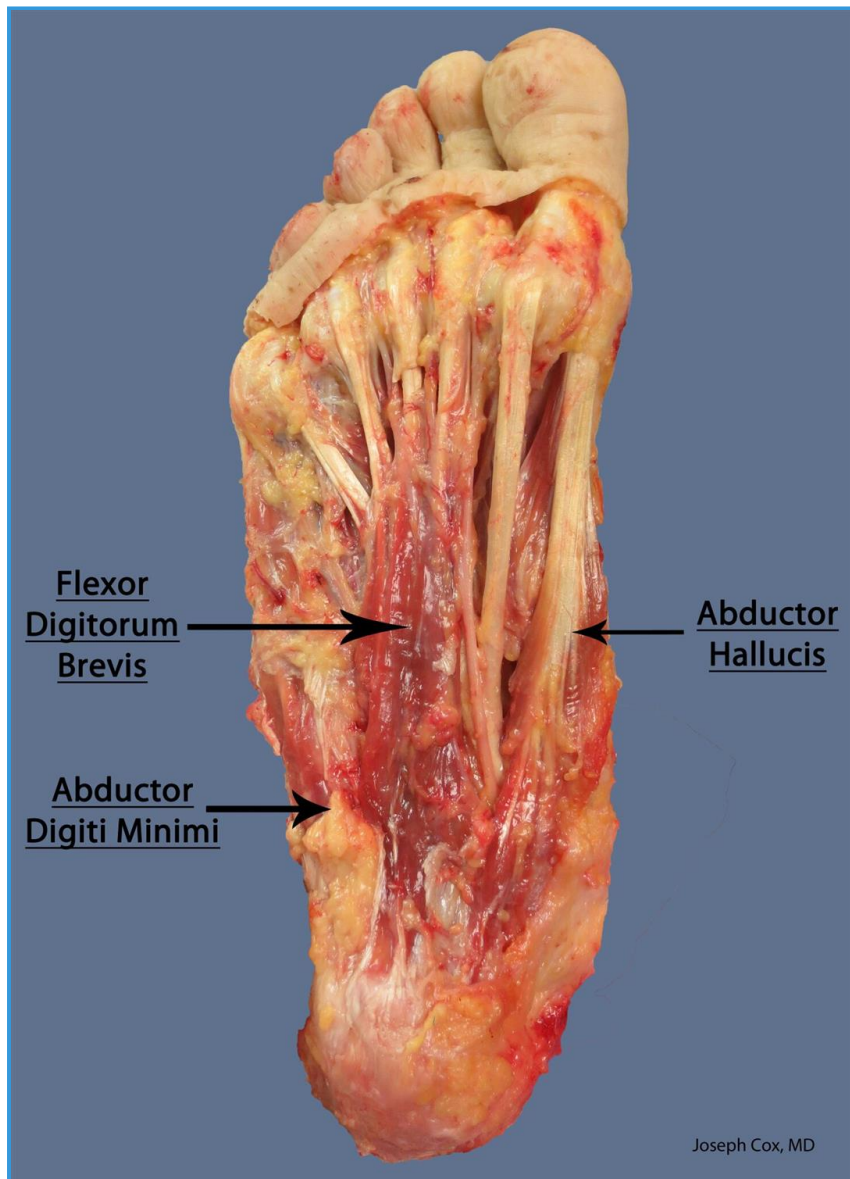
Summary

<ul style="list-style-type: none"> Abductor hallucis 		
<ul style="list-style-type: none"> Origin 	<ul style="list-style-type: none"> Calcaneal tuberosity 	<ul style="list-style-type: none"> 
<ul style="list-style-type: none"> Insertion 	<ul style="list-style-type: none"> Base of great toe, proximal phalanx 	<ul style="list-style-type: none"> 
<ul style="list-style-type: none"> Action 	<ul style="list-style-type: none"> Abduct great toe 	<ul style="list-style-type: none">

		
<ul style="list-style-type: none"> ■ Innervation 	<ul style="list-style-type: none"> ■ Medial plantar nerve 	<ul style="list-style-type: none"> ■ 
<ul style="list-style-type: none"> ■ Arterial supply 	<ul style="list-style-type: none"> ■ Medial plantar artery 	<ul style="list-style-type: none"> ■ 

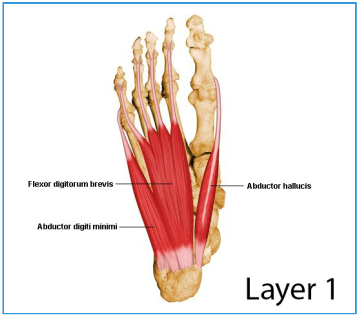
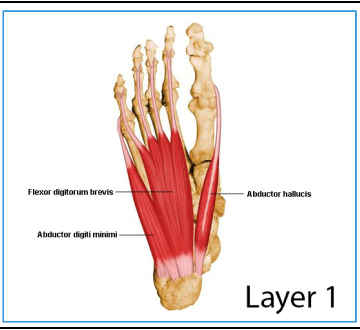
91- Flexor Digitorum Brevis

Images



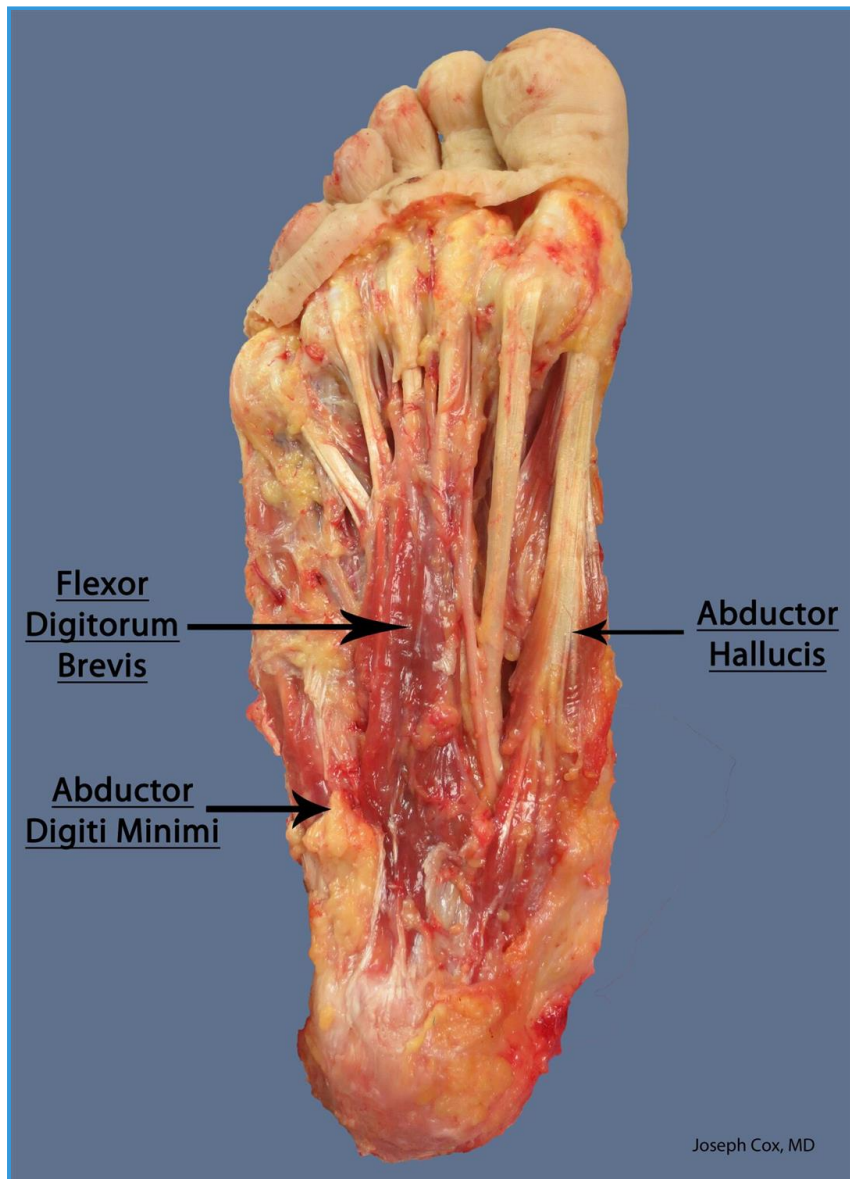
Summary

<ul style="list-style-type: none"> Flexor digitorum brevis 		
<ul style="list-style-type: none"> Origin 	<ul style="list-style-type: none"> Calcaneal tuberosity 	
<ul style="list-style-type: none"> Insertion 	<ul style="list-style-type: none"> Middle phalanx of second to fifth toes 	
<ul style="list-style-type: none"> Action 	<ul style="list-style-type: none"> Flexes toes 	
<ul style="list-style-type: none"> Innervation 	<ul style="list-style-type: none"> Medial plantar nerve 	

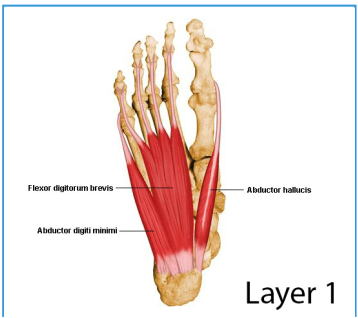
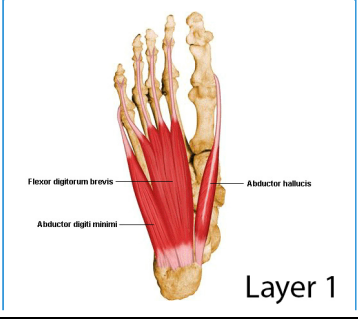
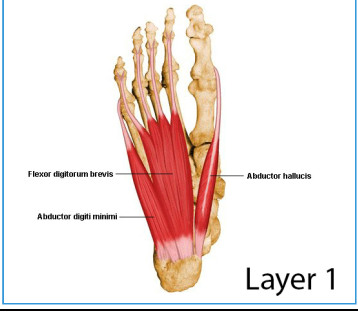
		
<ul style="list-style-type: none"> ■ Arterial supply 	<ul style="list-style-type: none"> ■ Medial plantar artery 	<ul style="list-style-type: none"> ■ 

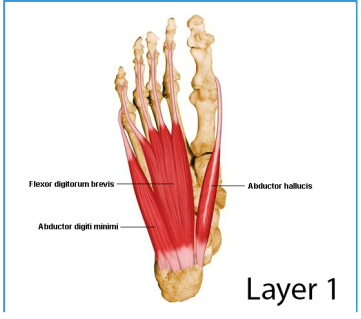
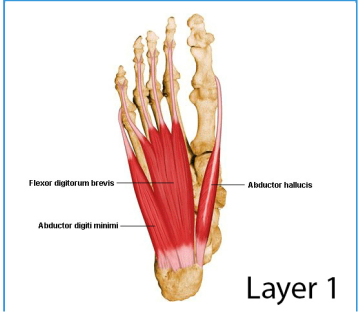
92- Abductor Digiti Minimi

Images



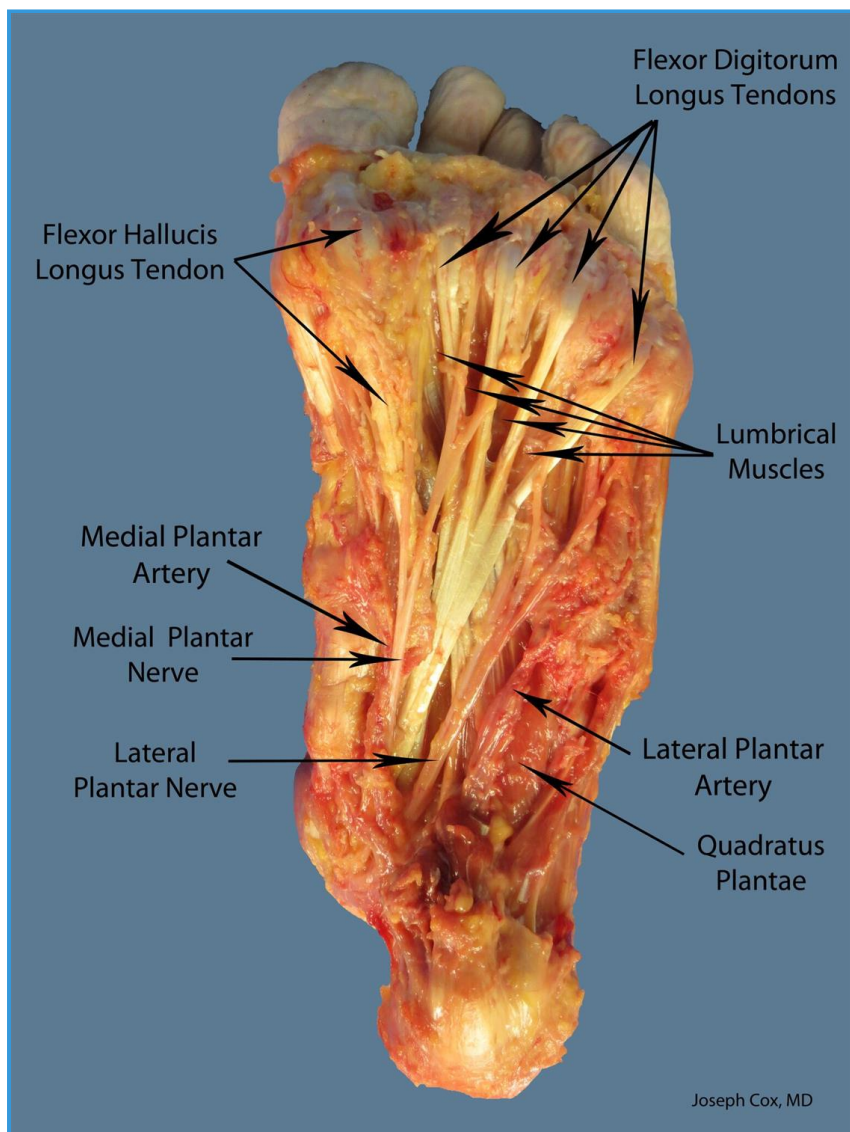
Summary

<ul style="list-style-type: none"> Abductor digiti minimi 		
<ul style="list-style-type: none"> Origin 	<ul style="list-style-type: none"> Calcaneal tuberosity 	<ul style="list-style-type: none"> 
<ul style="list-style-type: none"> Insertion 	<ul style="list-style-type: none"> Base of fifth toes 	<ul style="list-style-type: none"> 
<ul style="list-style-type: none"> Action 	<ul style="list-style-type: none"> Abduct small toe 	<ul style="list-style-type: none"> 
<ul style="list-style-type: none"> Innervation 	<ul style="list-style-type: none"> Lateral plantar nerve 	<ul style="list-style-type: none">

		 <p>Layer 1</p>
<ul style="list-style-type: none">■ Arterial supply	<ul style="list-style-type: none">■ Lateral plantar artery	<ul style="list-style-type: none">■ 

93- Quadratus Plantae

Images

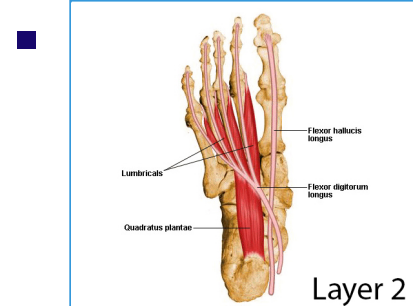


Summary

Quadratus plantae

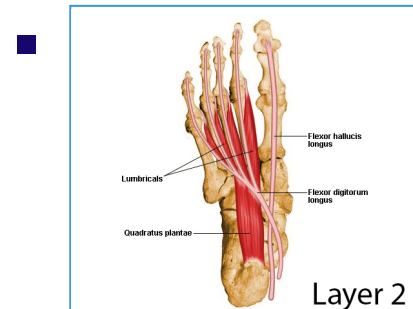
Origin

Medial and lateral calcaneus



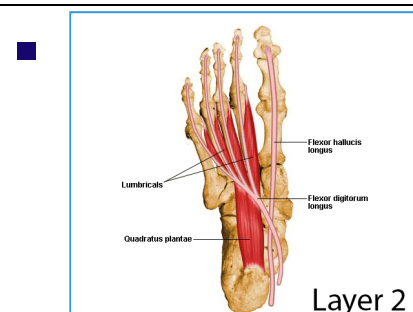
Insertion

FDL tendon



Action

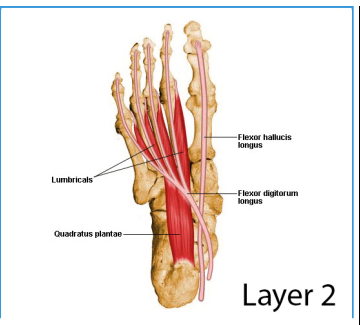
Helps flex distal phalanges



Innervation

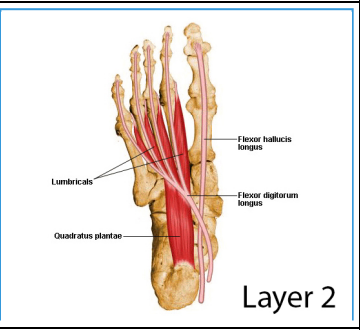
Lateral plantar nerve





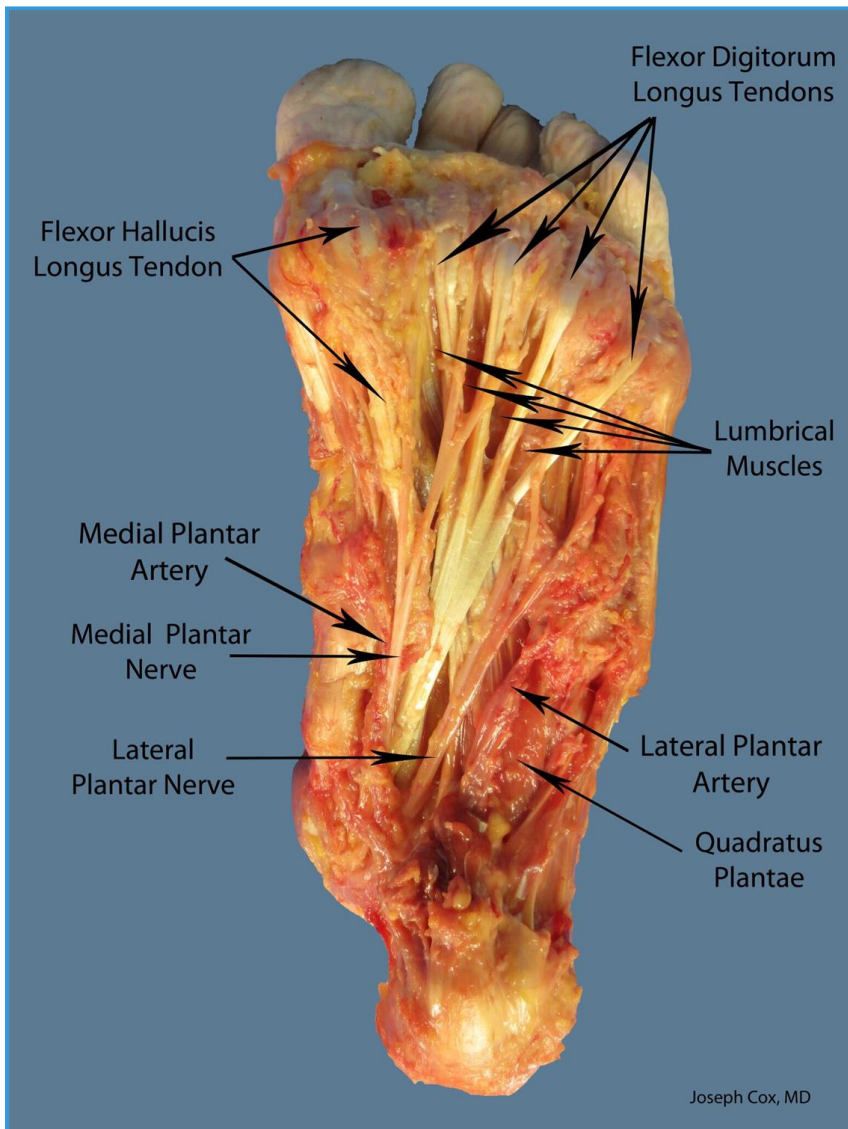
■ **Arterial supply**

■ Lateral plantar artery

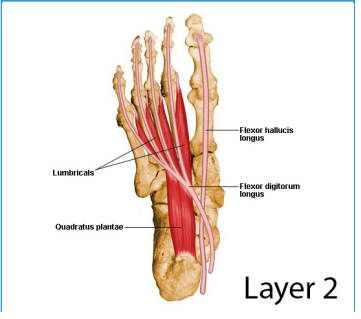
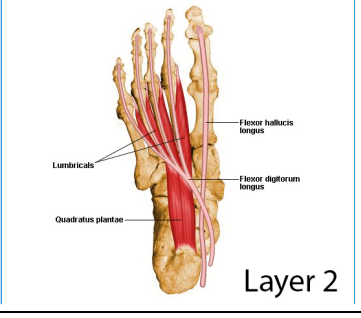
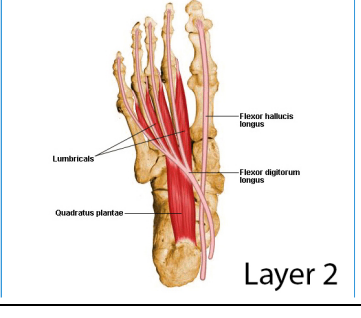



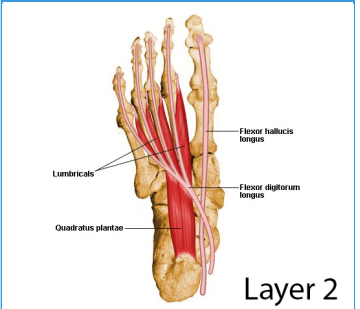
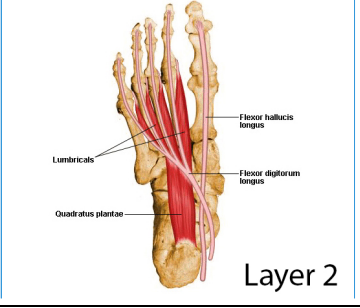
94- Lumbricals

Images



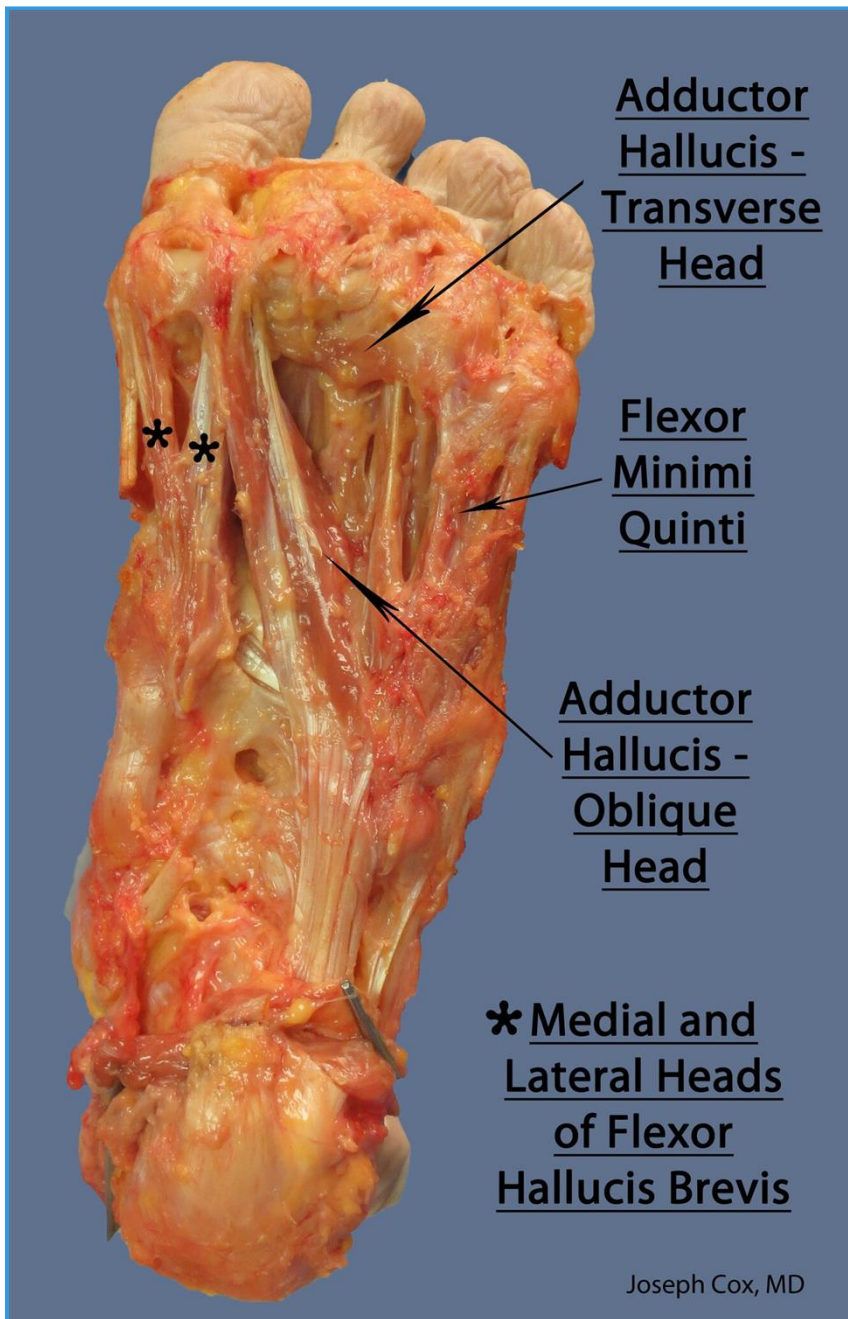
Summary

<ul style="list-style-type: none"> ■ Lumbricals 		
<ul style="list-style-type: none"> ■ Origin 	<ul style="list-style-type: none"> ■ FDL tendon 	<ul style="list-style-type: none"> ■  Layer 2
<ul style="list-style-type: none"> ■ Insertion 	<ul style="list-style-type: none"> ■ EDL tendon 	<ul style="list-style-type: none"> ■  Layer 2
<ul style="list-style-type: none"> ■ Action 	<ul style="list-style-type: none"> ■ Flex metatarsophalangeal, extends interphalangeal 	<ul style="list-style-type: none"> ■  Layer 2
<ul style="list-style-type: none"> ■ Innervation 	<ul style="list-style-type: none"> ■ Lumbrical 1: medial plantar nerve ■ Lumbrical 2-4: lateral plantar nerve 	<ul style="list-style-type: none"> ■ 

		 <p>Layer 2</p>
<ul style="list-style-type: none"> ■ Arterial supply 	<ul style="list-style-type: none"> ■ Medial and lateral plantar artery 	<ul style="list-style-type: none"> ■  <p>Layer 2</p>

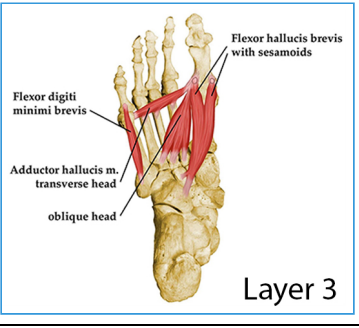
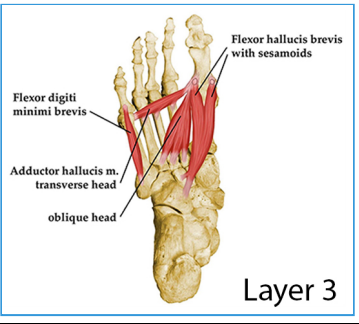
95- Flexor Hallucis Brevis

Images



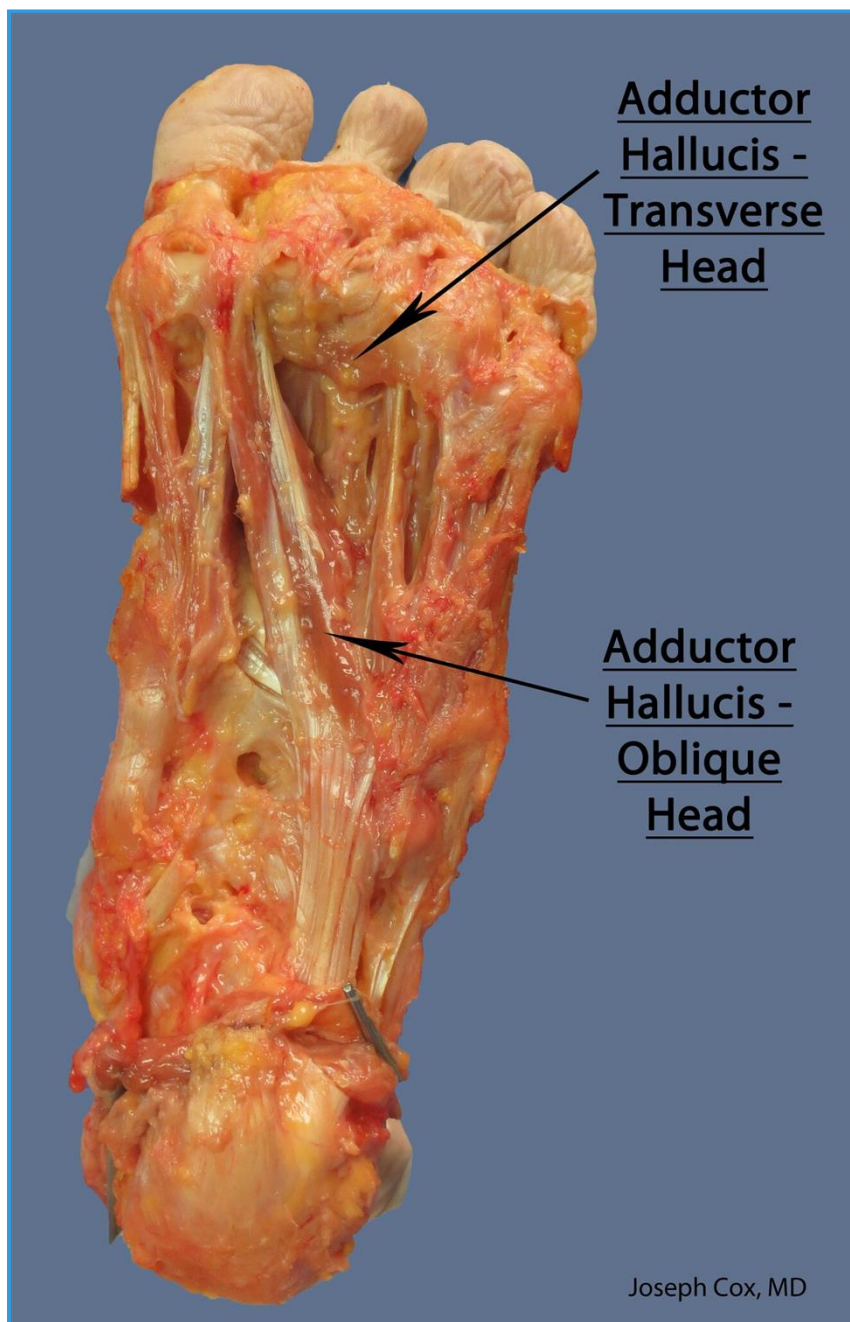
Summary

<ul style="list-style-type: none"> Flexor hallucis brevis 		
<ul style="list-style-type: none"> Origin 	<ul style="list-style-type: none"> Cuboid / lateral cuneiform 	
<ul style="list-style-type: none"> Insertion 	<ul style="list-style-type: none"> Proximal phalanx of great toes 	
<ul style="list-style-type: none"> Action 	<ul style="list-style-type: none"> Flexes great toe 	

<ul style="list-style-type: none"> ■ Innervation 	<ul style="list-style-type: none"> ■ Medial plantar nerve 	<ul style="list-style-type: none"> ■ 
<ul style="list-style-type: none"> ■ Arterial supply 	<ul style="list-style-type: none"> ■ Medial plantar artery 	<ul style="list-style-type: none"> ■ 

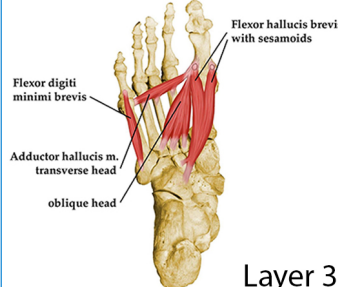
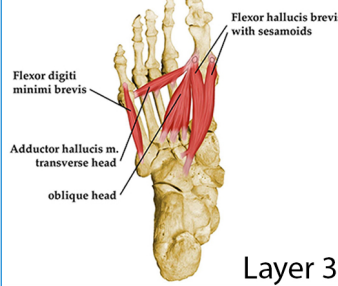
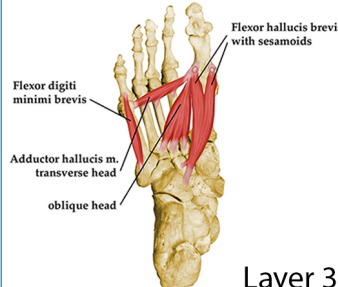
96- Adductor Hallucis

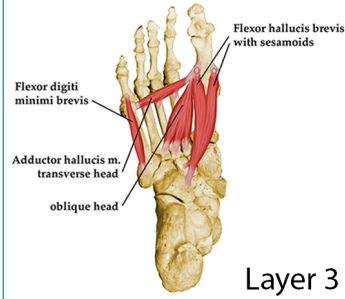
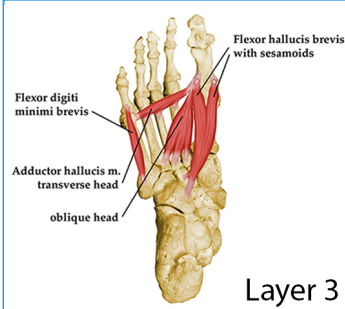
Images



Summary

■ Adductor hallucis

<p>■ Origin</p>	<p>■ Oblique: second to fourth metatarsal</p>	<p>■ </p>
<p>■ Insertion</p>	<p>■ Proximal phalanx of great toe (lateral side)</p>	<p>■ </p>
<p>■ Action</p>	<p>■ Adduct great toe</p>	<p>■ </p>

<ul style="list-style-type: none"> ■ Innervation 	<ul style="list-style-type: none"> ■ Lateral plantar nerve 	<ul style="list-style-type: none"> ■ 
<ul style="list-style-type: none"> ■ Arterial supply 	<ul style="list-style-type: none"> ■ Lateral plantar artery 	<ul style="list-style-type: none"> ■ 

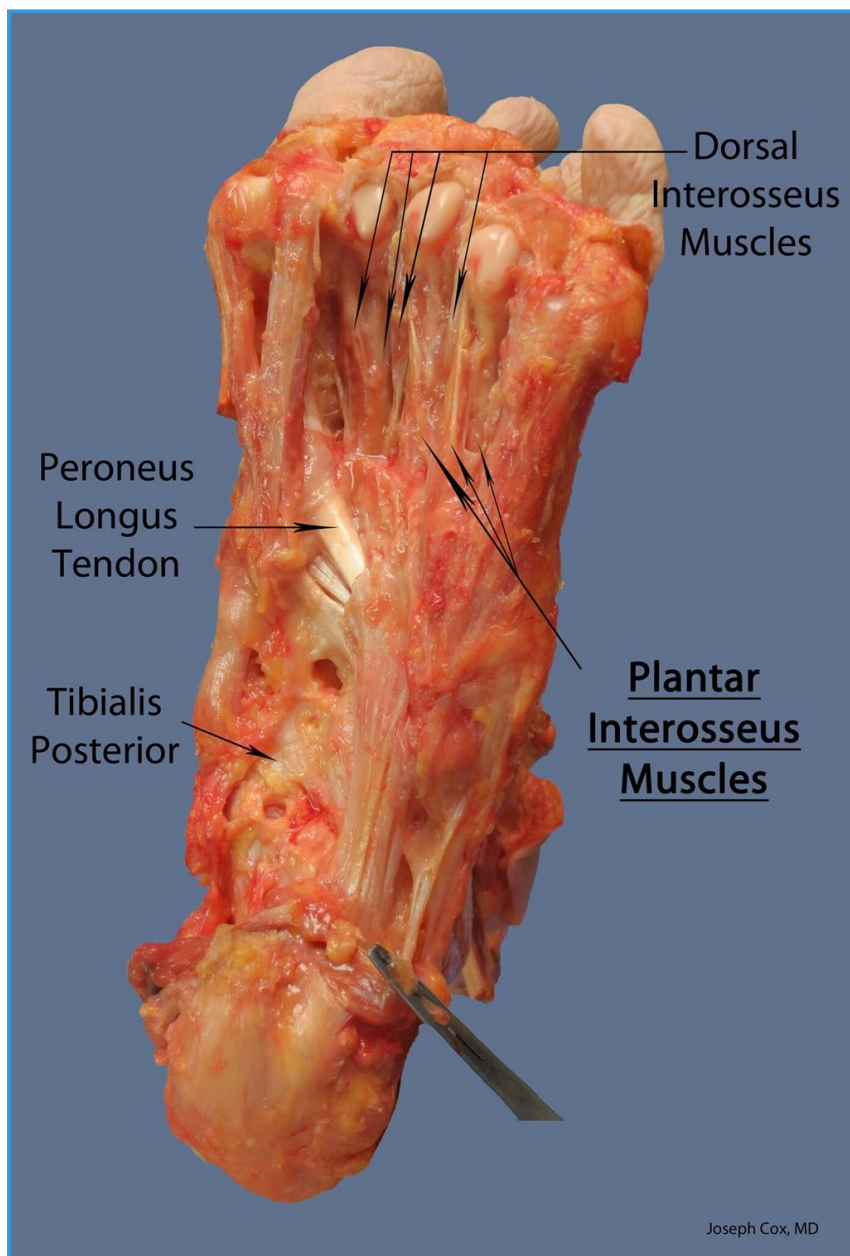
97- Flexor Digiti Minimi Brevis

- Summary

<ul style="list-style-type: none"> Flexor digiti minimi brevis 		
<ul style="list-style-type: none"> Origin 	<ul style="list-style-type: none"> Base of fifth metatarsal head 	
<ul style="list-style-type: none"> Insertion 	<ul style="list-style-type: none"> Proximal phalanx of small toe 	
<ul style="list-style-type: none"> Action 	<ul style="list-style-type: none"> Flexes small toe 	
<ul style="list-style-type: none"> Innervation 	<ul style="list-style-type: none"> Lateral plantar nerve 	
<ul style="list-style-type: none"> Arterial supply 	<ul style="list-style-type: none"> Lateral plantar artery 	

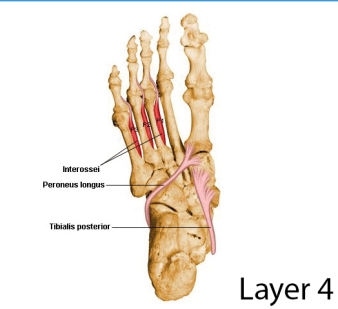
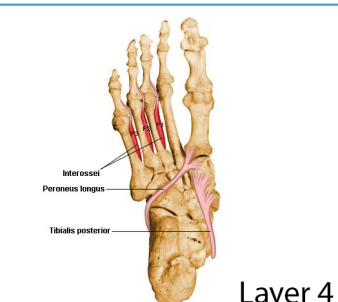
98- Plantar Interossei

Images



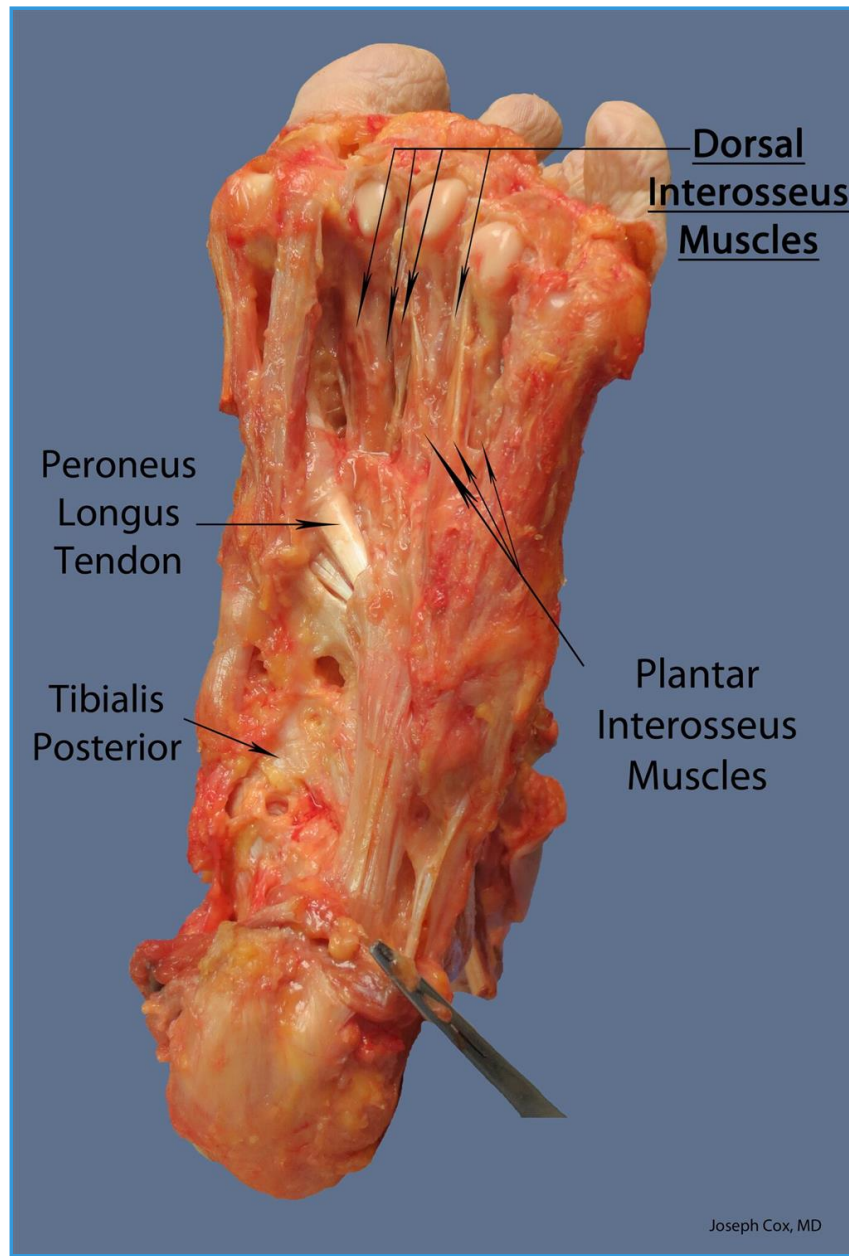
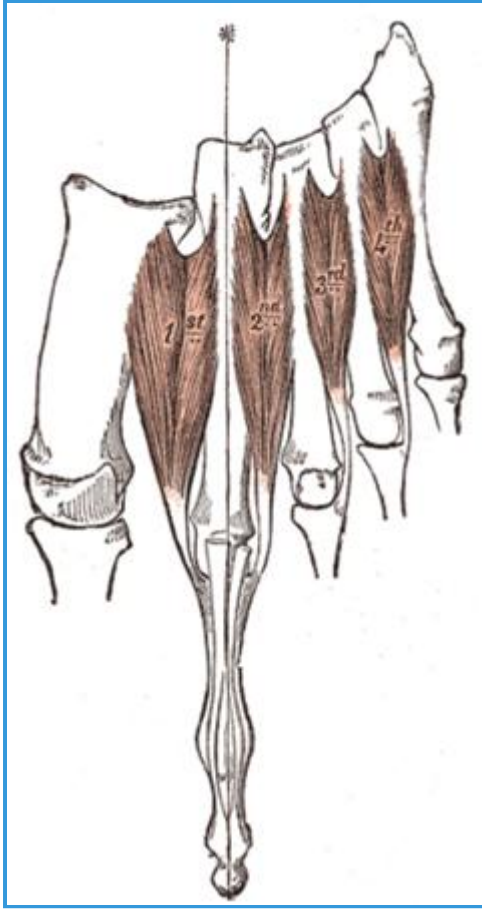
Summary

<ul style="list-style-type: none"> Plantar interossei (3 muscles) 		
<ul style="list-style-type: none"> Origin 	<ul style="list-style-type: none"> Third to fifth metatarsals 	
<ul style="list-style-type: none"> Insertion 	<ul style="list-style-type: none"> Proximal phalanges medially 	
<ul style="list-style-type: none"> Action 	<ul style="list-style-type: none"> Adducts toes 	
<ul style="list-style-type: none"> Innervation 	<ul style="list-style-type: none"> Lateral plantar nerve 	<ul style="list-style-type: none">

		
<ul style="list-style-type: none"> ■ Arterial supply 	<ul style="list-style-type: none"> ■ Lateral plantar artery 	<ul style="list-style-type: none"> ■ 


99- Dorsal Interossei Lpn





Images



Summary

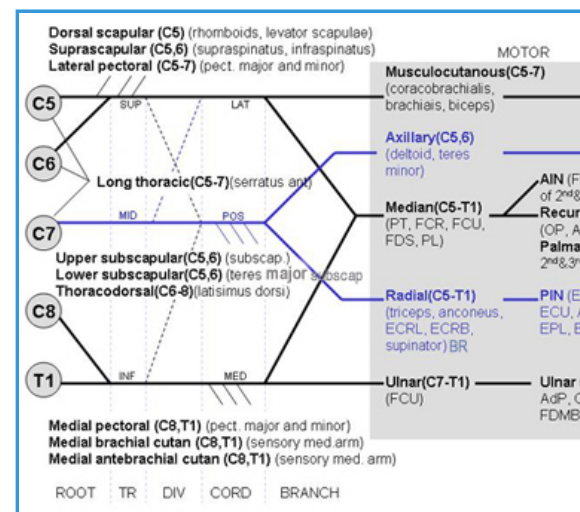
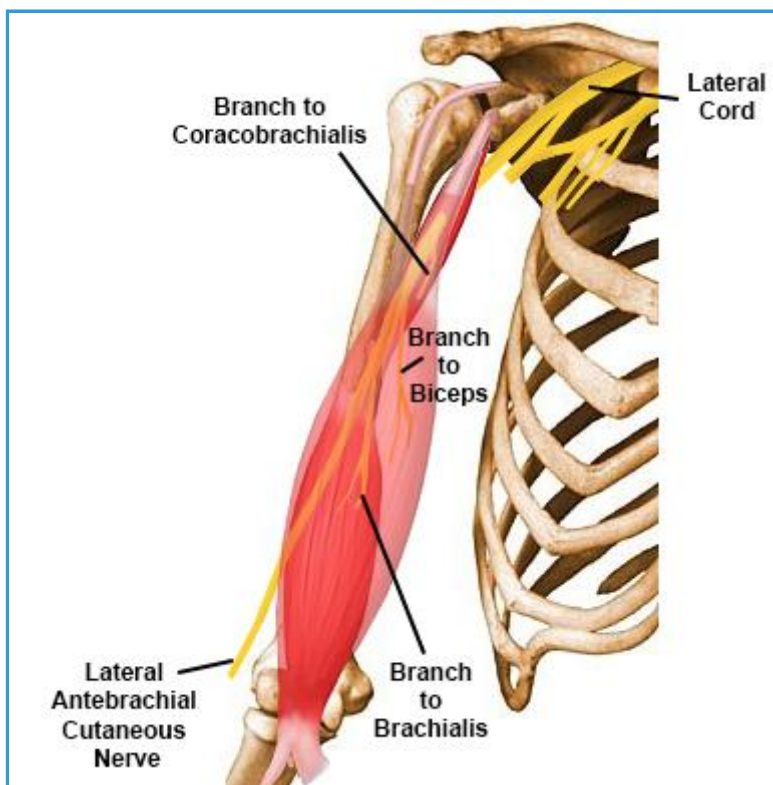
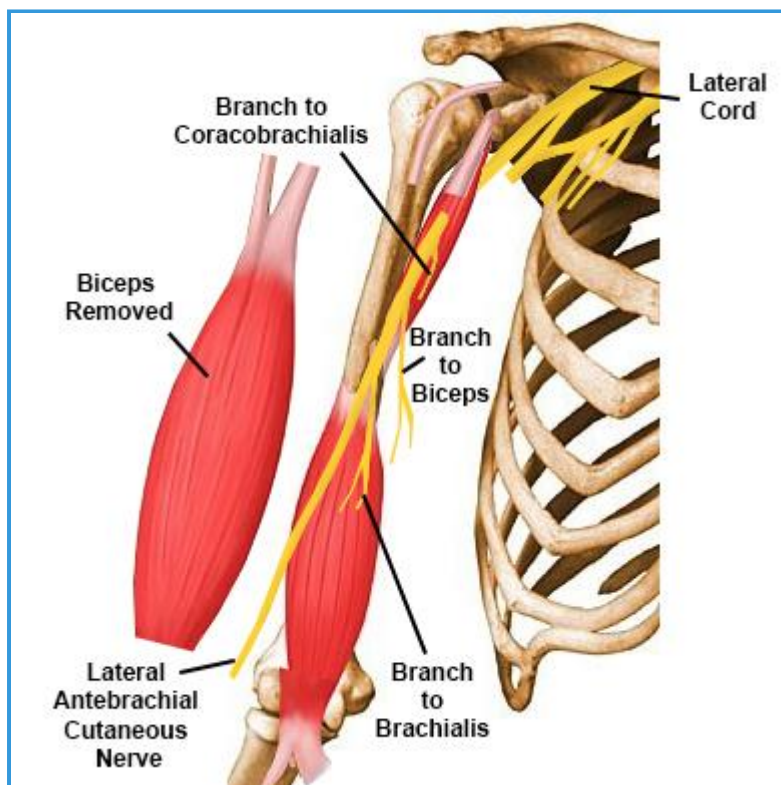
○ ■ Dorsal interossei (4 muscles)

<p>■ Origin</p>	<p>■ Two heads from the proximal half of the sides of adjacent metatarsal bones</p>	<p>■ </p> <p>Dorsal interossei</p>
<p>■ Insertion</p>	<p>■ The two heads of each muscle form a central tendon that insert on the bases of the second, third, and fourth proximal phalanges and into the aponeurosis of the tendons of EDL. The first is inserted into the medial side of the second toe; the other three are inserted into the lateral sides of the 2nd, 3rd, and 4th toes.</p>	<p>■</p>

		
<ul style="list-style-type: none"> ■ Action 	<ul style="list-style-type: none"> ■ Abduct MTP joint 	<ul style="list-style-type: none"> ■ 
<ul style="list-style-type: none"> ■ Innervation 	<ul style="list-style-type: none"> ■ Lateral plantar nerve 	<ul style="list-style-type: none"> ■ 
<ul style="list-style-type: none"> ■ Arterial supply 	<ul style="list-style-type: none"> ■ Anterior tibial artery via dorsalis pedis and dorsal metatarsal arteries; Posterior tibial artery via lateral plantar and plantar metatarsal arteries 	<ul style="list-style-type: none"> ■ 

100- Musculocutaneous Nerve

Images



• Innervation

- Motor
- Sensory
 - lateral antebrachial cutaneous nerve
 - forearm sensory

• Origin

- C5,6,7
 - superior trunk
 - lateral cord
 - **musculocutaneous nerve**
 - branch to coracobrachialis
 - branch to biceps
 - branch to brachialis
 - lateral antebrachial cutaneous nerve (terminal branch)

• Course

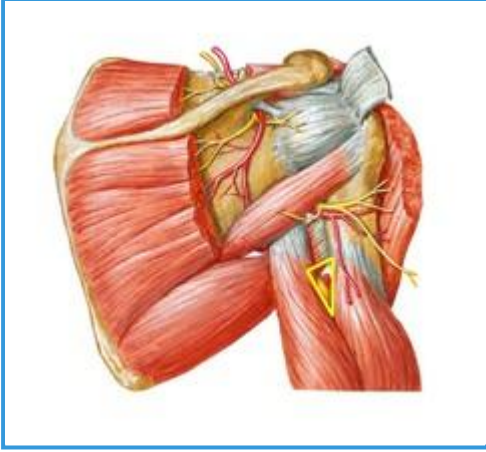
- Pierces Coracobrachialis
 - pierces coracobrachialis 3-8 cm distal to coracoid

- gives branch to coracobrachialis
- Splits biceps and brachialis
 - runs between biceps and brachialis in the anterior compartment to enter the lateral aspect of the arm
 - gives branch to biceps and brachialis
- Pierces deep fascia lateral to biceps brachii
 - a little above the elbow it pierces the deep fascia lateral to the tendon of the biceps brachii
- Becomes lateral antebrachial cutaneous nerve (terminal branch)
 - emerges lateral to distal bicep tendon and brachioradialis to form lateral antebrachial cutaneous nerve
- Injury & Clinical Conditions
 - **Musculocutaneous Nerve Injury**
 - usually iatrogenic during deltopectoral approach with dissection or retraction medial to conjoint tendon

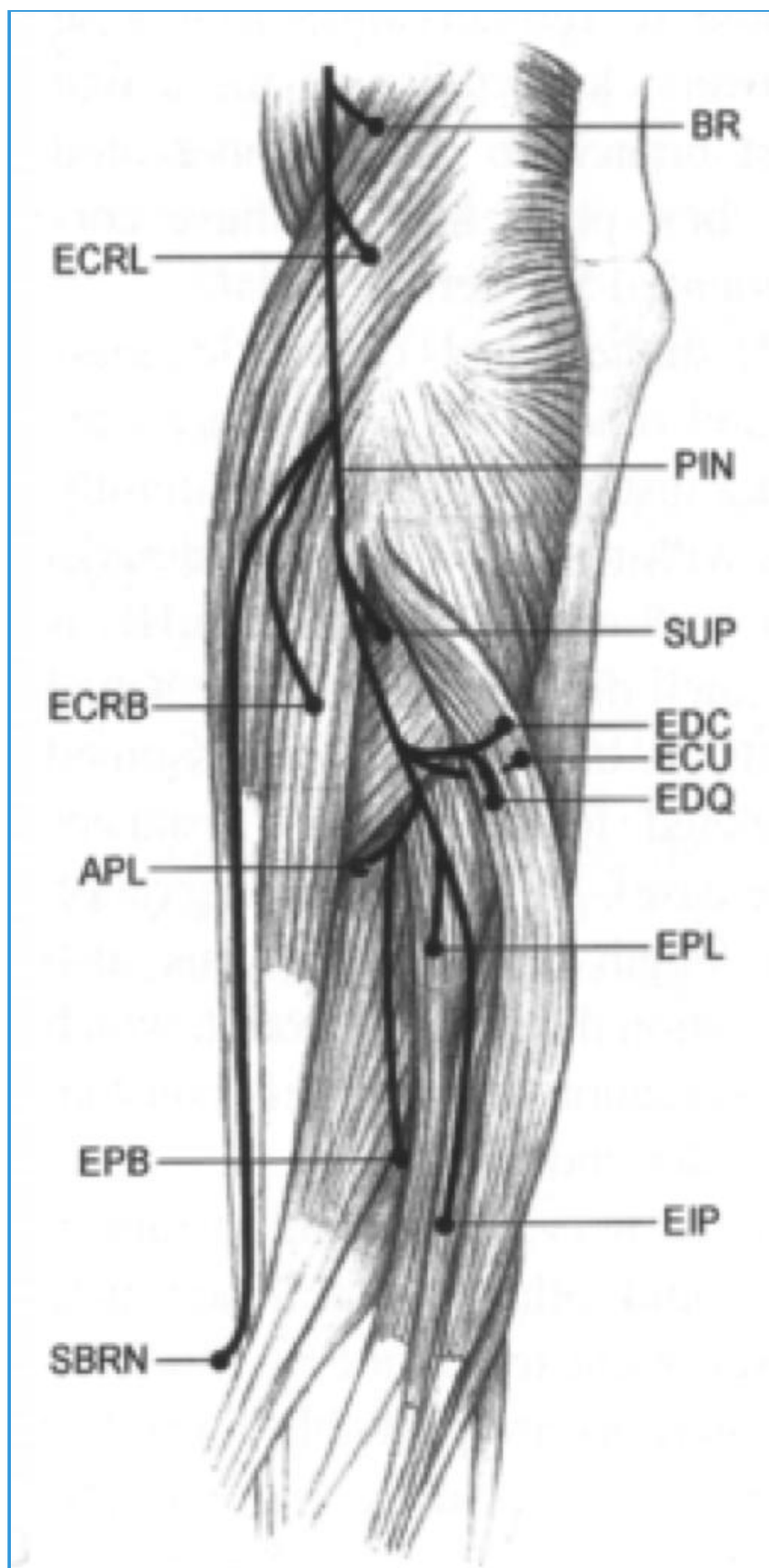
101- Radial Nerve

Innervation

- Motor



- radial nerve proper
- ▶_triceps
 - ▶_anconeus
 - ▶_ECRL
 - ▶_ECRB
 - ▶_brachioradialis



- PIN

- ▶_ED
- ▶_supinator
- ▶_EDM
- ▶_ECU
- ▶_APL
- ▶_EPL
- ▶_EPB
- ▶_EIP

- Sensory

- posterior cutaneous nerve arm
- posterior cutaneous nerve - forearm
- superficial branch radial nerve
- dorsal digital branch

Origin

- Radial nerve originates from the posterior cord of the brachial plexus (C5-T1)

- behind axillary artery

Course

- **Posterior wall axilla**

- courses on the posterior wall of the axilla (on subscapularis, latissimus dorsi, teres major)
- 3 Branches in axilla
 - posterior cutaneous nerve of the arm
 - branch to long head of triceps
 - branch to medial head of triceps

- **Triangular interval**

- it then runs through the triangular interval with profunda brachii artery in posterior compartment between long head of triceps and humerus ?

- **Spiral groove**

- next it courses through the spiral groove between lateral and medial heads of triceps
 - bottom line = Safe zone posteriorly of 10 cm distal to the lateral acromion and 10 cm proximal to lateral epicondyle
- branches in spiral groove
 - inferior lateral cutaneous nerve of the arm
 - posterior cutaneous nerve of the forearm
 - branch to lateral head of triceps
 - branch to medial head of triceps and anconeus

- **Lateral intermuscular septa**

- next it passes through the lateral intermuscular septa never less than 7.5 cm above the distal articular surface .
- runs *between brachialis and brachioradialis* (anterior to lateral epicondyle)
 - gives branches to supply: lateral brachialis, brachioradialis, ECRL, ECRB

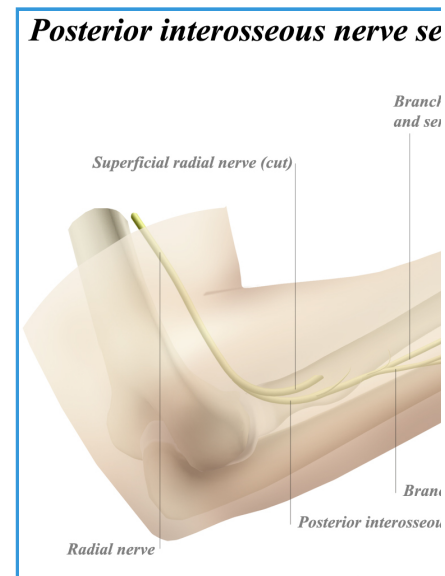
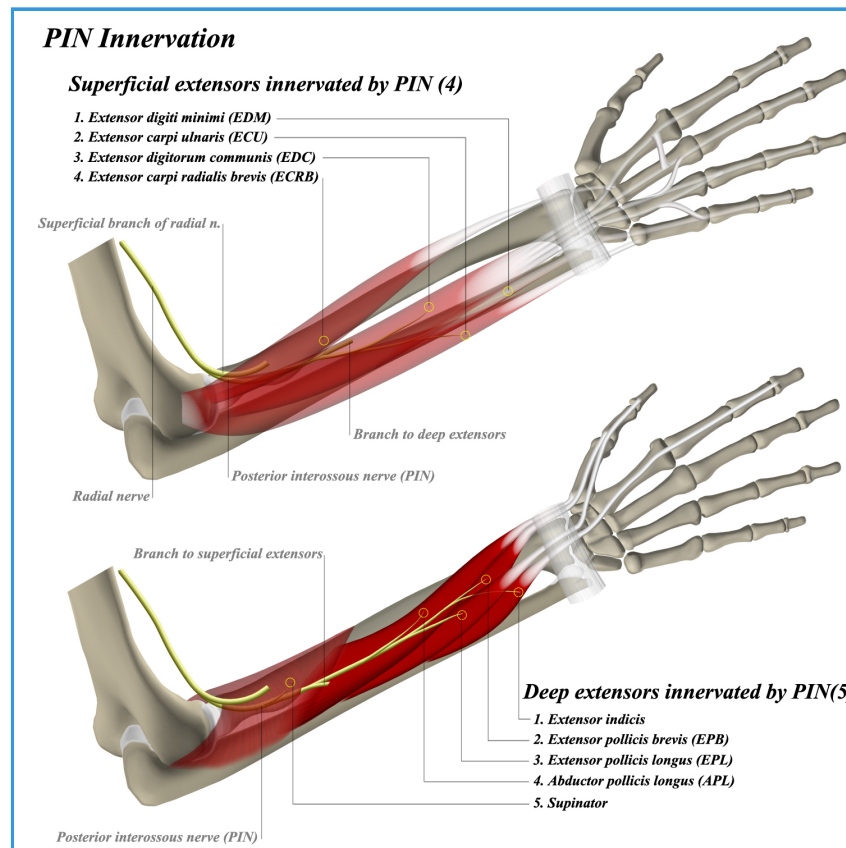
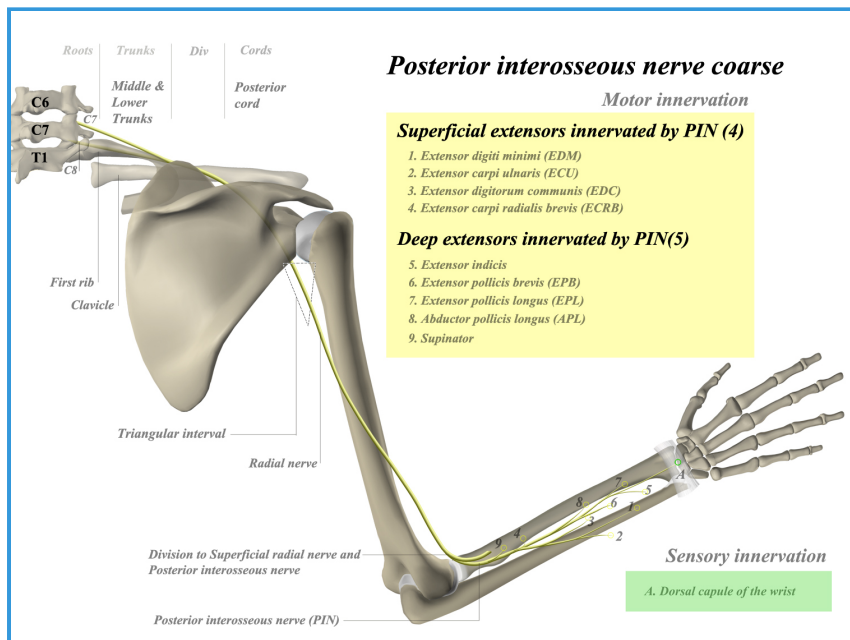
- **Terminal branches**

- level of radiohumeral joint line, divides into terminal branches
 - **superficial sensory branch**
 - **Deep branch/PIN**
 - **ECRB branch**

Injury & Clinical Conditions

- **PIN compression Syndrome**
- **Radial Tunnel Syndrome**

102- Posterior Interosseous Nerve



Course

- **Origins**
 - originates from the radial nerve at the radiohumeral joint line
- **Course**
 - **arcade of Frosche at radial head**
 - dives under supinator at arcade of Frohse (thickened edge of between heads of supinator)
 - **forearm posterior compartment**
 - winds around radial neck within substance of muscle to posterior compartment of forearm
 - **interosseous membrane**
 - reaches interosseous membrane of forearm and ends as sensation to dorsal wrist capsule
 - **dorsal wrist capsule**

Motor Innervation

- **Motor**
 - **common extensors**
 - ECRB (often from radial nerve proper, but can be from PIN)
 - Extensor digitorum communis (EDC)
 - Extensor digiti minimi (EDM)
 - Extensor carpi ulnaris (ECU)

- **deep extensors**
 - Supinator
 - Abductor pollicis longus (APL)
 - Extensor pollicus brevis (EPB)
 - Extensor pollicus longus (EPL)
 - Extensor indicis proprius (EIP)

Sensory Innervation

- Sensory
 - **sensory fibers to dorsal wrist capsule**
 - provided by terminal branch which is located on the floor of the 4th extensor compartment
 - no cutaneous innervation

Clinical

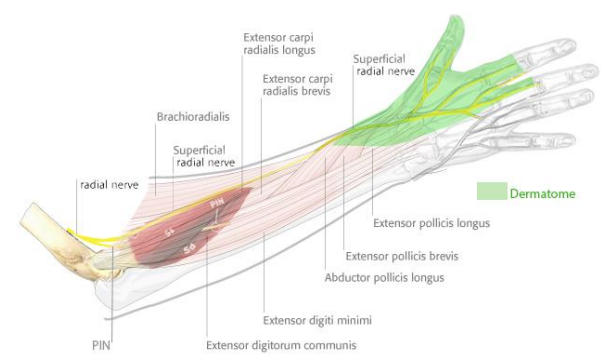
- **PIN compression Syndrome**
 - in PIN palsy, the last muscle to recover is the extensor indicis proprius
- **Dorsal Approach to Radius (Thompson)**

103- Superficial Radial Nerve

Additional Images

Innervation

- Sensory
 - medial branch
 - sensory function to the ulnar half of the dorsal thumb, dorsal index, long, and radial half of the ring finger
 - lateral branch
 - sensory function to the radial dorsal thumb



Origin

- Originates from the radial nerve proper at the level of the radiocapitellar joint.

Course

- **Underneath the brachioradialis**
 - runs distally in the forearm underneath the brachioradialis, lateral to the radial artery.
- **Forearm deep fascia**
 - It pierces the deep fascia of the forearm approximately 7 cm proximal to the radiocarpal joint (9 cm proximal to radial styloid)
 - runs over snuff box to supply dorsal radial surface of hand
- **Terminal branches**
 - it then divides into two branches: medial and lateral.

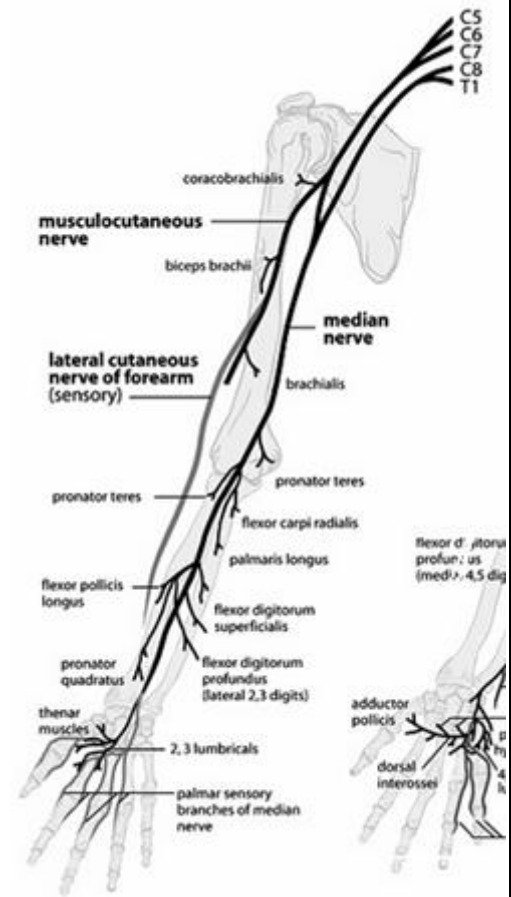
Injury & Clinical Conditions

- Wartenberg's Syndrome


104- Median Nerve

Innervation

- Motor
 - superficial volar forearm group
 - Flexor carpi radialis
 - Palmaris longus
 - Pronator teres
 - Flexor digitorum superficialis
 - intermediate group
 - Flexor digitorum profundus (lateral)
 - Flexor pollicis longus
 - Pronator quadratus
 - hand
 - 1st and 2nd lumbricals
 - Opponens pollicis
 - Abductor pollicis brevis
 - Flexor pollicis brevis



Origin

- Brachial plexus 
 - C5-T1 roots
 - medial and lateral cords

Course

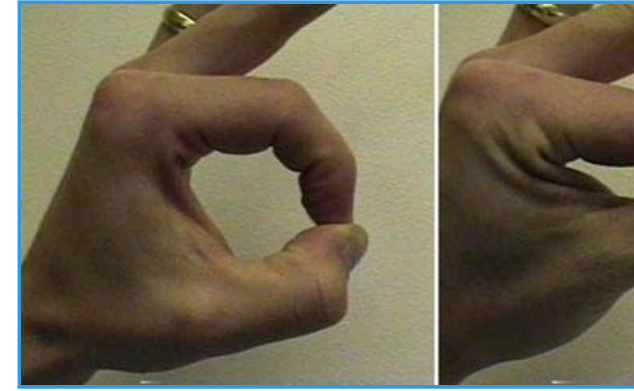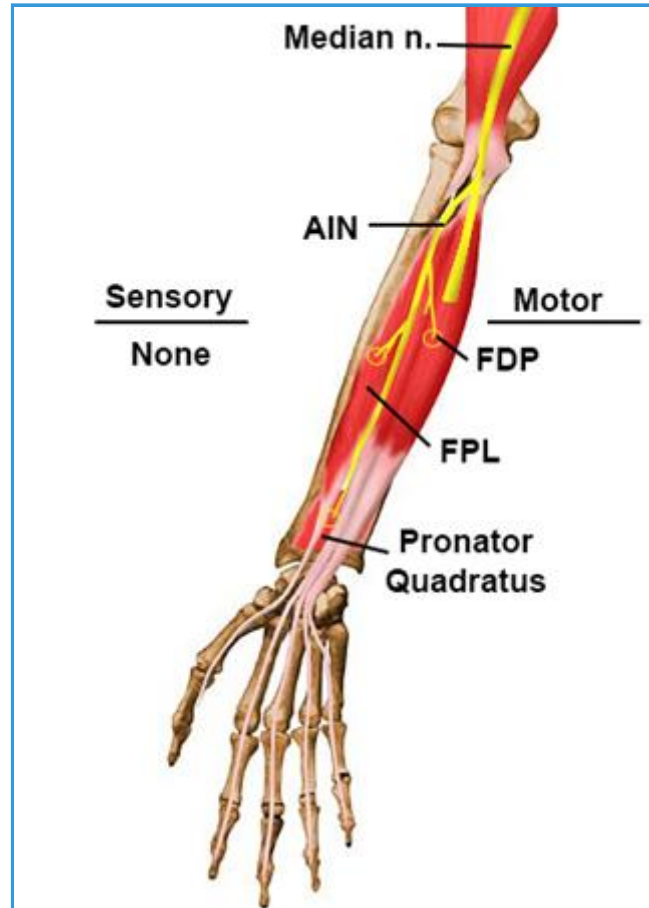
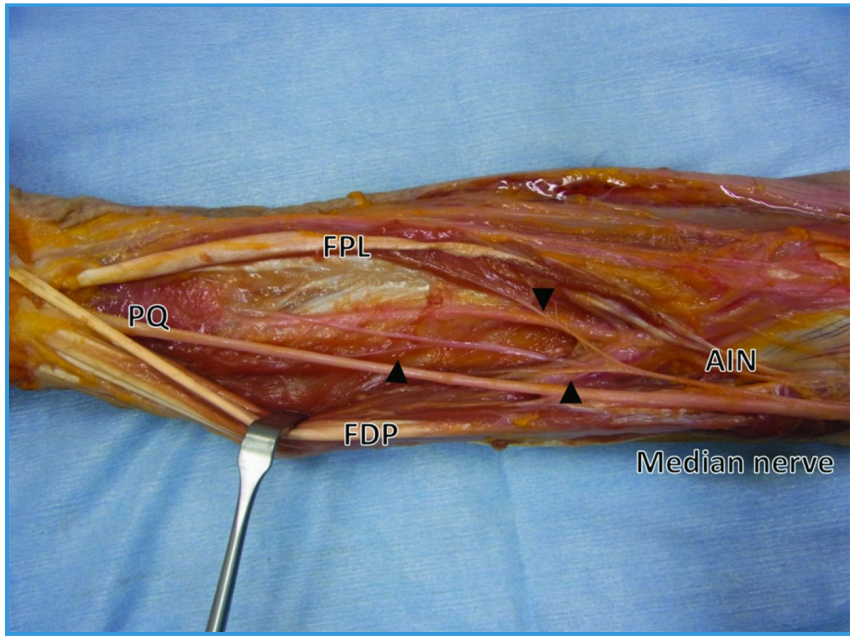- Anterior compartment of arm
 - anterior compartment (anteromedial to humerus)
 - runs with brachial artery (lateral in upper arm / medial at elbow)
 - no branches in the arm
- Forearm
 - enters the forearm between the pronator teres and biceps tendon
 - travels between flexor digitorum superficialis (FDS) and flexor digitorum profundus (FDP)
 - then emerges between the FDS and flexor pollicis longus (FPL)
- Hand

- the nerve then enters the hand via the carpal tunnel, along with the tendons of the FDS, FDP and FPL
- Terminal branches
 - anterior interosseous branch (AIN)
 - innervates the deep volar compartment of forearm except the ulnar half of the FDP
 - palmar cutaneous branch
 - supplies sensory innervation to lateral palm
 - recurrent branch (to thenar compartment)
 - digital cutaneous branches
 - supply the radial 3 1/2 digits (palmar)
 - can also supply the index, long, and ring fingers dorsally

Clinical Conditions

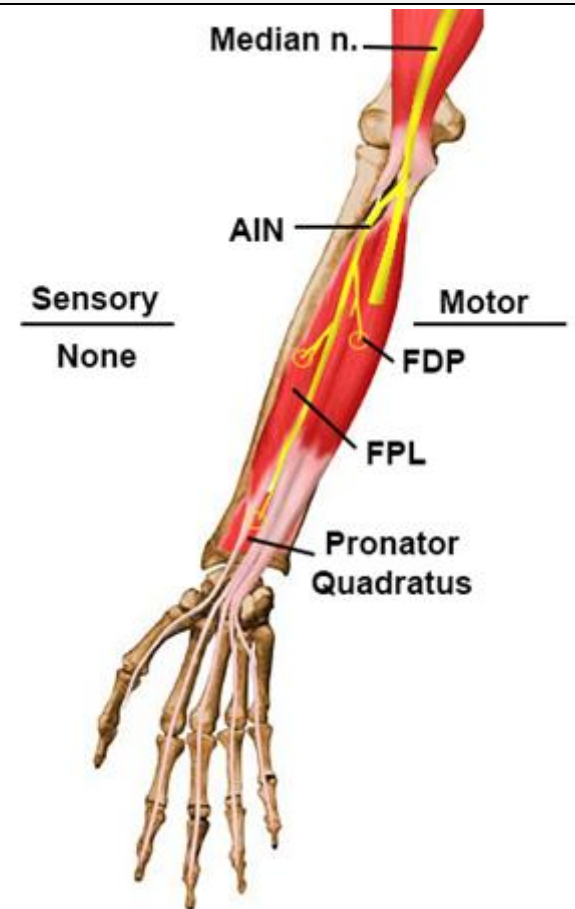
- **Carpal Tunnel Syndrome**
- **AIN Neuropathy**
- **Pronator Syndrome**

105- Anterior Interosseous Nerve



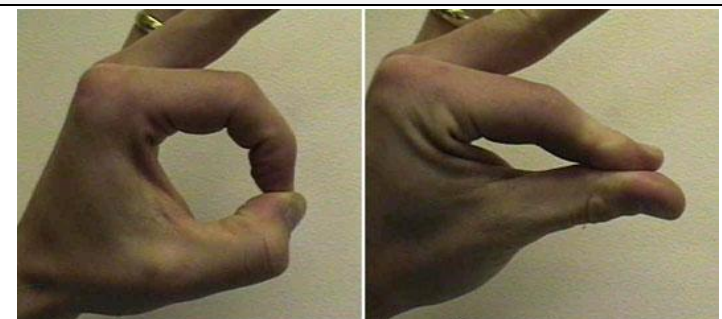
Course

- Origins
 - arises from the median nerve at the radiohumeral joint line
 - C5-T1 roots
 - medial and lateral cord of brachial plexus
 - median nerve
 - **AIN**
 - branch to FDP
 - branch to FPL
 - branch to pronator quadratus
- Course
 - arises 5-8 cm distal to lateral epicondyle
 - passes between two heads of pronator teres
 - runs along the volar surface of the FDP
 - courses distally along the interosseous membrane
 - terminates in PQ near wrist joint



Motor Innervation

- Motor
 - deep forearm muscles
 - **flexor digitorum profundus** - radial half
 - **flexor pollicis longus**



- pronator quadratus

Sensory Innervation

- Sensory
 - sensory fibers to volar wrist joint capsule
 - no cutaneous innervation

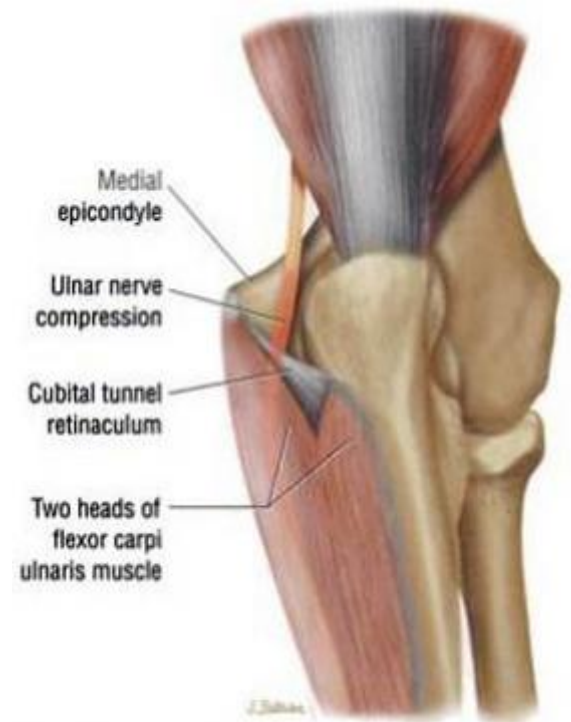Clinical Conditions

- **AIN compressive neuropathy**
- **Pediatric supracondylar fractures**

106- Ulnar Nerve

Origin

- Ulnar nerve comes from the medial cord of the brachial plexus (C8-T1)



Course

- Arm
 - lies **posteromedial** to brachial artery in anterior compartment of upper 1/2 arm
 - pierces medial IM septum at the **arcade of Struthers** ~ 8cm from medial epicondyle and **lies medial to the triceps**
 - the arcade of Struthers is an aponeurotic band extending from the medial IM septum to the medial head of the triceps
- Elbow
 - runs behind medial epicondyle with **superior ulnar collateral artery**
 - Cubital tunnel
 - roof - **Osbourne's** ligament proximally (extension of deep forearm fascia between heads of FCU) and FCU aponeurosis distally
 - floor - **posterior and transverse** bands of **MCL** and **elbow joint capsule**
 - sends small sensory branch to elbow that can be sacrificed
- Forearm
 - enters forearm between 2 heads (humeral and ulnar heads) of FCU
 - runs between FCU and FDP
- Wrist
 - the ulnar nerve and artery pass **superficial** to the transverse carpal ligament
 - bifurcates into sensory and deep motor branches in Guyon's canal
 - roof - volar carpal ligament
 - floor - transverse carpal ligament, hypothenar muscles
 - ulnar border - pisiform and pisohamate ligament, abductor digiti minimi muscle belly
 - radial border - hook of hamate

Innervation

- **Motor Innervation**

- forearm
 - FCU
 - FDP ring and small
- thenar
 - adductor pollicis
 - deep head of flexor pollicis brevis (FPB)
- fingers
 - interossei (dorsal & palmar)
 - 3rd & 4th lumbricals
- hypothenar muscles
 - abductor digiti minimi
 - opponens digiti minimi
 - flexor digiti minimi

- **Sensory Innervation**

- sensory branches of ulnar nerve
 - dorsal cutaneous branch
 - palmar cutaneous branch
 - superficial terminal branches

Clinical Conditions

- **Cubital Tunnel Syndrome**

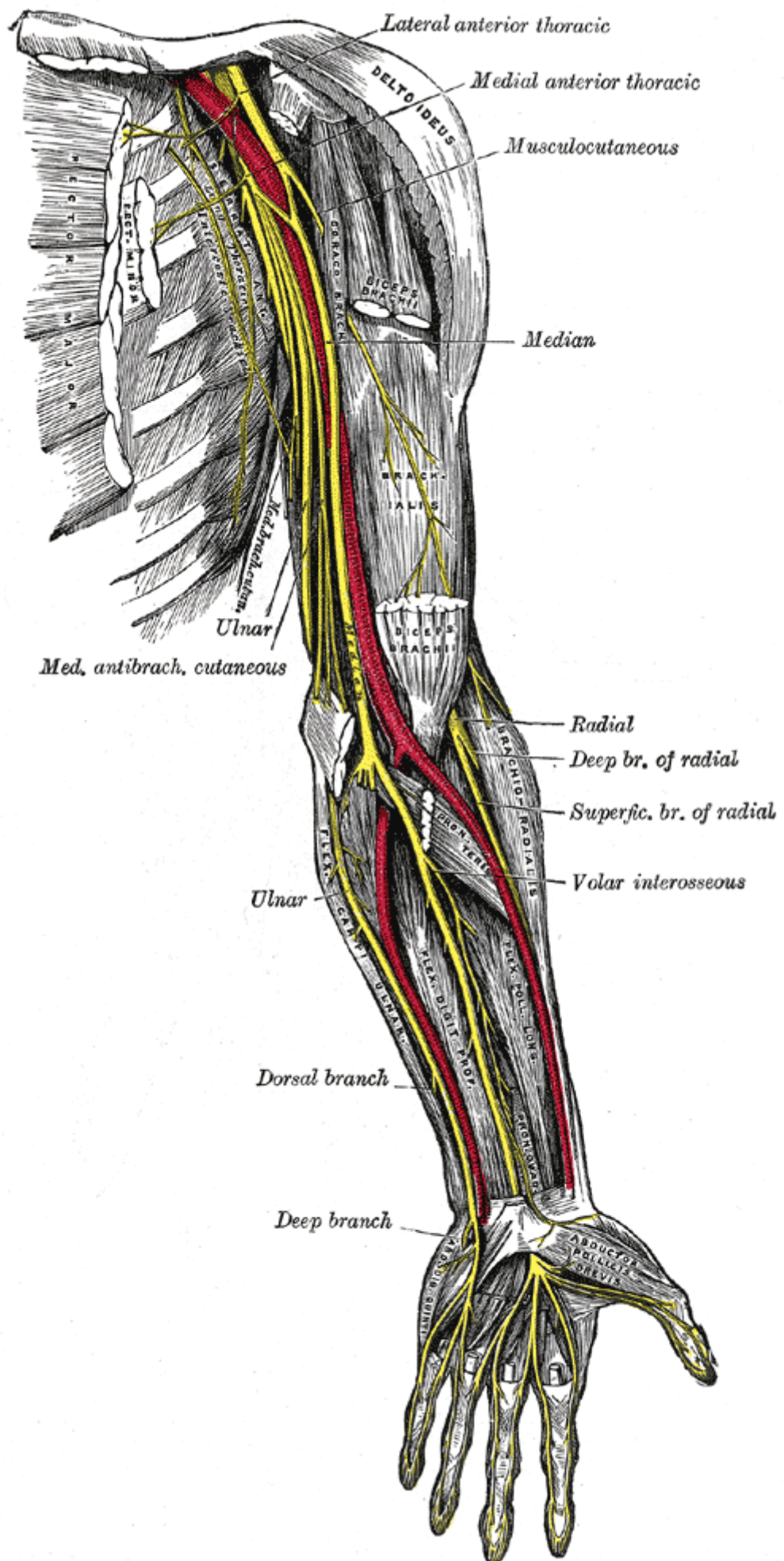
- sites of compression (proximal to distal)
 - medial intermuscular septum
 - most proximal site, 8cm proximal to medial epicondyle
 - Arcade of Struthers
 - medial epicondyle (osteophytes)
 - cubital tunnel retinaculum (Osborne's ligament)
 - anconeus epitrochlearis muscle replaces Osborne's ligament in 11% of population, causing static compression
 - aponeurosis of the two heads of the FCU (arcuate ligament)
 - often continuous with Osbourne's ligament
 - deep flexor/pronator aponeurosis
 - most distal site, 4 cm distal to medial epicondyle
- elbow flexion reduce cubital tunnel volume because
 - FCU aponeurosis tenses
 - Osborne's ligament becomes taught
 - MCL bulges into cubital tunnel
- the internal anatomy of the ulnar nerve explains the predominance of hand symptoms in cubital tunnel syndrome

- fibers to FCU and FDP are central and hand intrinsic fibers are peripheral

• Ulnar tunnel syndrome

○ compression in Guyon's Canal

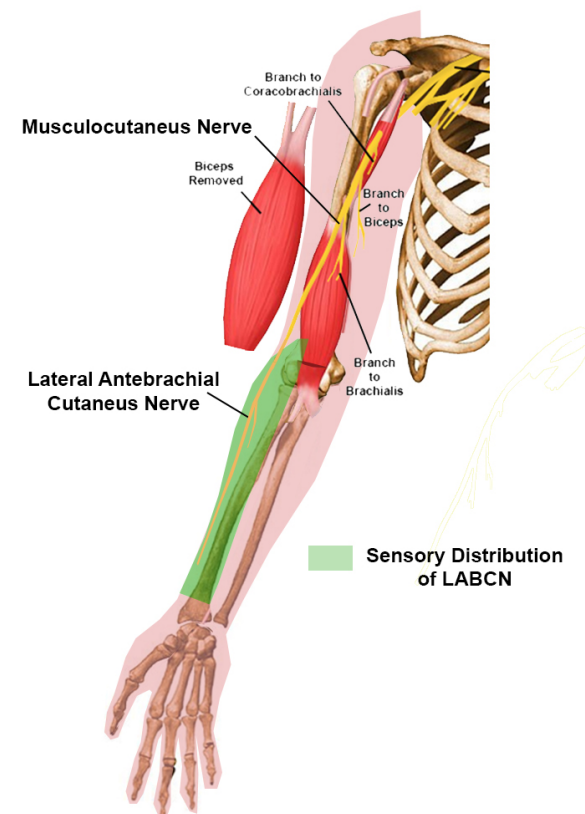
- no involvement of dorsal cutaneous nerve since it branches before canal
- no involvement of FDP of 4th & 5th and FCU
- causes
 - ganglia most common cause (from triquetrohamate joint, 30-50%)
 - other causes include mass, trauma (fracture of distal radius or ulna, hook of hamate), muscle anomaly, ulnar artery aneurysm or thrombosis
- compression sites
 - Zone 1: proximal to bifurcation, **both** motor & sensory symptoms
 - caused by hook of hamate fracture and ganglia
 - Zone 2: deep motor branch, **motor** symptoms only
 - caused by hook of hamate fracture and ganglia
 - Zone 3: superficial sensory branch, **sensory** symptoms only
 - caused by ulnar artery aneurysm or thrombosis




107- Lateral Antebrachial Cut Nerve

Innervation

- Motor
 - none
- Sensory
 - radial forearm
- Reflexes
 - none



Origin

- C5,6,7 
 - superior trunk
 - lateral cord
 - musculocutaneous nerve ▶
 - **lateral antebrachial cutaneous nerve**

Course of Lateral Antebrachial Cutaneous Nerve

- Originates from the **musculocutaneous nerve**
 - passes behind the cephalic vein
 - pierces the deep fascia lateral to the biceps tendon
 - divides at the level of the elbow joint into volar and dorsal branches

Terminal Branches

- Volar
 - runs distally along radial border of forearm, supplying lateral volar forearm skin sensation
 - small branches innervate the radial aspect of radiocarpal joint
 - ends in communicating branches to
 - superficial branch of the radial nerve (dorsal radial thumb innervation)
 - palmar cutaneous branch of median nerve (volar thumb innervation)
- Dorsal

- runs distally along dorsal radial forearm, supplying dorsal-lateral cutaneous innervation
- ends in communicating branches
 - superficial radial nerve
 - dorsal antebrachial cutaneous branch of radial nerve

Nerve Injury & Clinical Conditions

- Injury
 - results in loss of sensation along the radial aspect of the forearm

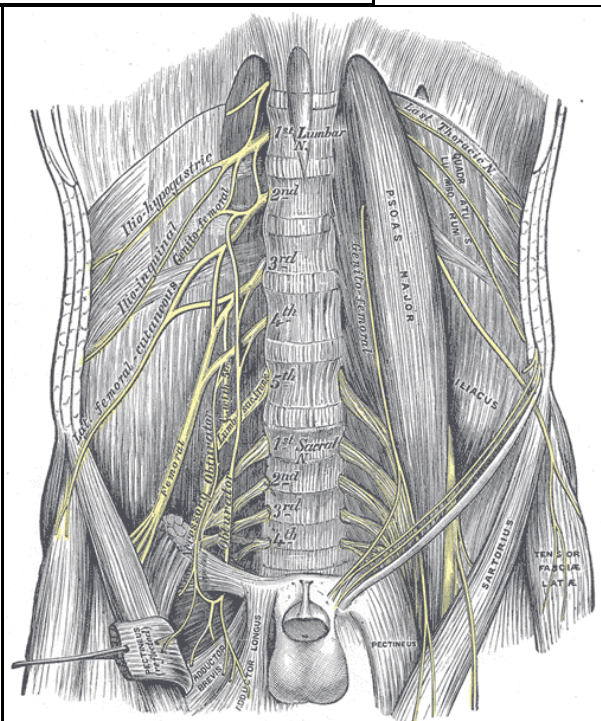
108- Lumbosacral Plexus

Anatomy

- ventral rami from T12-S3
- found on the anterior surface of the quadratus lumborum and lies posterior to the psoas muscle
- sciatic nerve composed of L4-S3
 - peroneal division more lateral than the tibial division
- **NAVAL** : Within the triangle, from a lateral to medial direction, are the femoral **N**erve, **A**rtery, and **V**ein and the **L**ymphatic vessels
- **POP'S IQ** : nerves exiting below piriformis are : **P**udendal, **O**bturator internus, **P**ostfemoral cutaneous, **S**ciatic, **I**nferior gluteal, **Q**uadratus femoris
- L5 nerve root endangered during percutaneous iliosacral screw placement

Superior gluteal	L4-S1	Gluteus medius and minimus/tensor fascia lata
------------------	-------	---

Quadratus femoris	L4-S1	Quadratus femoris/inferior gemellus
-------------------	-------	-------------------------------------



Peroneal	L4-S2	Biceps (short head)/tibialis anterior/extensor digitorum longus/peroneus tertius/extensor hallucis longus
		Peroneus longus and brevis/extensor hallucis

brevis/extensor
digitorum brevis

• Tibia L4-S3 Semimembranosus/semitendinosus/biceps (long head)/adductor magnus/gastrocnemius/soleus/plantarisis/popliteus/tibialis posterior/flexor digitorum longus/flexor hallucis longus

• Obturator internus L5-S2 Obturatorius internus/superior gemellus

• Inferior gluteal L5-S2 Gluteus maximus

• Posterior femoral cutaneous S1-S3
○ Sensory: posterior thigh

109- Femoral Nerve

Innervation

- Motor
 - anterior division branches
 - sartorius
 - pectineus
 - posterior division branches
 - rectus femoris
 - vastus medialis
 - vastus lateralis
 - vastus intermedius
- Sensory
 - anterior division branches provides sensation to anteromedial aspect of the thigh, consists of 2 branches:
 - medial cutaneous nerve of thigh
 - intermediate cutaneous nerve
 - posterior division
 - saphenous nerve
 - provides sensation to anteromedial aspect of lower leg
 - infrapatellar branches to knee
 - pierces the sartorius and fascia lata medial to the knee, and provides cutaneous innervation to the skin anteriorly over the patella

Origin

- L2 to L4 nerve roots
 - lumbosacral plexus
 - femoral nerve
 - anterior division branches
 - posterior division branches

Course

- Through psoas
 - courses through the psoas major muscle
 - emerges from lateral border of psoas; then passes downward between psoas and iliacus
- Deep to inguinal ligament

- Runs deep to the inguinal ligament to enter the thigh
- branches 4 cm inferior to the inguinal ligament (anterior and posterior branches)
- Terminal Branches
 - anterior division branches
 - medial cutaneous nerve of thigh
 - intermediate cutaneous nerve
 - motor branch to sartorius
 - motor branch to pectineus
 - posterior division branches
 - saphenous nerve
 - motor branches to
 - rectus femoris
 - vastus medialis
 - vastus lateralis
 - vastus intermedius
 - articular branches to knee

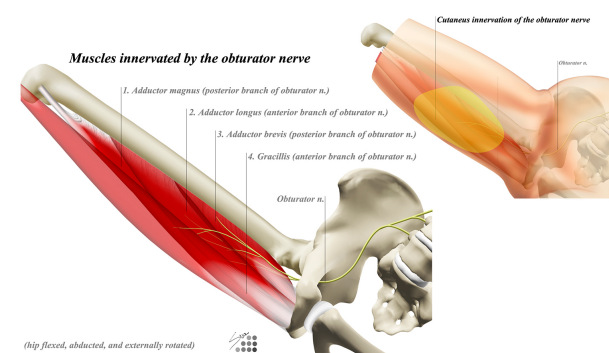
Injury & Clinical Conditions

- **Femoral nerve damage**
 - causes
 - direct trauma is most common
 - iatrogenic (ie. percutaneous proximal interlocking screw placement through IM nail)
 - compression from tumor or hematoma
 - clinical signs
 - motor
 - quadriceps wasting
 - loss of knee extension and some hip flexion (iliacus, pectinues)
 - sensory
 - loss of sensation over front and medial side of thigh (anterior and medial cutaneous nerves of the thigh)
 - loss of sensation over medial aspect of lower leg and foot (saphenous nerve)

110- Obturator Nerve

Innervation

- Sensory
 - medial aspect of the thigh
 - articular branches to hip and knee joints
- Motor
 - obturator externus
 - adductor longus
 - adductor magnus
 - adductor brevis
 - gracilis



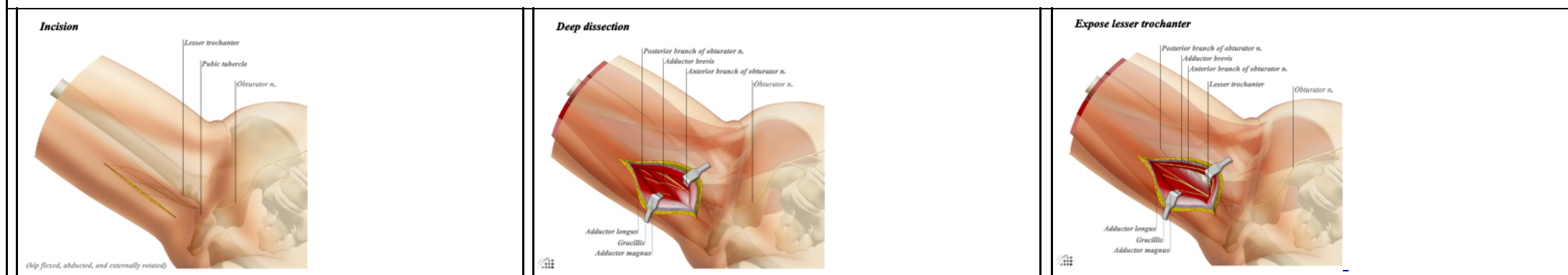
Course of Obturator Nerve

- Origin
 - obturator nerve comes from L2, L3, and L4
- Course
 - **substance of psoas**
 - the obturator descends through the substance of the psoas and exits medially near pelvic brim
 - **behind common iliac vessels**
 - passes behind common iliac vessels, lateral to the hypogastric vessels
 - **anterior to obturator vessels**
 - runs along lateral wall of lesser pelvis, anterior to the obturator vessels
 - **enters obturator foramen**
 - enters the superior aspect of the obturator foramen
 - it then enters the thigh through the obturator canal
- Terminal branches
 - **anterior branch**
 - innervates
 - adductor longus
 - adductor brevis
 - gracilis
 - **posterior branch**
 - innervates

- adductor magnus
- adductor brevis
- obturator externus
- these branches are separated by the obturator externus and adductor brevis

Relevant Approaches

- Hip Medial Approach



- Modified Stoppa Approach ▶

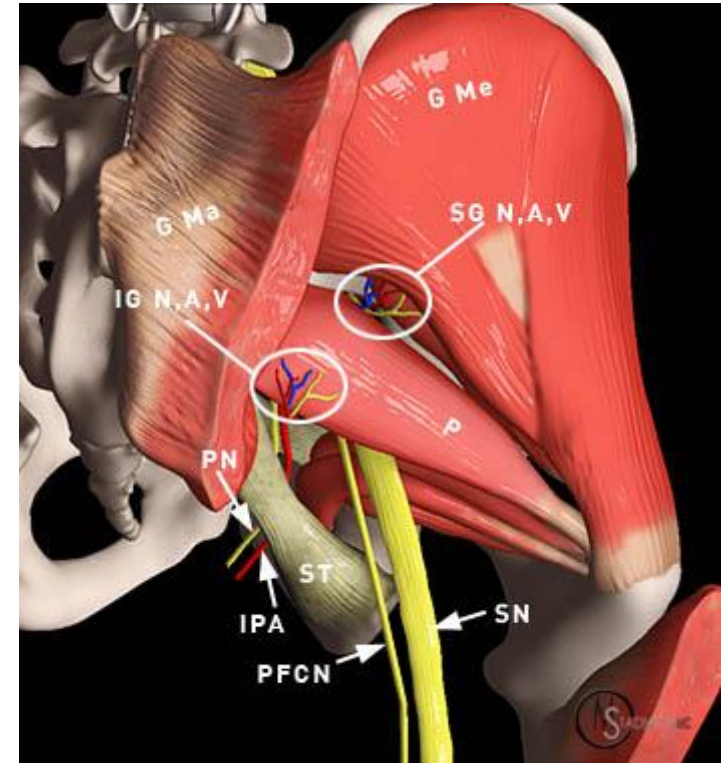
Clinical Conditions

- Obturator nerve injury
 - can be an iatrogenic injury from retraction during the modified Stoppa approach

111- Superior Gluteal Nerve

Innervation

- Motor
 - gluteus medius
 - gluteus minimus
 - tensor fascia lata
- Sensory
 - none



Origin

- Lumbo-sacro plexus
 - nerve roots L4-S1

Course

- Greater sciatic notch
 - leaves pelvis through the greater sciatic notch
 - contents of greater sciatic notch include
 - superior gluteal nerve
 - superior gluteal artery and vein
 - runs over the piriformis between the gluteus medius and minimus
 - do not split gluteus medius more than 5 cm proximal to greater trochanter due to risk of denervating the muscle
 - at risk during the lateral (Hardinge) approach to the hip
- Terminal branches
 - branch to gluteus medius
 - branch to gluteus minimus
 - branch to tensor fascia lata

Nerve Injury & Clinical Conditions

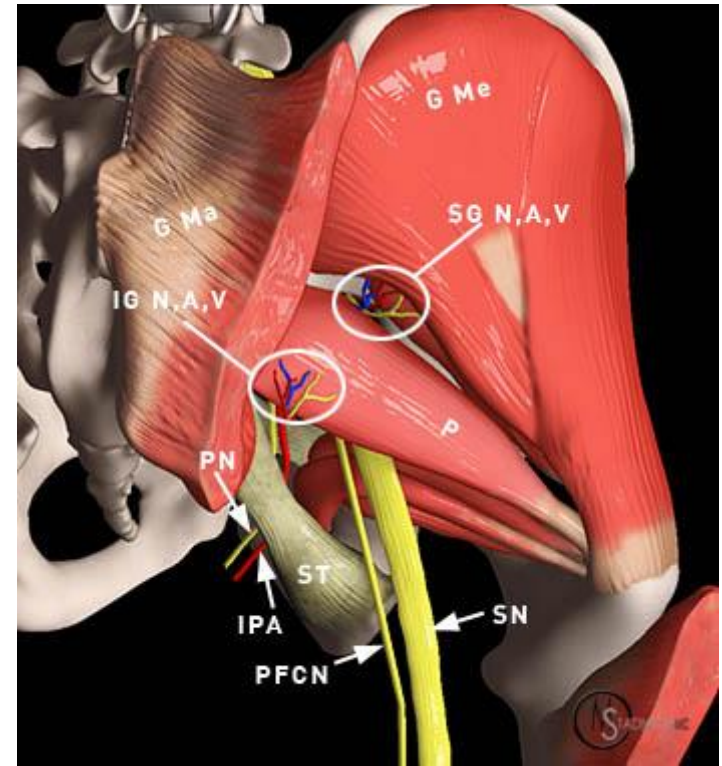
- **Gluteus Medius Nerve Injury**
 - Trendelenburg Gait

- the tilted pelvis and shifted center of gravity are compensated through shifts in the upper body over the affected hip during the period of single-leg stance.
- the combination of sagging pelvis and upper body shifts results in a classic waddling gait.

112- Inferior Gluteal Nerve

Innervation

- Motor
 - [gluteus maximus](#)
- Sensory
 - none



Origin

- Originates from the [sacral plexus](#)
 - carries fibers from [L5, S1, and S2](#)

Course of Nerve

- Arises from the ventral divisions of L5, S1 and S2
- Leaves the pelvis through the greater sciatic foramen
- Runs underneath the piriformis
- Divides into muscular branches to supply the [gluteus maximus](#)

Nerve Injury & Clinical Conditions

- Injury to this nerve leads to a gluteus maximus lurch
 - when gluteus maximus is weak/injured, trunk extends (lean back) on heel-strike on weakened side
 - compensates for weakness of hip extension

113- Sciatic Nerve

Innervation

- Tibial division
 - motor
 - semitendinous
 - semimembranous
 - long head biceps femoris
 - gastrocnemius
 - popliteus
 - ▶_plantaris
 - ▶_soleus
 - ▶_tibialis posterior
 - ▶_flexor digitorum longus
 - ▶_flexor hallucis longus
 - sensory innervation
 - none
- Peroneal division
 - motor
 - ▶_abductor hallucis
 - ▶_flexor digitorum brevis
 - ▶_flexor hallucis brevis
 - ▶_foot lumbricals
 - ▶_quadratus plantae
 - ▶_flexor digiti minimi
 - ▶_adductor hallucis
 - ▶_foot interossei
 - ▶_abductor digiti minimi
 - sensory
 - articular branch to knee joint
 - **sural nerve** branch
 - runs distal with the small saphenous vein
 - anastomoses with a branch from the peroneal nerve
 - continues distal on lateral aspect of the Achilles tendon
 - terminates as the **lateral dorsal cutaneous nerve** of the foot

- **common peroneal nerve**

- **motor**

- short head of biceps femoris

- **deep peroneal nerve**

- **motor**

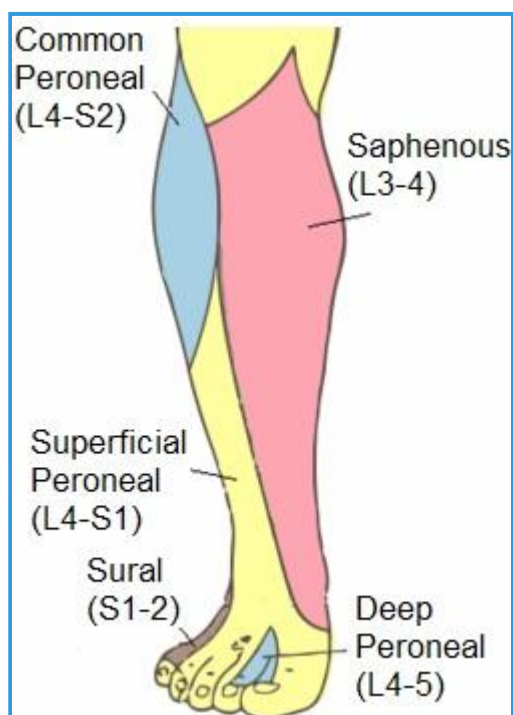
- **leg**

- tibialis anterior
- extensor digitorum longus
- peroneus tertius
- extensor hallucis longus

- **foot**

- extensor digitorum brevis (lateral terminal branch)
- extensor hallucis brevis (lateral terminal branch)

- **sensory**



- articular branch to the ankle joint
- medial terminal branch: **1st dorsal webspace**

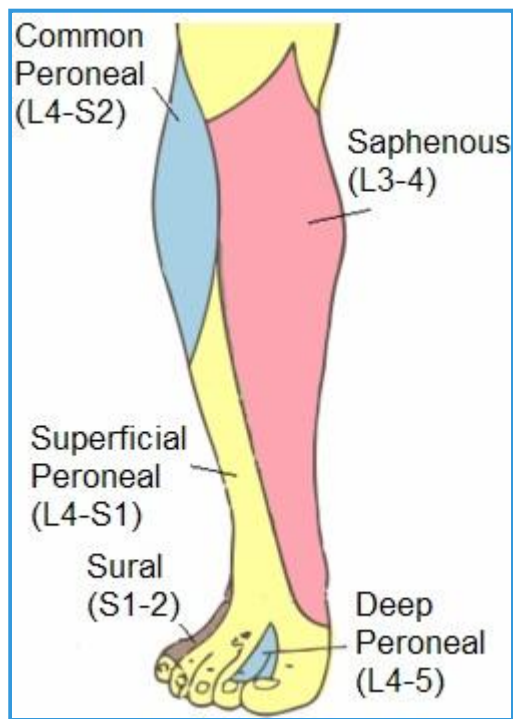
- **superficial peroneal nerve** ▶

- **motor**

- **lateral compartment of leg**

- ▶_peroneus longus
- ▶_peroneus brevis

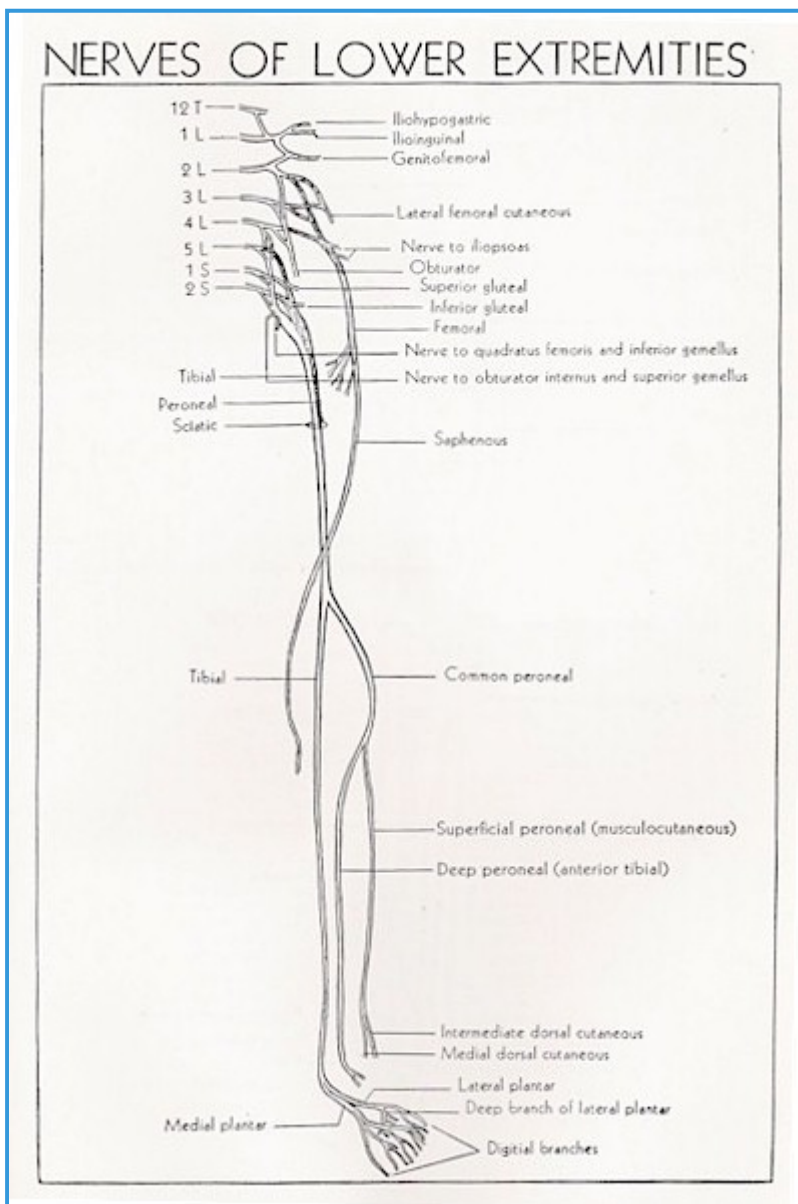
- **sensory**



- majority of skin on the dorsum of foot, excluding webspace between hallux and second digit (deep peroneal nerve)
- anterolateral distal 1/3 of leg

Origin

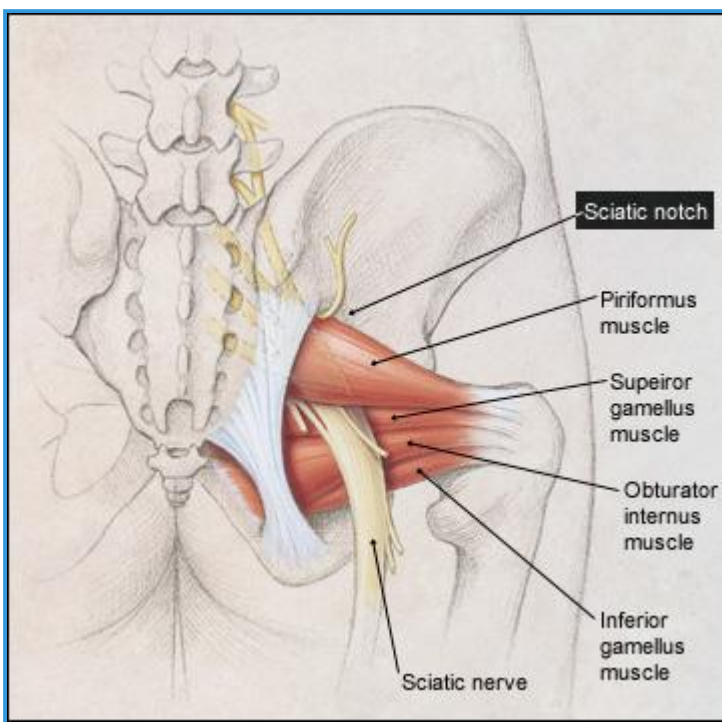
- The sciatic nerve originates from lumbosacral plexus L4-S3



- tibial division
 - originates from anterior **preaxial branches** of L4,L5,S1,S2,S3
- peroneal division
 - originates from from **postaxial branches** of L4,L5,S1,S2

Course

- Exits sciatic notch



- runs anterior or deep to piriformis
- runs posterior or superficial to short external rotators (superior gemellus, inferior gemellus, obturator internus)
- **Posterior leg**
 - It then runs down the posterior leg where it breaks into its three main divisions at the level of the mid thigh
- **Terminal branches**
 - **common peroneal nerve**
 - **tibial nerve**

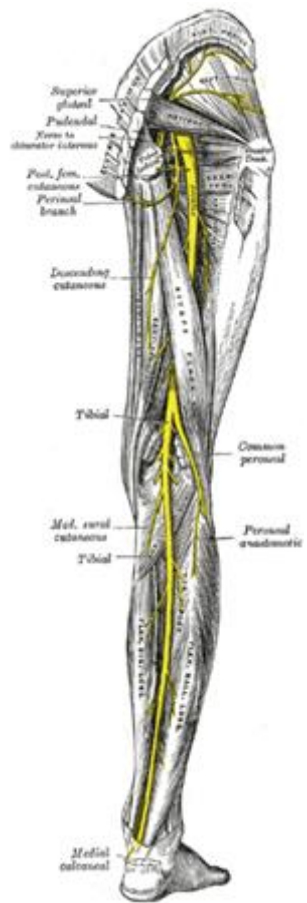
Injury & Clinical Conditions

- Iatrogenic Injury
 - methods to prevent injury
 - routine visual identification not advised in primary THA
 - palpation recommended
 - visual identification is recommended in revision THA
 - hip extension, knee flexion decreases tension on nerve

114- Tibial Nerve

Innervation

- Motor
 - gastrocnemius
 - popliteus
 - soleus
 - tibialis posterior
 - flexor digitorum longus
 - flexor hallucis longus
 - abductor hallucis
 - flexor digitorum brevis
 - flexor hallucis brevis
 - foot lumbricals
 - quadratus plantae
 - flexor digiti minimi
 - adductor hallucis
 - foot interossei
 - abductor digiti minimi
- Sensory
 - articular branch to knee joint
 - **sural nerve** branch
 - runs distal with the small saphenous vein
 - anastomoses with a branch from the peroneal nerve
 - continues distal on lateral aspect of the Achilles tendon
 - terminates as the **lateral dorsal cutaneous nerve** of the foot
- Reflexes
 - none



Origin

- L4-S3 roots
 - lumbosacral plexus
 - sciatic nerve
 - **tibial nerve**
 - **medial plantar nerve**

- lateral plantar nerve

Course of Tibial Nerve

- Originates from the **sciatic nerve**
 - splits from sciatic nerve in distal thigh
 - passes through popliteal fossa
 - runs under arch of **soleus**
 - continues distally on undersurface of **soleus**
 - passes into foot posterior to the medial malleolus

Terminal Branches

- Medial plantar nerve
 - runs under the abductor hallucis and superficial to the flexor digitorum brevis
 - gives motor branches to:
 - **abductor hallucis**
 - **flexor digitorum brevis**
 - **flexor hallucis brevis**
 - **1st lumbrical**
 - gives sensory branches to:
 - plantar medial 3 1/2 digits
 - medial 3 1/2 dorsal nailbeds
- Lateral plantar nerve
 - runs between the flexor digitorum brevis and quadratus plantae
 - gives motor branches to:
 - **quadratus plantae**
 - **flexor digiti minimi**
 - **adductor hallucis**
 - **interossei**
 - **three lateral lumbricals**
 - **abductor digiti minimi**
 - gives sensory branches to:
 - lateral plantar surface
 - lateral 1 1/2 toes
 - lateral 1 1/2 dorsal nailbeds

Nerve Injury & Clinical Conditions

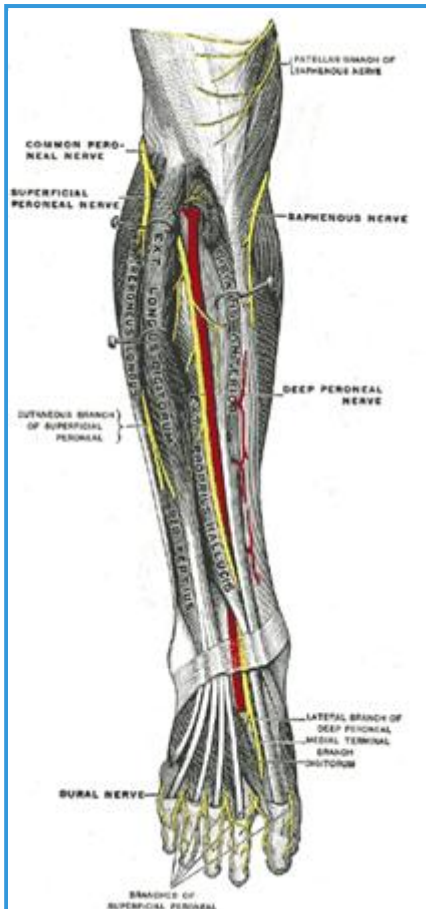
- Tibial Nerve Injury
 - can result from direct trauma or peripheral neuropathy (less common)
 - leads to:

- loss of ankle and toe plantarflexion
- weakened foot inversion
- sensory loss to the plantar aspect of the foot

115- Deep Peroneal Nerve

Innervation

- Motor
 - leg

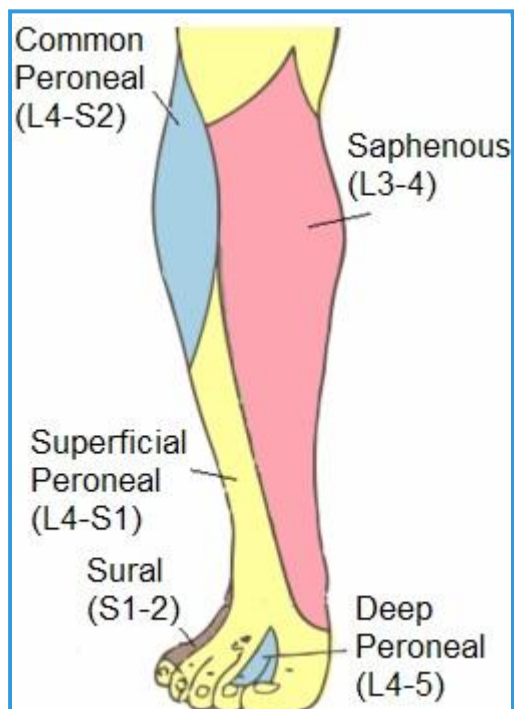


- tibialis anterior
- extensor digitorum longus
- peroneus tertius
- extensor hallucis longus

- foot

- lateral terminal branch: extensor digitorum brevis and extensor hallucis brevis

- Sensory



- articular branch to the ankle joint

- medial terminal branch: 1st dorsal webspace
- Reflex
 - none

Origin

- CNS origin
 - is derived from the common peroneal (fibular) nerve, which is made of the dorsal branches of L4 and L5

Course

- Bifurcation of the common peroneal nerve
 - between the fibula and upper part of the peroneus longus
- Interosseous membrane
 - passes deep to extensor digitorum longus along anterior surface of interosseous membrane
- Crosses anterior tibial artery
 - runs initially lateral to the anterior tibial artery, but crosses over to run on the medial side by the time it reaches the ankle joint
- Anterior tarsal tunnel
 - deep peroneal nerve passes through the anterior tarsal tunnel
- Terminal branches
 - lateral terminal branch
 - medial terminal branch

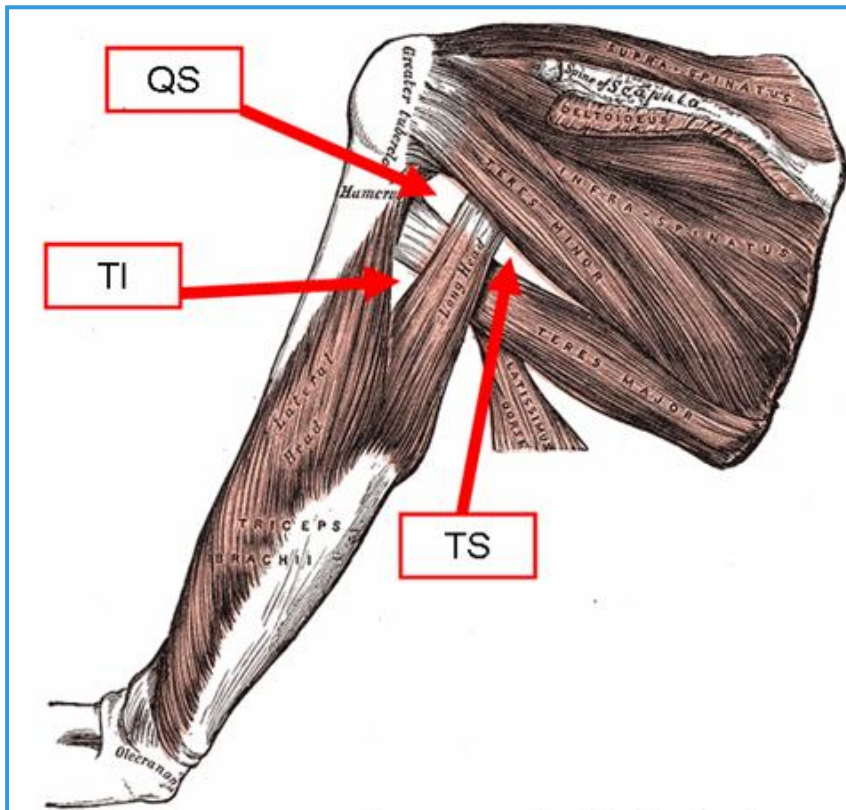
Injury & Clinical Conditions

- Damage to this nerve results in **foot drop**
 - most common isolated mononeuropathy of the lower extremity
 - systemic causes of injury
 - lower motor neuron disease
 - diabetes
 - ischemia
 - inflammatory conditions
 - iatrogenic injuries
 - TKA
 - surgical approach
 - traumatic injuries
 - treatment consists of observation followed by tendon transfers for those that do not resolve

116- Quadrangular Space Triangular Space Triangular Interval

Introduction

- Three important spaces of the shoulder that are bordered by the triceps include



- quadrangular space
- triangular space
- triangular interval

Quadrangular Space

- Borders
 - medial: long head of triceps
 - lateral: humeral shaft
 - superior: teres minor
 - inferior: teres major
- Contents
 - axillary nerve
 - passes through the quadrilateral space on its path to innervate the teres minor and deltoid and provide sensation to the lateral arm
 - posterior humeral circumflex artery

Triangular Space

- Borders
 - inferior: teres major

- lateral: long head of triceps
- superior: lower border of teres minor

- Contents

- **scapular circumflex artery**

Triangular Interval

- Borders

- superior: teres major
- lateral: lateral head of the triceps or the humerus
- medial: long head of the triceps

- Contents

- **profunda brachii artery**
- **radial nerve**

117- Posterior Approach To Knee

- Introduction
 - Overview
 - primarily a neurovascular approach
 - pathology related to posterolateral and posteromedial corners of the knee should be approached using lateral and medial approaches to knee respectively
 - Indications
 - neurovascular repair in traumatic injury
 - PCL avulsion repair
 - gastrocnemius recession in knee contractures
 - hamstring lengthening
 - Baker's / popliteal cyst excision
 - tibial nerve compression by soleus
- Key Anatomy
 - Muscles
 - gastrocnemius
 - semimembranosus
 - semitendinosus
 - Nerves
 - medial sural nerve
 - Vessels
 - small saphenous vein
 - popliteal artery and vein
 - genicular vessels (two superior, two inferior, one middle)
- Internervous Plane
 - There is no true internervous plane
- Preparation & Positioning
 - Preparation
 - table

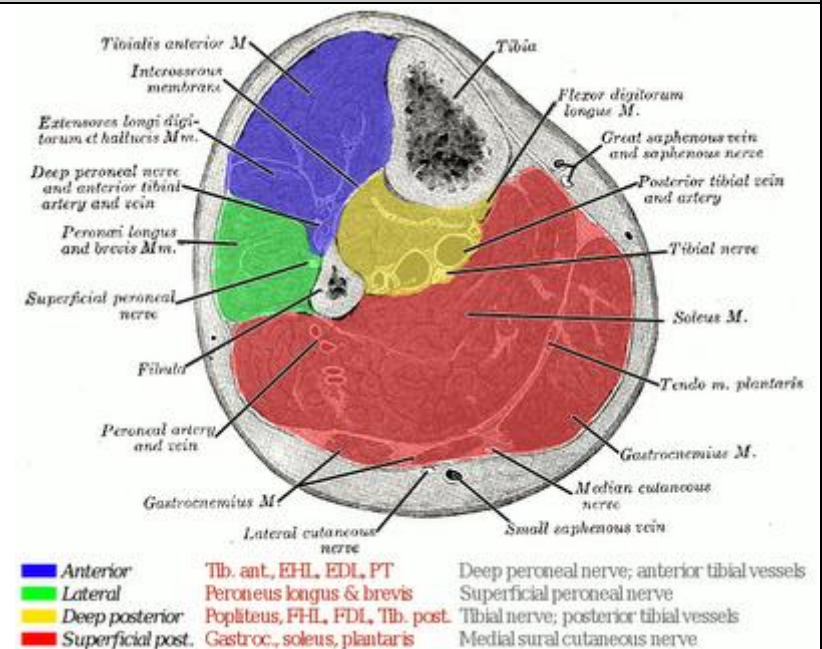
- use radioopaque table when performing fixation (PCL avulsion)
- tourniquet
 - used in most cases except when a vascular repair is being performed
 - may delay exsanguination until vein is identified
- Position
 - patient is placed prone
- Approach
 - Incision
 - identify superficial landmarks
 - gastrocnemius
 - semimembranous
 - semitendinosus
 - biceps femoris
 - make lazy-S incision running
 - from lateral biceps femoris
 - to medial head of gastrocnemius muscle and into calf
 - Superficial Dissection
 - make subcutaneous skin flaps
 - generous skin flaps will facilitate closure
 - identify small saphenous vein and medial sural nerve
 - medial sural nerve runs on lateral side of vein
 - small saphenous vein can assist in locating the medial sural nerve
 - the medial sural nerve is a branch of the tibial nerve and can be used as a guide and into popliteal fossa
 - incise fascia of popliteal fossa
 - make fascial incision just medial to small saphenous vein
 - dissect to apex of popliteal fossa
 - use tibial nerve as a guide to apex of popliteal fossa
 - apex is formed by semimembranous (medial) and biceps femoris (lateral)
 - mobilize common peroneal nerve
 - branches from tibial nerve at apex of popliteal fossa
 - runs along posterior border of biceps femoris
 - mobilize popliteal artery and vein
 - lies deep and medial to tibial nerve
 - popliteal vein lies medial to artery as it enters the fossa, then it curves and lies directly posterior to the artery at the midpoint in the fossa

- must identify and ligate at least one of the five genicular branches in the posterior knee that include
- Deep Dissection
 - evaluate posteromedial joint capsule
 - facilitated by detaching medial head of gastrocnemius at origin
 - evaluate posterolateral corner of joint
 - develop plane between lateral head of gastrocnemius and biceps femoris
 - facilitated by detaching lateral head of gastrocnemius at origin
- Dangers & Complications
 - Medial sural cutaneous nerve injury
 - avoid injury by entering fossa medial medial to small saphenous vein (nerve lies lateral)
 - injury make lead to painful neuroma or anesthesia
 - Tibial nerve injury
 - injury at this level leads to paralysis of foot and toes flexors
 - Common peroneal nerve injury
 - injury at this level leads to paralysis of extensors and evertor of the foot
 - Popliteal artery

118- Compartments Of Leg

Compartments

- The leg is divided into four osseofascial compartments by
 - interosseous membrane of the leg
 - transverse intermuscular septum
 - anterior intermuscular (crural) septum



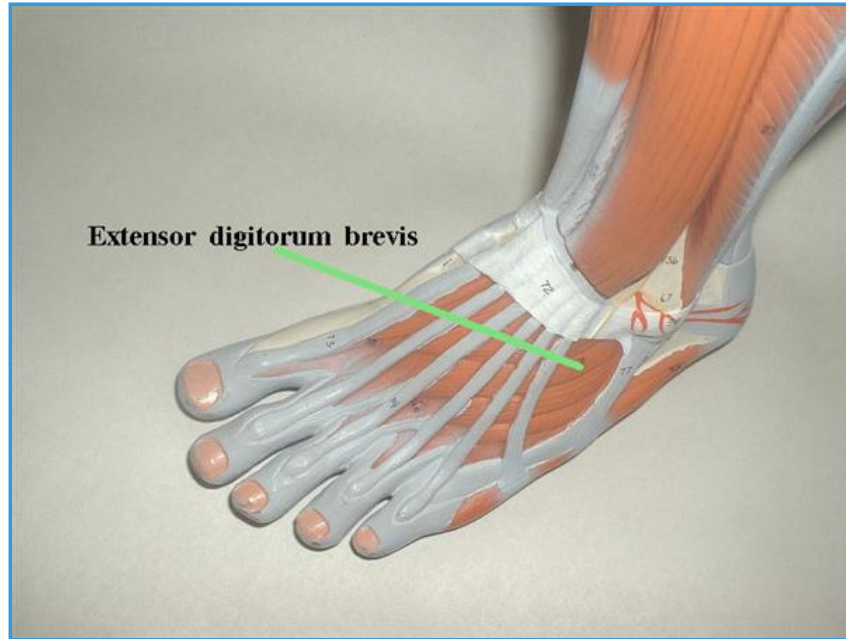
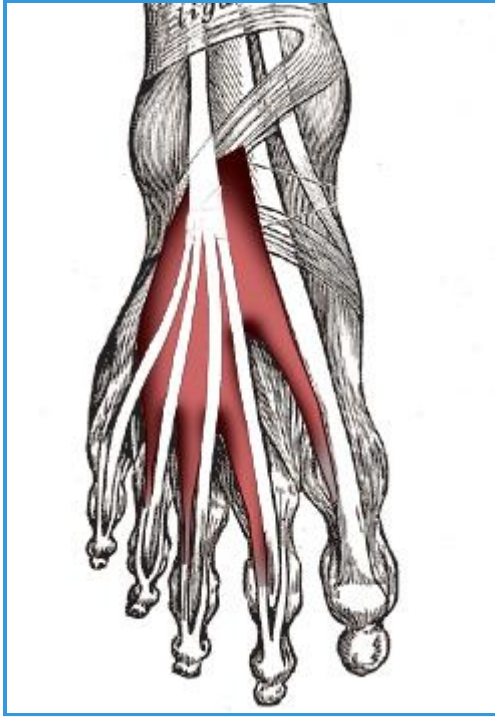
Compartment Contents

- **Anterior compartment**
 - muscular
 - tibialis anterior ▶
 - extensor hallucis longus ▶
 - extensor digitorum longus ▶
 - peroneus tertius ▶
 - neurovascular
 - deep peroneal nerve
 - anterior tibial vessels
- **Lateral compartment**
 - muscular
 - peroneus longus ▶
 - peroneus brevis ▶
 - neurovascular
 - superficial peroneal nerve
- **Superficial posterior compartment**
 - muscular
 - gastrocnemius ▶
 - plantaris ▶
 - soleus ▶
 - neurovascular
 - sural nerve
- **Deep posterior compartment**

- muscular
 - tibialis posterior ▶
 - flexor hallucis longus ▶
 - flexor digitorum longus ▶
 - popliteus ▶
- neurovascular
 - tibial nerve
 - posterior tibial vessels

119- Extensor Digitorum And Hallucis Brevis

Images



Summary

Extensor Digitorum & Hallucis Brevis

<p>■ Origin</p>	<p>■ Dorsal surface of calcaneus</p>	
<p>■ Insertion</p>	<p>■ Base of PP of great (EHB), 2nd, 3rd, 4th (EDB) toes</p>	
<p>■ Action</p>	<p>■ Extends toes</p>	
<p>■ Innervation</p>	<p>■ Deep peroneal nerve (L5)</p>	
<p>■ Arterial supply</p>	<p>■ Dorsalis pedis artery</p>	

120- Long Thoracic Nerve

Anatomy of Long Thoracic Nerve

- **Innervation**

- serratus anterior

- **Origin**

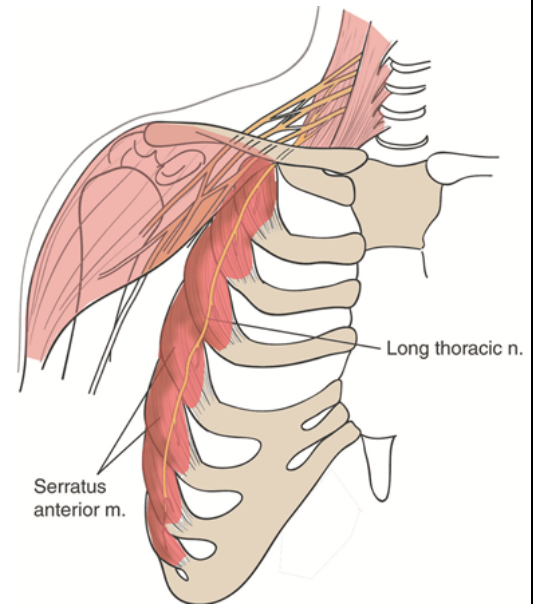
- long thoracic nerve is derived from ventral rami of C5, C6, C7 & roots of brachial plexus
 - C8 contribution in 8% of patients

- **Course**

- runs downward & passes anterior to scalenus posterior muscle
- courses distal and laterally deep to clavicle and superficial to first and second rib
- runs inferior on chest wall along mid axillary line on the outer surface of the serratus anterior for a distance of 22 to 24 cm

- **Terminal Branches**

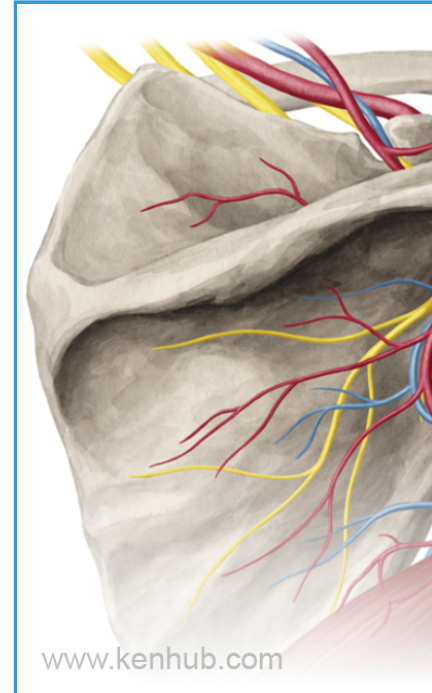
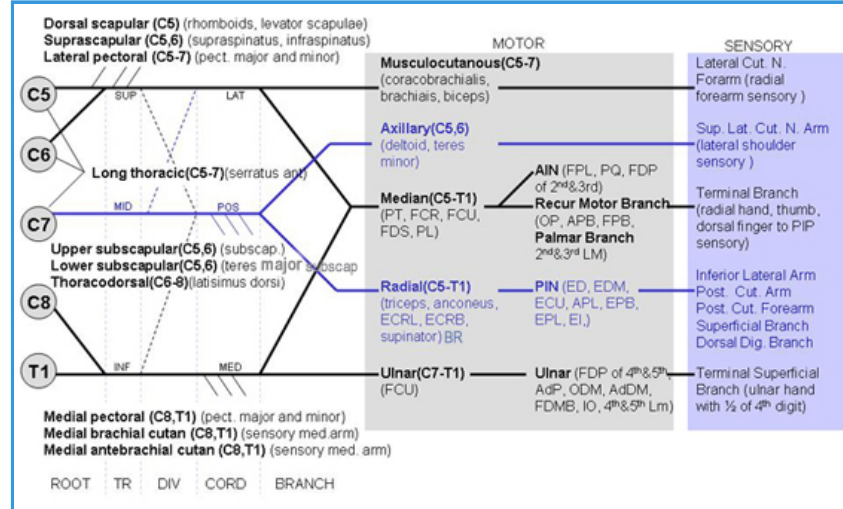
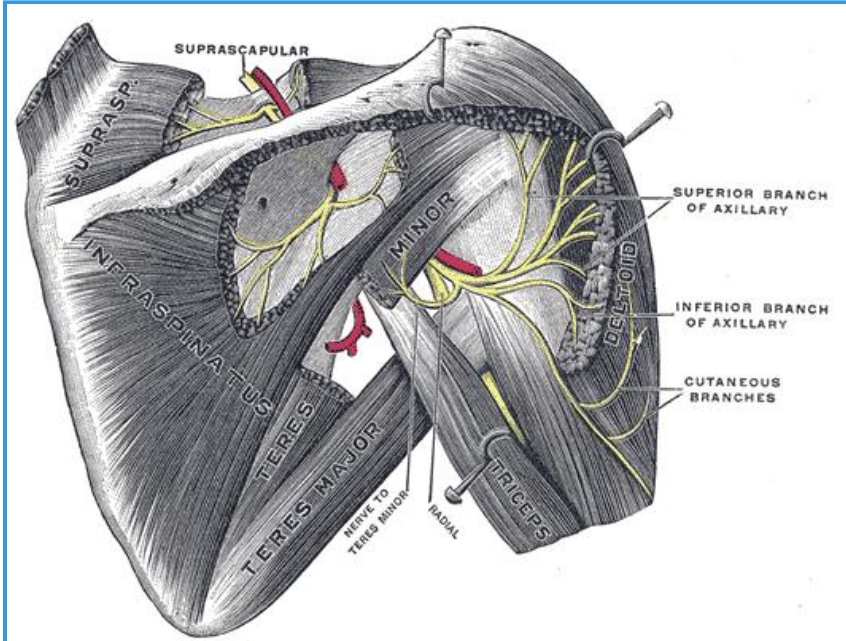
- terminal branches are small branches of long thoracic nerve that penetrate into serratus anterior muscles



Clinical Condition

- Scapular Winging

121- Axillary Nerve



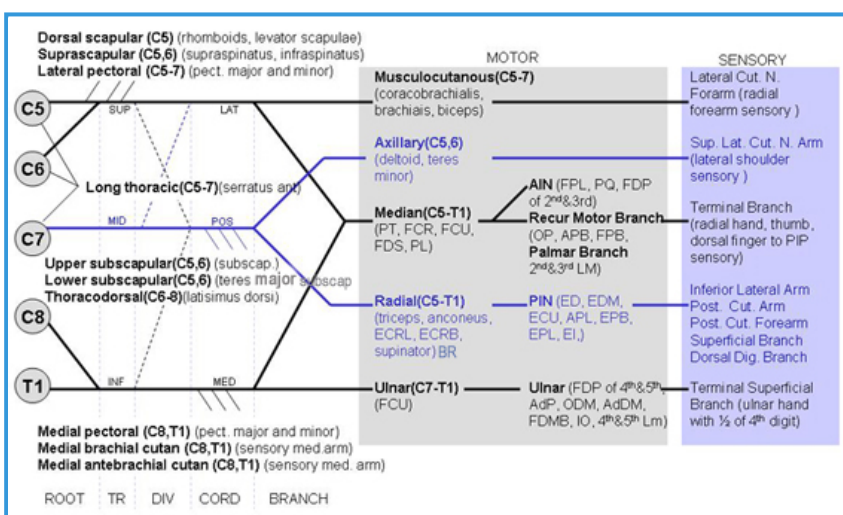
www.kenhub.com

Innervation

- Motor
 - deltoid
 - anterior and posterior branches of axillary nerve
 - teres minor
 - posterior branch of axillary nerve
- Sensory
 - superior lateral brachial cutaneous nerve
 - lateral shoulder sensation

Origin

- Brachial plexus
 - middle trunk - posterior division - posterior cord

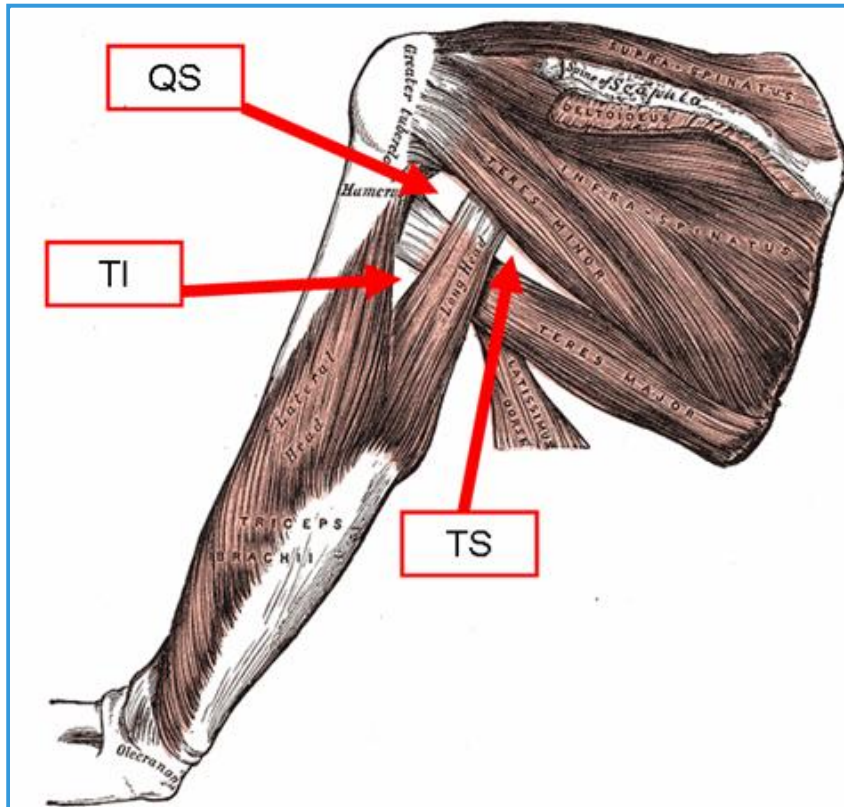


- C5 and C6 fibers

Course

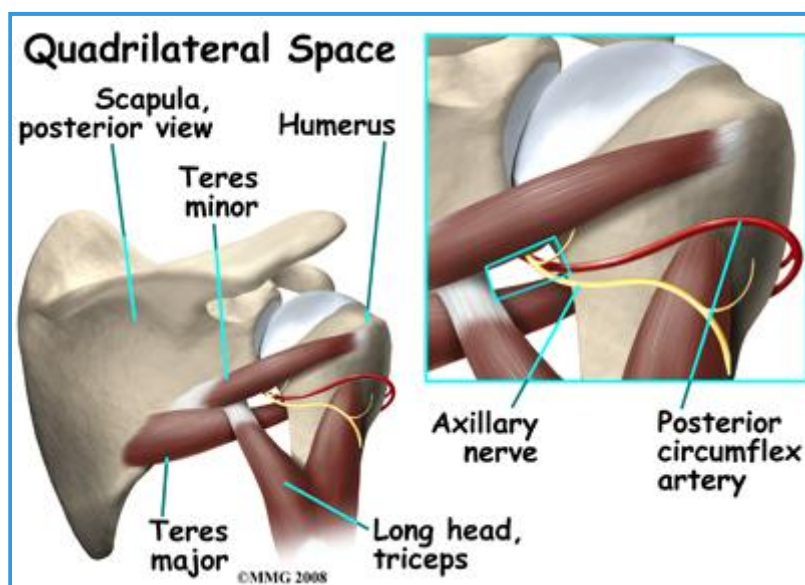
- Arises from the posterior cord of the brachial plexus
 - anterior to the subscapularis muscle and posterior to the axillary artery
 - courses along anterior subscapularis to inferior edge

- passes beneath glenohumeral joint capsule
 - gives off **articular branches** that supply the capsule
- Travels through the **quadrangular space**
 - location
 - lateral to triangular space and superomedial to triangular interval



- boundaries
 - superior - teres minor
 - inferior - teres major
 - medial - long head of triceps brachii
 - lateral - surgical neck of the humerus

- contents
 - **axillary nerve**



- posterior circumflex humeral artery
- divides into anterior and posterior branches within the quadrangular space
- Terminal branches

- **anterior branch**

- wraps around the surgical neck of the humerus, running in the deep deltoid fascia with the **posterior circumflex humeral artery**
- supplies the **anterior deltoid** muscle ▶▶
- traditional "safe zone" from lateral acromion is 5 cm

- anterior branch has been shown to run 5-7 cm distal to the lateral edge of the acromion
 - arm abduction to 90° decreases the distance between acromion and nerve by 30%
- damage to nerve with a muscle split will denervate the anterior deltoid
- terminates in small cutaneous branches supplying the anterior and anterolateral shoulder
- **posterior branch**
 - supplies the **teres minor** and **posterior deltoid** muscles
 - branch to the teres minor is closest to glenoid labrum and most susceptible to injury during arthroscopy
 - pierces the deep fascia
 - terminates as the **superior lateral brachial cutaneous nerve** supplying the lateral shoulder

Clinical Conditions

- **Quadrangular space syndrome**

- compression of the axillary nerve within the quadrangular space
- overhead athletes
- muscle hypertrophy or paralabral cysts
- present with vague posterior or posterolateral shoulder pain
- weakness +/- atrophy of teres minor and deltoid muscles
- most treated successfully without surgery but can undergo nerve decompression in recalcitrant cases

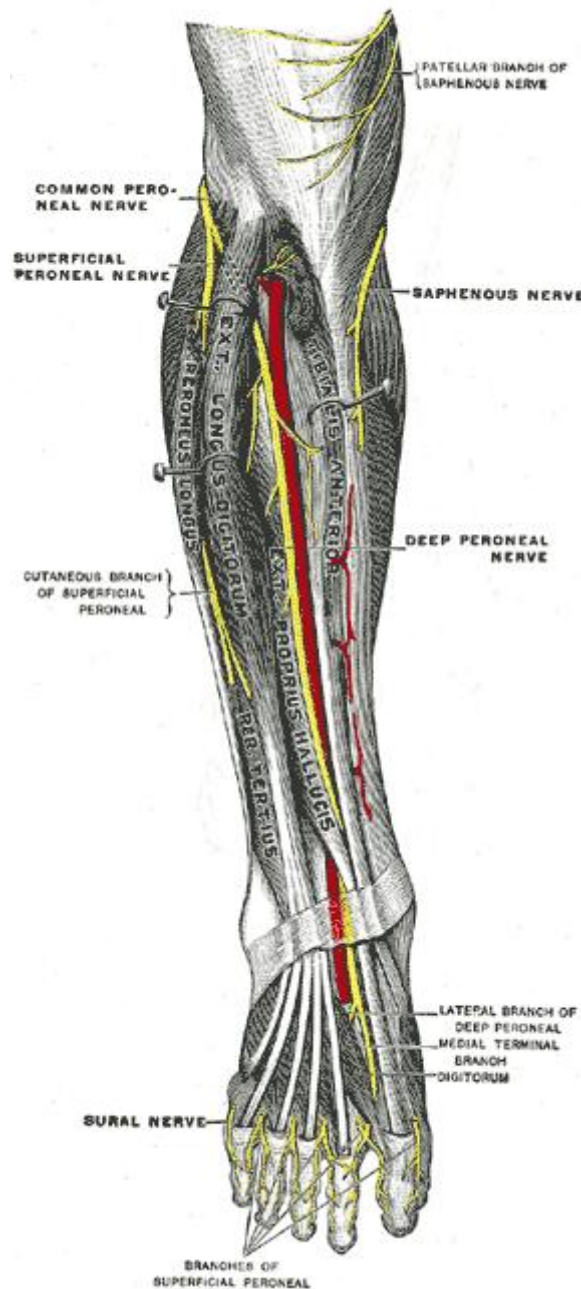
- **Iatrogenic injury** ?

- arthroscopic surgery
 - the posterior branch has an intimate association with the inferior glenoid and capsule
 - can be damaged during arthroscopic HAGL repair or inferior capsule release
- Hornblower's test
 - detects teres minor weakness
 - place shoulder in 90° abduction and 90° external rotation
 - positive if patient unable to maintain external rotation, arm falls into internal rotation

122- Superficial Peroneal Nerve

Innervation

- Motor
 - lateral compartment of leg
 - peroneus longus
 - peroneus brevis
- Sensory
 - majority of skin on the dorsum of foot, excluding webspace between hallux and second digit (deep peroneal nerve)
 - anterolateral distal 1/3 of leg
- Reflex
 - none



Origin

- CNS origin
 - terminal branch of the common peroneal nerve
 - nerve roots: L4-S1

Course

- **Bifurcation of the common peroneal nerve**
 - begins at the bifurcation of the common peroneal nerve
- **Proximal neck of fibula**
 - passes between peroneal muscles and lateral side of extensor digitorum longus
 - gives off motor branches to peroneus longus and brevis
- **Anterolateral distal leg**
 - descends and supplies only sensory innervation
- **Deep crural fascia**
 - superficial peroneal nerve pierces deep crural

- **Terminal branches**

- medial dorsal cutaneous nerve
- intermedial dorsal cutaneous nerve

Injury & Clinical Conditions

- **Superficial peroneal nerve entrapment**

- mechanism
 - ankle sprains and ankle twisting causing stretching of superficial peroneal nerve
 - compression where the nerve exits the deep fascia of the leg
- presentation
 - pain and paresthesias over dorsum of foot

- **Direct damage**

- mechanism
 - fractures of the proximal fibula
 - perforating injury to lateral leg
- presentation
 - loss of eversion
 - motor to peroneus longus and brevis injured
 - loss of sensation over most of dorsal foot and anterolateral aspect of distal leg

